

SURGICAL TECHNIQUES FOR BREAST RECONSTRUCTION AFTER CANCER REMOVAL

Falgari, Maria Antonietta

Master's thesis / Diplomski rad

2024

Degree Grantor / Ustanova koja je dodijelila akademski / stručni stupanj: **University of Rijeka, Faculty of Medicine / Sveučilište u Rijeci, Medicinski fakultet**

Permanent link / Trajna poveznica: <https://um.nsk.hr/um:nbn:hr:184:508650>

Rights / Prava: [In copyright](#) / [Zaštićeno autorskim pravom.](#)

Download date / Datum preuzimanja: **2025-01-18**



Repository / Repozitorij:

[Repository of the University of Rijeka, Faculty of Medicine - FMRI Repository](#)



UNIVERSITY OF RIJEKA

FACULTY OF MEDICINE

**UNIVERSITY INTEGRATED UNDERGRADUATED AND GRADUATED
STUDY OF MEDICINE IN ENGLISH LANGUAGE**

FALGARI MARIA ANTONIETTA

**SURGICAL TECHNIQUES FOR BREAST RECONSTRUCTION AFTER
CANCER REMOVAL**

GRADUATION THESIS

RIJEKA, 2024

UNIVERSITY OF RIJEKA

FACULTY OF MEDICINE

**UNIVERSITY INTEGRATED UNDERGRADUATED AND GRADUATED
STUDY OF MEDICINE IN ENGLISH LANGUAGE**

FALGARI MARIA ANTONIETTA

**SURGICAL TECHNIQUES FOR BREAST RECONSTRUCTION AFTER
CANCER REMOVAL**

GRADUATION THESIS

RIJEKA, 2024

Thesis mentor: Aleksandra Pirjavec Mahić, MD, PhD, Professor

The graduation thesis was graded on 30-04-24 in Rijeka, before the Committee composed of the following members:

1. Damir Grebić , MD, PhD, Professor (Committee Head)
2. Harry Grbas, MD, PhD, Professor
3. Marko Zelić, MD, PhD, Professor

The graduation thesis contains 49 pages, 12 figures, 0 tables, 39 references.

Preface

Before the beginning of my elaborate I would like to thank few people that tagged me along this long period studies.

I want to thank my parents for the support and the love they provided me with during this journey. It wasn't easy but without you it wouldn't be possible at all.

I want to thank my friends and the family for keeping me with you and providing with the love even if I was so many kilometers away, the love will never be forgotten, and I will always keep you in my heart.

My life in Rijeka, and most of all, my studies wouldn't have been the same without few important people:

Ana, thank you, for being the best professor in anatomy. You made me fall in love with medicine and you made me realize that I took the right choice; those anatomy hours whit you were my light in between never-ending classes that put me through hell the first years. You saved me again when you thought me how to read slides for histology first and pathology after, and now you helped me with this elaborate so I can surely say that I wouldn't be the student that I am today without you. Other than the academic life you were part of my Rijeka life, thank you for all the sushi and nachos that we shared and the love and peace you provided me with even by sitting by each other looking at the sky. You will forever be in my heart.

Thank you, Paola, for being the best helper that I could have asked for. Through respect and kindness, I gained your trust and other than helping me with university, you helped me in my life in Rijeka and we became friends, and I am really happy to define you so. You were always ready to spend time with me sharing coffee and stories talking about shopping, Italy, food, and of course our favorites TV shows. I am waiting for you to come to Italy, and I hope you'll visit me soon to spend more quality time together.

Dear Neda, you were my classmate first and you are one of my closest friends now. You were the student I would want to be, always on top of your game, always ready to help everyone and with a smile on. The joy that every time I have when I see you it's not explainable by words, for me you represent the sun, and whenever I am with you, I am sure that the time will fly, and I will be happier. I will always remember the hours spent till midnight to learn Head and Neck anatomy, one of the hardest moments of our career but one of the best memories as well. Thank you for having me at your home places, for showing be your life over there, for introducing me

to your parents and always making me feel home. Thank you for all the Mc Donald's that we shared, thank you for all the support through ups and downs, you are my person, you're my Cristina (because we both know that you're smarter) and I hope I am your Meredith, love you. In the end I want to thank all of those professors that provided me with not only medicine notions but also with kindness and were really interested in teaching something, how to be a good doctor in the human sense as well.

I would also like to thank my mentor for being supportive and welcoming for always having time to meet whenever I had the need, thank you.

Table of contents

1. INTRODUCTION.....	1
2. AIM AND OBJECTIVES	2
3. LITERATURE REVIEW	2
3.1. SURGICAL THERAPHY OF BREAST CANCER.....	2
3.2. GENERAL CONSIDERATIONS.....	4
3.3. PATIENT SELECTION.....	4
3.4. TIMING OF RECONSTRUCTION.....	4
3.5. AIMS OF THE RECONSTRUCTION	5
3.6. CHOOSING THE TECHNIQUE OF RECONSTRUCTION	6
3.7. RECONSTRUCTION VIA CUTANEOUS FLAPS, MYOCUTANEOUS, PEDUNCULATED OR FREE	6
3.7.1. THORACOEPIGASTRIC FLAP.....	6
3.7.2. CONTROLATERAL MYOCUTANEOUS THORACOEPIGASTRIC FLAP.....	8
3.7.3. LATISSIMUS DORSI FLAP.....	9
3.7.3.1. TIMING.....	10
3.7.4. TRAM FLAP.....	13
3.7.4.1. ANATOMY.....	14
3.7.4.2. PATINET SELECTION.....	15
3.7.4.3. TIMING.....	15
3.7.4.4. FLAP MAKING.....	16
3.7.4.5.EARLY COMPLICATIONS.....	20
3.7.4.6. LATE COMPLICATIONS	20
3.7.5. FREE FLAP.....	21

3.7.6.	INFERIOR GLUTEAL FREE FLAP	22
3.7.6.1.	ANATOMY.....	22
3.7.6.2.	OPERATIVE TECHNIQUE	24
3.7.6.3.	INDICATIONS	25
3.7.6.4.	DISADVANTAGES AND COMPLICATIONS	25
3.8.	EXPANDERS AND PROTHESIS IN BREAST RECONSTRUCTION	26
3.8.1.	PREFILLED PROTHESIS	26
3.8.2.	INFLATABLE PROTHESIS	26
3.8.2.1.	DISADVANTAGES	27
3.8.3.	DOUBLE CHAMBER PROTHESIS	27
3.8.4.	BEKER'S EXPANDERS AND PROTHESIS.....	27
3.8.4.1.	ADVANTAGES.....	28
3.8.4.2.	DISADVANTAGES	28
3.8.4.3.	COMPLICATIONS	29
3.9.	CAPSULE AND CAPSULAR RETRACTION	30
3.10.	IDEAL TIMING OF IMPLANT INTRODUCTION	31
3.11.	CUTANEOUS EXPANDERS IN MAMMARY RECONSTRUCTION.....	32
3.12.	NIPPLE AREOLA COMPLEX RECONSTRUCTION.....	34
3.12.1.	AREOLAR RECONSTRUCTION	34
3.12.2.	RECONSTRUCTION WITH CONTRALATERAL AREOLA.....	35
3.12.3.	INNER THIGH AREOLA RECONSTRUCTION	36
3.12.4.	GRAFTING.....	37
3.13.	NIPPLE RECONSTRUCTION	37
3.13.1.	CONTRALATERAL NIPPLE RECONSTRUCTION	37

3.13.2. AURICULAR LOBE RECONSTRUCTION.....	38
4. DISCUSSION	39
5. CONCLUSIONS.....	43
6. SUMMARY.....	44
7. LITERATURE.....	45
8. CV.....	49

1. INTRODUCTION

Breast reconstruction after mastectomy is a significant aspect of reconstructive surgery, which has developed rapidly in recent decades. The goal is to restore lost volume and shape to the thorax, achieving a harmonious and symmetrical breast morphology. This goes beyond mere aesthetics, significantly improving the patient's quality of life.

Initially, breast cancer therapy was based on demolitive techniques that altered the thoracic wall and axillary region. However, current techniques aim to minimize disfigurement while considering the patient's desire for good aesthetic outcomes. Numerous studies show no significant difference in outcome or survival between more demolitive and conservative surgeries.

The choice of surgical method depends on the stage of the neoplasm. Modern surgery is highly personalized, considering the patient's needs and expectations. The surgeon must select the quality patient, determine the best timing, and choose the most suitable surgical technique.

Patients who undergo surgery for breast cancer have the same right to reconstruction as those who have other surgeries resulting in deformity. They should be informed about the possibilities of reconstructive surgery, which can contribute to their complete recovery. The possibility of relapse does not exclude patients from reconstruction, as it can still be allowed during remission periods.

The choice between immediate or postponed reconstruction depends on the tumor staging. Immediate reconstruction is possible for small tumors, resulting in less extensive surgery, shorter duration, less tissue sacrifice, and simpler reconstructive processes. However, it has disadvantages such as difficulty organizing two surgical teams, increased surgery complexity and duration, and higher risk of complications like local necrosis, infections, and hematomas.

The surgeon and patient must agree on the aims and possibilities of reconstruction, which may require follow-up procedures like areola and nipple reconstruction. The aims of breast reconstruction include restoring scarified tissues, giving the breast projection and shape, reconstructing the axillary pillar, compensating for subclavian deficit, reconstructing the areolar-nipple complex, and creating symmetry between the two breasts.

Various techniques can be used, including those that use existing tissues with simple volume integration, reconstruction through flaps and cutaneous-subcutaneous tissues, and usage of distant flaps involving myocutaneous tissues. The choice of technique depends on the local situation after mastectomy, not the type of mastectomy performed.

In conclusion, breast reconstruction is a complex process that requires careful planning and execution. The choice of technique depends on the patient's individual situation and the surgeon's expertise. The aim is to restore the patient's physical and psychological well-being, helping them to regain their confidence and quality of life after breast cancer surgery.

2. AIM AND OBJECTIVES

As previously stated breast reconstruction after mastectomy is a topic of reconstructive surgery that developed promptly in the last few decades. This review , “Surgical techniques for breast reconstruction after cancer removal”, has the intent to go through the possible outcomes and techniques that have the aim to restore the lost volume and shape to the thorax while also keeping the focus of the aesthetic, sexual and psychological problematics that a mastectomized woman overcomes.

3. LITERATURE REVIEW

3.1.SURGICAL THERAPHY OF BREAST CANCER

Initially the therapy for breast cancer was always based on more or less demolitive techniques towards the morphology and physiology of anterior thoracic wall and axillar region. Those types of treatments were always disfiguring in regards of such an important sexual, aesthetic and so psychological anatomical region of a woman.

Nowadays the techniques are carried out to reduce to minimal the defacement with keeping in mind the need for the patient of a good aesthetic outcome and in consideration of the new information that demonstrated the inutility of excessive demolitive surgeries.

Numerous studies confronted patients that underwent more demolitive studies with those that underwent more conservative surgeries and according to those we don't have a significant difference in the outcome and survival of the studied cases (1-4).

It seems that breast cancer is not a disease of the organ but more of precocious systemic disease in which the regional control of the neoplasia is aimed mostly to the metastasis prevention which depends on other factors as well such as local biochemical and immunological conditions (5-12).

All of these findings together with more frequent early diagnosis, which is obtained thanks to awareness campaigns and better diagnostic techniques, angled therapy toward a less mutilative surgeries with regards to both the cutis, mammary gland and muscular planes of thorax.

Nevertheless, some interventions such as radical mastectomy according to Halsted method, are still used and follow precise indications.

According to his method a neoplasia that infiltrates the lymph nodes needs to be controlled though removal of breast, axillar lymph nodes, intermedial lymph vessels and considering that those are in between muscles it seems necessary to remove those as well in the same operatory event.

The outcomes of this surgery (that required removal of mammary gland, major part of the cutis, pectoralis major and minor plus adipose axillar tissue with lymph nodes) deface the woman body because it doesn't require "just" the breast removal but it takes also majority of the interested hemithorax; the pectoral muscles asportation makes the subclavicular depression, intercostal spaces and shoulder articulation much more visible and the following reconstructive surgery much more difficult. Luckily the indications for this surgery are few: tumor needs to be very infiltrative >T2, deeply situated and with massive axillar metastasis (13–17).

Less radical and more open to reconstruction method is the one according to Patey; his radical modified mastectomy requires breast asportation, the cutis, the pectoralis major fascia (leaving the muscle in position) pectoralis minor and the axillar lymph tissue. This technique offers more reconstructive possibilities because with the preservation of a part of the pectoral musculature it's possible to obtain good aesthetic results with not too complicated techniques.

Another less invasive method would be the QUART method which consist of quadrantectomy, axillar dissection and radiotherapy; it was introduced by Veronesi in 1977. It is based off the removal of large resection of the breast tissue, upper cutis and underlying pectoral fascia together with total axillar dissection with removal of all lymph nodes till the apex of the axilla. The surgery is followed two weeks after by radiotherapy with a dose of 50Gy through two opposite tangential fields with high energy photon and a surplus of 10Gy on the cutis around the surgery scar. This method showed optimal results on survival rates not only for tumors less than two centimeters but also for those that are staged as T2 NO MO meaning less than four centimeters without involvement of axillar metastasis or proves of systemic invasion.

In this moment breast surgery must be highly personalized and scheduled together with the patient taking into account:

-stage of neoplasia.

-advantages, disadvantages, and risks connected with various techniques compared with age and general conditions of the patient.

-marital status, children, profession, life philosophy and psychic equilibrium.

The actual orientation is to choose a technique that respects the oncologic radicality but at the same time has the least of the mutilation for the thoracic wall.

3.2.GENERAL CONSIDERATIONS

Today the surgeon is able to reconstruct the breast that according to the oncological principles can satisfy the aesthetical and psychological purposes of the patient. Keeping in mind this final aim it's necessary to carry out quality patient selection, good timing for the operation and the surgical technique that best fits the specific patient case.

3.3.PATIENT SELECTION

The patient that undergoes surgery due to breast cancer must have, according to general rule, the same right to do reconstruction as for those other surgeries that entailed a deformity. Every woman must be informed about the possibilities that reconstructive surgery offers which can contribute to the complete patient outcome.

The most important factor for patient selection is that the local disease must be fully eradicated. The possibility of relapse is not enough to exclude patients from reconstruction; breast cancer is considered a chronic disease for which in case of a systematic diffusion, but in a remission period, it's still allowed to undergo reconstruction.

It's important to inform the patient about what is and what is not possible to achieve with nowadays techniques; many women won't go all the way though the plan and will settle with partial results, others will never be fully satisfied.

3.4.TIMING OF RECONSTRUCTION

In choosing an immediate or postponed reconstruction we need to consider the tumor staging because it influences a series of parameter such as:

-the entity and the duration of the demolitive surgery

- the local radicality
- complexity of following reconstruction

Immediate reconstruction

In case of a small tumor, the demolitive surgery will be less extensive, less time consuming and with less tissue sacrifice and will require less complicated reconstructive processes with use of prothesis and proximal flaps. The immediate reconstruction has some disadvantages:

- difficulty in organizing two surgical equipes
- more complexity and duration of the surgery
- more exposure to possible complications such as local necrosis, infections, and hematomas
- lastly but not least we should consider that without the possibility to visualize the pre reconstructive deformity the patient won't have full comparative ability and could be unsatisfied with the difference between the reconstructed and non reconstructed breast.

It is important that there is agreement in between the patient, the oncologic surgeon, the plastic surgeon, and the patient so that the aims and the possibility to achieve those are well outlined; it is also important to explain that to achieve full results it will be necessary to do following touch ups, such as the areola and nipple reconstruction.

3.5.AIMS OF THE RECONSTRUCTION

The outline of breast reconstruction has a series of aims that should be obtained which are outlined together with the patient needs and expectations, those include:

- retrieval of scarified tissues, the cutis in particular manner
- give back the breast its projection and shape
- reconstruct the axillary pillar
- compensate the subclavian deficit if present
- reconstruct the areolar-nipple complex
- recreate the symmetry in between the two breasts with involvement of the unaffected breast is necessary.

3.6.CHOOSING THE TECHNIQUE OF RECONSTRUCTION

The surgeon can choose between various techniques that can be subdivided into three groups:
-using existing tissues with simple volume integration through introduction of a prosthesis with preceding cutaneous expansion if needed.

-reconstruction through flaps and cutaneous-subcutaneous tissues

-usage of distant flaps that involve myocutaneous tissues, pedunculated or free

In terms of which techniques should be used it is not fundamental the type of mastectomy is used but rather the local situation left by the mastectomy; it is not enough to say that a patient that underwent the Halsted technique should undergo a certain type of reconstruction but it is important to analyze the local tissue situation : in particular the cutis, subcutis and the trophism of the residual muscles.

Those elements together with the shape, dimension and general configuration of the unaffected breast should advise the use of a methodology rather than another.

3.7.RECONSTRUCTION VIA CUTANEOUS FLAPS, MYOCUTANEOUS, PEDUNCULATED OR FREE

3.7.1. THORACOEPIGASTRIC FLAP

Cutaneous flap that runs horizontally, up taken from the lateral abdominal wall with medial side in the epigastric area.

We can use this method when the anatomical situation requires, for a good reconstruction, something more than a prosthesis but at the same time the utilization of a muscular flap is unnecessary.

This flap is particularly used in case of scars that run obliquely or vertically with horizontal cutaneous and subcutaneous deficit; the fat provides excellent protection and softness.

Anatomically the flap is made up of cutaneous and subcutaneous tissue in a transversal direction on epigastric region of homolateral abdominal wall and can have a length of twenty centimeters and a width of ten, twelve. It is provided by its own vascular appendage made of the lateral branch of superior epigastric artery plus three or four smaller branches coming from internal

mammal artery; the flap made like this can be used without risks with a length:width relationship 2:1.

-Surgical technique: we start with flap mobilization from the serratus and external oblique muscles but keeping their fascia so that their own vasculature can provide nutriment to the flap. The dissection proceeds till the medial margin of the rectus fascia and can go on till half of the muscle if needed.

Following step is to cut the old scar paying attention in creating correspondence between the lower margin of the cut with the new sub mammary fold; at this point you can rotate the flap in the final position. The abdominal cutis is detached till the iliac spine so that it is possible to permit closing of the donor site. A prosthesis can be inserted during the same surgery under the pectoral muscle, if it was preserved or directly under the flap if it was radical surgery.

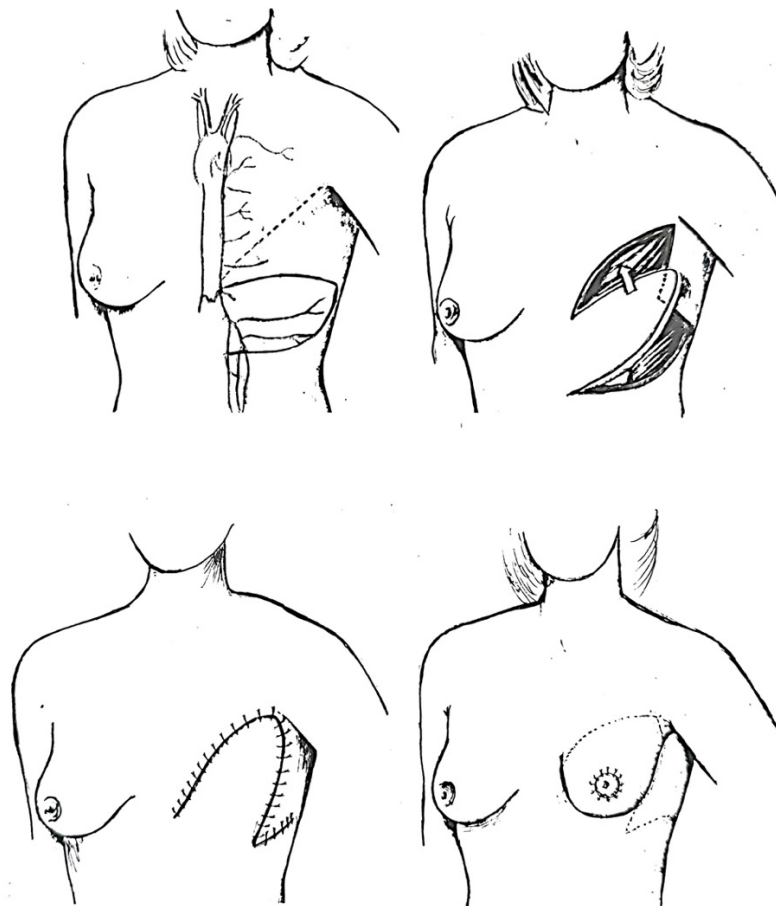


Fig.1 Reconstruction with ipsilateral thoracoepigastric flap

Advantages:

- Easy and safe
- can be rotated in vertical or oblique position
- can cover big cutaneous deficits in the lower third of the thoracic wall
- the donor site can be close for primary intention and the residual scar, which runs horizontally, won't disturb the patient because it lies in the bra curve.
- the cutis and the subcutis provide soft coverage for the prosthesis and will give more natural outcome

Disadvantages:

- it requires an additionally scar in the donor site
- it can't be used to cover the upper and lateral deficit or the thoracic wall
- it doesn't reconstruct the axillar site and the subclavicular area as well so it shouldn't be used in mastectomy according to Hastled method.

3.7.2. CONTROLATERAL MYOCUTANEOUS THORACOEPIGASTRIC FLAP

This technique is used in case of breast reconstruction with smaller breasts and remains quite easy method compared with TRAM for example.

The flap mobilization starts at the lateral margin till the abdominal rectus fascia in which the medial fascia is section instead the posterior part is left in situ; after that we will section the sternal and costal insertions so that we can mobilize the flap.

The mobilized part together with its vasculature, superior epigastric vessels, it's lifted and rotated 180° degrees and translated in the mammal area.

The cutis under the mastectomy scar is de-epithelized and the medial portion is cut and doubled to achieve augmentation the central profile of the breast.

The donor area is closed with juxtaposition of the margins and making a scar that will lie in the mammal sulcus.

The advantage of this techniques is the utilization of autologous tissue and not prosthesis, which for the patient can be a further positive aspect.

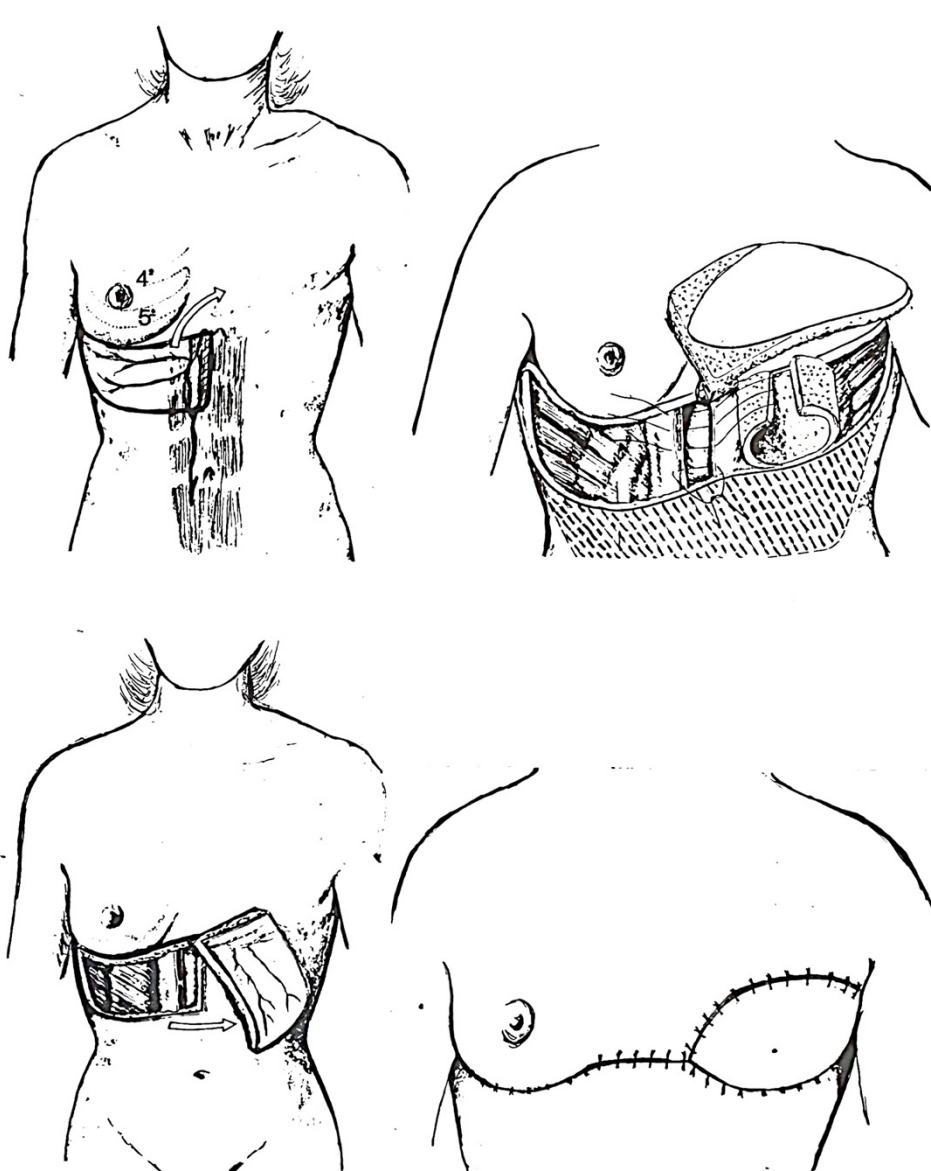


Fig.2 Contralateral musculocutaneous thoracoepigastric flap

3.7.3. LATISSIMUS DORSI FLAP

We can obtain great result using myocutaneous flap from the latissimus dorsi, thanks to its great stability over time and rather easy execution.

The latissimus dorsi is a big flat muscle that originated from the 6th thoracic vertebra and extends until the iliac spine. The vascular component is given by the subscapular artery that pierces the muscle at the axilla near its insertion on the humerus.

The use of this muscle, with its vascular component, allows the correction of the subclavicular depression and the possibility to substitute the pectoralis major and create an adequate pocket for a prosthesis. Considering that the cutaneous portion above the latissimus is nourished by perforating vessels it is possible to relocate the cutis together with the muscle so that we have a double wear.

3.7.3.1. TIMING

Planification: As first thing we need to assess the integrity of the nerves and vessels after the mastectomy, we can do so asking our patient to put a hand on a rigid surface and observe the contraction of the muscle; if the contraction functionality is preserved, we can assume that the totality of the components wasn't compromised.

If we want or need more of an in dept study we can either apply electromyographer, use the echography with color Doppler (dynamic and static study of the vascularization) or, in the end, run a CT that allows us to assess the surface, the thickness, the consistency and the relation between the true muscle and the degenerative fat part.

We then proceed at drawing the flap with the patient sitting and the cutaneous portion placement is based on:

- the rotation point will be the posterior pillar of axilla
- direction of the post mastectomy scar
- cutaneous deficit entity and/or muscular

Isolation and transposition of the myocutaneous flap of latissimus dorsi: the surgery is carried out with the patient laying on lateral decubitus of the opposite side of the mastectomy so that you can have access of the donor and receiver site at the same time.

The area on the skin is engraved following the preoperative drawing up until you reach the muscle; at that point you detach the rest of the skin that overlies the muscle.

The following step is to identify and isolate the peduncle containing: arteries, thoraco-dorsalis veins and the corresponding nerve.

You then proceed with freeing the deep fascia and separating the serratus anterior. In the upper portion the superior the inferior angle of the scapula is detached. On the medial side the aponeurotic insertion on the vertebras is sectioned.

Inferiorly, the muscle is interrupted based on how much is necessary to bridge the deficit of the receiving side; the flap that is then freed is rolled around its peduncle on the posterior pillar of the axilla.

After excising the mastectomy scar, the following step is to create a tunnel that opens communication between the cutaneous portion and the deficit area so and we can make the flap pass through.

At this point it is possible to close up the residual dorsal portion by placing a suction drainage. The dorsal scar it's usually acceptable by position, quality and extension and it's hidden by the strap of the bra.

It is convenient to change the position of the patient before going on, putting her on supine position, after which we proceed with isolation of the skin in every direction.

It is necessary then to prepare and mold the flap on the receiving site by anchoring the margin superiorly in the subclavicular region, medially on sternal margin and inferiorly the suture is corresponding to the inframammary fold. Before finishing up it is important, in case the patients want to, to introduce the prosthesis through the lateral margin which it is still open. After that we need to suture the external wall to avoid the sliding of the prosthesis.

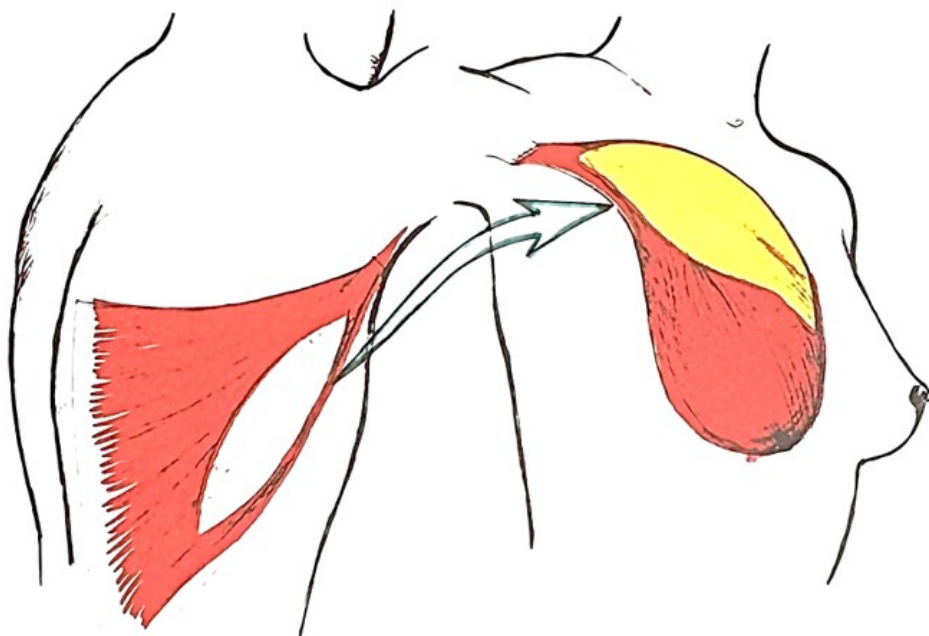


Fig.3 Positioning of the maneuvered Latissimus Dorsi

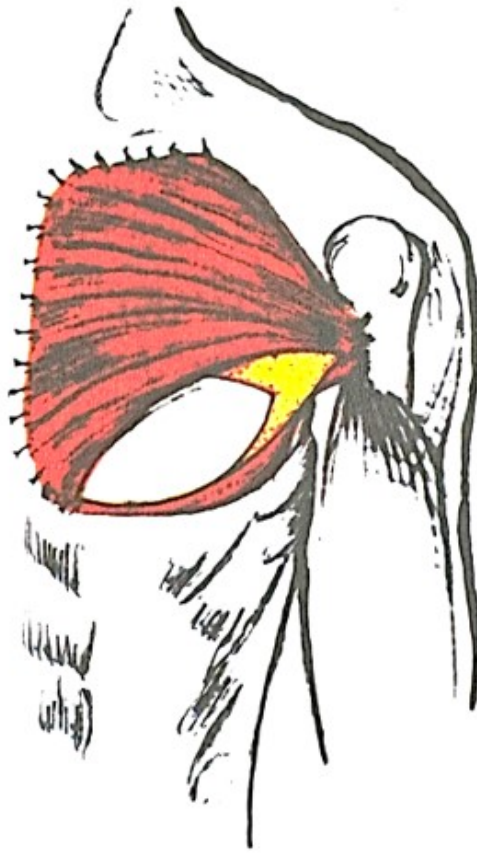


Fig.4 Fixed position

Following step is to make the cutaneous suture and to insert drainage who is left on for the next 12 to 24 hours making attention that the dressing doesn't compromise the peduncle.

The surgery can be accompanied by remodeling of the contralateral breast to correct the volume and/or the ptosis, eventually in the same operatory sitting. On the other hand, the areolar and nipple complex is never reconstructed in the same sitting, that is to avoid asymmetry due to scar retraction and settling of tissues. The convalescence is usually brief and doesn't require particular attention and the postoperative hospitalization mostly of a week.

Advantages of use of latissimus dorsi are:

- It allows the reconstruction in one sitting
- Relatively easy setup and execution
- Almost nonexistent deficit on the donor site
- Post operative scar is easily hidden by clothing and barely visible by the patient

- Broad, movable, and well adaptable flap
- It reconstitutes the deficient muscle component on the anterior thoracic wall substituting the pectoralis major and creates a pocket for a prosthesis.
- It corrects the anesthetic depression on the subclavicular site
- It reconstructs in a sufficient manner the anterior axillar pillar
- Thanks to the muscular but also skin contribution it becomes helpful in case of post radiation dermatitis in the mastectomy locus

Disadvantages of the use of latissimus dorsi can be considered:

- The usual use of a prosthesis and its eventual complication (infection, rupture, capsular retraction)
- The “patch” effect since the dorsal skin has different color and appearance compared with the anterior thorax
- As for other flap it is possible to have infection and partial dehiscence of the suture and second intention healing

Other eventual small inconvenience can be manifests precociously after the surgery or can be evident only after few years but are superimposable with those complications of other reconstructive surgeries.

The limit in the use of latissimus dorsi is, generally talking, that the nerve section and ligature of the peduncle of the muscle and axillar pillar during the mastectomy and that can create doubts about the quality and vascularity of the flap; the ligature can favor the formation of a collateral circulation in the periscapular complex. In every case, after the ligature of the peduncle or severe axilla irradiation, we can use the contralateral latissimus dorsi or other reconstructive possibilities.

3.7.4. TRAM FLAP

The lateral musculocutaneous flap of rectus abdominis is an alternative for the latissimus dorsi when the local situation doesn't permit the use or when it's required a major quantity of tissue. It is made of an infraumbilical transverse cutaneous-adipose island that has a major versatility due to broad quantity of cutis and subcutis, in this way you can create with autologous tissues the normal mammary ptosis complaint with the contralateral breast. This flap can be made homolaterally to the breast that needs to be reconstructed or contralaterally muscle that allows better rotation and avoids an excessive flap rotation.

If a major vessel component is needed (for example in repairing ulcerated or post radiation areas) it is possible to use bipeduncular flap.

3.7.4.1. ANATOMY

The rectus abdominis is a long muscle made of two muscular fascias that run paramedially along all anterior abdominal wall. It originates on the para-xiphoid cartilaginous portion of rib five, six and seven to insert inferiorly on the iliac crest. In its supraumbilical portion, the rectus abdominis, has some partial tendinous transformations that modify its consistency and interrupt its vascularity.

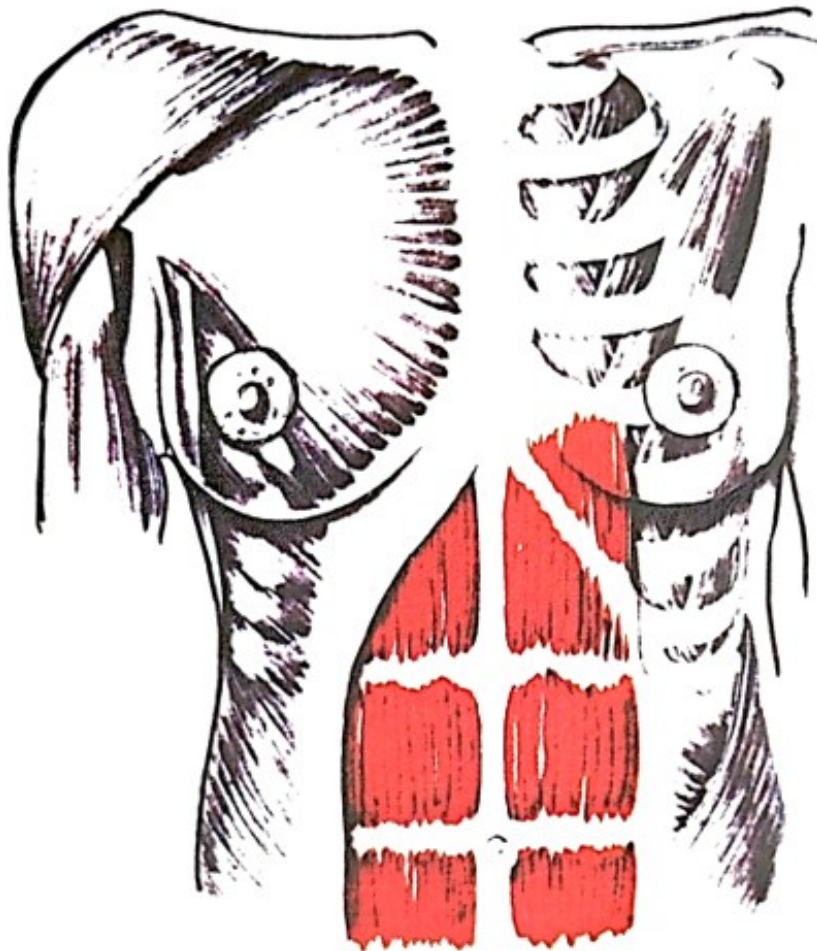


Fig.5 Anatomy of Rectus Abdominis muscle

The muscle is contained in a fibrous sheath that contributes to its contentive function. The rectus sheath it's made up of an anterior leaflet that covers the muscle for its extension derives from the attachment of the aponeurosis of internal oblique; whereas the posterior leaflet it's constructed by the junction with posterior lamina of the internal oblique with the transverse oblique. This structure covers only the upper two thirds of the posterior part of the muscle that, in the proximity of the umbilicus and the pubic area, continues without the tendinous strengthening showing a portion with less strength.

The most important vascular system of the rectus abdominis is made of the epigastric arteries. The superior peduncle, quite thin and susceptible to the individual variations, it's composed of superior epigastric artery which is the terminal branch of internal thoracic artery. The vessel runs deeply in the width of the muscle and inferiorly, at the umbilical level, anastomoses with the terminal branches of inferior epigastric artery, big branch of the external iliac artery, that gives the best contribution to the epigastric-rectus vascular system.

3.7.4.2.PATINET SELECTION

Factors that need to be kept in mind because they predispose to higher risk of complications and may suggest other reconstructive techniques are:

-Advanced age

-Obesity: increased weight over the twenty percent of the supposed one usually associates to hypertension, hypercholesterolemia and diabetes and links to higher incidence of complications to surgery in general.

-Smoking: there is a possibility of alterations in microcirculation that predispose to postoperative ischemia of the flap.

-Scars in the upper quadrants of the abdomen are important because of the possibility of damage to the superior epigastric artery.

-Radio or chemotherapy.

3.7.4.3.TIMING

The cutaneous drawing resembles the one that is outlined for an aesthetic abdominoplasty.

The flap has an elliptic shape and it's placed on the inferior part of the abdomen with the superior margin being over the umbilicus (which is circumscribed by an incision and left in loco) and the inferior portion being in the suprapubic region. This section is ideally divided in four areas according to roman numbers: zone one corresponds to the vector muscle, zone two to the contralateral rectus, zone three to the cutaneous area immediately lateral to the muscular vector and lastly area four for the contralateral zone which is the furthest area form the flap and so being the one with highest unreliable vascularization.

To correctly plan the surgery, we need to address the presence of preexisting scars in the abdominal wall that might compromise the vascular integrity of the TRAM flap or its parts. In case of scars that run vertically and medially, that block the collateral vascularity, we can use only the homolateral areas (one and three) or create a bipeduncular flap, whereas in case of subcostal incisions we can use a flap with the vector being the contralateral area to the scar.

Suprapubic scars, coming from previous pelvic surgeries, interrupt the perforations from the posterior part of the rectus but that doesn't compromise the vascularity and the use of the flap. Every single case must be thoroughly studied, and it's suggested that the integrity of the flap is investigated through instrumental methods.

It is important to take in consideration that:

- The entity of necessary tissue that recreates the mammary protrusion in comparison with the volume of the contralateral breast and eventually the axillar and subclavian deficit.
- Type of mastectomy
- The following scar orientation in the donor area
- If the patient has undergone previous mediastinal radiotherapy that can have significantly reduced the vascular relationship of the superior epigastric arteries.

3.7.4.4.FLAP MAKING

The flap is prepared with the patient lying in the dorsal decubitus position and it's started by following the preoperative drawings incising the cutis and subcutis until the fascial plane and detaching the cutaneous flap from the aponeurosis of the external oblique muscle until the pararectal region bilaterally. Superiorly the detachment is extended till the subcostal area and on the contralateral area the rectus is part of the flap with the disengagement being extended till the linea alba. After extending over the linea alba the perforating vessels are identified and if

those are in sufficient number and integrity the following step it's a double longitudinal incision of the superficial fascia and the deep fascia is left in situ.

Inferiorly the incision is carried transversely just above the arcuate line of Douglas, positioned seven eight centimeters from the pubis, with previously isolation and ligation of inferior epigastric vessels.

In this way the musculocutaneous flap is made of a cutaneous muscular island of substantial extension and volume and it's nourished by the vascular peduncle of superior epigastric artery through a muscular vector that can be fifteen to twenty centimeters long.

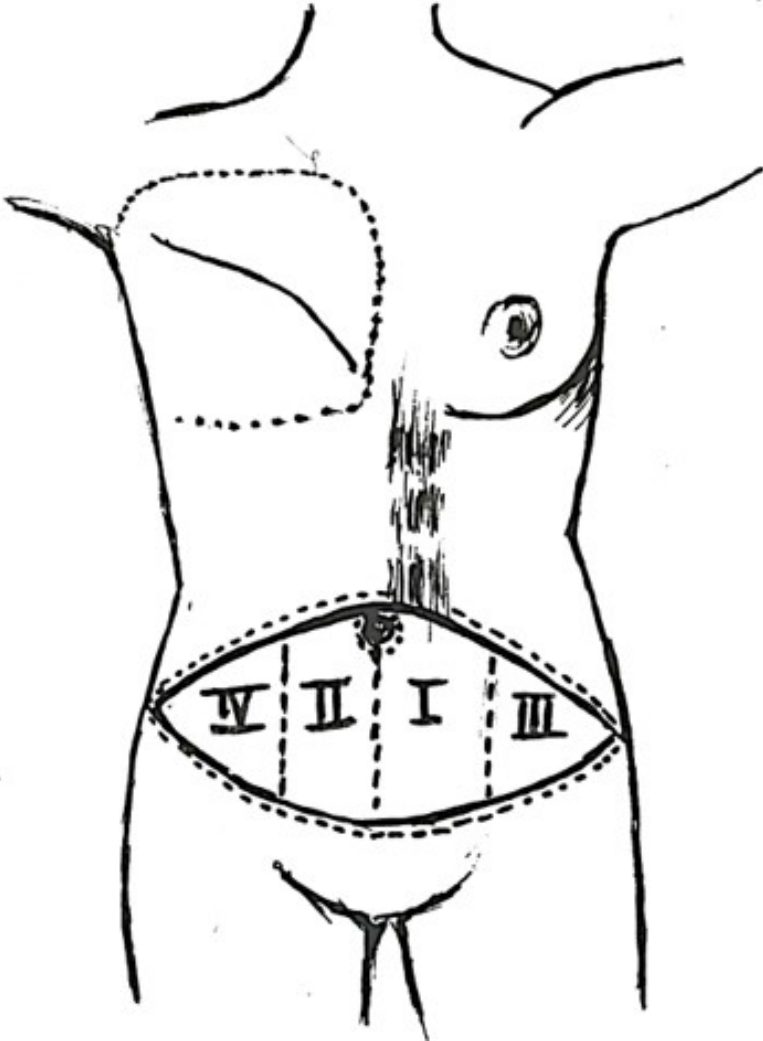


Fig.6 TRAM design

With this method only a small area of superficial fascia between the muscular belly and the cutaneous flap is relocated: the aponeurotic deficit left behind is so reduced that it can be closed through simple nearing and with minimal tension.

This, together with sparing of longitudinal strip of muscle and its inferior section handled over the physiological area of weakness underneath the Douglas line, it is sufficient to avoid weaknesses or hernias of abdominal wall without needing the use of alloplastic materials.

The cutaneous island, isolated from the muscle vector, it's transferred trough a subcutaneous tunnel in thoracic area. The flap is position in a way so that it is possible to obtain the best appearance and mammary profile.

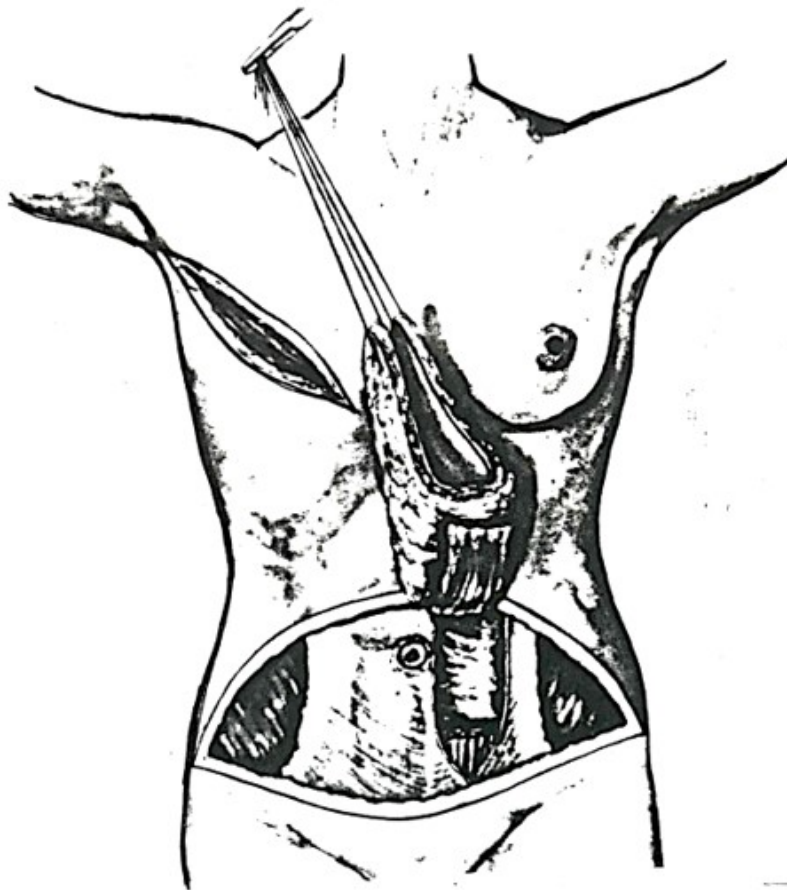


Fig.7 TRAM flap preparation

This part of the operation requires much time and craft for the result and relies on the aesthetic taste of the surgeon and the ability to assess the position and ideal dimensions of the cutis to be left exposed and obtain the best feature and grade of symmetry.

The advantages with the use of this flap are:

-it gives enough autologous tissue so that it is possible to recreate the projection and mammary symmetry without the use, for most of the time, of alloplastic materials.

-with this flap we obtain considerable quantity of cutis and subcutis in many patients, and it is possible to recreate the mammary ptosis which is difficult to obtain with the prothesis alone.

- it helps to transfer more similar cutis, for color and characteristic, to the one of the mammary regions.

-it has the undoubted advantage to gain, at the same time, a better aesthetic appearance in the abdomen similar to the one after an abdominoplasty.

-the extra scar in the donor area it's located in an area easily hidden.

-the patient feels less artificiality of her reconstructed breast, and this helps to make it more acceptable and better satisfactory grade.

The disadvantages of TRAM flap are:

-more aggressive surgery both for the surgeon and the patient.

-it has longer operatory times

-more technical difficulties

-longer postoperative hospitalization

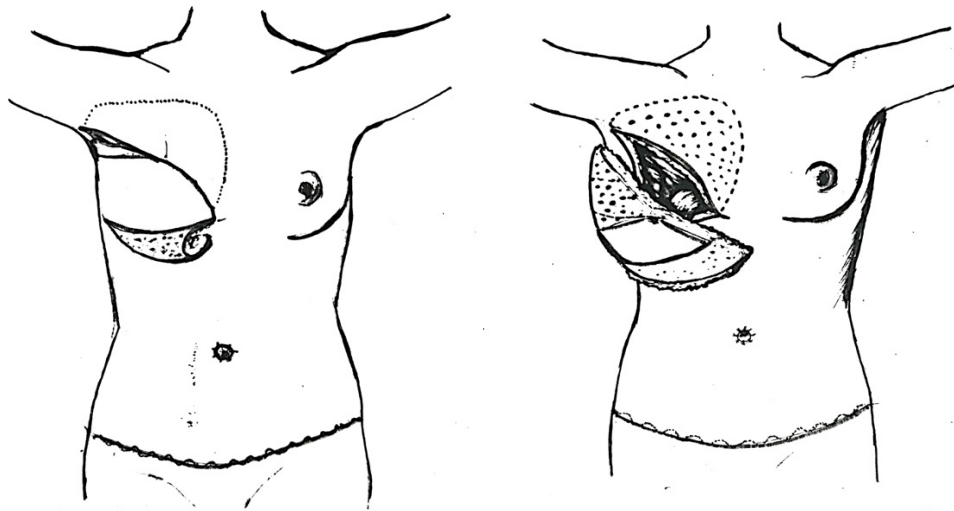


Fig.8 and 9 Adjustment of TRAM flap

3.7.4.5.EARLY COMPLICATIONS

- Partial necrosis of the flap that are generally not so compromising
- Excessive intraoperative bleeding that can be compensated with autologous transfusion previously taken from the patient.
- Thromboembolic events are described in literature, in every case are rare, but can complicate every important surgery and are usually prevented and cured with heparin therapy and early mobilization.
- Hematoma at the flap site, axilla, abdomen, or neck.
- Dehiscence of the wound and healing of secondary intention.
- Lung atelectasis.

3.7.4.6.LATE COMPLICATIONS

Weakness of abdominal wall with formation of laparocoele and hernia, it is a rare complication for those who follow every step of technical procedures, and in obese patients this surgery can improve the contentive capabilities because it creates tension in the structure of the wall itself and corrects the rectal muscle diastasis that can be present in these patients.

Liponecrosis with consequent small fibrotic areas that can be created especially in superior external quadrants.

In conclusion the use of TRAM flap for mammary reconstruction is more extensive for both the surgeon and the patient but it's the flap that in general gives the best grade of satisfaction in time. This procedure should be considered not only if the use of prosthesis or latissimus is not available but as first choice too.

3.7.5. FREE FLAP

The preparation of the flap is similar to the TRAM setup with the pedunculated flap and the use of inferior epigastric artery that has a major reach, and it gives a better vascular contribution. It is also possible to connect the flap with numerous receiving vessels, especially when considering the size of the flap which needs enough of a good circulation and good flow.

-Subclavicular: it is not always necessary to reach the axis to be sure to have a good blood flow, to get attach to high would imply to have a more lateral reconstructed breast

-Thoracodorsal: generally, this is the vessel that is firstly identify and its collaterals are subdivided

-Thoracodorsalis collateral: it's used for the Serratus muscle

-Circumflex scapular: when it is necessary to use the Latissimus Dorsi after the loss of the free flap.

-Thoracoacromial: the thoraco acromial Pectoral branches.

It's important to isolate the flap before cutting the inferior epigastric arteries and check the blood flow through the Doppler ultrasound in the different areas.

The measurements need to be very careful and when it's possible it is advisable to spare the area IV. This technique is, without any doubt, the most demanding both for the surgeon and the patient considering the technique-organizing problematics of microsurgery in general but is surely the one that gives off the best result and the higher grade of satisfaction over time.

-The missteps of this technique are very rare compared with the TRAM with the superior flap in which the farther areas tend to suffer necrosis.

-The reconstructed breast is better in shape, mobility, morbidity, and color.

-Better results over time with minimal changes.

The most negative aspects concern the viability of the flap, especially after the difficulty that the patient is enduring for this extensive surgery which is done in deferred phase.

3.7.6. INFERIOR GLUTEAL FREE FLAP

The increasing evolution of microsurgery techniques and the direction of benefiting, when it's possible, immediate reconstruction with free flaps in breast reconstruction. As matter of fact there is a selective group of patients to which the use of combine microsurgery and free flap represents the best possibility. In these cases, as first choice method, it's preferable to use the rectus abdominis musculocutaneous flap based on the inferior epigastric vascular flap. When those tissues are not available it is possible to use the gluteal region and considering this option, we two possibilities:

1-Superior gluteal musculocutaneous free flap

2-Inferior gluteal musculocutaneous free flap

The second alternative it is mostly preferred because it has undoubted advantages both in the technical level and aesthetic results in the donor site and in the restored breast.

3.7.6.1. ANATOMY

The feminine gluteal region has an abundancy in the soft tissue and in the adipose tissue generally well represented.

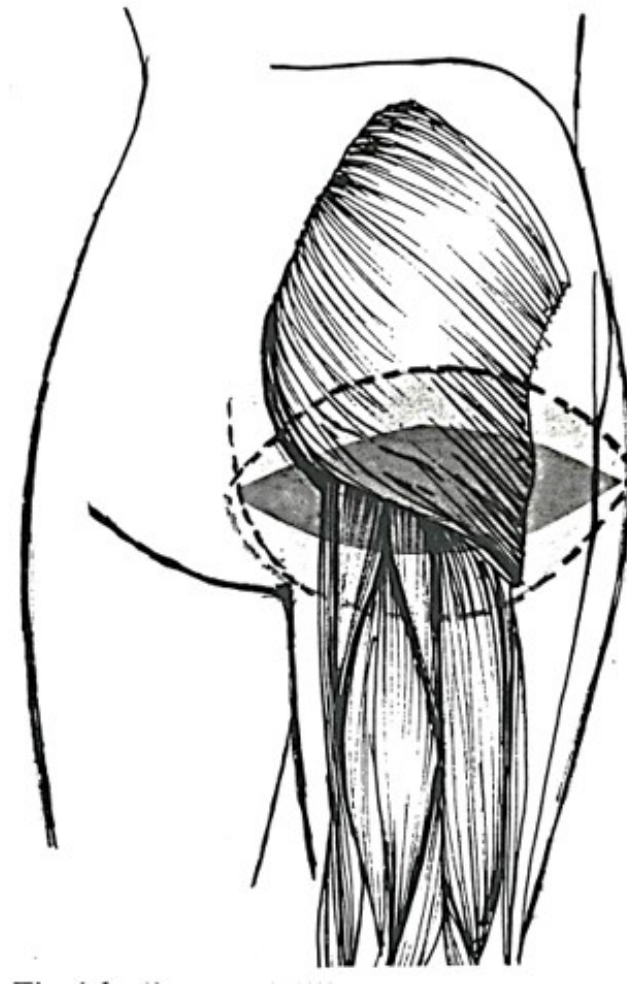


Fig.10 Inferior gluteal flap design

The vascular contribution in this region is mainly supplied by the muscular perforating arteries originating from superior and inferior gluteal artery. These are both collateral branches of internal iliac artery.

Superior gluteal artery → it is the most voluminous of the branches of the internal iliac artery; it crosses through the superior part of the great ischiatic foramen, above the piriformis muscle, then it gets out the pelvis, together with two satellite veins and the superior gluteal nerve; enters in the gluteal region and it divides in two terminal branches.

1-superficial branch that distributes to the gluteal maximus.

2-deep branch that supplies the gluteus medius and minimus.

Inferior gluteal artery → it descends in the pelvis in front of the sacral plexus and piriformis muscle; it goes through the great ischiatic foramen, it exits the pelvis and descends between the great trochanter and ischial tuberosity, together with the ischiatic nerve and posterior cutaneous femoral nerve giving then off its terminal branches that anastomose with the perforating arteries. It supplies the gluteus maximus, quadratus femoris, great adductor, the cutis and the muscles in the coccygeal area.

The anatomy of the superior and inferior gluteal vessels tends to be constant so that both flaps can offer good outcome for the microsurgery techniques.

3.7.6.2. OPERATIVE TECHNIQUE

The preparation of the inferior gluteal musculocutaneous flap starts with a transverse incision just under the inferior gluteal fold. We then proceed with the dissection of the subcutaneous tissue and identification of posterior cutaneous femoral nerve and inferior gluteal artery in the spot in which they exit the gluteus maximus just laterally to the ischiatic great tuberosity; this place is anatomically important because the nerve and the artery are located closer and more superficially with respect of the sciatic nerve. The dissection moves on with the ligation of the anastomose branches of the arteries and freeing a strap of gluteus maximum of 5x8 centimeters adjacent to the inferior gluteal artery peduncle so that it is guaranteed, through the muscular perforating arteries, a sufficient flow to the cutaneous and subcutaneous tissues. The dissection is carried on proximally to increase the length of the peduncle and making an easier microvascular transfer; when proceeding with this maneuver we meet two or three branches of the inferior gluteal nerve that need to be preserved to maintain the innervation to the remaining gluteus maximus. Furthermore, the ischiatic nerve also needs to be handled and carefully divided by the surrounding tissues and generally there are not issues from segmented ischemia of the nerve because the length of the exposure is limited; usually a strap of the bicep femoris is mobilized and placed to cover the nerve.

Once completely isolated the flap is transferred in the thoracic region and it is anastomosed with the internal mammary vessel like described for the superior gluteal artery.

To obtain access to the internal mammary vessel four or five cartilaginous processes of ribs are removed. Often the internal mammary artery is slim, inconsistent, and inadequate so it is necessary to use the cephalic or external jugular artery for the microvascular anastomosis. If

the inferior gluteal peduncle it is not sufficiently long for an adequate positioning of the flap it is possible to involve vascular grafts for both internal mammary vessels and axillar vessels. This simplifies considerably the surgery so every time the length of the peduncle is sufficient for the anastomosis with the axillar vessels it becomes not imperative to carry out the cut of the cartilaginous process of the ribs avoiding an extra invasive portion of the surgery.

3.7.6.3. INDICATIONS

When the local situation is so that is not enough to use a prothesis or cutaneous expansion, when we have previous scars or insults to the vascular peduncle so that is not possible to involve the latissimus dorsi or rectus abdominis.

It is still very important for the surgeon to evaluate the patient to find the best technique and balance that with the desires and preferences of the patients.

The advantages of the use of this flap are manifested by a vascular peduncle which is longer and of a bigger diameter that allows an easier anastomosis with the axillar vessels.

The scar in the donor site, which lies in correspondence with the gluteal fold, it is less anaesthetic compared with the one of the superior gluteal flaps that runs in the same region but in a higher position.

There is a superior concentration of adipose tissue in the inferior gluteal fold, specially in lean patients, which allows us to use an adequate quantity of autologous tissue to achieve a good projection and breast symmetry.

3.7.6.4. DISADVANTAGES AND COMPLICATIONS

The technique is quite recent not well codified in respect with possible deficit in the donor area. One of the crucial step is to maintain the innervation of the remaining portion of the gluteus maximus; considering that it is entirely innervated by the inferior gluteal nerve (L5, S1, S2) that escort the way with the inferior gluteal artery it is not possible to isolate an inferior segment of gluteal muscle without damaging the inferior gluteal nerve. With these considerations it is still possible, during the dissection, to preserve small residual branches that will retain the function of the residual parts of the muscle.

The paralysis of the muscle in its entire function will not lead to static deficiency rather in the loss of the functional capability leading to unsatisfactory extension and extra rotation of the

thigh; this impairment will be visible when getting up the stairs, standing from a sitting position or when running.

3.8. EXPANDERS AND PROTHESIS IN BREAST RECONSTRUCTION

The use of these aids in reconstructive breast techniques started around 70 years ago with the Cronin prosthesis and since then numerous ways of reconstruction have been described to redress the complications of the use of autologous material. We can describe four types of approaches:

- 1-Prefilled prosthesis
- 2-Inflatable prosthesis
- 3-Double chamber prosthesis
- 4-Baker's expanders/prosthesis

3.8.1. PREFILLED PROTHESIS

This are the first that have been used. They are made of a shell of smooth silicone rubber, soft, slim and at the same time resilient to trauma; inside we have a silicone gel of which its physical and chemical properties such as the viscosity and specific weight that make it very similar to the mammary gland.

3.8.2. INFLATABLE PROTHESIS

This are also made of a slim membrane of silicone which, once in loco, will be progressively filled with a sterile physiologic solution through a valve which is positioned in the subcutis.

This type of prosthesis shows, compared with other types, some disadvantages, and advantages such as:

- less use of alloplastic material
- realization through a small cavity of entrance
- it resolves the issue of periprosthesis spread of silicone gel in case of complications with prosthesis transudate considering that spread of physiologic solution doesn't represent a hazard
- it is possible to play with the filling, to get a better consistency and breast volume more like the natural one

-the physiologic solution can also be medicated with some steroidal drugs which inhibit the fibroblast proliferation and collagen synthesis decreasing the possibility of formation of retractive periprosthesis capsule.

3.8.2.1. DISADVANTAGES

The valve is the main issue with this type of prosthesis because it does not have perfect watertight valve; the stability of the result over time will depend on the quality of the valve. The loss of fluid through the valve is a quite common complication that determines a reduction of volume and a shift of the implant. It is also very important to consider that the physiologic solution will give to the implant a “balloon” consistency that will result unnatural in many cases.

3.8.3. DOUBLE CHAMBER PROTHESIS

These represents a compromise in between the previous two types and are studied to avoid the shortcomings of both: they are made of a nucleus of silicone gel covered by a double membrane, internal and external, which are also made of silicone, and limit an area which is filled with physiologic solution. In this way we have, on one side, a decrease possibility of rupture and subsequent silicone transudate and, on the other side, all the advantages of the inflatable prosthesis.

But even with this combined method the issue of deflation and volume reduction is not yet resolved.

3.8.4. BEKER'S EXPANDERS AND PROTHESIS

This apparatus synthesizes the use of a normal expander together with the ones of permanent prosthesis.

It is made of two membranes, totally independent from one another, that create two compartments, an outer one made of silicone and an inner one inflatable with physiologic solution through a channel and a double valve located on each membrane. The prosthesis is introduced deflated, generally in a submuscular pocket, and then through a flexible tube connected to the double valvular system the physiologic solution is introduced. After fifteen to eighteen days, it is possible to start the expansion by injecting fifty cubic centimeters of solution each time.

3.8.4.1. ADVANTAGES

- Possibility to modify the volume and achieve the desired proportion
- Thanks to the possibility of distension of the skin over time the outcome is more natural and ptotic which is not the case with the conventional prosthesis.
- It acquires a one-time surgery thanks to postoperative adjustments with the only use of a definitive prosthesis instead of skin expanders before and prosthesis after.
- In case of presence of an early fibrous capsule formation permits an overinflation to distend it and avoids an internal capsulotomy and subsequent bleeding.

3.8.4.2. DISADVANTAGES

- High cost
- Same limits of an expansion technique
- Baker's prosthesis was created with the aim of breast reconstruction in a one time only surgery but unfortunately this is possible in very rare cases because often many adjustments are necessary to correct asymmetries of the mammary fold or prosthesis position in general.

To these before mentioned prosthesis many changes have been made to ameliorate certain features and decrease the defects such as, first, and most importantly, the pericapsular fibrosis that can induce retractions and breast induration (18–24).

Cronin prosthesis:

These are prefilled apparatus in which the application of patches made of dacron on the posterior side, eventually on the anterior side as well, permits the invasion and settlement of connective tissue which will result in stabilization of the implant. This type of implant was then forsaken because it was quite big, massive and would result in hard and solid breast with capsular retraction events due to the excess use of dacron.

Ashley prosthesis:

These are made of silicon covered by a polyurethane foam (25). This outer material has noticeably reduced the percentages of per prosthesis capsular contraction (26). The negative side of these implants are for example the difficulty in complete removal of the prosthesis in case of substitution or potential biodegradation in toxic agents.

Low bleed prosthesis:

These have low possibility of oozing due to being made of an exterior membrane of triple layer of alternating silicone and cohesive silicone.

Microtextured prosthesis:

They maintain the advantages of the polyurethane but avoid the toxic biodegradation possibility meaning that the outer part is made of thirty-micron pores allowing the penetration of fibroblasts and quiescent histocytes that induce an optimal growth of collagen fibers. After some time, we will have the formation of a loose net that will bestow a better adherence and limited reactive connective component with the result being a thinner capsule (27–32).

3.8.4.3. COMPLICATIONS

The secondary obstacles encountered in the use of prosthesis are different for frequency and variability and can be classified according to timing of their appearance:

Immediate:

- perforation or laceration of the apparatus

Precocious postoperative complications:

- serous effusion

- hematoma

- infection

- prosthesis expulsion

Late postoperative complications:

- malposition

- soft and visible borders

- cold breasts

- decreased sensibility

- thoracic pain

- diminished breast volume

- capsular retraction

Some of these drawbacks, like serous effusions, hematomas or infections, are present for every other surgical intervention; of course, in reconstructive cases the risks are higher when considering the introduction of an external object, with big dimensions, plus the continuous solicitation by the nearby muscles. It is possible to reduce complications in frequency and

duration by adopting sterile suction drains and avoidance of excessive precocious mobilization of the operating area.

3.9. CAPSULE AND CAPSULAR RETRACTION

The introduction of an external apparatus, which is in this case the prosthesis, will result in the formation of a capsule, a sac, in its proximity and around its border as a physiologic reaction of the organism rather than a complication. The inflammatory reaction, which becomes visible even after few days, is made of inflammatory cells and collagen fibers and over time it becomes more an irritative event with chronic characteristics; it will get colder, less cellular rich and with marked collagen abundance rich in polysaccharides and proteins which will bestow moderate hardness. Clinically this capsule is not palpable, and it doesn't change the operated breast consistency.

On the other side of this physiologic reaction, it is possible to develop, in a variable window of post-surgery time, microscopic modifications with abnormal fibroblast, called myofibroblasts, containing actin and myosin filaments plus defective collagen which will result in a smaller contracted capsule visible clinically in an indurated painful breast. The capsular retraction represents the most important problem in mammary prosthesis of any type: we have border accentuation, which becomes very evident, unnatural breast consistency and worst case scenario formation of abnormal folds.

The etiology of capsular retraction is unknown but may be linked or accentuated by:

- postoperative hematoma
- bacterial contamination
- overproduction of lactic acid by pectoral muscle
- transudation of silicone through the prosthesis membrane

Classification of the contraction severity and entity was proposed by Beker:

Stage 1:

Normal inspection

Normal palpation: the operated breast has the same consistency as the natural breast.

Stage 2:

Normal inspection

Abnormal palpation: the operated breast is less soft compared with the natural breast.

Palpable prosthesis but not visible

Stage 3:

Normal inspection

Abnormal palpation: hard operated breast

Visible and palpable implant

Stage 4:

Marble breast—>hard, cold, painful, and deformed

The various new implants, together with modifications and technic-operative precautions, contributed to a reduction of capsular retraction by forty percent nevertheless in case of consistent retraction (stage three or four according to Beker's classification) has to undergo therapeutic treatment such as capsulectomy with implant change or external capsulectomy. Some factors that can avoid or decrease the chance of developing these complications can be local use of steroids, submuscular positioning of the prosthesis or the use of specific materials such as polyurethane.

3.10. IDEAL TIMING OF IMPLANT INTRODUCTION

Immediate insertion:

The single surgery with immediate breast reconstruction and prosthesis introduction is of course the most liked option for the patient but it's not always possible or unproblematic:

-the hemostasis is not always optimal

-in case of mastectomy the pocket that is created by the mammary glandular removal may be too big for the implant

-there may be problems with excessive tension in the suture lines or in the transported flaps that may compromise their viability

-it's not possible to have the histologic confirmation and the staging of the tumor

Implant insertion after few days:

This second intervention can be done using a portion of the present scar, nevertheless sometimes when the submuscular insertion it's chosen an extra incision may be necessary. When postponing the surgery of a week it is possible to avoid some problematics related to the immediate reconstruction such as a more precise histologic analysis and a better staging that will indicate the patient needed radicality.

Late prosthesis insertion after three months or more:

The patient's desire or incertitude may contribute to the postponing but at the same time it can also be due to waiting time for resolution of infections, cutaneous necrosis and dehiscence. When the disease is advanced and the chemo and radiotherapy are necessary than the delay of the second operation becomes mandatory for the better patient outcome.

One issue that is encountered with the postponed technique is that the healing process is linked to the formation of a subcutaneous scar tissue and the pocket created by the dissection can't be used for the implant as well so a more profound tissue detachment becomes decisive.

3.11. CUTANEOUS EXPANDERS IN MAMMARY RECONSTRUCTION

The expanders ameliorated the aesthetic results in breast reconstruction with implants and has opened the possibility to the use of this approach in which local situation was not so favorable such as in very demolitive mastectomies that at least impose tissue distention before the insertion of the implants.

We have two types of expanders, both valid, that can be chosen according to each individuals need:

- temporary expander of Radovan
- permanent expander/prosthesis of Beker

Cutaneous expansion to ameliorate definitive results is best engaged when we have enough of cutaneous and muscular tissue to welcome the implants. When the cutaneous portion is not enough the expanders found use as an alternative to dermo epithelial flap; whereas on the other hand in case of muscular and cutaneous defects the muscular portion needs to be adjusted first and the skin can be stretched then by the expanders.

The expander has a double advantage:

- on one side it helps the skin extend the cutis from the thoracic wall without having to reduce the contralateral breast.
- on the other side it creates an easy homing for the definitive implant in a subcutaneous pocket bigger than normally so that we have a decreased risk of capsular contraction and obtaining a better ptosis result.

The disadvantages are:

- The conditions that contraindicated their use are all of those that directly or indirectly diminish the cutaneous trophism.

- The methodology requires long time to completed, indeed, the ambulatory injections that are necessary are for six to eight weeks and must be thirty percent of overdistention more than the desired volume. This aspect needs to be considered when choosing the appropriate technique for the case and keeping in mind the common emotional liability of the mastectomized patient.

- Generally, two surgeries are required: one for the introduction of the expander and the other for its removal and the other for substitution, after two months, with definitive prosthesis.

To conclude, the approach of breast reconstruction with the use of prosthesis, with or without skin expansion, can recreate a symmetric and harmonious breast morphology with the advantage of being an easy methodology and applicable in a hospital environment which is either not fully equipped with technologic media necessary for microsurgery or with the specialist that have enough of experience and capability for a TRAM reconstruction.

One of the ongoing trends about prosthesis complications is the implant fear, in particular in January 2016 the United States FDA approved an updated safety communication that identified a possible association between breast implants and the development of anaplastic large cell lymphoma, which is a rare type of non-Hodgkin's lymphoma. It was seen that this rare but very undifferentiated type of lymphoma seems to mostly develop around implants with textured surfaces; according to World Health organization this is not a type of breast cancer but a tumor of the immune system. It is estimated that the hazard of developing such cancer it is predicted to be 1:2207 to 1:86029 but in cases of women with textured prosthesis.

The clinical presentation of patient with BIA-ALCL will be breast swelling, asymmetry, overlying rash, pain and bulging in the axilla or breast; the average time of presentation is eight to ten years after implant insertion. It is important to keep in mind that the cancer develops in both silicone and saline implants and both breast reconstructed and cosmetic patients.

Step treatment in case of BIA-ALCL development include:

- it will provably be necessary to undergo PET/CT scan so that it will be possible to visualize any distant spreading in the body and so it is important for staging the disease as well.

- after the report it important to be referred to an oncologist that will guide the patient to all the following step and create a treating plan.

- surgery may be then required to remove the implant and the pocket in which it was deposited.

- some of these patients will require chemotherapy and radiotherapy.

In the end it is important to mention that today there are not any confirmed BIA-ALCL cancer developed from a smooth implant and it's also not possible to test and identify who is at risk for the disease (33–39).

3.12. NIPPLE AREOLA COMPLEX RECONSTRUCTION

The reconstruction of this complex is another main component of breast reconstruction, and it is part of its completion. The finality of this intervention is in part to simulate and in the other part recreate, at its best, the organ in all of its appearance in both the artistic and aesthetic parts. The new breast, even if perfectly reconstructed, will never look natural without the normal darker areola and nipple protrusion.

In order to obtain a good aesthetic result, it is fundamental to search for the possible perfect symmetry in location, color dimension and projection; that's why the nipple-areolar complex surgery it's usually postponed of some months in respect to the primary reconstructing surgery, it is important to permit a better consolidation of tissues and with this the possible variation in the contour and morphology of the new breast. Sometimes, to obtain a good grade of symmetry between the two breasts, it may be necessary to correct the volume and profile of the contralateral breast; in this case then the reconstruction of the areolar-nipple complex can be made in concomitance with that of the surgery or contralateral breast adjustment.

When these surgeries are not necessary, and when the chosen technique permits it, the reconstruction can be carried out in local anesthesia and in ambulatory office so that it is possible to avoid extra hospitalization.

3.12.1. AREOLAR RECONSTRUCTION

Some donor sites that can be used are:

- contralateral areola
- cutis from the thigh
- retro auricular region
- labia majora
- superior eyelid
- vulvar mucosa

Another possibility which becomes more and more common today is the possibility to tattoo the area.

When choosing the donor site, it is important to acknowledge that the color of the donor site compared with the contralateral areola plus the following aesthetic and functional damages given by the donation. Considering the color, the graft taken from the thigh, once takes root and heals will become light brown; the labia majora are more pigmented; retro auricular portion will give the cutis a more pallid pink component and so it is indicated only when the contralateral breast has a very light-colored areola.

The choice has to evaluate the damages that will result from the graft on the donor site as well; of course, it would be preferable to adopt those methods that will bring less evident scars or in more hidden sites such as the medial side of the thigh. The best donor areas remain the medial aspect of the thigh and the contralateral areola. Site and dimensions will be determined preoperatively, particular attention is mandatory when measuring for a good symmetric nipple.

3.12.2. RECONSTRUCTION WITH CONTRALATERAL AREOLA

This technique is to be preferred when it's necessary to intervene in contralateral breast and both can be carried out in the same operative session. The fundamental requisite is that the areola has dimensions that will permit the withdrawal of a portion of it being at least of four centimeters of diameter; considering that the normal length of an areola is around ten millimeters, the donor site shouldn't be less than fifty-six millimeters so that both the donor and recipient areola will have a final length of thirty-six millimeters.

It is desirable to withdrawal of a small concentric circle external of the areola and eventually thinner it to obtain a better tissue rooting and color preservation and, in the end, place this graft in the recipient area that must be de-epithelized previously.

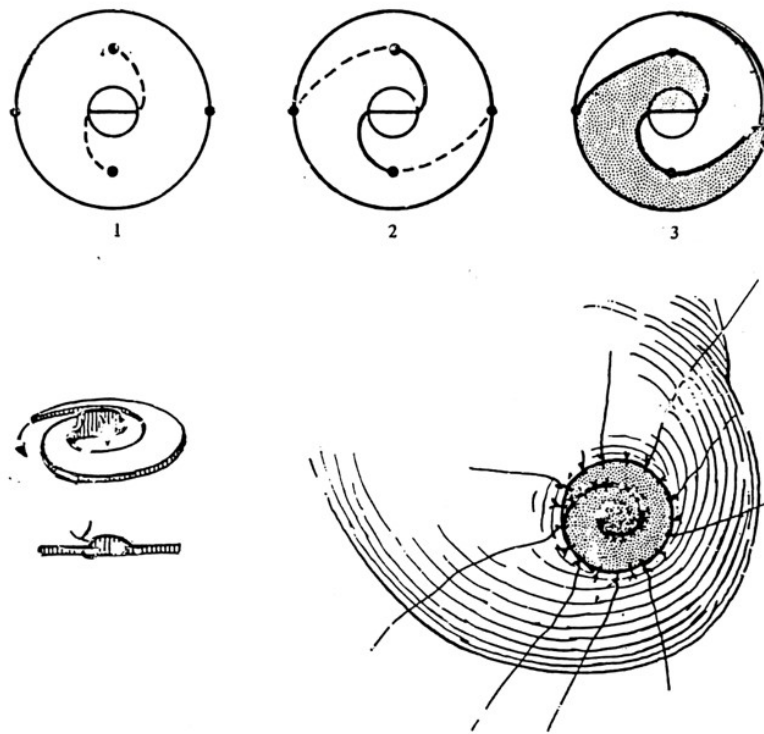


Fig.11 Nipple reconstruction by spiral method

3.12.3. INNER THIGH AREOLA RECONSTRUCTION

The cutis of the upper medial thigh will give tissue, for color and structure that is very similar to the areola. The precise location is chosen by the intensity of pigmentation, trying to allocate the future scar in correspondence with the inguinal fold, so that it will be covered by underwear or bathing-suit. It is important to take an elliptical area of which the smallest diameter it's at least same as the one necessary for reconstruction. Surfaces of thirty to forty millimeters of diameter can be closed by direct approximation. On the other site the graft needs to be deprived from hair bulb before being grafted in the recipient donor area.

3.12.4. GRAFTING

The nipple and areola complex can be taken by the removed breast during mastectomy and from that it's possible to obtain some fragments to send to pathology for analysis; furthermore, for tissue survival while waiting for the pathologic response cryopreservation is preferable.

3.12.5. TATTOO RECONSTRUCTION

It is a methodology that consist of introduction of pigment, which is opportunely chosen, in dermis of the area that needs to be reconstructed. It has the advantage of being quite simple and, in expert hands, can give back optimal results. Nowadays experts are able to recreate the most perfect match color and when we think about the ability to cover up stretch marks then we can agree that when in presence of the tattoo artists with the right skills and experience than graft tissue becomes not necessary.

3.13. NIPPLE RECONSTRUCTION

For nipple reconstruction it is possible to use a composite graft; the locations for graft withdrawal are multiple but most commonly inquire the nipple of the contralateral breast and the auricle.

3.13.1. CONTRALATERAL NIPPLE RECONSTRUCTION

It is a methodology that when possible, thanks to the conditions, will leave no scars and optimal results. Certainly, the nipple has to have sufficient dimension and projection to permit tissue sampling. This can be carried out by transverse decapitation of the distal three-fifths in cases of which the projection is bigger than the diameter (projection which is major than eleven millimeters); or in cases which the diameter is bigger than the projection than the longitudinal incision is carried out.

In the other hand if the nipple is of small dimensions or if the patients doesn't want to have surgery in the other breast, another location must be considered.

3.13.2. AURICULAR LOBE RECONSTRUCTION

A delicate graft is created and quickly transferred by paying attention to minimize trauma; this methodology creates a natural projection and scar which are not so visible in the donor area. Some of small cartilaginous fragments can be dispersed under the graft to reconstruct the areola and give off a more natural outcome.

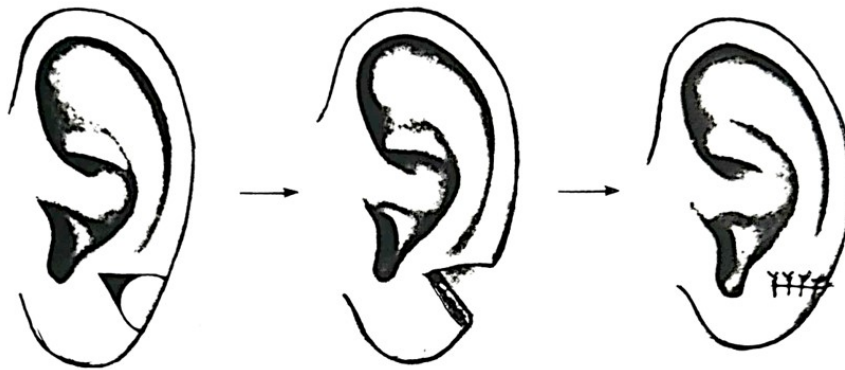


Fig.12 Nipple reconstruction with auricular graft

4. DISCUSSION

Initially, breast cancer therapy was based on demolitive techniques for the anterior thoracic wall and axillar region. Now, techniques aim to minimize defacement while considering aesthetic outcomes. Numerous studies show no significant difference in outcome and survival between more demolitive and conservative surgeries.

A neoplasia that infiltrates lymph nodes requires removal of the breast, axillar lymph nodes, intermedial lymph vessels, and possibly muscles. This surgery, which requires mammary gland, cutis, pectoralis major and minor, and axillar tissue removal, can deface a woman's body and make reconstructive surgery difficult.

Less radical and more reconstruction-friendly methods exist, such as Patey's radical modified mastectomy. This technique only removes the pectoralis major fascia, leaving the muscle intact, and offers better aesthetic results. Breast surgery must be personalized, considering the stage of neoplasia, patient lifestyle, and psychic equilibrium.

Reconstructive surgery is a right for every woman undergoing breast cancer surgery. Patients should be informed about possible reconstruction outcomes, which can contribute to complete patient recovery. The possibility of relapse should not exclude patients from reconstruction.

Immediate reconstruction is possible for small tumors, with less extensive demolitive surgery, shorter duration, and simpler reconstructive processes. However, it has disadvantages, such as difficulty organizing two surgical teams, increased surgery complexity and duration, and possible complications like local necrosis, infections, and hematomas.

Patient, oncologic surgeon, plastic surgeon, and patient agreement is necessary for successful breast reconstruction. A series of aims should be outlined, including retrieval of scarified tissues, breast projection and shape restoration, axillary pillar reconstruction, subclavian deficit compensation, areolar-nipple complex reconstruction, and breast symmetry.

Various techniques can be used, including those using existing tissues, flaps and cutaneous-subcutaneous tissues, and distant flaps with myocutaneous tissues. The choice of technique depends on the local situation after mastectomy, not the type of mastectomy. The techniques that were analyzed in this review were:

The thoracoepigastric flap is a cutaneous flap from the lateral abdominal wall, used when more than a prothesis is required but a muscular flap is unnecessary. It is composed of cutaneous and subcutaneous tissue in a transversal direction and has its own vascular supply. This flap can be used without risks and offers advantages like easy rotation, coverage of big cutaneous deficits,

primary intention closure of the donor site, and a residual scar in the bra curve. However, it requires an additional scar in the donor site and cannot cover upper and lateral deficits or the thoracic wall. This technique is used for smaller breasts and is easier than other methods. The flap mobilization starts at the lateral margin and extends to the abdominal rectus fascia. The medial fascia is sectioned, and the sternal and costal insertions are mobilized. The cutis under the mastectomy scar is de-epithelized, and the medial portion is cut and doubled for breast profile augmentation. The use of autologous tissue in this technique is an advantage, as it can be more satisfying for the patient. Great results can be achieved using myocutaneous flaps from the latissimus dorsi, thanks to their stability and easy execution.

The use of the latissimus dorsi allows for the correction of subclavicular depression and the possibility to substitute the pectoralis major and create an adequate pocket for a prosthesis. The cutaneous portion is nourished by perforating vessels, allowing for double wear and better results. Planning is crucial, involving an assessment of nerve and vessel integrity after mastectomy. The flap is drawn with the patient sitting, considering the rotation point, post-mastectomy scar, and cutaneous deficit entity. The myocutaneous flap is isolated and transposed through a tunnel to the deficit area. Advantages of the latissimus dorsi include reconstruction in one sitting, relatively easy setup and execution, almost nonexistent deficit on the donor site, a postoperative scar easily hidden by clothing, a broad, movable, and well-adaptable flap, and the reconstitution of the deficient muscle component on the anterior thoracic wall. Disadvantages include the usual use of a prosthesis and its eventual complications, a "patch" effect due to different dorsal skin color, possible infection and partial dehiscence of the suture, and superimposable complications with other reconstructive surgeries. The limit in the use of latissimus dorsi is usually nerve section and ligature of the peduncle during mastectomy, which can create doubts about the quality and vascularity of the flap. In these cases, the contralateral latissimus dorsi or other reconstructive possibilities can be used.

The lateral musculocutaneous flap of rectus abdominis is an alternative for the latissimus dorsi when the local situation doesn't permit its use or when a major quantity of tissue is required. It is made of an infraumbilical transverse cutaneous-adipose island and can be made homolaterally or contralaterally to the breast that needs to be reconstructed. The rectus sheath is made up of an anterior leaflet covering the muscle and a posterior leaflet constructed by the junction of the internal oblique with the transverse oblique. The superior peduncle is composed of the superior epigastric artery, a terminal branch of the internal thoracic artery. The flap has an elliptic shape and is placed on the inferior part of the abdomen. It is ideally divided into four

areas, with zone one corresponding to the vector muscle, zone two to the contralateral rectus, zone three to the cutaneous area immediately lateral to the muscular vector, and zone four for the contralateral zone. To correctly plan the surgery, the presence of preexisting scars in the abdominal wall must be addressed, as they might compromise the vascular integrity of the TRAM flap or its parts. The flap is prepared with the patient lying in the dorsal decubitus position and is started by incising the cutis and subcutis until the fascial plane.

The musculocutaneous flap is made of a cutaneous muscular island of substantial extension and volume and is nourished by the vascular peduncle of the superior epigastric artery through a muscular vector. The aponeurotic deficit left behind is reduced, allowing for minimal tension closure. This technique gives enough autologous tissue for projection and symmetry without the use of alloplastic materials, recreates mammary ptosis, and hides the extra scar in an easily concealable area. However, it requires a more aggressive surgery for both the surgeon and the patient.

The use of TRAM flap for mammary reconstruction is extensive but gives the best grade of satisfaction in time. The preparation of the flap is similar to the TRAM setup with the pedunculated flap and the use of inferior epigastric artery, giving a better vascular contribution. The rectus abdominis musculocutaneous flap based on the inferior epigastric vascular flap is the best possibility for combine microsurgery and free flap use in a selective group of patients. When those tissues are not available, the gluteal region can be used, with the superior or inferior gluteal musculocutaneous free flap as possibilities.

The inferior gluteal flap is mostly preferred due to its undoubted advantages in technical level and aesthetic results in the donor site and in the restored breast. The vascular contribution in this region is mainly supplied by the muscular perforating arteries originating from the superior and inferior gluteal artery. The preparation of the inferior gluteal musculocutaneous flap starts with a transverse incision just under the inferior gluteal fold. The dissection moves on with the ligation of the anastomose branches of the arteries and freeing a strap of gluteus maximum adjacent to the inferior gluteal artery peduncle. Once completely isolated, the flap is transferred in the thoracic region and is anastomosed with the internal mammary vessel. If the inferior gluteal peduncle is not sufficiently long for an adequate positioning of the flap, vascular grafts can be involved for both internal mammary vessels and axillar vessels.

When the local situation is so that it is not enough to use a prosthesis or cutaneous expansion, when there are previous scars or insults to the vascular peduncle so that it is not possible to

involve the latissimus dorsi or rectus abdominis, the surgeon must evaluate the patient to find the best technique and balance that with the desires and preferences of the patients.

5. CONCLUSIONS

The breast reconstruction after cancer removal, it is a vast chapter in plastic surgery that in the last years has assumed a considerable importance. The development of operating techniques, the better results and the less sacrifices from the patient site that must undergo minor surgeries, contributed to a better acceptance from the patient point of view as well for reconstruction per se. All of this is facilitated if in the medical equip a psychologist support is present as well.

The general and plastic surgeon have the task to heal the cancer by amputating a very particular organ and giving back volume and shape to an area that is mostly characterized by harmony and symmetry plus specific features such as mammary fold and nipple and areola complex.

The precocity in the diagnostic procedure in breast cancer, the radicality of the surgery and the possible reconstructive outcomes were the aim of this review.

After underlying the importance of psychologic and social aspect of the topic, the various techniques were described, and the following conclusions were abducted: generally talking simpler techniques are there to be preferred to the more complicated and radical ones such as a fascia-cutaneous or musculo-cutaneous rotational flap.

Anyway, good results can be obtained even with the use of implants and eventually with skin expanders to ameliorate the results.

The most prepared equipes use various types of microsurgery approaches (TRAM flap, gluteal flap) but surely this are not carried out so much anymore because of their radicality and postoperative difficulties.

Maybe over time with multi-specialist team and operating center it will be possible to carry out more complete and wide breast reconstructions and it would be possible to have better postoperative follow up and results evaluation.

6. SUMMARY

Breast reconstruction after mastectomy is a significant aspect of reconstructive surgery, which has developed rapidly in recent decades. The goal goes beyond mere aesthetics, significantly improving the patient's quality of life. Initially, breast cancer therapy was based on demolitive techniques that altered the morphology and physiology of the anterior thoracic wall and axillary region. However, current techniques aim to minimize defacement while considering the patient's desire for good aesthetic outcomes. Breast surgery must be highly personalized, considering the stage of the neoplasia, the patient's preferences, and the oncological principles. The surgeon can choose from various techniques to achieve the best aesthetic and psychological outcomes for the patient. Breast cancer is considered a chronic disease, and reconstruction can be allowed during remission periods, even in cases of systematic diffusion. Various techniques can be used, including those that use existing tissues with simple volume integration, reconstruction through flaps and cutaneous-subcutaneous tissues, and the usage of distant flaps involving myocutaneous tissues. The choice of technique depends on the local situation left by the mastectomy, not the type of mastectomy performed. The agreement between the patient, the oncologic surgeon, and the plastic surgeon is crucial for successful breast reconstruction. The patient should be informed about what can and cannot be achieved with current techniques. Many women will settle for partial results, while others will never be fully satisfied.

7. LITERATURE

1. Jonczyk MM, Jean J, Graham R, Chatterjee A. Surgical trends in breast cancer: a rise in novel operative treatment options over a 12 year analysis. *Breast Cancer Res Treat.* 2019;173(2):267-274. doi:10.1007/s10549-018-5018-1
2. Ilonzo N, Tsang A, Tsantes S, Estabrook A, Thu Ma AM. Breast reconstruction after mastectomy: A ten-year analysis of trends and immediate postoperative outcomes. *Breast.* 2017;32:7-12. doi:10.1016/j.breast.2016.11.023
3. Chen K, Pan Z, Zhu L, et al. Comparison of breast-conserving surgery and mastectomy in early breast cancer using observational data revisited: a propensity score-matched analysis. *Sci China Life Sci.* 2018;61(12):1528-1536. doi:10.1007/s11427-018-9396-x
4. Thiessen FEF, Tjalma WAA, Tondu T. Breast reconstruction after breast conservation therapy for breast cancer. *Eur J Obstet Gynecol Reprod Biol.* 2018;230:233-238. doi:10.1016/j.ejogrb.2018.03.049
5. Barzaman K, Karami J, Zarei Z, et al. Breast cancer: Biology, biomarkers, and treatments. *Int Immunopharmacol.* 2020;84:106535. doi:10.1016/j.intimp.2020.106535
6. Akram M, Iqbal M, Daniyal M, Khan AU. Awareness and current knowledge of breast cancer. *Biol Res.* 2017;50(1):33. Published 2017 Oct 2. doi:10.1186/s40659-017-0140-9
7. Byler S, Goldgar S, Heerboth S, et al. Genetic and epigenetic aspects of breast cancer progression and therapy. *Anticancer Res.* 2014;34(3):1071-1077.
8. Eini M, Zainodini N, Montazeri H, Mirzabeigi P, Tarighi P. A Review of Therapeutic Antibodies in Breast Cancer. *J Pharm Pharm Sci.* 2021;24:363-380. doi:10.18433/jpps31864
9. De Martino M, Vanpouille-Box C, Galluzzi L. Immunological barriers to immunotherapy in primary and metastatic breast cancer. *EMBO Mol Med.* 2021;13(8):e14393. doi:10.15252/emmm.202114393
10. Kim MY. Breast Cancer Metastasis. *Adv Exp Med Biol.* 2021;1187:183-204. doi:10.1007/978-981-32-9620-6_9
11. Kozłowski J, Kozłowska A, Kocki J. Breast cancer metastasis - insight into selected molecular mechanisms of the phenomenon. *Postepy Hig Med Dosw (Online).* 2015;69:447-451. Published 2015 Apr 8. doi:10.5604/17322693.1148710

12. Barco I, Garcia-Font M, García-Fernández A, et al. Breast cancer patients developing distant metastasis at follow-up: Mortality-related factors. *Breast J*. 2021;27(3):291-293. doi:10.1111/tbj.14159
13. Uematsu T. MRI findings of inflammatory breast cancer, locally advanced breast cancer, and acute mastitis: T2-weighted images can increase the specificity of inflammatory breast cancer. *Breast Cancer*. 2012;19(4):289-294. doi:10.1007/s12282-012-0346-1
14. Chen Y, Wang L, Luo R, Liu H, Zhang Y, Wang D. Focal breast edema and breast edema score on T2-weighted images provides valuable biological information for invasive breast cancer. *Insights Imaging*. 2023;14(1):73. Published 2023 Apr 30. doi:10.1186/s13244-023-01424-7
15. Maxwell F, de Margerie Mellon C, Bricout M, et al. Diagnostic strategy for the assessment of axillary lymph node status in breast cancer. *Diagn Interv Imaging*. 2015;96(10):1089-1101. doi:10.1016/j.diii.2015.07.007
16. Chin HW, Guerra JF. Breast cancer and axillary nodal status. *J Can Assoc Radiol*. 1980;31(3):187-189.
17. Datsenko VS, Rozanov IB, Sukhoveev PN, Vinogradov LI. Radikal'naiia mastéktomiia po Peiti pri kombinirovannom lechenii raka molochnoï zhelezy [Patey's radical mastectomy in combined treatment of breast cancer]. *Khirurgiiia (Mosk)*. 1989;(12):81-85.
18. Castellano M, Marín M, Alcalá L, et al. Exhaustive diagnosis of breast implants with capsular contracture: The microbiology laboratory as a major support. *J Plast Reconstr Aesthet Surg*. 2022;75(9):3085-3093. doi:10.1016/j.bjps.2022.06.014
19. Ganon S, Morinet S, Serror K, Mimoun M, Chaouat M, Boccara D. Epidemiology and Prevention of Breast Prosthesis Capsular Contracture Recurrence. *Aesthetic Plast Surg*. 2021;45(1):15-23. doi:10.1007/s00266-020-01876-y
20. Wan D, Rohrich RJ. Revisiting the Management of Capsular Contracture in Breast Augmentation: A Systematic Review. *Plast Reconstr Surg*. 2016;137(3):826-841. doi:10.1097/01.prs.0000480095.23356.ae
21. Boyd CJ, Chiodo MV, Lisiecki JL, Wagner RD, Rohrich RJ. Systematic Review of Capsular Contracture Management following Breast Augmentation: An Update. *Plast Reconstr Surg*. 2024;153(2):303e-321e. doi:10.1097/PRS.0000000000010358

22. Kuehlmann B, Burkhardt R, Kosaric N, Prantl L. Capsular fibrosis in aesthetic and reconstructive-cancer patients: A retrospective analysis of 319 cases. *Clin Hemorheol Microcirc.* 2018;70(2):191-200. doi:10.3233/CH-170365
23. Pollock H. Breast capsular contracture. *Plast Reconstr Surg.* 1997;100(6):1619-1620. doi:10.1097/00006534-199711000-00054
24. Spear SL, Baker JL Jr. Classification of capsular contracture after prosthetic breast reconstruction. *Plast Reconstr Surg.* 1995;96(5):1119-1124.
25. Capozzi A, Pennisi VR. Clinical experience with polyurethane-covered gel-filled mammary prostheses. *Plast Reconstr Surg.* 1981;68(4):512-520. doi:10.1097/00006534-198110000-00006
26. Berrino P, Franchelli S, Santi P. Surgical correction of breast deformities following long-lasting complications of polyurethane-covered implants. *Ann Plast Surg.* 1990;24(6):481-488. doi:10.1097/00000637-199006000-00003
27. Heine N, Brebant V, Seitz S, Eigenberger A, Prantl L, Tessmann V. Lightweight implants in breast reconstruction. *Clin Hemorheol Microcirc.* 2023;84(1):103-109. doi:10.3233/CH-239101
28. Rubin R. New Breast Implant Safety Concerns. *JAMA.* 2022;328(15):1492. doi:10.1001/jama.2022.15477
29. Austin RE, Lista F, Ahmad J. Hot Topics in Breast Surgery. *Clin Plast Surg.* 2021;48(1):131-139. doi:10.1016/j.cps.2020.09.004
30. McKernan CD, Vorstenbosch J, Chu JJ, Nelson JA. Breast Implant Safety: an Overview of Current Regulations and Screening Guidelines. *J Gen Intern Med.* 2022;37(1):212-216. doi:10.1007/s11606-021-06899-y
31. Zhao Q, Ogino S, Lee S, et al. Development of new bioabsorbable implants with de novo adipogenesis. *Regen Ther.* 2023;24:311-317. Published 2023 Aug 12. doi:10.1016/j.reth.2023.07.008
32. Prasad K, Zhou R, Zhou R, Schuessler D, Ostrikov KK, Bazaka K. Cosmetic reconstruction in breast cancer patients: Opportunities for nanocomposite materials. *Acta Biomater.* 2019;86:41-65. doi:10.1016/j.actbio.2018.12.024
33. Danino MA, Dao L, Retchkiman M, Matetsa E, Iezioni J, Bou-Merhi JS. Analysis of Allergan's Biocell Implant Recall in a Major University Breast Center. *Plast Reconstr Surg Glob Open.* 2020;8(6):e2906. Published 2020 Jun 25. doi:10.1097/GOX.0000000000002906

34. Spear SL, Hedén P. Allergan's silicone gel breast implants. *Expert Rev Med Devices*. 2007;4(5):699-708. doi:10.1586/17434440.4.5.699
35. Swanson E. Concerns Regarding Dishonesty in Reporting a Large Study of Patients Treated With Allergan Biocell Breast Implants. *Ann Plast Surg*. 2022;88(6):585-588. doi:10.1097/SAP.0000000000003199
36. Unger JG, Carreras JM, Nagarkar P, Jeong HS, Carpenter W. Allergan Style 410 Implants for Breast Reconstruction: A Prospective Study in Efficacy, Safety, and Symmetry. *Plast Reconstr Surg*. 2016;138(3):548-555. doi:10.1097/PRS.0000000000002429
37. Doren EL, Pierpont YN, Shivers SC, Berger LH. Comparison of Allergan, Mentor, and Sientra Contoured Cohesive Gel Breast Implants: A Single Surgeon's 10-Year Experience. *Plast Reconstr Surg*. 2015;136(5):957-966. doi:10.1097/PRS.0000000000001675
38. Jewell ML, Bengtson BP, Smither K, Nuti G, Perry T. Physical Properties of Silicone Gel Breast Implants [published correction appears in *Aesthet Surg J*. 2019 Nov 13;39(12):NP552-NP553]. *Aesthet Surg J*. 2019;39(3):264-275. doi:10.1093/asj/sjy103
39. Nathan B, Nash Z, Nathan M. Intraoperative irreversible deformation of Allergan's style 410 breast implant. *Aesthetic Plast Surg*. 2014;38(2):484. doi:10.1007/s00266-014-0305-7

8. CV

Falgari Maria Antonietta, born on April 13th, 1997, in Florence, Italy. She started her educational journey in 2003, attending primary school. Her studies included three years of middle school and five years of scientific high school from which she graduated with 81/100 in 2015/2016. After that she spent a year studying at biomedical faculty in Florence while entering marine military forces. In 2017, she then pursued her passion for medicine by enrolling at the University of Rijeka in Croatia. In addition to her medical studies, Maria Antonietta actively participated in different internships within various medical hospitals during her summer vacations while helping and learning from her mother, an Otorhinolaryngologist and Aesthetic surgeon, gaining essential hands-on experience and expanding her practical understanding of the medical profession.