

Reconstructive surgery of the nose

Barišić, Dominik

Master's thesis / Diplomski rad

2016

Degree Grantor / Ustanova koja je dodijelila akademski / stručni stupanj: **University of Zagreb, School of Medicine / Sveučilište u Zagrebu, Medicinski fakultet**

Permanent link / Trajna poveznica: <https://um.nsk.hr/um:nbn:hr:105:745973>

Rights / Prava: [In copyright / Zaštićeno autorskim pravom.](#)

Download date / Datum preuzimanja: **2024-04-25**



Repository / Repozitorij:

[Dr Med - University of Zagreb School of Medicine
Digital Repository](#)



UNIVERSITY OF ZAGREB

SCHOOL OF MEDICINE

Dominik Barišić

RECONSTRUCTIVE SURGERY OF THE NOSE

GRADUATE THESIS



Zagreb, 2016

This graduation paper has been done at the Department of ENT H&N Surgery Sisters of Mercy University medical centre of Zagreb under the supervision of Prof.dr.sc Tomislav Baudoin in the academic year of 2015 /2016.

1 LIST OF FIGURES

- Figure 1:** Total number of septoplasties and septo-rhinoplasties performed at the department of ENT H&N Surgery Sisters of Mercy University medical centre of Zagreb between 2012 and 2015.
- Figure 2:** Total number of septoplasties performed at the department of ENT H&N Surgery Sisters of Mercy University medical centre of Zagreb between 2012 and 2015.
- Figure 3:** Total number of septo -rhinoplasties performed at the department of ENT H&N Surgery Sisters of Mercy University medical centre of Zagreb between 2012 and 2015.
- Figure 4:** Number of septo-rhinoplasties performed at the department of ENT H&N Surgery Sisters of Mercy University medical centre of Zagreb between 2012 and 2015, stratified by age groups.
- Figure 5:** Number of septoplasties performed at the department of ENT H&N Surgery Sisters of Mercy University medical centre of Zagreb between 2012 and 2015, stratified by age groups.

2 LIST OF ABBREVIATIONS

| | |
|------|--------------------------------------|
| A | Alar groove |
| ENT | Ear nose and throat |
| FTSG | Full thickness skin graft |
| LLC | Lower lateral cartilage |
| N | Nasion |
| NF | Nasofrontal angle |
| NL | Nasolabial angle |
| RSTL | Resting skin tension line |
| SFL | Superficial fatty layer |
| SMAS | Superficial musculoaponeurotic layer |
| SSTE | Skin-soft tissue envelope |
| STSG | Split thickness skin graft |
| T | Nasal tip |

Table of Contents

| | | |
|--------------|--|------------|
| 1 | LIST OF FIGURES | iii |
| 2 | LIST OF ABBREVIATIONS..... | iv |
| 3 | ABSTRACT | vii |
| 4 | Introduction | 1 |
| 4.1 | Anatomy of the nose..... | 3 |
| 4.1.1 | External Anatomy of the nose | 3 |
| 4.1.1.1 | Nasal Pyramid..... | 4 |
| 4.1.1.1.1 | Bony Pyramid | 4 |
| 4.1.1.1.2 | Cartilaginous Pyramid | 5 |
| 4.1.1.1.3 | Lobule | 6 |
| 4.1.1.1.4 | Soft tissue envelope | 7 |
| 4.1.1.2 | Neurovascular structures..... | 8 |
| 4.1.2 | Internal Anatomy of the nose..... | 10 |
| 4.2 | Physiology of the nose | 10 |
| 4.2.1 | Respiration | 10 |
| 4.2.1.1 | Air conditioning | 11 |
| 4.2.1.2 | Filtration | 12 |
| 4.2.2 | Olfaction | 13 |
| 4.3 | Aesthetics of the nose | 14 |
| 4.3.1 | Facial proportions..... | 14 |
| 4.3.1.1 | Frontal view..... | 15 |
| 4.3.1.2 | Lateral view..... | 16 |
| 4.3.1.3 | Oblique view | 18 |
| 4.3.1.4 | Basal view | 18 |
| 4.4 | Aesthetic principles in Reconstructive Nose Surgery | 19 |
| 4.4.1 | Septoplasty | 20 |
| 4.4.1.1 | Surgical Technique | 21 |
| 4.4.1.2 | Complications of Septal Surgery | 25 |
| 4.4.2 | Rhinoplasty | 26 |
| 4.4.2.1 | Approach to Rhinoplasty..... | 27 |
| 4.4.2.2 | Surgery of the Osseocartilaginous Vault | 28 |
| 4.4.2.3 | Resection of the Dorsal Hump..... | 28 |
| 4.4.2.4 | Complications after Dorsal Hump Resection | 31 |
| 4.4.3 | Osteotomies | 31 |
| 4.4.3.1 | Complications after Osteotomies..... | 33 |
| 4.4.4 | Surgery of the Nasal Tip..... | 34 |
| 4.4.4.1 | Surgical Incisions in Nasal Tip Surgery | 34 |
| 4.4.4.2 | Approaches and Surgical Techniques in Nasal Tip Surgery | 35 |
| 4.4.4.2.1 | The Nondelivery Approach | 36 |
| 4.4.4.2.2 | The Delivery Approach | 37 |
| 4.4.4.2.3 | The External Approach | 38 |
| 4.4.5 | Reconstruction of Skin Cancer Defects of the Nose | 39 |
| 4.4.5.1 | Nasal Reconstruction Modalities in Skin Cancer Defect | 39 |
| 4.4.5.1.1 | Healing by Primary Intention | 40 |
| 4.4.5.1.2 | Healing by Secondary Intention | 40 |
| 4.4.5.1.3 | Skin Grafts | 41 |
| 4.4.5.2 | Local and Regional Flaps | 43 |

| | | |
|-----------|--|-----------|
| 4.4.5.3 | Local Flaps..... | 43 |
| 4.4.5.4 | The Rhomboid Flap | 43 |
| 4.4.5.5 | The Note Flap | 44 |
| 4.4.5.6 | The Bilobular Transposition Flap | 44 |
| 4.4.5.7 | The V-to-Y Island Pedicle Advancement Flap | 45 |
| 4.4.5.8 | Regional Flaps | 45 |
| 4.4.5.9 | The Nasolabial Flap..... | 46 |
| 4.4.5.10 | The Forehead Flap | 46 |
| 5 | Research Goal | 47 |
| 6 | Results..... | 48 |
| 7 | Discussion..... | 53 |
| 8 | Conclusion | 55 |
| 9 | Acknowledgement | 56 |
| 10 | References..... | 57 |

3 ABSTRACT

Title: Reconstructive Nose Surgery

Author: Dominik Barisic

The field of reconstructive nose surgery looks back on a long history, having its origins in ancient Egypt and India. As early as 600 BC, a Hindu surgeon reconstructed a nose using an advancement flap from the cheek (Rogers BO, 1967). Nasal disfigurement caused by barbaric war customs in some ancient population further raised the need for surgical intervention to restore function and appearance to the premorbid state of the nose.

Nowadays, the most common reasons for reconstructive nose surgery range from simple procedures such as the correction of a deviated septum to fully reconstructing a nose after skin cancer extirpation or animal wound bites.

This retrospective study attempts to summarize all major surgical techniques used in reconstructive nose surgery and analyzes the data of patients having undergone septoplasty and septo-rhinoplasties performed in the period of 2012 to 2015 at the department of ENT H&N Surgery Sisters of Mercy University medical center of Zagreb, Croatia.

Keywords: Reconstructive Nose Surgery; Septoplasty; Septo-rhinoplasty, Skin graft

4 Introduction

The nose as a composite structure is composed of a nasal skeleton, an internal lining of mucosa, as well as an external layer of skin. The external topographical features of the nose created by the blend of concavities, convexities and ridges mirror the underlying nasal skeleton. The face is considered to be closely linked to peoples identity and self-image. The nose as the most central and prominent part of the human face plays a crucial role in maintaining that image. This is why the disruption of the normal appearance of this organ can be tremendously distressing for affected people. The structural complexity of the nose as a whole combined with its aesthetic significance reflects how challenging it is to facial plastic surgeons when it comes to reconstructing this delicate body part.

Before determining how to properly perform nasal reconstruction, a detailed anatomical knowledge including the aesthetic aspects of the nose are essential to acquire when configuring the reconstructive effort. In the next step, the surgeon must select a proper reconstruction technique or a combination of them taking into consideration the size, the localization of the defect as well as the availability of tissue. An anatomical reconstruction must ensure to restore the inner lining, the osseocartilaginous framework and the skin cover to achieve the best possible aesthetic and functional results (Park S, 2008). The aesthetic expectations of both minor and major nasal repair include symmetry, natural contour, excellent color and texture match, and a final product that remains inconspicuous to the casual observer (Menick FJ, 2010).

Nevertheless, reality has taught us that recreating the human nose to its initial, natural appearance remains close to impossible. The task of the surgeon lies in modeling bits and pieces of expandable tissues into a facsimile to ultimately give the visual impression of a normal nose.

The main goals of reconstructive nose surgery are limited to four important aspects. Creating a clean, dry wound that restores the skin's normal barrier function. Restoring and maintaining the function of the nose as well as restoring the nose to its aesthetically perfect, premorbid state. Lastly, restoring the nose to a state that does not permit the individual to have feelings of embarrassment in its environment. The goal of achieving a nearly perfect cosmetic result that is in no way inferior to the premorbid state still poses the greatest challenge to the surgeon, working in this field of medicine. This is what drives facial plastic surgeons to improve existing techniques or develop new ones, with the ultimate purpose of attaining perfect results.

In the scope of this thesis paper, we will discuss the principles of nasal reconstruction and review all relevant surgical reconstruction techniques.

Moreover, we will analyze and discuss the results of septoplasties and septo-rhinoplasties performed on patients in the department of ENT H&N Surgery Sisters of Mercy University medical center of Zagreb, Croatia between the years of 2012 to 2015.

4.1 Anatomy of the nose

4.1.1 External Anatomy of the nose

The external nose makes up the visible portion of the nose that projects from the face. Its underlying framework is largely composed of cartilaginous structures which for the most part are responsible for the diversity in size and shape of the nose in individuals.

By visual appearance, the nose can be divided into the root, the dorsum of the nose, nasal tip or apex and base. The nasal root forms the most cephalic structure. It is formed by the junction of the paired nasal bones with the nasal process of the frontal bone. Furthermore, it serves as the starting point of the nasal dorsum which extends all the way caudally to the apex of the nose. Moreover, the anterior surface of the nose contains two additional important anatomical landmarks namely the nasion and rhinion. The nasion is the distinctly depressed area situated directly between the eyes, just superior to the root of the nose. The rhinion on the other hand is located more caudally representing the point at the osteocartilaginous junction over the dorsum of the nose.

The triangular shaped nasal base faces downward and is formed by two alae nasi or wings of the nose and the external nares. It is further divided in the midline by a mobile bar-like structure, called columella.

4.1.1.1 Nasal Pyramid

The major structural components of the external nose can be divided into the bony pyramid, the cartilaginous pyramid, the lobule and soft tissue areas.

4.1.1.1.1 Bony Pyramid

The supporting bony framework of the external nose essentially consists of the nasal bones and the frontal process of the maxilla. It may include the base of the frontal bone in the formation of the root of the nose depending on the size of the nasal bone.

The paired nasal bones communicate with the nasal processes of the frontal bone cephalically, thus forming the so-called nasofrontal angle. Laterally, the nasal bones are joint to the frontal process of the maxillary bone, partially overriding the upper lateral cartilages. This pyramid encloses the nasal cavity and is largely responsible for the width of the bony nose in the upper third.

The pear shaped bony inlet of the nose, formed by the nasal bones and frontal processes of the maxilla superiorly and laterally and the body of the maxilla inferiorly is known as the pyriform aperture. The anterior nasal spine is a sharp projection arising at midline level on the lower margin of this aperture.

4.1.1.1.2 Cartilaginous Pyramid

The nasal cartilages make up the lower two thirds of the nose and thus form the largest part of the external nasal structures. Consisting of the cartilaginous part of the nasal septum and the upper lateral cartilages, the cartilaginous pyramid creates one big cartilaginous unit that assumes triangular shape. The angle which is therefore created between the nasal septum and the caudal border of the upper lateral cartilages adds up to around 10 -15 °, and is termed the internal valve of the nose (Kasperbauer JL, 1987). On the contrary, the external valve is described as the region caudal to the internal valve, bounded laterally by the nasal ala and medially by the septum and columella. Those two valves form the so-called valve area, which in turn regulates the inspiratory airflow and is considered as the area of maximum nasal flow resistance (Walsh, 2006).

The upper lateral cartilages are connected cephalically to the caudal margin of the nasal bones with a slight underlap of 1 to 2 mm. On their caudal end however, they overlap the more inferiorly situated cephalic border of the lower lateral cartilages. This region of overlap, known as the scroll area, forms the first major support mechanism of the nasal tip (Griesman BL, 1944).

Laterally, dense connective tissue serves as a site of attachment and support of the ULC to the pyriform aperture.

The cartilaginous nasal septum forms the most anterior part of the nasal septum articulating caudally, from ventral to dorsal with three different bony structures, namely the anterior nasal spine, the premaxilla and the vomer. On its caudal side it forms a free

connection with the columella whereas dorsally it attaches firmly to the perpendicular plate of the ethmoid bone.

4.1.1.1.3 Lobule

The lobule is the nasal structure, which consists of the two LLCs, muscle fibers, fat and connective tissue. On its outside it is covered by thick skin containing a high density of sebaceous glands. As the most forward projecting structure of the nose, the lobule can be further divided into the subareas namely the tip, alae, the columella, the nostril and the vestibule.

The tip makes up the anterior point of the lobule. The area situated immediately above the tip is referred to as supratip and the area below is known as infratip.

The lateral walls of the lobule are formed by the alae or wings of the nose. From the inside to the outside these walls are made of the lateral crura of the LLC, muscle and skin.

Lastly, the columella, which is located on the base of the lobule, is the column shaped bar that forms the most caudal part of the nasal septum.

All of the above-mentioned structures of the lobule are mainly determined in shape and form by one structure, the LLCs or alar cartilages. For surgical purposes, this cartilaginous structure is further divided into the lateral, the intermediate and the medial crura as well as the dome. The lateral crus, on the lateral side of the LLC varies in shape assuming either convex, concave, convex-concave, or concave-convex forms. It is firmly connected to the bony margin of the pyriform aperture by dense fibrous tissue and shows additional soft tissue attachments to the frontal processes of the maxilla on its posterior border. Besides,

this area commonly exhibits small sesamoid cartilages, which are also referred to as minor alar cartilages.

The more anteriorly located convex curved intermediate or middle crus extends between the medial crus and the domes. It consists of the upper domal segment and the antero-caudal lobular segment. Although the narrowest, thinnest and most delicate portion of the entire alar cartilage arch, the two domal segments or domes conjointly form and shape the tip of the nose. The more medially located lobular segments on the other hand determine the shape, height and protrusion of the infratip lobule. In addition, the area posterocaudally to the domes between the lateral and medial segments contains two pieces of soft tissue, which are commonly referred to as the soft triangles.

Like the intermediate crus of the LLCs, the medial crus can also be divided into two distinct sections: the footplate and the columella. The dorsally located part of the medial crus is termed the footplate segment whereas the ventral part is known as the columellar segment. The lateral angulation and the size of the footplate can vary significantly in individuals. In addition, the degree of lateral angulation defines the width of the base of the columella.

4.1.1.1.4 *Soft tissue envelope*

The soft tissue envelope comprises four layers namely, the superficial fatty layer, the fibromuscular layer, the deep fatty layer, and the perichondrial/periosteal layer (Letaourneau A, 1988). The uppermost superficial fatty layer (SFL) is intimately attached

to the dermis. Directly underneath the SFL one can find the so called fibromuscular layer. These two layers combined are also known as superficial musculoaponeurotic system (SMAS), which is in continuity with the remainder of the SMAS overlying the face. Moreover, the mimetic muscles of the nose are considered to be encased in this construction.

The next layer is the deep fatty layer, which encloses all neural as well as vascular structures of the nose. Sitting between this layer and the subjacent perichondreal/periosteal layer is the so-called avascular plane. This plane plays an important part in the degloving process during rhinoplasties.

As mentioned above, the mimetic muscles make up a significant part of the soft tissue envelope. They are generally divided into 4 groups (Griesman BL, 1955). The elevator muscles namely, the procerus, levator labii superioris alaeque nasi and the anomalous nasi shorten the nose and dilate the nostrils. The depressor muscles, lengthening the nose and dilating the nostrils comprise the alar nasalis and the depressor septi nasi. Furthermore, the compressor muscles function to lengthen the nose and narrow the nostrils are known as transverse nasalis and the compressor narium minor. Finally, the minor dilator muscle, the dilator naris anterior, widens the nostrils.

4.1.1.2 Neurovascular structures

Branches of both external carotid artery and internal carotid artery generally provide the blood supply of the nose (Oneal RM, 2011). These branches include the facial artery and infraorbital artery and the ophthalmic and anterior ethmoidal artery, respectively.

In the external carotid artery system, the facial artery gives off two terminal branches, the angular and the superior labial artery. The latter extends medially to the columella, dividing into septal branches to supply the anterior portion of the nasal septum mucosa. In contrast, the angular artery passes in a deep groove between nasal alae and the cheek giving off a lateral nasal branch which provides blood supply to the lateral segments of the caudal nose.

The internal carotid artery system also forms an extensive vascular network that supplies the nose. The ophthalmic artery branches into ocular and orbital branches, which in turn supplies blood to the anterosuperior of the nasal cavity.

The nerve supply to the nose is provided by the ophthalmic and maxillary branches of the trigeminal nerve. The sensation in the skin of the middle third of the face that is the cheek ala and upper lip is derived from the infraorbital branch of the maxillary nerve. On the contrary the upper third of the nose and the medial orbital angle is supplied by the infratrochlear nerve, a branch of the ophthalmic. Finally, the middle third of the nose and nasal dorsum and nasal tip receives their nerve supply from the external branches of the ethmoidal nerve.

The motor nerve supply to the muscles of the nose is as for all other facial muscles provided by the facial nerve.

4.1.2 Internal Anatomy of the nose

When looking at the anatomical structures comprising the inner part of the nose we can divide the nose into two internal spaces. These two spaces are confined by the nasal septum as the midline or dividing structure and the two lateral nasal walls as the flanking borders.

The floor of these two spaces are made up of bone namely, the palatine process of the maxilla anteriorly and the horizontal plate of the palatine bone posteriorly. In contrary, the roof of this cavity comprises bony segments in the cephalic part as well as cartilaginous segments in the caudal part.

Protruding from the inner lateral walls of the nasal cavity three thin, curved, bony prominences can be found, called the turbinates or conchae.

4.2 Physiology of the nose

Besides its sheer complexity and essence to the quality of life, the physiology of the nose is an intriguing and dynamic field of study with a staggering amount of new discoveries made on macroscopic, microscopic and molecular level in recent years.

As the primary site of entry for inhaled air in the upper respiratory system the nose assumes several important functions.

4.2.1 Respiration

The nose serves as a semi-rigid conduit for in and out going air. On entering the nostrils in a 60 ° angulation, the inspired air is conducted upwards. As it reaches the nasal vault the

airstream diverges into multiple flows following the different meatus and the space below the turbinates. At this level, the airstream traverses mostly horizontal until it hits against the posterior wall of the nasopharynx. The previously separated air streams reunite at this point to continue traveling in a downward angulation of about 80 - 90 ° towards the lower parts of the respiratory system.

The internal nasal valve is the narrowest part of the upper respiratory tract with a cross section of 20-40 mm², provides about 50% of the total airways resistance (Courtiss EH, 1987). In the horizontal segments of the nasal airway posterior to this point the cross section broadens while the air streams remains narrow and therefore gives rise to a large surface, which is in intimate contact with the air stream.

Another factor that was thought to contribute to resistance in the nasal passages is the phenomenon known as the nasal cycle. In health, cyclical congestion and decongestion of the mucosa alternating between the two nasal cavities occur in a four to twelve hour rhythm. These changes usually occur without any awareness in the healthy individual and were found not to have any impact on the nasal resistance despite the constant diameter alterations within the nasal vault.

4.2.1.1 Air conditioning

The nose acts as an air conditioning unit, thus performing its two principal functions: Heating and humidification of inspired air. The mechanisms responsible for these changes namely, convection, conduction, radiation and evaporation are in fact so efficient, that the

inspired air at the level of nasopharynx measure body temperature with a relative humidity of around 85 % (DL Swft, 1982).

4.2.1.2 Filtration

The high concentration of particulate matter found in inspired air could be potentially harmful to the delicate structures of the lower respiratory tract. To avoid entry of particles into the descending airways, the nose functions as a filter, trying to trap particles in the mucus film, which covers the nasal epithelium. The entrapped particulate matter is subsequently transported to the oropharynx, from where it can be swallowed.

The efficacy of the nasal filter function has been shown to depend mostly on the normal anatomical and functional integrity of the nose as well as the size of the airborne particles. As a result, almost 85-90 % of the inspired particles with a diameter greater than or equal 5 μm is deposited along the nasal cavity by the time the airflow reaches the posterior nasopharynx (Ballenger JJ, 1993).

The structure responsible of retaining airborne particles is known to be the mucociliary blanket. This layer of mucus covering the ciliated respiratory epithelium creates a positive electrostatic charge on the walls of the nasal cavity. As a consequence of this, all inhaled particles carrying a negative electrical charge are thereby attracted to the nasal walls and thus prevented from advancing any farther down the respiratory tract.

The constantly moving cilia propel the mucociliary blanket with its entrapped particles towards the oropharynx where they are subsequently swallowed or expectorated.

In addition, larger particles can be trapped directly by the vibrissae, situated just within the vestibule of the nose.

Additional protective mechanisms of the nose against foreign particles lie directly within or underneath the mucociliary blanket. A mixture of immunoglobulins and other macromolecules like lactoferrin, lysozymes help to neutralize noxious microorganisms.

4.2.2 Olfaction

The probably most complex of all functions of the nose is the ability to smell. The region responsible for smelling in the nose is situated high up in the roof of the nasal cavities and measures no more than 2.5 square centimeters on each side (Behrbom H, 2004). The olfactory region can be divided into several components each of which can be seen as one segment in the olfactory sensory transduction pathway. Starting at the bottom, olfactory cilia project down from the olfactory epithelium into a layer of mucus. These cilia are extensions of the bipolar neurons known as olfactory receptor neurons which in turn are embedded in the layer of the olfactory epithelium.

The mucus layer consisting of lipid-rich secretions assists in the transport of odorant molecules to the receptors of the olfactory neurons. These neuronal cells form axons that are bundled in groups to penetrate the ethmoidal cribriform plate of bone, reaching the olfactory bulb of the brain where they converge to terminate with post-synaptic cells to form synaptic structures called glomeruli.

From there on the information is relayed through the olfactory tract to the olfactory cortex.

4.3 Aesthetics of the nose

The nose occupies a central position in the human face and acts as a key anatomic structure for aesthetic and facial harmony. In addition to the nose, the face incorporates four other major aesthetic components namely forehead, eyes, lips and chin. The harmonious interplay of these structures is hence viewed as to create facial aesthetics. Changing the proportions and angles of any of these facial constituents can therefore directly interfere with the others and ultimately result in aesthetic disharmony of the face. For that reason, it is imperative for the surgeon to look and analyze the face in its entirety when planning a surgical intervention of the nose.

4.3.1 Facial proportions

There is no absolute standard for the aesthetically ideal proportions of the face or nose. The parameters, which determine the proportions of the nose, are chosen individually, taking into account sex, age, body type and facial characteristics.

In general, the female nose is relatively smaller, the dorsum and lobule narrower and on lateral view may show a slight concavity in dorsal aspect. In contrary, the male nose is relatively bigger than the female nose and tends to present a slightly convex dorsum in its profile. Moreover, the nose should be in harmony with the body type and structure. Shorter individuals can therefore have smaller noses and more tip rotation than tall individuals. In addition, the shape of the face should also be considered when reshaping the nose. In people with long or oval faces, a long or narrow nose will usually look more natural and

aesthetically harmonious. On the contrary, a short and broad nose will suit a more round or square face.

Taking all of the above mentioned parameters into consideration, one should yet supplement the pure visual examination of facial proportions with some more in depth analysis. Methods used for this purpose are mostly related to photographs or radiographs, which allow us to make precise measurements on angles, lines and distances between facial structures.

4.3.1.1 *Frontal view*

One of the first assessments of facial aesthetics, which should be made in frontal view, is the measurement of facial height and facial width. For this purpose, the face is divided into three horizontal and five vertical columns, respectively.

The three horizontal parts are bounded by lines that intersect four topographic points in the face: trichion (hairline in the midline), glabella (most prominent projection of lower forehead), subnasale (nasal spine) and menton (lower edge of the chin).

The accepted aesthetic ratio of this analysis is that of equal thirds. The upper third of the face includes the forehead, incorporating the uppermost bony parts of the nose. The aesthetic ideal of nasal bones should display symmetry and make up around 75 % of the width of the intercanthal distance. The middle third accommodates the biggest part of the nose. An imaginary curvilinear line can be drawn from the inner aspect of the eyebrow,

extending along the shadow of the bridge where it deviates slightly lateral as it transitions into the tip of the nose. This so-called brow tip aesthetic line should be a continuous curve without any disruptions along its path formed by any bony or cartilaginous irregularities. The line should be symmetrical on each side of the nose assuming the shape of an hourglass.

When assessing facial width, the face is divided into five vertical columns or fifths, which ideally are of equal size. The central fifth is measured between the inner canthi of the eyes and should be equal in size to the remaining fifths. It contains the middle parts of the face including the nose and provides means to estimate nasal width in context of overall facial width. The outer margins of the nose should fall within this central fifth. In other words, the aesthetic ideal of nasal width is given when the intercanthal distance is equal in size to the width of the alar base.

4.3.1.2 Lateral view

In lateral view, the patient's head needs to be aligned within the so-called Frankfort horizontal plane. For this purpose, the head is positioned in the way that a straight line can be drawn from the inferior orbital rim to the superior aspect of the external auditory canal which parallels the surface of earth or horizon. This view allows us to assess for the following major aspects of the nose: the projection and rotation of the nasal tip as well as the contour of the dorsum of the nose.

While there are several ways of measuring tip projection, the one most frequently used is the so-called Goode method. Using this method, first a vertical line is drawn from the nasion (N) to the alar groove (A). Next a second horizontal line is drawn that runs from the

nasal tip (T) perpendicular to the vertical line. The measure for tip projection is the ratio of TA/TN, which ideally lies in the range of around 0.55-0.60.

When trying to assess tip rotation on the lateral view, one can use the aid of what is known as the aesthetic angles of the face. The angle particularly used to assess tip rotation is called nasolabial angle (NL). This angle is essentially defined as the angle created between upper lip and the columella. On average this angle lies somewhere in the range of 90 -120 degrees differing in sex (male 90-105 degrees, female 105-120 degrees).

Multiple studies such as the one by Sinno et al indicated that there is no real consensus on an ideal nasolabial angle, suggesting to treat such measurements as a sole approximation (Sinno HH, 2014).

Another important angle to assess on profile view of the face is the nasofrontal angle (NF). The NF reflects the angle between the dorsum of the nose and the glabella. The NF in an aesthetically pleasing profile should measure approximately 115-125 degrees in women and 120-130 degrees in men. Moreover, the NF is commonly assigned the starting point of the nose, since it appears where the forehead ends and the nose begins.

As far as the contour of the nasal dorsum is concerned, the currently accepted standard is a straight and high dorsal profile. A slightly concave and a slightly convex appearance of the dorsum is acceptable in women and men, respectively.

The columellar show is another minor feature of the nose that can be assessed on the profile view of the nose. It reflects the visible extent of the inner nostril lining in this view. Ideally, the columella should extend 3-5 mm below the nares. In the case of insufficient columellar show the nostrils may appear retracted in profile. An aspect of less importance

on lateral view is the supra tip break. It presents as a small depression just cephalic to the nasal tip, at the point where the lobule meets the dorsal portion of the cartilaginous vault. More pronounced in women than in men this subtle depression is considered to be extremely aesthetically pleasing when present in the nasal profile.

4.3.1.3 Oblique view

Although one of the most underrated projection, the oblique view provides a good general overall impression of the contours of the lateral nasal wall. Especially Irregularities of the nasal bones, nasal length dorsal height are well highlighted on this view. Furthermore, one can check for discontinuation in the brow tip aesthetic lines and inhomogeneity in soft tissue facets, which are usually easy to discover in this projection.

4.3.1.4 Basal view

When inspecting the base of the nose we can assess the columella, alar rims and the subsurface of the tip. The overall shape of the nasal base can be described as that of an equilateral triangle with the nostrils making up two thirds of the height. This triangle is often referred to as a soft triangle since its tip is more like a dome. The columella can also be divided into three equal parts namely, the anterior lobular, a narrower intermediate part and a wider basal part.

The nostrils should be symmetric and ovoid in shape. Furthermore, the sides of the nostrils should be down to the point where the medial crura starts to flare. In case they flare out too soon, the columella may appear short and the nostrils would fail to assume the ovoid

shape. In addition, the basal view offers an excellent perspective to evaluate the width of the alar base. Ideally the width should equalize the length of the intercanthal distance.

4.4 Aesthetic principles in Reconstructive Nose Surgery

As a general rule, there are 3 key principles that reconstructive surgeons need to follow to obtain aesthetically pleasing results. The first principle applies to the replacement of missing tissue and states that missing tissue if possible should always be replaced by tissue of similar properties. The nasal skin can vary widely in color, texture and appearance within different parts of the nose. Hence, areas of the nose such as the nasal tip and ala are covered with thick, pitted skin owing to the high density of sebaceous glands in that region. On the contrary, areas like the columella, alar margins, nasal dorsum and the sidewalls of the nose show thin, smooth skin. The skin color also varies according to the region of the nose with pale skin of matt texture on the sides of the nose and a more shiny slightly pinkish appearance over the tip of the nose (Watts S, 2005). This principle is implemented when looking at the various flaps that are being used for nasal reconstruction. Despite many other factors the operator needs to take into consideration when choosing an appropriate flap, he always tries to find a flap, which shows the best match in color, texture and appearance to the missing tissue.

The second principle refers to the replacement of missing portions of the nasal skeleton. Therefore, any loss of primary cartilage support caused by removal of upper or lower cartilages needs to be restored by replacing it with septal or auricular cartilage.

Finally, the nose should be topographically divided into aesthetic units, often referred to as subunit principle. These subunits divide the nose into dorsum, tip, columella and the paired ala, sidewalls and soft triangles. The principle suggests that if a defect comprises more than 50% of a subunit, excision of the residual normal tissue should be considered (Burget GC, 1985). As a result, the entire subunit is reconstructed with a flap instead of just covering the original defect. The rationale of this principle is that by replacing an entire subunit it allows the surgeon to place scars in joints between three-dimensional units, where they can be hidden and less visible. In contrast, for defects comprising less than 50% of the subunit, the reconstruction should provide sufficient color and contour match, without removing any viable tissue.

4.4.1 Septoplasty

At birth and throughout childhood, the nasal septum usually assumes a straight line dividing the nose into two separate nasal cavities. However, as age progresses this structure tends to become deviated in some people leading to problems most commonly related to breathing but also epistaxis and the feeling of pressure and pain (Sooknundun 1986).

The etiology of such deformity is believed to be traumatic or iatrogenic in the majority of cases. In particular, the so-called congenital type of deviated septum is frequently related to traumatic birth as in the case of forceps delivered babies and newborns delivered through a narrow birth canal (Jafek BJ, 2001).

Therefore, septoplasty is the surgical procedure that aims at correcting this deformity to its initial state with the purpose of improving nasal breathing.

4.4.1.1 Surgical Technique

The general perception and approach in today's septoplasties is that of conservative resection and preservation of septal cartilage and bone. While there are different surgical approaches to perform septoplasty such as the endonasal, the open and the endoscopic approach we shall look at the traditional endonasal septoplasty for the purpose of this thesis.

Prior to the first incision, the nose needs to be treated with topical and local anesthetics. This is done by first inserting cotton pledgets soaked in oxymetazoline inside the nasal cavity with a bayonet forceps. Following this, the nasal septum is injected along the submucoperichondrial plane with a 1% lidocaine solution containing a ratio of 1: 100,000 parts of epinephrine. The injection is started at the most caudal part of the septum and follows a posterior course. Note that the opposite side of the septum should also be injected in the same manner.

These anesthetics will not only exert their analgesic effect directly onto the nasal septum and surrounding areas but will even more so help to minimize the bleeding into the operative field by decongesting the nasal mucosa. As a consequence of this an adequate view on the nasal septum is maintained at all times during the operation.

In general, there are four different ways of gaining surgical access to the nasal septum. Each one of these approaches or incisions has its own indications and merits but all together follow the ultimate goal of providing entrance to the submucoperichondral and subperiostal plane of the septum. The classic incision according to Killian is a vertical

incision made 1-1.5 cm cranially from the caudal septal border through mucoperichondrium preserving the contralateral side (Hinderer KH 1971). This incision offers relatively good access to almost all parts but especially the posterior side of the septum. Therefore, it is often advised for correction of a septum, which contains a straight anterior part and a septal deviation within the posterior third of the nasal cavity. The only limitation however is the poor access to the most caudally located septal areas.

Another way of accessing the nasal septum is by an open rhinoplasty approach using a Rethi incision. It refers to a horizontal transcollumelar incision, which enables the surgeon to elevate the skin from the nasal tip and dorsum. Furthermore, the alar cartilages and membranous septum are divided exposing the caudal border of the septum. This approach is generally reserved for the repair of septal perforations or in conjunction with open rhinoplasties.

The most commonly employed incision is the hemi-transfixion incision, which has the great advantage of providing both access to anterior as well as posterior parts of the septum. It is a vertical vestibular skin incision performed at the most caudal point of the cartilaginous septum where it adjoins the membranous septum (Cottle MH, 1948). Hence, it preserves the integrity of the membranous septum as opposed to the so-called total transfixion incision. The latter is an incision, which is identical to the hemitransfixion incision but dissects through the membranous septum. Furthermore, this incision in combination with intercartilaginous dissections provides excellent means of exposing the valve area as well as other parts of the nasal dorsum.

Regardless of which incision is chosen, it is of cardinal importance to identify the proper subperichondrial layer as it ensures an avascular plane for dissection.

Once the initial incision is made a Cottle elevator is used to elevate the mucoperichondrium from the cartilaginous septum under direct vision. The sharp end of the instrument is used to begin the dissection in the submucoperichondrial plane followed by using the blunt end to elevate the envelope anteriorly, posteriorly and inferiorly. This process of creating a wide mucoperichondrial envelope is also known as tunneling.

The decision as to whether creating tunnels on both sides or on only one side of the septum is made according to each individual case. Elevating the perichondrium unilaterally may theoretically leave a better blood supply to the cartilaginous septum yet in the case of a severe septal deviation a bilateral elevation may be advised as it provides much better access to the septum overall.

Regardless of which one of these two options is chosen the next step of the procedure includes an overall inspection of the septum with the help of a nasal speculum that is inserted at the entry site of the mucoperichondrial envelope. In case, a septal displacement off the maxillary crest or vomer is discovered upon visualization an inferior tunnel along the nasal floor needs to be created. Using an osteotome has proven useful in the task of releasing the septum from its attachments to the bony nasal crest.

Once the septum is liberated from these inferior floor attachments, it can be realigned to a midline position and subsequently secured to the periosteum of the most anterior part of the maxillary crest.

After the mucoperichondrial flap has been elevated and the septal displacement in the cartilaginous septum located, a Cottle or no.15 blade can be used to incise and penetrate through the cartilage at the point just anterior to the offending deviation. When opting for

bilateral mucoperichondrial elevation this incision would present adequate means of elevating the contralateral mucoperichondrium. Following this, the deviated part of the cartilaginous septum can be resected using a swivel knife or Cottle. In an attempt to decrease the potential for losing nasal support after cartilaginous resection of the nasal septum it is of utmost importance to preserve a 1-cm dorsal and 1-cm caudal segment of septal cartilage. This so created septal strut is also known as L-strut owing to its close resemblance to the letter „L“(Planas J., 1977). When disregarded, major post surgical complications such as saddle nose deformities are likely to arise.

Once excised the pieces of cartilage can be simply removed or morselized and the fragments repositioned between the opposing mucoperichondrial layers. This will bring the advantage of hindering the formation of adhesions between the two opposing layer and ultimately lowers the risk of septal perforation. The mucoperichondrial flaps can then be sutured together using mattress stitches. In this way all reimplanted material inside the nasal septum gets fixated. Furthermore, it reduces the risk of formation of potential dead space within the septum where a hematoma could form. An additional option to protect the nasal septum from forming septal hematoma is the application of postoperative splints. This method however is mostly restricted to cases of severe cartilaginous deviations of the septum where additional temporary support is needed. If splints are used, they can be safely removed 5-7 days after the operation (Anand K. 2009). Moreover, patients with nasal splints should be kept on antibiotic coverage while the splints are kept in place.

The endoscopic approach in septoplasty has been generally considered to be less invasive, requiring a lower degree of tissue manipulation than the previously described conventional method. Moreover, the nasal endoscope allows for better illumination and visualization of structures during the surgery as well as for a more precise identification of septal pathology and associated lateral nasal wall abnormalities, preoperatively.

However, certain limitations such as the higher requirement of expertise and the repetitive cleaning of the camera lens may favor the traditional approach in some cases.

4.4.1.2 Complications of Septal Surgery

Although not common, postusurgical bleeding ranks as the most frequent complication amongst all possible complications in the postoperative period with an incidence rate of 2-7 % (Fjermedal O, 1988). Incisions made around the branches of the palatine artery and premaxilla are frequently considered culprit of such bleedings. When bleeding occurs, the hematoma separates the mucoperichondrium from the cartilage, which ultimately leads to an interruption in the cartilage's blood supply. The resulting signs and symptoms present as acute pain, edema and complete nasal airway obstruction.

In the event, the hematoma is not evacuated within three days of onset it can lead to necrosis, resorption of cartilage and may potentially result in distortion of the nasal form.

In consideration of the fact that septoplasties are usually performed in an unsterile environment, the infection rate is rather low. It normally lies somewhat under 3 % (Lawson W 1983; Pirsig W. 1998).

Special attention should be paid to cases where nasal packs or splints are applied postoperatively. These patients run the risk of developing toxic shock syndrome and should always be placed on anti-staphylococcal antibiotics during the time of nasal packing or splinting.

Another rare but serious complication that can occur after septoplasty is a CSF leak. It usually results from an injury to the cribriform plate while trying to manipulate the septum, intraoperatively. Management involves surgical closure of the leak with subsequent bed rest, nasal packing and antibiotics. Moreover, it is of critical importance to keep such patients under close observation for signs of meningitis such as headache, fever, nuchal rigidity and photophobia (Wax MK, 1997)

Septoplasties in which submucosal resections are performed extensively often carry the risk of creating a perforation in the septum. The opening between the two nasal cavities can cause the patient to have nasal crusting, frequent episodes of nose bleeds and whistling during nasal respiration.

As pointed out previously, the maintenance of an adequate L-shaped nasal strut is imperative for septoplasty to be successful. Failure to do so can lead to major deformities of the nose including retraction of the columella, saddling of the nasal dorsum as well as alar widening.

4.4.2 Rhinoplasty

The surgical field of rhinoplasty is considered one of the most challenging fields of surgery entailing some of the most complex surgical procedures performed in the field of plastic surgery. The major contributing factors in this intricate surgery are believed to be the high

degree of anatomical complexity of the nose as well as the vast variability in size and shape of different nasal segments in each individual.

Given the complexity of the procedure, the field of rhinoplasty can be described as highly dynamic in the way that new surgical techniques and concepts are developed to attain even better results.

4.4.2.1 Approach to Rhinoplasty

In general, surgical access to the nose can be obtained either via the so-called endonasal/closed approach or the external/open approach. As the name implies the endonasal approach is performed when the incision is placed inside the nose as opposed to the external approach, which comprises an additional external incision over the columella.

Placing the extra transcollumellar incision outside the nose, enables the surgeon to lift skin and soft tissue envelope over the cartilaginous framework to get maximal exposure of the underlying cartilaginous framework. This is specifically useful in complex cases such as revision rhinoplasties and rhinoplasties involving grafting, which generally require a great deal of tissue manipulation and direct visualization of structures. Despite the benefit of having a better visualization on the underlying structures of the nose, the external approach also presents with certain disadvantages. The increased need of tissue manipulation and dissection is generally considered to result in longer operation time, longer postoperative recovery and an increased potential of unnecessary scarring.

However, the awareness of such complications is high amongst rhinoplastic surgeons and has led to a great number of new techniques and concepts trying to minimize the potential risk of such occurrence.

4.4.2.2 Surgery of the Osseocartilaginous Vault

In the sequence of operative steps in rhinoplasty, many surgeons favor to operate on the osseocartilaginous vault after tip surgery. One of the advantages of doing so is that the operator can apply an external nasal dressing right after the osteotomy. This helps to prevent or at least reduce the formation of postoperative edema and heavy bruising.

Moreover, in the majority of cases it is much easier to shape and adjust the osseocartilaginous vault to the form of the nasal tip than vice versa.

For the sake of simplicity, we will divide this part of the surgery into four sections and look at each one separately.

4.4.2.3 Resection of the Dorsal Hump

The adequate reduction of an over-projecting dorsum of the nose is a major determinant in achieving aesthetically pleasing results in rhinoplasty. Most dorsal hump deformities involve the protrusion of both the cartilaginous and the bony nasal vault. The bony segment of the hump however is usually much smaller than the cartilaginous segment.

Generally, we should differentiate between an absolute and a relative over-projection of the nose. In the case of an acute nasofrontal angle for example, the bony dorsum of the nose might look relatively over-projected. Hence, instead of reducing the nasal dorsum, as

we would do in the case of an absolute over-projection, we would try to employ an augmentative approach by adding cartilaginous or bony grafts.

Surgical access to the nasal dorsum is gained by either the transcolumellar, transcartilaginous or the intercartilaginous incision depending on which approach was used during tip refinement. When using the endonasal approach, the intercartilaginous incision is positioned at the caudal border of the nasal valve, extending laterally to medially around the anterior septal angle. A partial hemitransfixion incision is then placed along the caudal border of the septum, connecting the two intercartilaginous incisions.

In the next step of the procedure the operator tries to expose the cartilaginous vault by lifting the skin-soft tissue envelope (SSTE). This is achieved by applying small circular motions with a scalpel (No.15 Blade) in the suprachondrial surgical plane thus creating a dorsal tunnel. It is crucial to stay in this relatively avascular plane between perichondrium and muscle in order to avoid unnecessary bleeding and scarring.

Once the cartilaginous vault is fully exposed, an incision is made in the periosteum at the caudal end of the nasal bone. In this way, a transition to the subperiosteal plane is created which allows the surgeon to access the bony part of the nasal dorsum. Using a Joseph elevator, the periosteum together with the SSTE can be elevated cranially, which enables the operator to carefully evaluate the dorsum. Most dorsal humps consist primarily of cartilage with a small bony component.

At this stage of the procedure, it should be emphasized that the thickness of the overlying skin varies along the dorsum of the nose. The areas that should therefore be paid special attention to when freeing the cartilaginous vault from its overlying attachments is the area

covering the cartilaginous dorsum just above the supratip area and the area over the nasal bones just below the glabellar region. These areas show the thinnest overlying skin and are therefore prone to perforation when manipulated.

Moreover, it is important not to go underneath the nasal bone and disrupt the attachments of the ULC to the nasal bone. These attachments make up a major support mechanism of the nasal dorsum and can result in major nasal deformities when damaged.

With a retractor in place the surgeon can now excise the over-projecting part of the cartilaginous vault with a through and through incision from cephalic to caudal along the planned resection line. In order to achieve optimal results it is important to cut symmetrical through all three layers (both ULC and septum) of the cartilaginous vault. Another method employed to reduce the cartilaginous part of the dorsum is to cut the cartilaginous vault in three steps. The first step involves dissecting the ULCs on both sides of the septum. In the subsequent step, the freed cartilaginous septum is reduced to the desired height and the ULC trimmed to adapt the newly shaped septum.

Once the cartilaginous segment of the nasal hump is corrected we move on to excise any excess bone from the osseous part of the nasal hump. This resection can either be done in an incremental or en bloc manner. Furthermore, depending on the size of the dorsal hump the operator either uses an osteotome or a bone rasp. The instrument is introduced and advanced cranially by using the already established cartilaginous cutting face as a guideline. This is followed by the removal of the bone fragments and smoothing of the bony surface with the help of a fine diamond rasp. Once the nasal dorsum is retouched, it can be reevaluated by digital palpation using two fingers. If any irregularities are felt upon

the reevaluation, additional shaving of bone or cartilage can be done to obtain the desired smooth dorsal profile of the nose.

4.4.2.4 Complications after Dorsal Hump Resection

One of the most frequently encountered complications after surgery of the overprojecting dorsum is an over- or undercorrection of the nasal profile. In the case of an overcorrection it is possible to reinsert previously removed material or use autogenous septal cartilage grafts to restore the dorsal profile to an aesthetically pleasing result (Skoog T, 1966). In contrary, an undercorrection of the nasal dorsum can be simply reshaped by removing additional cartilage or bone. In either case, the operator should take note of such complication during the surgery and carry out any correction in the same procedure.

In the event the bony part of the dorsum is relatively overresected or in contrast the cartilaginous part insufficiently resected, it might lead to a deformity known as “polly beak deformity”. The patient affected by such complication can be described as having a nose with a high septal angle combined with a drooping nasal tip, thus giving it an appearance similar to that of a parrot’s beak (Tardy ME, 1989).

Another complication that can be seen postoperatively is an “open roof deformity”

4.4.3 Osteotomies

After hump excision the patient is usually left with what is known as an “open roof deformity”. This indicates that the nasal bone presents with a gap or a discontinuation in the dorsal area where it had been previously excised. Osteotomies are the most

commonly employed measure to reshape the osseous vault and thus close the gap. Other indications of osteotomies in rhinoplasty include: (1) to narrow the nasal sidewalls (2) to straighten a deviated nasal dorsum.

Commonly used osteotomy techniques include the lateral osteotomy, the medial osteotomy as well as the intermediate osteotomy.

A lateral osteotomy can be performed using either the linear (single cut) technique or the percutaneous perforating technique. With the linear technique, the micro-osteotome is used to make a bony incision along the nasal facial groove. The course of the incision begins at the ascending process of the maxilla or slightly above the superior margin of the inferior turbinate. The osteotome is advanced laterally preserving a bony ridge at the base of the lateral wall of the piriform aperture. This helps to keep the lateral attachments of the suspensory ligaments intact and therefore to maintain the nasal airway. Next, the osteotomy is continued cephalically up until the level of the inferior orbit where it curves anteriorly into the thinner aspects of the nasal bones.

In the perforating technique the operator places a small skin incision halfway along the desired fracture line. Next, small point-osteotomies are performed along the same line in a cephalic and caudal fashion. Although this technique may be more traumatic than the intranasal one, it has gained great popularity in recent times due to its ability to directly visualize the pathway of the osteotomy and thus providing excellent control for the surgeon. By far the most common indication for a lateral osteotomy is the correction of an open roof deformity.

Medial osteotomies are usually carried out when there is need to widen an overly narrowed bony nasal vault or when trying to mobilize the entire nasal sidewall. Depending

on the direction of the osteotomy we distinguish between the medial oblique osteotomy and the medial vertical osteotomy. The medial oblique osteotomy can again be performed linearly or percutaneously. The osteotome is placed on one side of the nasal bony dorsum just paramedian from the septum and advanced in an angular fashion superiorly and laterally.

Additional intermediate osteotomies are usually made parallel to the lateral osteotomy somewhere along the midportion of the nasal sidewall. They are usually performed prior to lateral osteotomies, as it is hard to make an intermediate cut once the bone is mobilized laterally. Primary uses for this osteotomy are: (1) to narrow extremely wide noses that have good height; (2) to straighten a markedly convex nasal bone; and (3) to correct a deviated nose with one sidewall much longer than the other (Larrabee WF, 1993).

After all the osteotomies are completed the nasal bones are infractured by applying digital pressure. The mobile nasal bones are realigned in the desired position and the open roof deformity closed.

4.4.3.1 Complications after Osteotomies

The three most common complications that may arise after osteotomy are: (1) a dorsum which is too narrow; (2) the rocker phenomenon; (3) the staircase phenomenon; and (3) asymmetries.

When performing the osteotomy too far cephalically beyond the intercanthal line the surgeon runs the risk of causing the upper segment of the osteotomized bone to project or

“rock” laterally. Hence, this deformity is referred to as rocker phenomenon (Anderson JR. 1966). The other phenomenon called the “staircase phenomenon” can be seen when the osteotomy is carried out too far medially. In this sequela, the conjoint nasal bones form an irregularity resembling that of a staircase. In the attempt of properly closing an open roof deformity, the operator might infracture the nasal bones in excess of what is required. This may result in a nasal dorsum that is too narrow and can therefore pose both aesthetical as well as functional problems to the patient. Finally, asymmetry in the nasal dorsum may occur when either a preexisting asymmetrical bony dorsum was not properly corrected during the surgery or the osteotomy itself was carried out in an asymmetrical way.

4.4.4 Surgery of the Nasal Tip

This part of the operation is considered the most challenging and by far the least understood of all parts. Given the anatomical complexity of the nasal tip and the broad structural variety in individuals, there is no single corrective procedure applicable to patients requiring nasal tip correction. Instead, the operator must be familiar and skilled in various approaches and maneuvers to successfully correct all deformities in an aesthetically pleasing fashion.

4.4.4.1 Surgical Incisions in Nasal Tip Surgery

Depending on which surgical approach is chosen, the two main incisions used in tip rhinoplasty are the intracartilaginous and the trans- or intercartilaginous incision. The latter is an incision placed between the upper and lower lateral cartilages whereas the

intracartilaginous incision is positioned more caudally, dissecting through vestibular skin and lateral crus. The two incisions can also be combined with a hemi or full transfixion incision in order to access the anterior septal angle and dorsum. Moreover, it needs to be emphasized that using the intercartilaginous incision and thus disrupting the connections between ULC and LLC weakens one of the major support mechanisms of the nasal tip. A third but minor incision used in tip rhinoplasty is the infracartilaginous or marginal incision. It courses along the caudal border of the LLC up to the columellar-lobular junction and is commonly used in conjunction with a transfixion incision in the external approach (Tardy ME,2002).

4.4.4.2 Approaches and Surgical Techniques in Nasal Tip Surgery

The choice of surgical approach made to expose the skeletal structures of the nasal tip is mainly based on the type and complexity of the nasal tip deformity. In addition, the experience of the operator often plays a crucial role in the decision-making process of which approach to use. Therefore, young inexperienced surgeon would frequently opt for an approach that provides better view and exposure of the anatomical structures although it may not be indicated.

Furthermore, the basic goal that all approaches of tip rhinoplasty have in common is to operate as atraumatically as possible and to preserve tip support whenever feasible. The three main approaches employed in nasal tip surgery are known as the intranasal (delivery or non-delivery) approach and the external approach.

4.4.4.2.1 The Nondelivery Approach

The non-delivery approach is usually performed when small volume reductions of the lateral crura and or slight cephalic nasal tip rotations are required. It can be carried out by either making a transcartilaginous or intercartilaginous incision, which is followed by cephalic trimming of the lateral crura and tissue manipulation (Daniel RK, 1993). Moreover, this approach proves to be most effective in people having good domal configuration, minimal tip bulbosity, medium skin thickness, tip cartilage symmetry and requiring only modest volume reduction.

In the operative procedure the surgeon first draws the skeletal landmarks and anatomical boundaries on the skin of the nose, making sure to outline the most cephalic part of the lateral crus to be respected. After that, a transcartilaginous incision is made with a No.15 blade and the vestibular skin is freed from the cephalic part with a pair of sharp pointed curved scissors. The same procedure is carried out on the opposite nonvestibular side of the LLC's cephalic part to be resected until it is fully exposed and ready to be excised. Once the cartilage is removed and a sufficient and symmetrical volume reduction is obtained on both sides of the nasal tip, the vestibular skin should be sutured with an atraumatic absorbable suture material. This simple approach to refine the nasal tip is by far the least traumatic of all approaches, which can mostly be attributed to keeping the integrity of the LLCs intact.

4.4.4.2.2 The Delivery Approach

In the event that more than just a small volume reduction is required as in the case of a widely arched, bifid or bulbous nasal tip deformity, the delivery approach presents a more suitable option than the non-delivery approach. It generally provides better exposure of structures and thus allows the surgeon to make more radical tip alterations such as the interrupted strip technique and suture narrowing. In this approach, an intercartilaginous incision is used in combination with a marginal incision to anteriorly deliver the LLCs out of the nostril as a bipediced chondrocutaneous flap. Therefore, the evident key benefit in this approach is that structures can be directly visualized. Yet the major drawback is the high risk of damaging the cartilage and altering the domal configuration (Quatela VC, 1997).

The first step in the surgical procedure to deliver the LLCs starts with an intercartilaginous incision using a No.15 blade. Performing this incision, the operator needs to make sure to extend it all around the anterior septal angle in order to avoid difficulties in the ensuing delivery. Next, a marginal incision is made and the non-vestibular side of the lateral crus is freed from all the overlying soft tissue by using a pair of sharp pointed curved scissors. The bipedicle chondrocutaneous flaps can now be delivered on both sides of the nose and kept in place with the help of two small hemostats. Finally, at this stage of the operation the surgeon can directly visualize the lower cartilaginous vault of the nose and precisely excise parts of the LLCs to reshape the nasal tip in the desired fashion.

To additionally reduce tip projection and obtain adequate cephalic tip rotation as would be needed in a tension nose for example, the LLCs are divided in the part of the lateral crus

at the junction of its middle and lateral third. This is followed by excising cartilage segments from the lateral and cephalic part and finally suturing the new ends together. This particular technique of nasal tip surgery is known as the interrupted strip technique. In the case of a bifid nasal tip, the same approach can be applied as before to expose the LLCs. However instead of excising parts of the cartilage the operator applies a horizontal mattress suture technique using non-absorbable or slow absorbable atraumatic sutures to advance and approximate the nasal domes and ultimately correct the deformity.

4.4.4.2.3 The External Approach

Although the most traumatic and most time consuming of all three approaches, the open or external approach is frequently used for complex nasal tip deformities. The reason why it has been commonly used in such cases is that it offers by far the greatest degree of exposure thus allowing the surgeon to evaluate underlying deformities more easily and thoroughly. In addition, it enables the operator to perform bimanual surgery and can therefore be of great help in cases, which require a lot of tissue manipulation. Indications to use this method include cases of congenital deformities such as cleft-lip nose, cases of severe nasal trauma as well as cases of extensive revision surgery. Nevertheless, a lot of young inexperienced rhinoplastic surgeons tend to use this method routinely, as it offers easier access and a better view on underlying structures.

The operative procedure involves making a bilateral marginal incision connected by a transcolumellar incision at the midcolumella. For optimal scarring, the midcolumellar incision should be shaped like an inverted- V, as recommended by Goodman and Charbonneau (Goodman WS, 1984). Once the incisions are made, the nasal skin can be

elevated from the LLCs up onto the radix and the surgeon proceeds to undertake alterations on the contour of the nasal tip. In the final step of the procedure, the midcolumnellar skin incisions need to be sutured back together meticulously as to prevent any skin necrosis and major scarring.

Even though the open approach does not compromise any major support mechanisms of the nasal tip, it needs to be emphasized that the wide surgical dissection used in this method creates numerous potential scarring sites in the nose. This being said, the increased scarring potential of this approach can create pulling forces, which can ultimately result in great distortion, postoperatively. In the attempt to counteract this, additional support in the form of grafts is being incorporated as an essential component in all open tip rhinoplasties.

4.4.5 Reconstruction of Skin Cancer Defects of the Nose

The management of reconstructing nasal defects following tumor surgery is affected by a vast array of factors such as the location of the tumor, the extent of the disease and previous treatment modalities used. These parameters determine the degree of tumor control and as a result, the method of reconstruction employed in each case.

The goal in nasal reconstructive surgery following removal of skin cancers is to not just to rebuild all or parts of the nose but rather tailor the old and new tissue in such fashion as to create cosmetically pleasing results. However, the great variety of skin texture, color and thickness of remaining tissue as well as the resources of available tissue can pose aesthetic limits that are often difficult to overcome.

4.4.5.1 Nasal Reconstruction Modalities in Skin Cancer Defect

A wide array of reconstructive modalities is nowadays available for the restoration of nasal skin cancer defects. Taking into consideration size, depth, and location of the surgical wound as well as the availability of the surrounding tissue, the surgeon must find and choose the most suitable technique for each individual case, to achieve aesthetically and functionally optimal results.

4.4.5.1.1 Healing by Primary Intention

By far one of the least frequently employed reconstructive modality in correcting nasal skin cancer defects is primary closure. This technique can be defined as simply suturing the wound edges together to close the skin defect.

The mobility of the skin overlying the nose varies according to nasal region, with moderately to very mobile skin in the supratip area and above as well as less mobile regions in the area around the nasal tip. Therefore, most small soft tissue wounds in the upper segments of the nose can be primarily closed without causing any appreciable deformity, whereas skin defects in the lower parts of the nose usually rely on other reconstruction techniques.

As a general rule, all incisions and lines of closure should whenever possible follow the lines of the RSTL. In the case that the skin defect lies perpendicularly to the RSTL, as would be the case for a dorsal defect for example, the simplest solution would be to advance lateral nasal walls and cheek tissues (Flint ID, 1994).

4.4.5.1.2 Healing by Secondary Intention

Healing by secondary intention is a reconstruction modality based on wound epithelialisation and wound contraction. Since it had been generally considered to yield unsatisfactory aesthetic results, it was frequently ignored as a valuable alternative to immediate surgical reconstruction of nasal skin defects (Zitelli JA, 1984; Gosler JB, 1992). However, from an aesthetic standpoint, the results obtained by using healing by secondary intention are frequently in no way inferior to the results obtained by using more complex reconstruction techniques.

In particular, concave anatomic areas such as the alar facial groove, the medial canthus or the naso-alar crease represent ideal healing sites to employ such a technique. On the contrary, wounds situated on the nasal dorsum or tip will invariably result in flattening of the convex nasal contour. Similarly, due to the high risk of wound retraction, defects

located along the alar and columellar margins represent unsuitable sites to use such a technique.

The major benefits of healing by secondary intention are its simplicity and cost effectiveness (Gosler JB, 1992). It allows for early detection of recurrent tumors that would otherwise be covered and kept hidden under a flap or graft and eliminates the need for additional surgery and further scar tissue that must be resected in case of recurrence. Consequently, excisional skin defects, resulting from tumors which possess a high likelihood of recurrence, are optimally managed by using this approach.

Despite the great number of benefits this approach might entail, there is a major disadvantage, which cannot be neglected. Skin defects, healing by secondary intention, generally require longer periods of time to fully recover, which can ultimately lead to a whole new range of other complications. Nevertheless, with proper patient selection and adequate wound care, this obstacle can be easily overcome.

4.4.5.1.3 Skin Grafts

In general, a free skin graft can be defined as a detached piece of skin, that has been severed from its local blood supply and transferred to another body part, to repair a given skin defect. They have been classically divided into three basic types namely, full thickness skin graft (FTSG), split thickness skin graft (STSG) and composite graft.

A FTSG includes the dermis with overlying epidermis and may be used in the reconstruction of small defects of the infra-tip lobule or the upper two-thirds of the nose (Johnson TM, 1992). FTSGs used in convex regions such as around the nasal tip are of limited use and generally perceived as cosmetically inferior. This can be mostly ascribed to the discrepancies in skin thickness, texture and color of the graft.

In the selection process of finding an appropriate donor site for a skin graft, that will match the recipient site accordingly, we need to take into consideration size, thickness and pigmentation of the required graft. Therefore, some of the potential donor sites for harvesting grafts that match the skin of the nose include the preauricular, postauricular, melo-labial and supraclavicular regions. Especially skin grafts from the melo-labial fold represent a superb match regarding texture and color for small defects in the region of the nasal tip and infra-tip lobule (24). Moreover, preauricular skin grafts have been proven to yield excellent results when used in the upper two thirds of the nose (Burgett GC, 1994).

Finally, postauricular and supraclaviular donor sites are in most instances regarded as a poor secondary donor sites, owing to the slight redness and thickness of the skin respectively.

STSGs have been less commonly used in nasal reconstruction mostly as a result of their tendency to lose pigment during healing and the unchecked secondary contraction of the underlying wound. Therefore, cosmetic results of this type of skin grafts are more than suboptimal and the procedure is predominantly used in elderly patients with very large skin defects and uncertain tumor margins (Johnson TM, 1992).

Grafts that contain at least two tissue types are considered composite grafts. The two types of tissue most commonly encountered in such grafts are either, skin and cartilage or skin and perichondrium (Stucker FJ, 1992). Furthermore, they are generally thicker than simple skin grafts and do not carry their own blood. As a result, they are a lot more vulnerable to ischemic injury and consequently graft failure, if not give an almost ideal recipient bed.

The preferred donor site of such grafts is the root of the helix. One of the reasons for the predilection of this area is that the secondary skin defect created at the donor site, can be easily closed with a cheek advancement flap, resulting in minimal deformity³⁴. The other type of composite graft, containing skin and perichondrium, can be taken from the retroauricular area or the cavum conchae. Given that this type of graft and simple skin grafts share similar indications, composite grafts containing skin and perichondrium, have a much higher reliability in graft survival and a much lower risk of presenting graft contraction. The only constraints known for this type of graft are the limited thickness of the graft and the limited use in cases of strict tissue matching.

The recipient sites for composite grafts are the alar rim and columella. In particular small superficial wounds show excellent results when treated with this type of graft.

An essential concept that applies universally to all skin grafts is the prerequisite for an adequate wound bed, which allows vascular growth. Consequently, avascular tissue such as exposed bone or cartilage is typically inapplicable for supporting FTSG or any of the other two types of skin graft. Furthermore, the idea of de-fatting the skin graft, in the attempt to promote new vessel ingrowth, has also been incorporated as a standard procedure in skin grafting (21). At last, hemostasis of the recipient site should be of utmost importance to the surgeon, as the slightest accumulation of blood from the recipient site can result in the loss of the graft. Moreover, the graft should be immobilized during the postoperative phase for four to five days, using quilting sutures and stent dressing.

4.4.5.2 Local and Regional Flaps

A flap in surgical terms can be defined as a mass of tissue, which is only partially removed from one site of the body so that it retains its own blood supply during transfer to another site. In addition, a flap for grafting normally includes the skin.

In general, flaps are the only reliable means in reconstruction surgery to deliver bulk tissue from one site of the body to another. As a result of having its own blood supply, flaps are considered to be completely independent of the recipient vascular bed. This can be specifically used as an advantage to cover nonvascular structures such as bare bone and cartilage (Barton FE, 1988).

4.4.5.3 Local Flaps

Local flaps are the least complex type of flaps. They are generally created by freeing a layer of tissue and subsequently stretching the freed layer to fill and cover a defect. According to the design of the flap, which includes the placement of incisions as well as the direction and angle the local flaps are pulled towards, they can be further divided into advancement flap, rotation flap and transposition flap.

Using local flaps from within the aesthetic subunits of the nose, offers a great approach to restore small skin defects on the nose. The excellent results accomplished by this method, can be largely attributed to the perfect match of donor and recipient site in terms of skin color, skin texture and thickness of the skin. Tissue reservoirs used to deliver local flaps are the dorsum of the nose as well as the lateral wall of the nose. There has been a great number of small transposition flaps employed for the reconstruction of small nasal defects. These include in particular the rhomboid flap, the note flap as well as the bilobular transposition flap. Moreover, the concept of using transposition flaps is to move excess tissue into adjacent tissue defects, mostly the upper segments or superior tip of the nose.

4.4.5.4 The Rhomboid Flap

The rhomboid or Limberg flap is an extremely versatile transposition flap that can be used to restore various types of skin defects. In particular when employed for nasal skin defects this type of flap tries to make optimal use of the of tension redistribution according to the lines of maximum extensibility. This is ususally accomplished by orienting the flap design

perpendicular to the skin tension lines (Larrabee WF, 1981). However, owing to the multiple geometrical variations in the design of a rhomboid flap, the concept of optimal usage of RSTLs is rarely implemented in reality. The exception to this is possibly the glabellar root and lateral side wall of the nose.

4.4.5.5 The Note Flap

Another transposition flap, which by many reconstructive surgeons is considered to be an elegant alternative to the rhomboid flap, is the so called note flap. Its elegance can be mostly attributed to the fact that unlike the rhomboid flap there is no sacrifice of normal tissue at the margins of a circular defect. As the name implies, the design of the flap looks like a musical eights note with the defect being the note head (Wolfswinkel, 2013 Reconstruction of Small Soft Tissue Nasal Defects). Like other types of transposition flaps, the use of note flaps is mostly indicated for skin defects in the upper two thirds of the nose. This is mostly related to the higher degree of skin laxity in the upper regions of the nose, which makes it considerably easier to close the donor site and inset of the flap. On the contrary, the skin in the lower third of the nose, around the alar wings and nasal tip is much more firmly attached to its underlying structures. As a result, using note flaps in lower parts of the nose can lead to tension wounds, which can ultimately lead to unilateral nasal deformities.

As far as the design of the note flap is concerned, the surgeon needs to first draw two tangents parallel to the RSTL. After that, four potential flaps are fashioned of which the most suitable for the skin defect is chosen.

A disadvantage, which is frequently mentioned in the context of note flaps, is the occurrence of dog-ear formation at the base of the flap. Moreover, note flaps are normally somewhat smaller than the skin defect they need to restore. Therefore, it requires a fair amount of experience from the operator's side, to correctly estimate and ensure that sufficient amounts of skin laxity are given to close the defect (Walike JW, 1985).

4.4.5.6 The Bilobular Transposition Flap

The bilobed flap is a variation of the standard single transposition flaps mentioned above (Murakami C.S, 1993). In that, it employs the use of two lobes instead of one lobe to repair the tissue defect. The specific design allows the surgeon to move looser skin from the upper parts of the nose into small defects on the lateral lower nose and adjacent tip.

More specifically, the primary lobe is used to repair the primary defect whereas the secondary lobe is formed to repair the secondary defect or donor site.

As a general rule, the angle of transposition in these flaps should not be more than 90 degrees (Zitelli J.A, 1990). When disregarded, the restored skin defect might show dog-ear formation. In addition, the defect should not exceed a diameter of 1.5 cm and the vascular pedicle is ideally based on the lateral aspect of the nose.

Since the bilobed flap employs incisions, which violate the lines of the surgical subunits of the nose, it tends to produce multiple secondary scar lines. However, with careful design, the flap may be individually fashioned to hide or minimize any possible distortion within the normal anatomic boundaries.

4.4.5.7 The V-to-Y Island Pedicle Advancement Flap

In the event certain skin defects render themselves unsuitable for the use of transposition flaps, the operator can switch to alternatives like advancement or rotational flaps. The V-to-Y advancement flap is a flap, which has commonly been used in the attempt to restore skin defects on the nasal sidewalls. Its recipient site, the cheek, has the advantage of having a high degree of skin laxity relative to the nose. Therefore, the flap can be easily advanced to fully cover the defect and not cause a tension wound.

4.4.5.8 Regional Flaps

In the case, that skin and soft tissue defects are more extensive, or if the underlying nasal support is missing and must be restored with cartilage grafts, a local flap is no longer a suitable option. These defects require the help of a regional or distant flap such as the forehead, nasolabial, or the nasal dorsal glabellar flap.

1.6.1.5.1 The Nasal Dorsal Glabellar Flap

The nasal dorsal glabellar flap is designed as a rotation flap. It generally aims to move skin from areas of relative excess as in the glabellar region, to defects situated in mid-nasal or lower-nasal areas (Dzubow L.M, 1952). Ideally, the donor site should be fairly lax and free of any hair follicles in the interbrow region.

When looking at the design of the flap, one can see that the arc of rotation is situated around the area of the medial canthus, getting its blood supply from the nasal dorsal artery. Moreover, before transferring tissue from the donor site to the defect, the surgeon

needs to make sure that the flap is larger than the primary defect as to maximize tissue mobility and to minimize wound tension at its donor site.

Harvesting donor tissue from the glabellar region, involves the elevation of the flap in the supra-perichondreal plane as one of the initial steps. Furthermore, additional dissection of tissue from the glabellar region is important as to equalize thickness of the donor site (glabella) to the respective recipient site (medial canthus). The secondary defect created in this surgery is ultimately closed by a either cheek advancement or interbrow approximation.

All in all this type of regional flap shows great results in terms of tissue matching and as a one stage, procedure lowers the risk of complication of further surgeries.

4.4.5.9 The Nasolabial Flap

The non-hair bearing area lateral to the nasolabial fold usually provides the basis of nasolabial flaps. They rely on the supply of random terminal branches of the facial artery and normally come into use when small defects of less than 2.5cm on the lower parts of the nose need to be restored. These defects may include defects on the nasal ala, tip or lateral sidewalls of the nose.

Generally, the flap can either be designed as a one-stage procedure or as a two staged procedure. For the one staged procedure, the operator insets the flap directly into the defect after excising the tissue bridge adjacent to the defect. In contrary, the second stage procedure maintains the tissue bridge and releases the flap after three weeks in a second stage procedure.

4.4.5.10 The Forehead Flap

Forehead flaps are being viewed as the type of flap used in the case of larger, more complex nasal defects that cannot be repaired using the above-mentioned methods. Therefore, nasal defects larger than 2.5 cm in length along transverse and horizontal plane are best closed using a forehead flap. Further indications include nasal defects with exposed bone or cartilage and cases involving a lack of periosteum and perichondrium.

The vertically oriented paramedian or median forehead flaps are supplied by the supratrochlear artery. Using Doppler ultrasound to localize the exact course of the artery, allows harvesting of a flap that has a relatively narrow pedicle of less than 2 cm. As a result, this method allows for pivot rotation providing more effective flap length and prevents donor site deformity in the glabellar region. The pedicle is divided at three weeks along with proper debulking and contouring at the recipient site.

Owing to its excellent blood supply, forehead flaps are generally considered to be very reliable. Besides its reliability, it allows thinning in its distal portion which in turn enhances pliability as well as final contouring with the incorporation of cartilage grafts to restore the nasal skeleton.

5 Research Goal

The goal of this thesis paper was to analyse the data of patients that have undergone septoplasty or septo-rhinoplasty in the period of January 1st, 2012 to December 31, 2015 at the department of ENT H&N Surgery, Sisters of Mercy University medical centre of Zagreb. The subjects were men and women from 18 to 73 years of age and children from 8 to 18 years of age.

6 Results

The total numbers of patients that have undergone septoplasty or septo-rhinoplasty in the period of 2012 to 2015, are presented below:

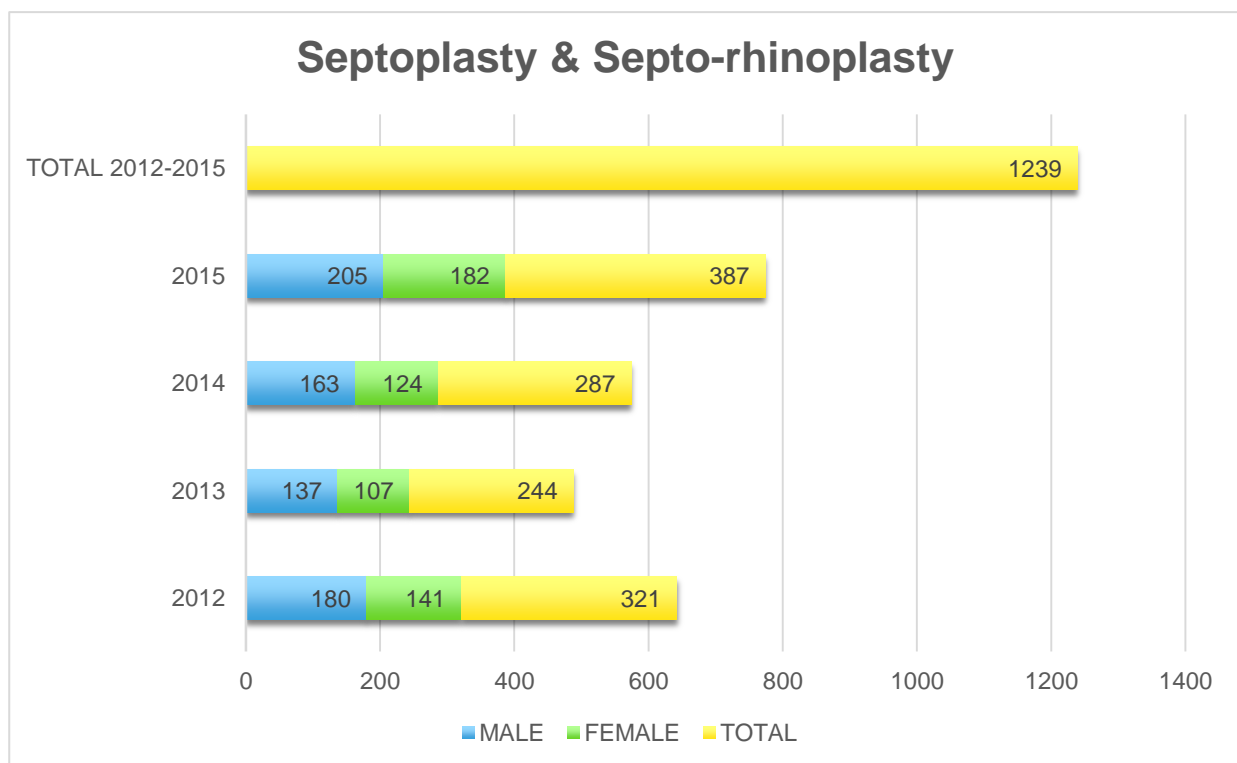


Figure 1: Total number of septoplasties and septo-rhinoplasties performed at the department of ENT H&N Surgery Sisters of Mercy University medical centre of Zagreb between 2012 and 2015.

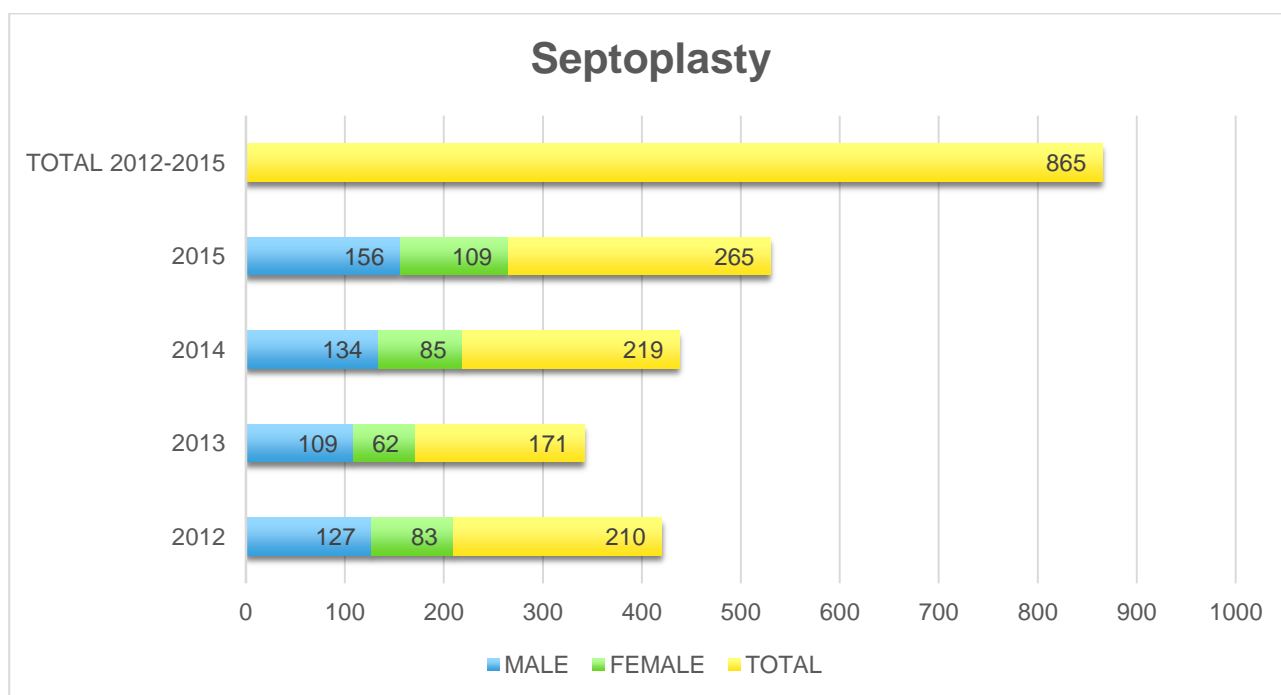


Figure 2: Total number of septoplasties performed at the department of ENT H&N Surgery Sisters of Mercy University medical centre of Zagreb between 2012 and 2015.

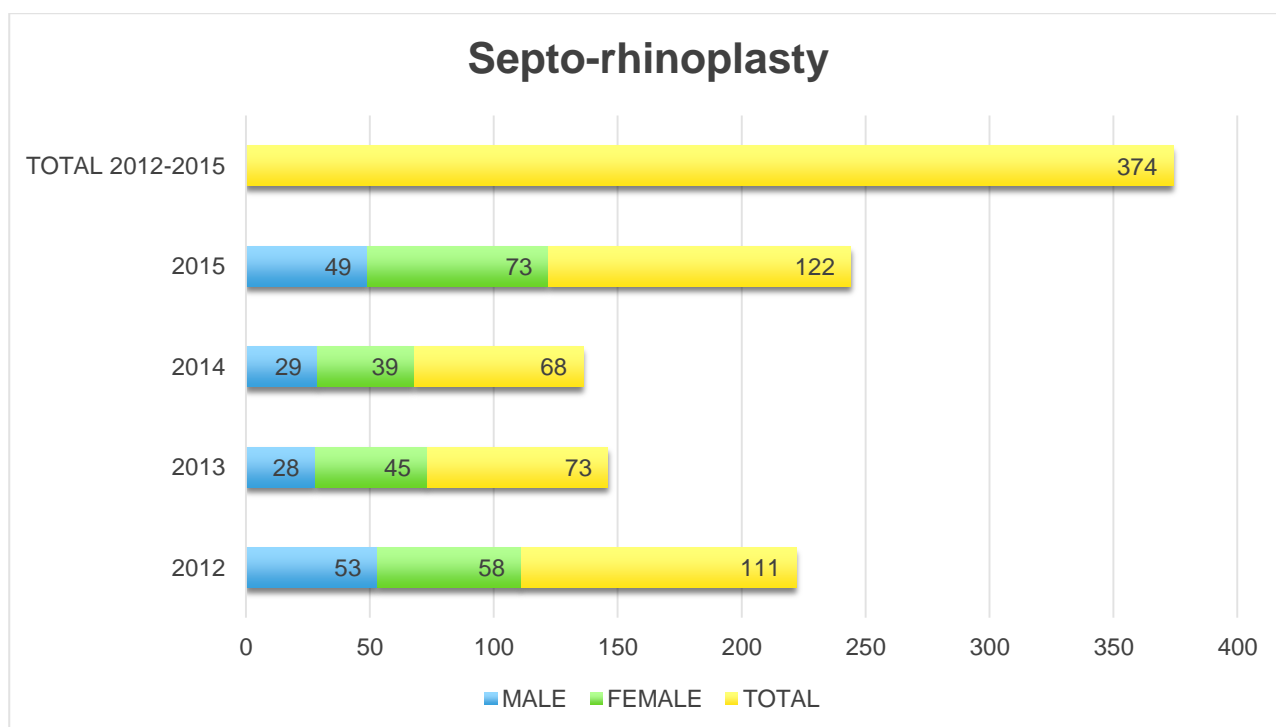


Figure 3: Total number of septo -rhinoplasties performed at the department of ENT H&N Surgery Sisters of Mercy University medical centre of Zagreb between 2012 and 2015.

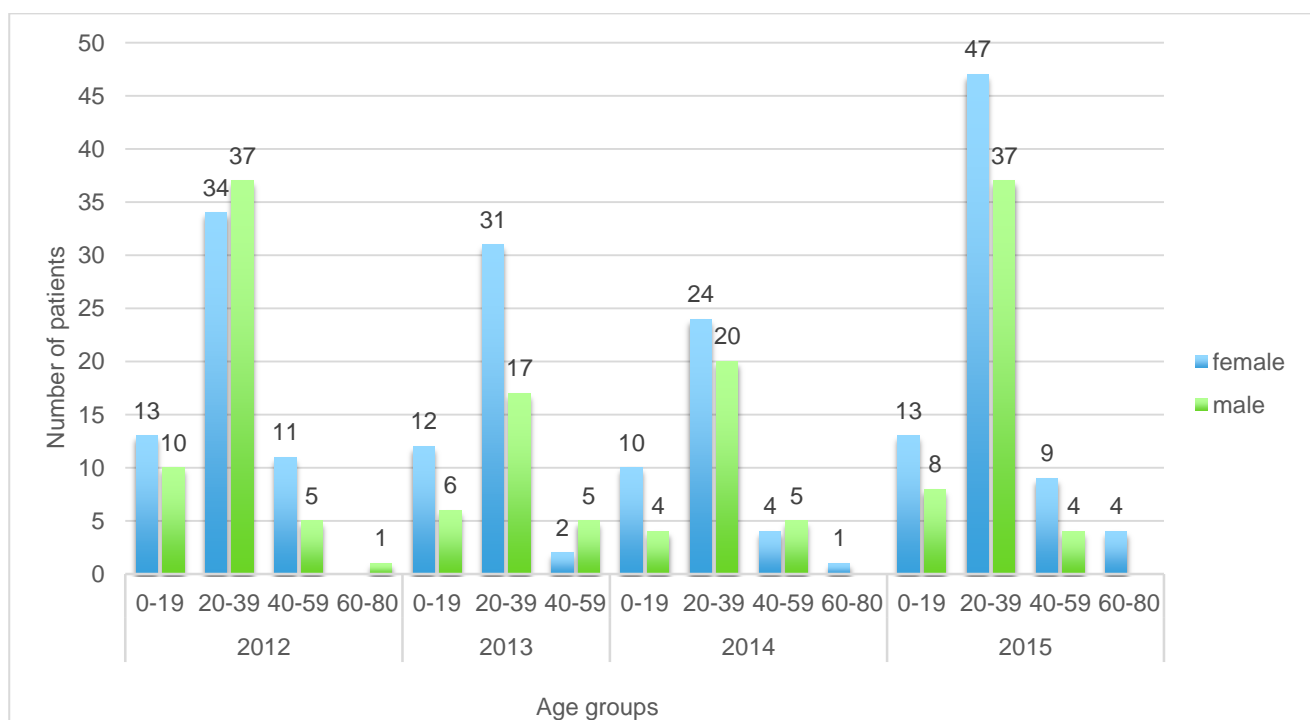


Figure 4: Number of rhino-septoplasties performed at the department of ENT H&N Surgery Sisters of Mercy University medical centre of Zagreb between 2012 and 2015, stratified by age groups.

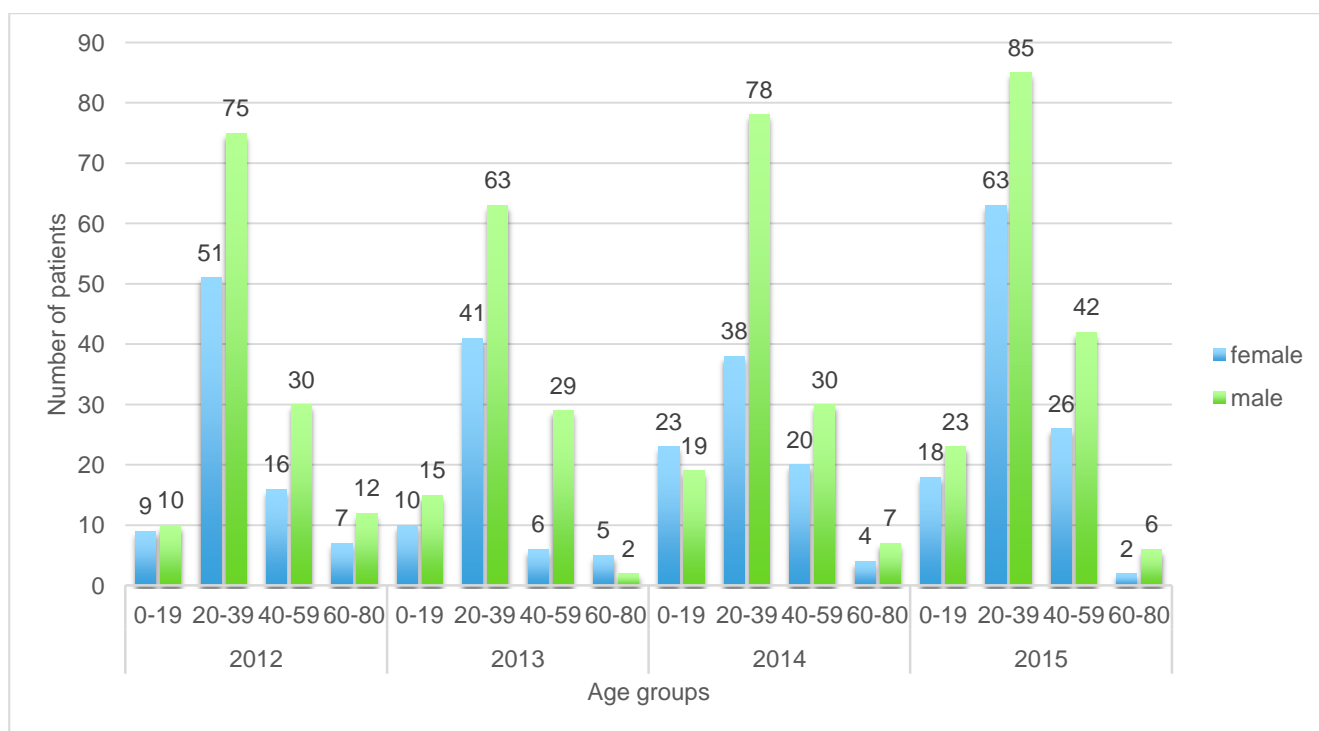


Figure 5: Number of septoplasties performed at the department of ENT H&N Surgery Sisters of Mercy University medical centre of Zagreb between 2012 and 2015, stratified by age groups.

7 Discussion

The two examples of reconstructive nose surgery examined in this study are septoplasties and septo-rhinoplasties. These procedures are generally considered some of the most frequently performed operations in the field of reconstructive nose surgery. The indications for septoplasty are patients with a deviated nasal septum, presenting with difficulties in breathing, recurrent epistaxis or chronic sinusitis. Besides the correction and reconstruction of the nasal septum as done in the case of a simple septoplasty, a septo-rhinoplasty additionally attempts to restore functional impairment or aesthetical misalignment of the external pyramid of the nose.

After the surgical management of a deviated septum, the majority of patients experiences a measurable improvement of their symptoms with rates ranging from 47% to 98% (Carolina Sundh, 2014).

The total number of patients that have undergone septoplasty or septo-rhinoplasty, in the four-year period of 2012 to 2015, amounts to 1239 patients. Out of these 1239 patients, 554 were of female sex and 685 of male sex (as seen in figure 1).

When comparing the total numbers of the given procedures separately, we can conclude that the number of septoplasties performed in this four-year period is more than twice as high as the number of septo-rhinoplasties. This discrepancy in numbers is mostly related to the lower prevalence of anatomical misalignment of the external pyramid in the presence of a deviated septum.

Looking at the entire time span from 2012 to 2015, there is no conclusive trend that would point to an overall increase or decrease in the two procedures. Following a slight reduction

in the number of septoplasties and septo-rhinoplasties performed between the years of 2012 to 2013, we can detect an incremental increase in the course of the next three years exceeding the initial value of 2012.

When considering the distribution of sex in the two examined procedures, we can observe a larger number of septoplasties performed in male than in female subjects. Since the incidence of septal deviation is generally higher in men, it would justify the unequal sex distribution found in the given data. On the contrary, the number of septo-rhinoplasties performed in the four-year period is higher for women than for men. This may be attributed to a potentially larger number of women seeking cosmetic enhancement of the nose in addition to correction of their deviated septum.

Regarding age distribution at the time of the operation, it is evident that the age group with the highest number of operations performed, lies between the ages of 20 - 39 for both septoplasties and septo-rhinoplasties (as seen in Fig.4 & Fig.5). A deflected nasal septum may often go unnoticed in childhood and thus the effects may not be apparent before adolescent hood or later in life. With age, loss of tensile strength in collagen may lead to collapse of the nasal valve area, uncovering preexisting nasal asymmetry. This may explain the variations in age groups seen with both procedures in this study.

8 Conclusion

Reconstructive nose surgery remains one of the most challenging and at the same time intriguing areas in the field of surgery. A wide range of techniques must be in the surgeon's armamentarium to master the various deformities and defects one is confronted with in this field of medicine. Regardless of what type of reconstructive nose surgery needs to be performed, the first task of the operator lies in the careful evaluation of the patient. This involves objective gathering of the patient's functional needs as well as their expectations, both in the long-term and short-term. Following this, a thorough preoperative planning is carried out, which precedes a close postoperative follow-up for potential complications. Obeying these basic principles in conjunction with excellent surgical technique will result in functionally and aesthetically pleasing results for the patient in need of nasal reconstruction.

9 Acknowledgement

I am thankful to my mentor, Prof. Dr.sc Tomislav Baudoin for his assistance knowledge and patience. Thank you to the department of ENT H&N Surgery Sisters of Mercy University medical centre of Zagreb and to the University of Zagreb, School of Medicine.

10 References

- Anand K. Devaiah Bounmany Kyle Keojampa. Surgery of the septum in: Rhinology and Facial Plastic Surgery, Springer 2009 pp 181-185
- Anderson JR. A new approach to rhinoplasty. Trans Am Acad Ophthalmol Otolaryngol 1966;70(2):183–192
- Ballenger JJ. Symposium: the nose versus the environment. Laryngo-scope 1983;93(1):56–57.
- Barton FE: Aesthetic aspects of nasal reconstruction. Clin Plast Surg 15(1):155-166, 1988
- Behrbohm H, Tardy ME. Essentials of septorhinoplasty: philosophy, approaches, techniques. New York: Georg Thieme; 2004
- Burgett G.C., Menick F.J. (1994) Aesthetic reconstruction of the nose. Mosby, St.
- Burgett GC, Menick FJ: The subunit principle for nasal reconstruction. Plast Reconstr Surg 76:239-247, 1985
- Cottle MH, Loring RM. Newer concepts of septum surgery: present status. Eye Ear Nose Throat Monthly 1948; 27:403
- Courtiss EH, Gargan TJ, Courtiss GB. Nasal physiology. Ann Plast Surg 1984;11:214 223
- D.L. Swift, Physical principles of airflow and transport influencing air modification, in: D.F. Proctor, I. Anderson (Eds.), The Nose: Upper Airway Physiology and the Atmospheric Environment, Elsevier, Amsterdam, 1982
- Daniel RK. The Nasal Tip. In: Daniel RK editor. Aesthetic Plastic Surgery Rhinoplasty.

Boston: Little, Brown and Company, 1993. p. 215-281

Dzubow L.M. Nasal dorsal flaps. (1995) Chapter 14, pp. 225-246. In: Local flaps in facial reconstruction

edition Head and Neck Surgery: Otolaryngology. Lippincott 2001;293–308

Fjermedal O, Saunte C, Pedersen S. Septoplasty and / or Submucous Resection? 5 Years Nasal Septum Operation. J Laryngol Otol. 1988;102:796–798

Flint I.D., Siegle R.J. (1994) The bipedicled flap revisited. J. Dermatol. Surg. Oncol 20, 394-400.

Gosler J.B., Pollack S.V . (1992) Healing by secondary intention. Chapter 9, 67-71. In: Cutaneous Facial Surgery. Eds. J.R. Reagan Thomas and J. Roller, Thieme Medical Publishers.

Gosler JB, Pollack SV: Healing by secondary intention. In: Thomas RJ, Roller J (eds) Cutaneous Facial Surgery. Stuttgart: Thieme Med Publ 1992

Griesman BL. Muscles and cartilage of the nose from the standpoint of typical rhinoplasty. Arch Otolaryngol Head Neck Surg 1944;39:334

Griesman BL. The tip of the nose. Arch Otolaryngol Head Neck Surg 1952;31(10):551–553

Hinderer KH: History of septoplasty. Fundamentals of anatomy and surgery of the nose, Birmingham, Alabama: Aesculapius Publishing Co.; 1971:1

Jafek BJ, Dodson BT. Nasal Obstruction In: Bailey BJ et al. 3rd

Johnson TM, Radner D, Nelson BR: Soft tissue reconstruction with skin grafting. J Am Acad Dermatol 27(2):151-162, 1992

Kasperbauer JL, Kern EB. Nasal valve physiology. Implications in nasal surgery. Otolaryngol Clin North Am 1987;20(4):699e719

Larrabee WF Jr. Open rhinoplasty and the upper third of the nose. *Facial Plast Surg Clin North Am* 1993;1:23–38

Larrabee WF, Trachy R, Sutton D: Rhomboid flap dynamics. *Arch Otolaryngol* 107:755–757, 1981

Lawson W, Kessler S, Biller JF. Unusual and Fatal Complications of Rhinoplasty. *Arch Otolaryngol*. 1983; 109:164–169

Letourneau A, Daniel RK: Superficial musculoaponeurotic system of the nose. *Plast Reconstr Surg* 82:48-57, 1988

Menick FJ. Nasal reconstruction. *Plast Reconstr Surg*. 2010 Apr. 125 (4):138e-150e

Murakami C.S., Odland P.D. (1993) Bilobed flap variations. *Operative Techniques in Otolaryngology/Head & Neck Surg*. 4, 76-79.

Nolst Trenité G.J. Anatomy. In: Nolst Trenité G.J., Ed, *Rhinoplasty*. Kugler Publications The Hague, The Netherlands, 1998. Chapter 1

Oneal RM, Beil RJ. Surgical anatomy of the nose, *Clin Plast Surg* 2010;37(2):191e211

Pirsig W, Schäfer J. The Importance of Antibiotic Treatment in Functional and Aesthetic Rhinosurgery. *Rhinology*. 1998; 4(Suppl):3–11

Planas J. The twisted nose. *Clin Plast Surg* 1977; 4:55

Quatela VC, Slupchynskyj OS. Surgery of the nasal tip. *Facial Plast Surg* 1997; 13(4):253–68

Rogers BO. The historical evolution of plastic and reconstructive surgery. Wood-Smith D, Porowski O, eds. *Nursing Care of the Plastic Surgery Patient*. 1967.

Sinno HH, Markarian MK, Ibrahim AM, Lin SJ. The ideal nasolabial angle in rhinoplasty: a preference analysis of the general population. *Plast Reconstr Surg*. 2014 Aug. 134 (2):201-10

Skoog T. A method of hump reduction in rhinoplasty. *Arch Otolaryngol* 1966; 83: 283

Sooknundun M, Kacker SK, Bhatia R, Deka RC: Nasal septal deviation: effective intervention and long term follow-up. *Int J Pediatr Otorhinolaryngol*. 1986, 12 (1): 65-72

Stephen S. Park, Nasal Reconstruction in the 21st Century-A Contemporary Review, *Clin Exp Otorhinolaryngol*. 2008 Mar; 1(1): 1–9

Stucker F.J., Shaw G.A. (1992) Perichondrial cutaneous graft, a twelve year clinical experience. *Arch. Otolaryngol. Head & Neck Surg*. 18, 287-292.

Tardy ME, Kron TK, Younger R, et al. The cartilaginous pollybeak: etiology, prevention and treatment. *Facial Plast Surg* 1989; 6: 2

Tardy ME, Toriumi DM, Hecht DA. Philosophy and Principles of Rhinoplasty. In: Papel ID et al, editors. *Facial Plastic and Reconstructive Surgery*. New York: Thieme Medical Publishers, Inc; 2002. p. 369-389.

Walike JW, Larrabee WF: The nose flap. *Arch Otolaryngol* 111:430-433, 1985

Walsh WE, Kern RC. Sinonasal anatomy, function, and evaluation. In: Bailey BJ, Johnson JT, Newlands SD, editors. *Head and neck surgery otolaryngology*. Philadelphia: Lippincott Williams & Wilkins; 2006. p. 307-318

Watts S, Vuyk HD, Kirkland P: Nasal reconstruction. In: Vuyk HD, Lohuis PJFM (eds) *Facial Plastic Reconstructive Surgery*. London: Hodder 2005

Wax MK, Ramadan HH, Ortiz O et al. Contemporary management of cerebrospinal fluid rhinorrhea. *Otolaryngol Head Neck Surg* 1997; 116(4):442–9

Zitelli JA: Secondary intention healing: an alternative to surgical repair. Clin Dermatol 2:92-106, 1984

Zitelli JA: The bilobed flap for nasal reconstruction. Arch Dermatol 125:957-559, 1990