

Variations in skin temperature between various peripheral nerve innervation areas in peripheral compression neuropathy of median nerve

Preveden, Boško

Master's thesis / Diplomski rad

2016

Degree Grantor / Ustanova koja je dodijelila akademski / stručni stupanj: **University of Zagreb, School of Medicine / Sveučilište u Zagrebu, Medicinski fakultet**

Permanent link / Trajna poveznica: <https://um.nsk.hr/um:nbn:hr:105:800911>

Rights / Prava: [In copyright](#) / [Zaštićeno autorskim pravom.](#)

Download date / Datum preuzimanja: **2024-04-25**



Repository / Repozitorij:

[Dr Med - University of Zagreb School of Medicine Digital Repository](#)



**UNIVERSITY OF ZAGREB
SCHOOL OF MEDICINE**

Boško Preveden

**Variations in skin temperature between
various peripheral nerve innervation areas
in peripheral compression neuropathy of
median nerve**

GRADUATE THESIS



Zagreb, 2016

UNIVERSITY OF ZAGREB

SCHOOL OF MEDICINE

Boško Preveden

**Variations in skin temperature between
various peripheral nerve innervation areas
in peripheral compression neuropathy of
median nerve**

GRADUATE THESIS



Zagreb, 2016

This graduation paper was realized at the Division for Plastic, reconstructive and breast surgery; Department of Surgery, Clinical Hospital "Rebro", School of Medicine, University of Zagreb, under the supervision of Krešimir Bulić, MD, PhD, and it was submitted for evaluation in the academic year of 2015/2016.

Mentor of the graduate thesis; Krešimir Bulić, MD, PhD

ABBREVIATIONS:

- CTS: Carpal Tunnel Syndrome
- C5: Cervical vertebrae 5
- C6: Cervical vertebrae 6
- C7: Cervical vertebrae 7
- C8: Cervical vertebrae 8
- T1: Thoracic vertebrae 1
- FCU: Flexor carpi ulnaris muscle
- FDP: Flexor digitorum profundus muscle
- FCR: Flexor carpi radialis muscle
- FDS: Flexor digitorum superficialis muscle
- EMG: Electromyography
- US: Ultrasound
- CT: Computed Tomography
- MRI: Magnetic Resonance Imaging

Table of Contents

1. SUMMARY.....	6
2.PREFACE	7
2.1. History	7
2.2. Anatomy.....	8
2.2.1. Median nerve	8
2.2.2. Radial nerve.....	9
2.2.3. Ulnar nerve	10
2.2.4. Carpal tunnel.....	11
2.3. Etiology	12
2.4. Pathophysiology	14
2.5. Clinical Presentation	15
2.6.Clinical Diagnosis	15
2.7. Treatment	18
2.8. Temperature regulation in human body	20
2.9. Changes in skin temperature regulation of peripheral nerves when blocked by local anesthetic.....	22
3. HYPOTHESIS.....	22
4. OBJECTIVES	22
5.MATERIAL AND METHODS.....	23
6.RESULTS	26
7.DISCUSSION	32
8.CONCLUSION	33
9.ACKNOWLEDGEMENTS	34
10.REFERENCES:.....	35
11.BIOGRAPHY	37

1. SUMMARY

Title: Variations in skin temperature between various peripheral nerve innervation areas in peripheral compression neuropathy of median nerve

Key words: CTS, median nerve, radial nerve, ulnar nerve

Author: Boško Preveden

Skin temperatures in the hand innervation areas of median, ulnar and radial nerves were measured and assessed in patients affected by Carpal tunnel syndrome, preoperatively. For measurement Laser thermometer was used for skin temperature measurements on parts of hand innervated by median, radial and ulnar nerve, three times for each nerve respectively.

Out of 15 patients, 13 were females and 2 males, with youngest patient being 37 years old and oldest 71 years old. Average age of patients was 49 years of age.

Results showed that there are no statistically significant changes when comparing temperatures of median, ulnar and radial nerve innervated skin on the hand of patients affected by CTS patients preoperatively.

2. PREFACE

Carpal tunnel syndrome is entrapment of the median nerve as it travels through the carpal tunnel. The condition is currently the most common hand problem, with as much as 5% of the adult population being affected. CTS surgery is at the moment the most common performed hand surgery.

In majority of the cases the condition is idiopathic. Surgical treatment often results in improvement yet residual loss of function and some persistence of symptoms are common. (1)

2.1. History

Although known under variety of different names in history, the first time CTS was definitely described was only after World War 2. Looking in the past, however this disease was described with its typical symptoms in surgical literature from mid 1800s.

Three major entities needed to unite to establish our current understanding of CTS (1). First of them, the median neuropathy after wrist fracture, was described for the first time by Gensoul (2). He described a case of median nerve entrapment after open fracture of the radius. The second major thread, speaking historically was acroparesthesias (1). In 1862 Raynaud wrote that there was vasomotor origin of paresthesia (3), but the symptoms he described and those were “a depressing sense of numbness and tingling...the tactile sense may be impaired so much that it is difficult for the fingers to retain small objects”. Hunt (4) ascribed thenar neuritis, the third thread, to occupational activities.

In 1873 Poore described clinical entity, which by symptoms resembled CTS and named it writer’s cramp (5). For many years it was believed, that first flexor retinaculum release was performed by James R. Learmouth for diagnosis of median neuropathy. A case found in Mayo Clinic medical records suggests that Herbert

Galloway, a Canadian orthopedic surgeon, released flexor retinaculum to explore median nerve at the wrist for a post crush median neuropathy in 1924 (6). No earlier cases have been identified (1).

2.2. Anatomy

2.2.1. Median nerve

2.2.1.1. Origin

Median nerve originates from lateral root, which is a terminal branch of lateral cord (C6, C7) and medial root, which is a terminal branch of medial cord (C8, T1). (7)

2.2.1.2. Course

When lateral and medial roots merge laterally to axillary artery median nerve is formed. The median nerve will descend through arm adjacent to brachial artery, gradually crossing anterior to artery to lie medial to artery in cubital fossa. It will exit cubital fossa by passing between heads of pronator teres. Then it descends in fascial plane between flexors digitorum superficialis and the profundus. It will run deep to the palmaris longus tendon as it approaches flexor retinaculum to traverse carpal tunnel to reach hand. Median nerve has no branches in the axilla or arm, but it does supply articular branches of elbow joint. In the forearm major branch is anterior interosseous nerve. It will also give few unnamed branches in the forearm: articular branches, muscular branches, anterior interosseous nerve and palmar cutaneous branch of the median nerve. Palmar cutaneous branch of the median nerve, which arises proximally to carpal tunnel will not traverse carpal tunnel as it runs superficially to flexor retinaculum. (7)

2.2.1.3. Innervation

Median nerve as the principal nerve of anterior compartment of forearm supplies muscular branches directly to the muscles of the superficial and intermediate layers of forearm flexors (except FCU), and deep muscles ((except for the medial (ulnar) half of the FDP) via its branch, the anterior interosseous nerve which also supplies pronator quadratus. The nerve to the pronator teres innervates FCR, the palmaris longus and the FDS. Distal to the carpal tunnel it supplies two and half thenar muscles and 1st and 2nd lumbricals. It also sends sensory fibers to innervate skin of the entire palmar surface, sides of the first three digits, the lateral half of the 4th digit, and the dorsum of the distal halves of these digits. (7)

2.2.2. Radial nerve

2.2.2.1. Origin

Radial nerve originates from larger terminal branch of posterior cord, which per se is the largest branch of brachial plexus. At its origin, the radial nerve receives fibers from C5- T1. (7)

2.2.2.2. Course

Radial nerve exits axillary fossa posterior to axillary artery and passes posterior to humerus in radial groove with deep brachial artery between lateral and medial heads of triceps. Within the radial groove, the branch of the radial nerve arises to the lateral head of the triceps. On it's way it will perforate lateral intermuscular septum, and then it enters cubital fossa and divides into superficial (cutaneous) and deep (motor) radial nerves. Posterior cutaneous nerve of the forearm arises from the radial nerve in the posterior compartment of the arm, on its way to the radial groove of the humerus. The superficial branch of radial nerve branches after it emerges from the overlying brachioradialis and crosses the roof of the anatomical snuff box. The deep branch of radial nerve, after piercing supinator runs in fascial plane between superficial and deep extensor muscles in close proximity to the posterior interosseous artery. (7)

2.2.2.3. Innervation

The radial nerve will innervate all muscles of posterior compartment of arm as well as of forearm. It will also innervate the skin of posterior and inferolateral arm, posterior forearm, and dorsum of hand lateral to axial line of digit 4. The deep branch of the radial nerve will supply all forearm muscles in the posterior compartment. The posterior cutaneous nerve of the forearm will supply posterior aspect of the skin. The superficial branch of the radial nerve is distributed to the skin on the dorsum of the hand and to a number of joints in the hand. (7)

2.2.3. Ulnar nerve

2.2.3.1. Origin

The ulnar nerve originates from the larger terminal branch of medial cord, receiving fibers from C8, T1 and often C7. (7)

2.2.3.2. Course

The ulnar nerve of the arm passes distally from the axilla, anterior to the teres major insertion and to the long head of the triceps, on the medial side of the brachial artery. Somewhere in the middle of the arm it will pierce medial intermuscular septum. Ulnar nerve will then pass posteriorly to the medial epicondyle of humerus. After that ulnar nerve descends ulnar aspect of the forearm to hand. The ulnar nerve will enter the hand by passing through the groove between the pisiform and the hook of the hamate. A band of fibrous tissue from the flexor retinaculum bridges the groove to form the small ulnar canal also known as Guyon canal. Like the median nerve, the ulnar nerve has no branches in the arm but it does supply articular branches of the elbow joint. (7)

2.2.3.3. Innervation

In the forearm ulnar nerve supplies FCU (as it enters the forearm by passing between its two heads of proximal attachment) and the ulnar part of the FDP, which sends tendons to the 4th and 5th digits. In the forearm it will give following branches: articular branches which will pass to the elbow joint, muscular branches that supply FCU and the medial half of FDP, and the palmar and dorsal cutaneous branches which sensory fibers are distributed to the skin of the hand. In the hand the palmar cutaneous branch will supply skin on the medial side of the hand, dorsal cutaneous branch of the ulnar nerve will supply the medial half of the dorsum of the hand, the 5th finger, and the medial half of the 4th finger. The ulnar nerve will at the distal end of the flexor retinaculum divide into the superficial and deep branches. The superficial branch of the ulnar nerve will supply cutaneous branches of the anterior surfaces of the medial one and a half digits. The deep branch of the ulnar nerve supplies the hypothenar muscles, the medial two lumbricals, the adductor pollicis, the deep head of the FPB, and all the interossei. The deep branch also supplies several joints in the hand. (7)

2.2.4. Carpal tunnel

The carpal tunnel is an osteofibrous canal and is located in the volar wrist. It is bounded by the carpal bones, which form the floor and the flexor retinaculum also known as transverse carpal ligament, which will form the roof. The retinaculum itself is 3-4 cm wide and inserts into the scaphoid tuberosity and into the pisiform (proximal carpal tunnel), subsequently it inserts into the trapezium and the hook of the hamate (distal carpal tunnel). On its radial side it divides into the superficial and a deep layer to accommodate the tendon of the flexor carpi radialis. (8)

The tunnel itself contains nine tendons and a nerve: the four flexor digitorum superficialis, the flexor pollicis longus, the four flexor digitorum profundus and a median nerve. (8)

2.3. Etiology

CTS comprises around 90% of nerve compression syndromes. Prevalently it develops in patients between 40 to 50 years of age, with female to male ratio of 3:1. Only 10% of CTS cases affect people younger than 30 years. Highest risk of CTS is among Caucasians. (11)

Primary cause of CTS is compression of the median nerve inside the carpal tunnel. This compression is linked to an increase in internal carpal canal pressure. Anatomically looking each canal has a fixed capacity. Consequently each condition that will provoke expansion of the inside of canal will cause increase in internal pressure of carpal canal leading to compression of the median nerve.

Any anomalous content will decrease available canal space. These anomalous contents include edema, hemorrhage deposits of pathologic substances such as calcium uric and /or conditions of amyloidosis, etc. There will be proportionally greater increase in intra canal pressure in canals that are smaller due to a congenital condition or various abnormal developments.

In the presence of a preexisting pathology, such as polyneuropathy or compression of median nerve more proximally, possibility of compressive median nerve damage is increased.

The majority of carpal tunnel syndrome cases are idiopathic meaning the cause is unknown. The most common systemic predisposing conditions include diabetes mellitus, rheumatoid arthritis and hypothyroidism. It is known that CTS can also appear during pregnancy or from hormonal alteration pathologies. Other collagen diseases and acromegaly are rarely the cause for CTS onset.

Sometimes CTS can be secondary to trauma to wrist or fracture. When this is the cause, CTS will have sudden onset.

CTS can be found as an isolated condition or linked with other disease such as De Quervain syndrome, Raynaud phenomenon, epicondylitis or shoulder pathologies. (1)

Table 2.3.1 Causes of Carpal tunnel syndrome:

CTS Causes:
Idiopathic
Secondary: <ul style="list-style-type: none"> -Aspecific Tenovaginitis of the flexor tendons -Rheumatoid Arthritis and Other Collagen disease (for example: Sjogren syndrome, lupus, dermatomyositis scleroderma) -Familiar neuropathy -Polyneuropathy -Rheumatic Polymyalgia -Vascular disease -Gout -Endocrine disease (Diabetes mellitus, hypo/hyperthyroidism, acromegaly) -Vitamin deficiency (lack of or excessive intake of vitamin B6) -Pregnancy and breastfeeding -Infections -Tumors -Obesity -Congenital diseases (mucopolysaccharidoses) -Children forms -Acute (fractures, blunt trauma, infections, burns) -Others

2.4. Pathophysiology

Pathophysiology of CTS is not fully understood but traumatic mechanisms such as friction, traction and repetitive compression can all lead to chronic nerve compression. (1,12)

Nerves by themselves are static structures, but when articulation or limb moves, nerve follows by adapting in a way to glide few millimeters along its course. (9)

From the vertebral column to the most distal part of the limb, nerves pass through narrow anatomical canals. Canals themselves do not represent fixed point so nerves must glide inside them. Nerves have their fixed point, where they emerge from the vertebral foramen and surrounding collateral areas with respective final terminations, which are muscular, sensitive branches etc.

The presence of even minor amounts of tissue edema can interfere with passive nerve movements. As limb moves, the nerve which is not very mobile will be stretched, leading to further damage such as edema, irritation and/ or micro injuries which will cause consequential scar adhesion formation. If a scar tissue is formed, the localized pressure will be increased thus leading to permanent nerve compression also known as nerve entrapment. (1)

From the anatomical standpoint of view, non-physiologic movements, repetitive muscle contractions, decrease or increase of the structure volume contained within the canal, can lead to nerve compression within osteofibrotic canals such as carpal tunnel, cubital tunnel or intervertebral foramina.

2.5. Clinical Presentation

Symptoms of carpal tunnel syndrome are numbness, tingling and burning pain, which is present in volar aspect of one or both hands, noted especially after work or at night.

Nocturnal symptoms also called nocturnal acroparesthesia will occur in 50 to 70 % of patients, being the most common subjective symptom. Patients will wake up during the night or early morning to shake their hands, changing the position of arms or letting the arm hang down and by that way resolving the symptoms. (10)

Paresthesia may occur also during the day, when being involved in particular activities such as driving, holding the phone when talking, or holding the book during reading.

When asked to describe the location of paresthesia, patient at first may not remember the exact finger. They may describe paresthesia, which involves whole hand, or whole palmar surface etc...(1)

Patients should be asked to remember more clearly if possible and be encouraged to perform movements which lead to paresthesia, and then the area involved will be the one innervated by the median nerve. That area involves three radial fingers and radial side of fourth finger. (7)

2.6.Clinical Diagnosis

Clinical diagnosis of CTS is based primarily on comprehensive history taking and patient's clinical presentation. Diagnosis itself should be based on three important CTS symptoms: hand muscle atrophy, disturbances in motility and sensibility. (13)

It is important to collect data about the hand dominance, previous operations, previous or concurrent medical illness (diabetes, amyloidosis, polyneuropathy, gout,

blunt trauma, fractures...), social and economical status, hobbies, drugs abuse, exact description of symptoms, work environment and type of work patient performs. When taking history in female patients it is also important to ask about their reproductive history.

Clinical exam should include evaluation of ABP motor strength, hand grip strength, lateral and key pinch strength.

When patients anamnesis and exam suggests possibility of CTS, usually two provocative tests are used, Tinel's and Phalen's tests.

Tinel's test by itself is not sufficient for diagnosis establishment, being valid in between of 58% to 67% patients who also had positive electromyographic tests. In 20% of cases Tinel test is positive in absence of disease. (1)

Phalen test is positive in between 66 to 88 % of patients, although it may show false positive in about 20% of patients. (1)

It is diagnostically important when both tests show positive signs, as this identifies up to 90% of CTS patients. (14)

As Phalen's and Tinel's tests can not provide 100% diagnostic accuracy, other tests were described. One of them is Durkan or compression of the median nerve test, which has up to 100% positivity by Williams (15).

Tests that evaluate sensitivity are divided in two groups. First one is innervation density test group and best known here is Weber -two point discrimination test, which is generally normal in mild to moderate CTS causes. In the second group, which comprises threshold tests, the most widely used test is Van Frey's pressure test with Semmes-Weinstein monofilaments.

Table 2.6.1. Tests for diagnosis of CTS

TEST	ELICITATION	Positive response
Tinel	Examiner should tap over the median nerve as it passes through the carpal tunnel in the wrist	The response to the test should be a sensation tingling following median nerve distribution over the hand
Phalen	Examiner should allow wrist to fall freely, being in maximal flexion, and this position should be maintained for 60 seconds or more	The response to the test should be a sensation tingling following median nerve distribution over the hand
Durkan	Examiner should apply pressure with his thumb at the level of carpal tunnel for 30 seconds	The response should be paresthesia in the territory of the median nerve.
Weber	Examiner should apply force with two sharp points	Patients can truly distinct that force was applied over two distinct points
Van Frey	Examiner applies monofilaments with different thickness perpendicular to finger tips	When patient can correctly identify the stimulated finger

It is also recommend to use hand diagrams in diagnosis where both sides of the hand are represented on the paper and patient can draw exactly where they felt paresthesias and loss of sensations. It can be of much help in establishing diagnosis if drawing represents involvement of classic median nerve hand innervation.

Electro-diagnostic exams can be of help They can not be used to make diagnosis in the absence of history that includes characteristic CTS criteria and excludes other causes. Among them the most specific, objective and sensitive exam as one of the tools for CTS diagnosis is Electromyography. EMG exam involves assessment of motor and sensory fibers. It can measure the speed of nerve conduction

via motor fibers, changes of action potential amplitudes and sensory conduction latency. Depending on the technique used for EMG, sensitivity is from 70 to 92% whereas specificity from 95 to 97%. The outcome of EMG exam is used as one of criteria when deciding for surgical treatment. (1)(16)

It has been shown when there is discordance between clinical and EMG finding, MRI can be useful to identify patients who can benefit from surgery. (17)

Nowadays EMG should be used as a first choice diagnostic tool, as there are no studies that support imaging studies as a better option. When diagnostically challenging case is presented, EMG can be combined with ultrasound. For pathologies related to bone structures computed tomography can be used, whereas for soft-tissue related injuries MRI can be used. (18)

2.7. Treatment

Treatment of CTS can be conservative or surgical. (1)

Table 1.7.1. CTS treatment

CTS TREATMENT	
Conservative	Short-term immobilization of the hand in non-strained position as well as avoidance of factors that increase chance of CTS.
Surgical	Decompression of connective, bone-connective or muscle-connective tissues, which are compressing the involved nerve. Sometimes an osteophyte, ganglion or tumor needs to be removed or transposition needs to be made. Sometimes longitudinal epineurotomy needs to be made if nerve is thickened, shortened or extremely compressed nerve segment

Among conservative treatment options the most useful and least harmful one is the use of night orthoses. It is worn during the night to prevent extreme wrist positions, and it might be used during the day if extreme paresthesias and pain attacks

are present. Among most used orthoses are those that will immobilize wrist in 15 degrees extension or in neutral wrist position. Orthoses are most useful if used within 3 months of symptoms presentation. (19)

Local corticosteroid injection is a short-term conservative treatment of limited duration. Usually is to be avoided due to side effects and used only where surgery is not possible.

Other anti-inflammatory drugs and diuretics given as injection can be used to treat tenosynovitis. They are given around flexor tendons, and as inflammation decreases, nerve compression will consequently decrease. (1)

Pulsed US is used in sudden attacks of pain and continuous US is used for chronic states. US will increase nerve regeneration, biologic membrane permeability, temperature of soft tissues, circulation and nutrition, all of which leads to improvement in CTS. (20)

Laser and TENS showed to be good alternative to conventional treatment if used in early phase of disease, when there is still absence of pathologic EMG.

A scoring point system was developed for evaluation of CTS. Each of these criteria represent one point: duration more than 10 months, age over 50 years, permanent paresthesias, positive Phalen sign in less than 30 seconds, and tenosynovitis of flexors. If patient has less than three of these, there is a 30% of chance that conservative treatment will be successful whereas if patient has more than three points, conservative treatment will be successful in less than 5% of patients. (1)

Around 40% of cases will require surgical treatment. Classical operation is division of the retinaculum under visual control. 3-4 cm incision will be made on the palmar side of the hand with transverse cut of the flexor retinaculum. In selected patients it can be done endoscopically, but it carries risk of nerve damage as visual field is decreased. The benefit is decreased postoperative pain with smaller wound and earlier return to work. (20)

The results after surgery are good, showing decreased pain in 86% of cases, return of normal function in 40%. In 5% of patients there can be worsening of symptoms. After operation, physiotherapy should start immediately after removal of compressive band. First day hand should be elevated to prevent swelling. On the second day patient should start with finger exercises. Exercises should be undertaken 3-6 times per day and lasts at least 10 days. After 3 to 4 weeks patient should start doing strength muscles exercises. Most patients can use hand after suture removal but will have to wait between 6 to 8 weeks for use of heavier loads. (20)

2.8. Temperature regulation in human body

The core temperature or temperature of deep tissues of the body will be maintained within $\pm 0.6^{\circ}\text{C}$, despite big external temperature changes (from 12 to 55 C degrees).

No single core temperature can be considered normal, as various measurements taken orally in healthy normal people showed variations between 36°C to more than 37.5°C . Even more the skin temperature will adjust to surrounding and can vary few degrees of C. The temperature has variation during the day of up to $0.6^{\circ}\text{C}\pm$, will reach maximum temperature between 6PM and 10PM, and minimum between 2AM to 4AM, phenomena linked to hypothalamic circadian rhythm. (21)

Temperature is maintained by balancing heat production and heat loss, regulated by thermoregulation center, located in posterior hypothalamus, which integrates information from peripheral receptors and generates response via effector nerves upon information given.

Anterior hypothalamus, within preoptic area contains large numbers of heat sensitive neurons and cold sensitive neurons. There are many heat sensitive neurons within lower part of the brainstem and spinal cord.

Peripheral skin receptors will send information about temperature to posterior hypothalamus and somatosensory cortex via spinothalamic tract and by that inform thermoregulatory center as well as consciousness about peripheral temperature

changes. Peripheral skin receptors will together with heat and cold sensitive neurons within anterior hypothalamus, as well within brainstem and spinal cord, generate whole body temperature picture inside thermoregulatory center located in posterior hypothalamus. (21)

The response to the information collected within thermoregulatory center will be sent via efferent nerves. Those are somatomotor and autonomic sympathetic nerve system as well as regulation via endocrine system.

Somatomotor system will generate heat with muscle shivering. It is located in dorsomedial portion of posterior hypothalamus, near the wall of the third ventricle. It will be inhibited by signals from heat center in the anterior hypothalamus while stimulated by cold signals from the skin and spinal cord. This mechanism by itself can increase body heat production four times during maximum shivering.

Sympathetic autonomic nerve system takes part in heat regulation via vasomotor, sweat gland stimulation and chemical or non-shivering thermogenesis.

When alpha-adrenergic receptors of smooth muscle cells located in blood vessels, are stimulated, blood vessels will be vasoconstricted leading to reduced heat loss from surface of the body. When this receptor activity is decreased, the result will be vasodilatation with consequent heat loss via radiation, conduction and convection.

Sweating will lead to heat loss. Sweating will occur when sweat glands are stimulated by acetylcholine. (21)

2.9. Changes in skin temperature regulation of peripheral nerves when blocked by local anesthetic

In his doctoral thesis, Dr.Petravić, assessed contralateral homotopic effects of peripheral cutaneous nerve functional block in humans. Local anesthetic was used as a block in 25 healthy volunteers. Result of unilateral compression of the radial nerve superficial branch showed a bilateral stereotypic hyperthermic response of continuously ascending dynamics in the corresponding areas of innervation. Adjacent innervation area of ulnar nerve showed bilateral stereotypic polyphasic hypo/hyperthermic response of gradually ascending dynamics. Dr.Petravić concluded that changes pointed to the existence of polysynaptic reflex transspinal transmission of neural impulses in both directions between corresponding zones of somatic and vegetative afferent and vegetative efferent nerves. (21)

3. HYPOTHESIS

Null- hypothesis of this graduate thesis is that in patients with CTS, there will be no statistical difference between the preoperative temperatures of the median, ulnar and radial nerve innervated hand skin.

H1 hypothesis of this graduate thesis is to see if there are any statistically significant differences between, median, ulnar and radial nerve innervated hand skin.

4. OBJECTIVES

Objectives and goals of this graduate thesis were to compare temperatures of median, ulnar and radial nerve innervated hand skin by using nonparametric Wilcoxon signed rank test, and to see will there be any statistically significant difference in any of the above mentioned relationships.

5.MATERIAL AND METHODS

This graduate thesis was a prospective study in which 15 patients had temperature measurement of radial, medial and ulnar nerve preoperatively.

For the use of the patients data for my graduate thesis I have obtained approval from the ethical committee in KBC Zagreb.

After approval from the side of the ethical committee in KBC Zagreb, and signed informed consent from all 15 patients, temperature measurement was conducted in KBC Zagreb.

Out of 15 patients, 13 were females and 2 males, with youngest patient being 37 years old and oldest 71 years old. Average age of patients was 49,33.

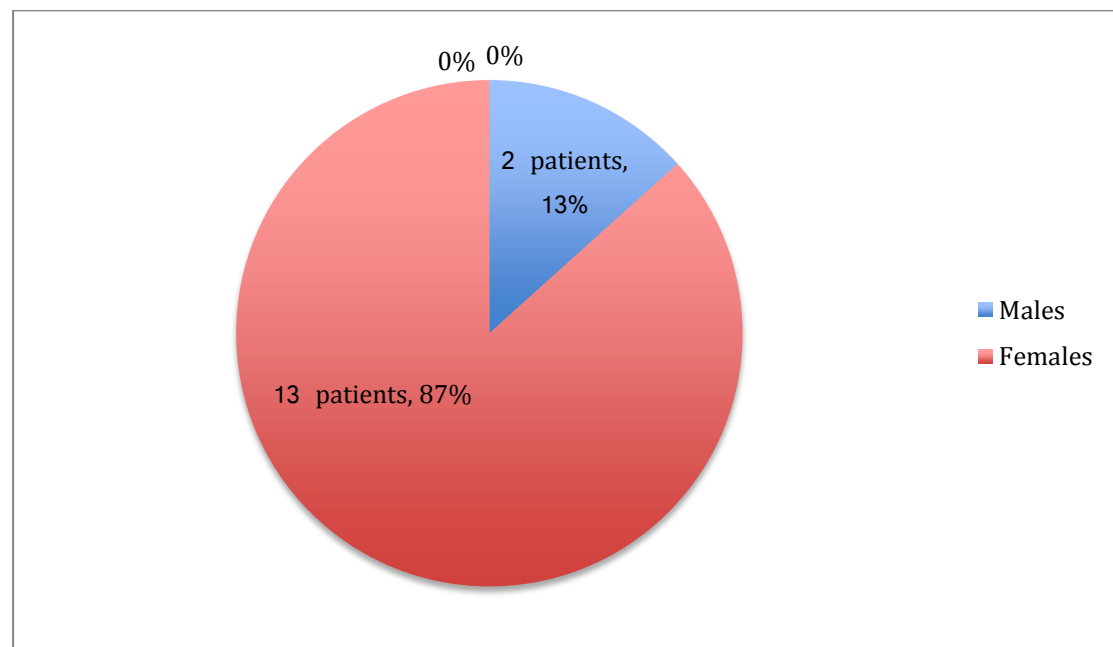
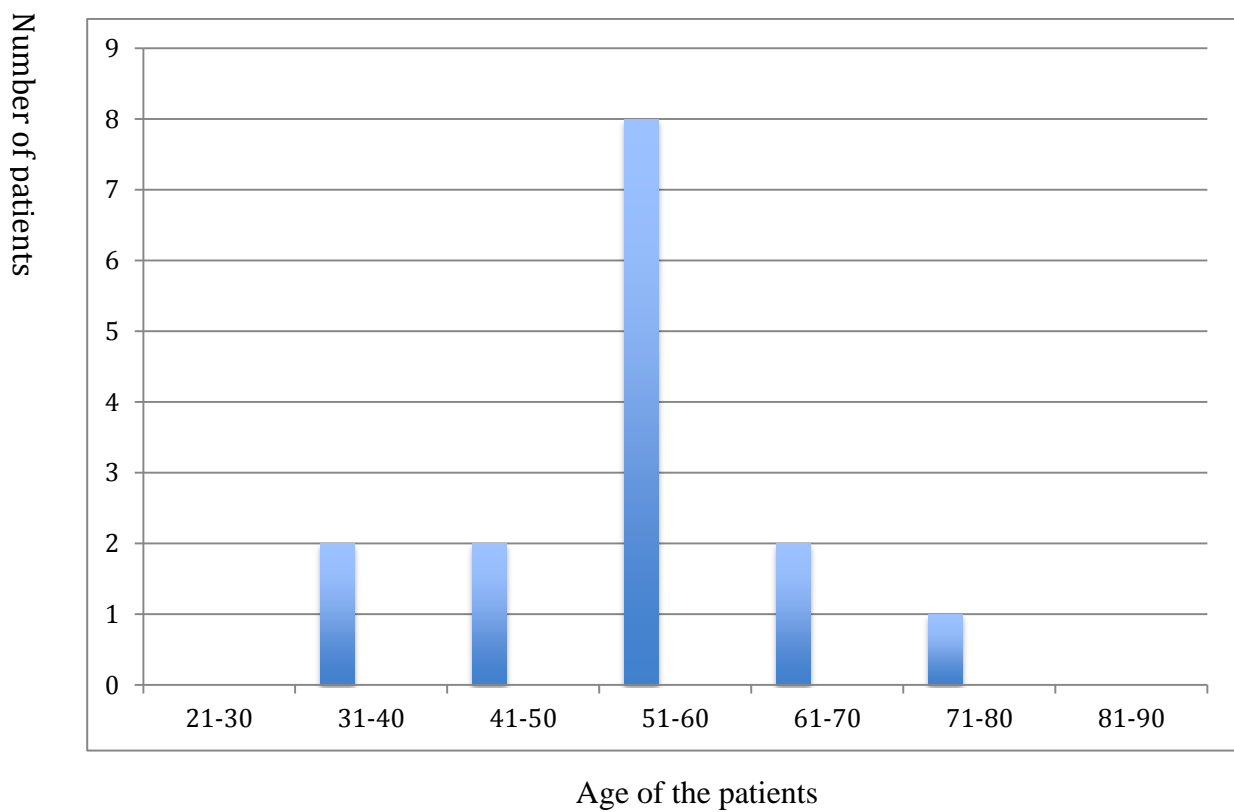


Chart 5.1. Distribution of patients by age

Distribution of patients by age:

- 31-40 years of age there were 2 patients
- 41-50 years of age there were 2 patients
- 51-60 years of age there were 8 patients
- 61-70 years of age there were 2 patients
- 71-80 years of age there was 1 patient



Column 5.2. Distribution of patients by age

In the study, skin temperature was measured on the parts of the hand affected by CTS innervated by median, ulnar and radial nerve, which are innervating dorsal and palmar side of the hand.

Skin temperature was measured 3 times on each referent point. The distance between thermometer and reference point was 2 cm.

For measuring, laser thermometer FS-300, non-contact infrared thermometer “Thermofinder”, made by HuBDIC Company from Republic of Korea was used.

All measures were undertaken prior to operation, and were conducted in constant environment with room temperature being set between 22-24°C, air humidity between 40-60% and between 8AM- 12AM.

On the day of the measurement, patients were left for 15 minutes with both hands in standard positions in the examination room, so they had time for adoption to environment of the examination room.

For the analysis median temperatures of areas innervated by median nerve, ulnar nerve and radial nerve will be used.

For statistical analysis of data, nonparametric Wilcoxon signed rank test will be used.

6.RESULTS

The results of preoperative temperature measurements of CTS patients will be presented in 4 parts. In first part median temperatures of median, radial and ulnar nerve temperature will be presented. In second part relationship of the median nerve to the radial nerve will be presented. In third part the relationship of the median nerve to the ulnar nerve will be presented. In the last part the relationship of the ulnar nerve to the radial nerve will be presented.

6.1. Presentation of obtained median temperature measurements

Patients	Median temperature of median nerve in °C	Median temperature of radial nerve in °C	Median temperature of ulnar nerve in °C
1	37.00	36.80	37.10
2	36.67	36.80	36.47
3	36.73	36.37	36.63
4	36.70	36.77	36.70
5	36.00	36.40	35.90
6	36.73	36.70	36.00
7	37.17	36.90	36.90
8	37.47	37.13	37.73
9	35.97	36.40	35.77
10	36.97	36.90	36.93
11	37.30	37.20	37.53
12	36.80	36.90	36.90
13	36.00	36.47	36.70
14	37.70	37.10	37.45
15	37.10	36.70	37.10

Table 6.1.1. Median temperature values of median, radial and ulnar nerve in °C

6.2. Relationship of the median nerve to the radial nerve

Analysis of median temperature of median nerve and median temperature of radial nerve by Wilcoxon signed rank test showed following results:

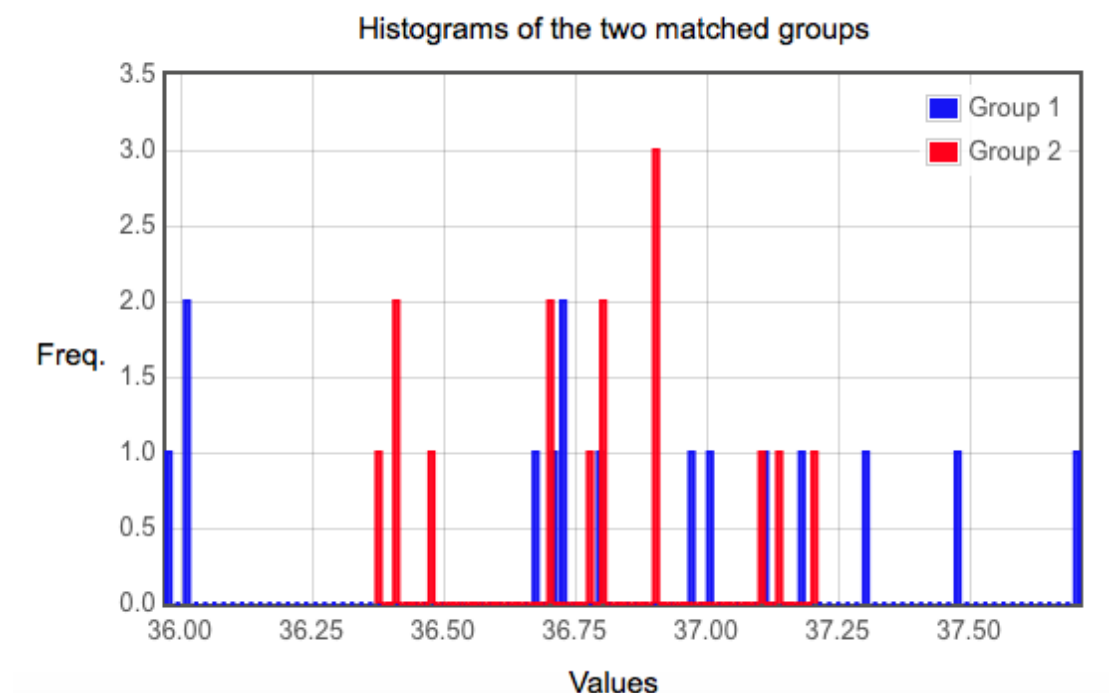
Result 1 - Z-value:

The Z-value is -0.4544. The p-value is 0.65272. The result is not significant at $p \leq 0.05$.

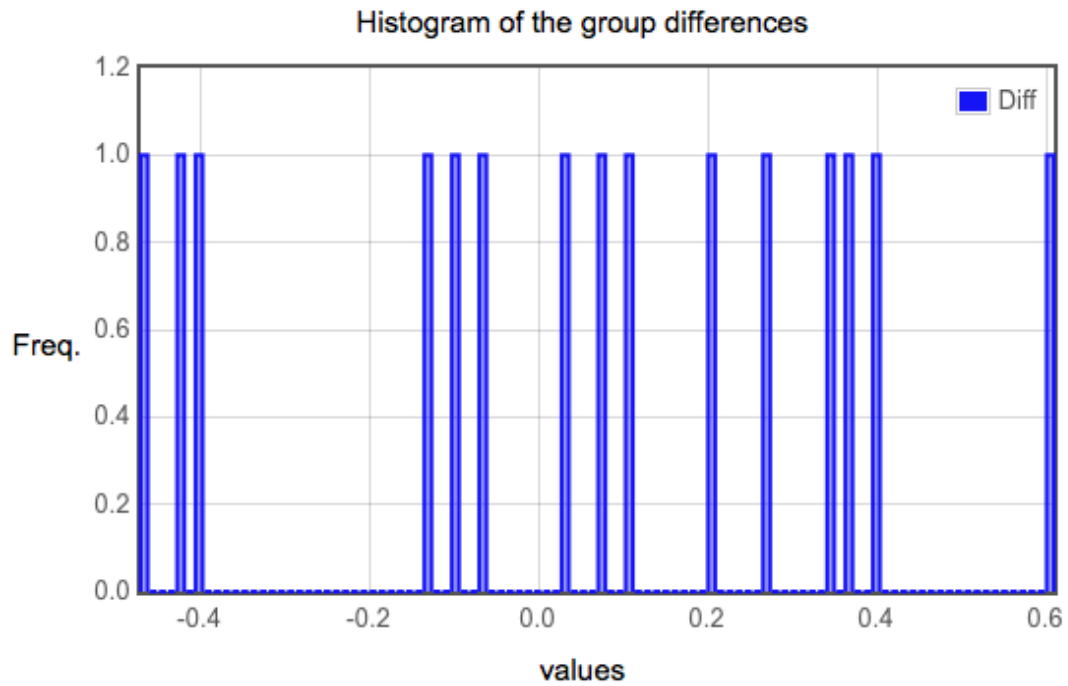
Result 2 - W-value:

The W-value is 52. The critical value of W for $N = 15$ at $p \leq 0.05$ is 25. Therefore, the result is not significant at $p \leq 0.05$.

Following histograms could be obtained from results:



Histogram 6.2.1. Histogram of the two matched groups, Group 1 being median nerve temperature and group 2 being radial nerve temperatures, whereas values represent temperatures in °C



Histogram 6.2.2. Histogram of the group differences

From the obtained results it can be concluded that results are not statistically significant. Null hypothesis is accepted.

6.3. Relationship of the median nerve to the ulnar nerve:

Analysis of median temperature of median nerve and median temperature of ulnar nerve by Wilcoxon signed rank test showed following results:

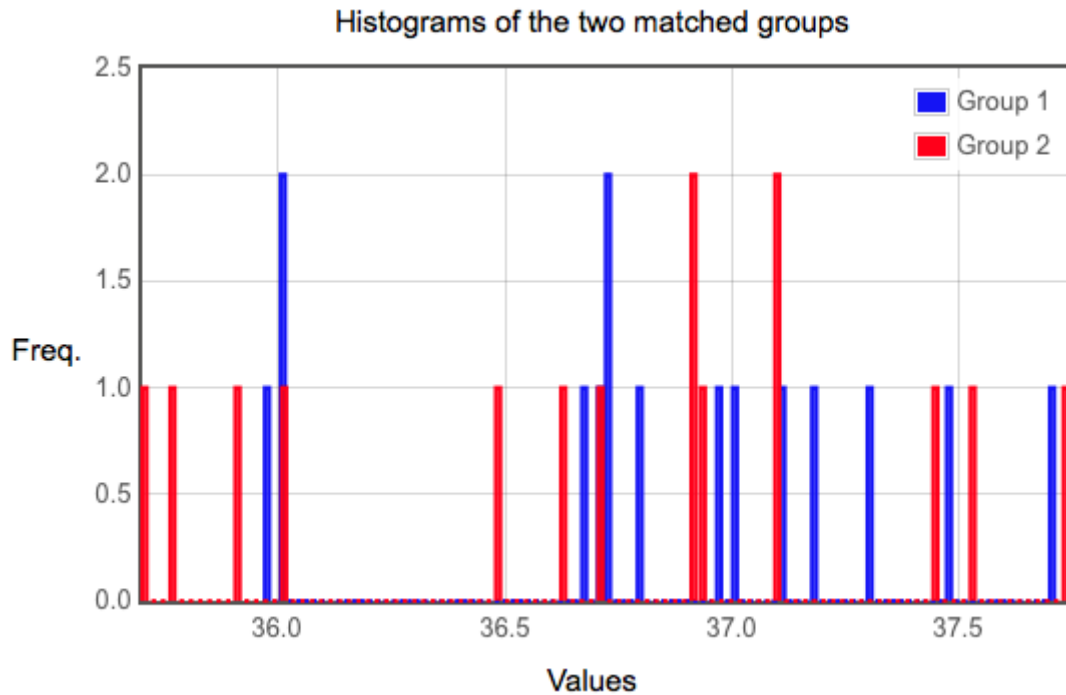
Result 1 - Z-value:

The Z-value is -1.3628. The p-value is 0.17384. The result is not significant at $p \leq 0.05$.

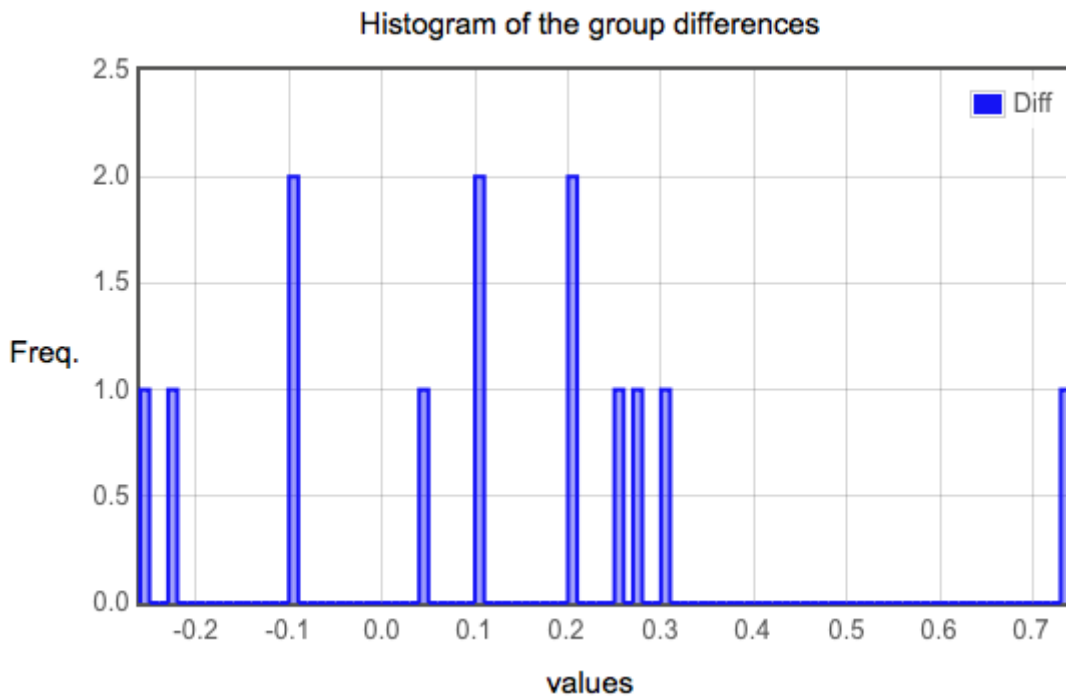
Result 2 - W-value:

The W-value is 26. The critical value of W for $N = 13$ at $p \leq 0.05$ is 17. Therefore, the result is not significant at $p \leq 0.05$.

Following histograms could be obtained from results:



Histogram 6.3.1. Histogram of the two matched groups, Group 1 being median nerve temperature and group 2 being ulnar nerve temperatures, whereas values represent temperatures in °C



Histogram 6.3.2. Histogram of the group differences

From the obtained results it can be concluded that results are not statistically significant. Null hypothesis is accepted.

6.4. Relationship of the ulnar nerve to the radial nerve:

Analysis of median temperature of median nerve and median temperature of ulnar nerve by Wilcoxon signed rank test showed following results:

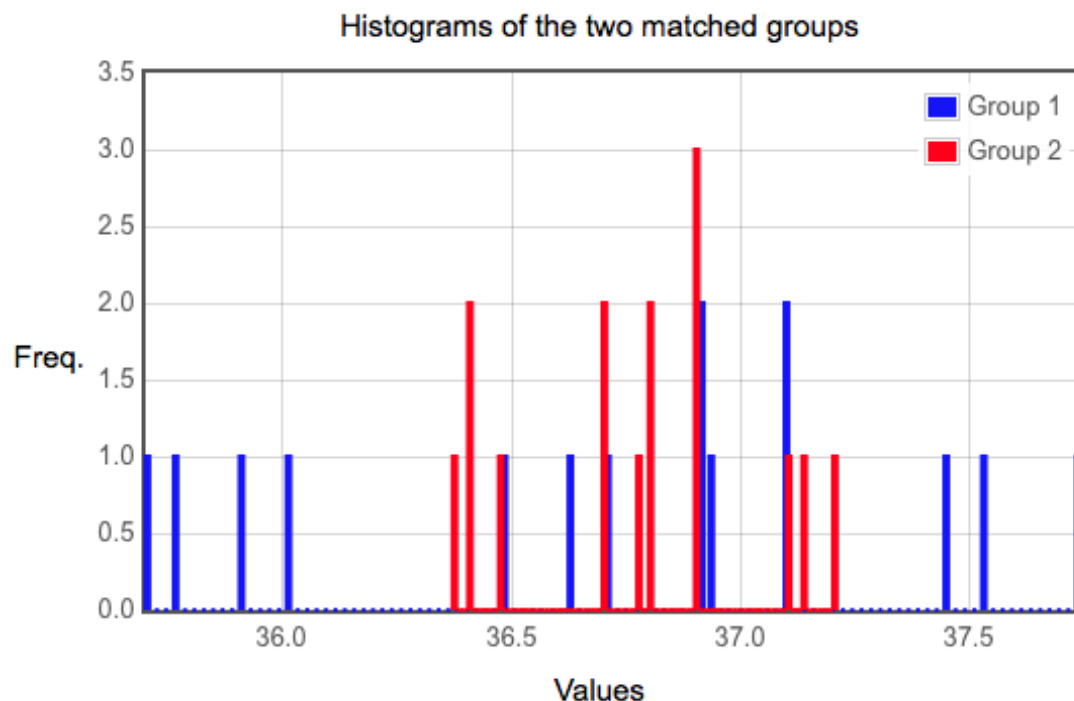
Result 1 - Z-value:

The Z-value is -0.4892. The p-value is 0.62414. The result is not significant at $p \leq 0.05$.

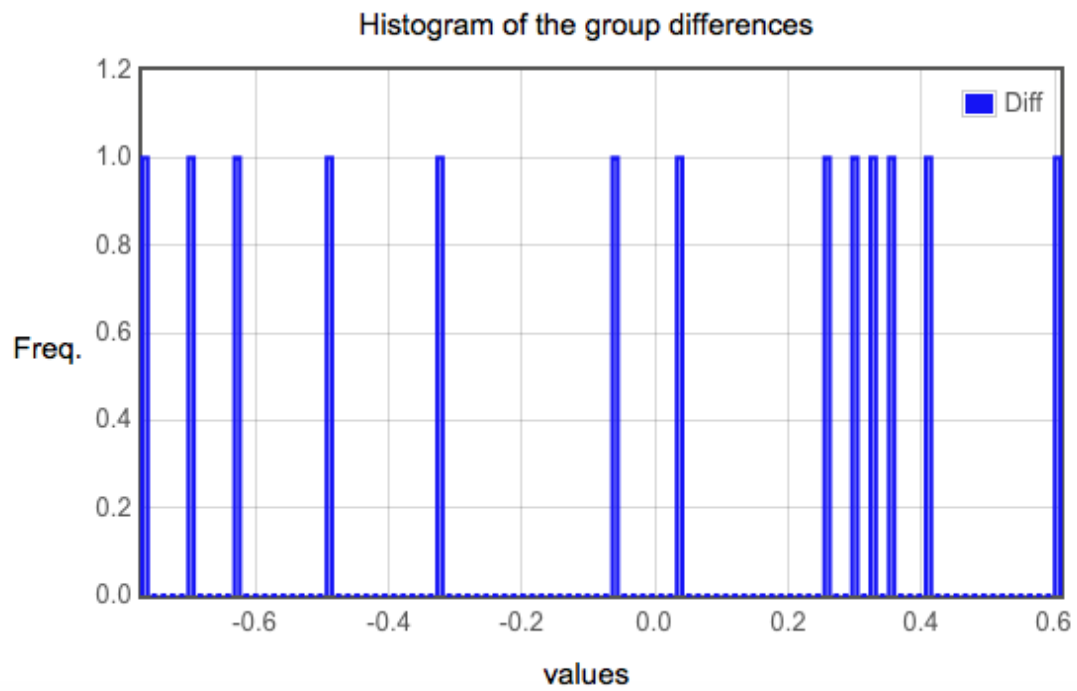
Result 2 - W-value:

The W-value is 38.5. The critical value of W for $N = 13$ at $p \leq 0.05$ is 17. Therefore, the result is not significant at $p \leq 0.05$.

Following histograms could be obtained from results



Histogram 6.4.1. Histogram of the two matched groups, Group 1 being ulnar nerve temperature and group 2 being radial nerve temperatures, whereas values represent temperatures in °C



Histogram 6.4.2. Histogram of the group differences

From the obtained results it can be concluded that results are not statistically significant. Null hypothesis is accepted.

7.DISCUSSION

CTS being the most common compression syndrome and affecting 5% of adult population represents a challenge in diagnosis, treatment and prevention. From current understandings CTS is mostly an idiopathic disease with surgical treatment being the most effective one. (1)

It has been proved that CTS is associated with specific occupational factors such as exposure to vibration for example forestry workers, stonemasons and assembly work such as food processing and packing, electrical assembly working, whereas use of computer keyboard and mouse does not pose a severe occupational hazard for developing CTS. (23)

It was shown that unilateral compression of radial nerve superficial branch would lead to bilateral stereotypic hyperthermic response. As well adjacent innervation area of ulnar nerve, showed bilateral stereotypic polyphasic hypo/hyperthermic response. This study was conducted on healthy volunteers. (22)

The goal was to see will there be any statistically significant increase or decrease in temperature relationship of median nerve to ulnar and radial nerve as well as ulnar to radial nerve on the hand affected by CTS, preoperatively, and if to try to describe what could be the reason for the changes that did occurred, as well as a potential role in diagnosis and treatment.

The Wilcoxon signed rank test shown that there were no statistically significant temperature changes in patients with CTS, when affected median nerve temperatures were compared to ulnar and radial nerve temperatures.

In our opinion, temperature of median nerve affected by CTS and surrounding ulnar and radial nerve looking preoperatively, will adjust to the chronic condition of the syndrome and if changed from the start point, temperature relationship of median to radial and ulnar, as well as ulnar to radial nerve will show no statistical significance.

8.CONCLUSION

When temperatures of the median, ulnar and radial nerve obtained by laser thermometer, preoperatively, in the hand affected by CTS were compared one to another, nonparametric Wilcoxon signed rank test shown that there was no statistically significant difference.

9.ACKNOWLEDGEMENTS

Foremost I would like to express sincere gratitude to my mentor Krešimir Bulić MD, PhD for his unconditional support and help, as well as his personal experience and expertise, motivation, teaching and guidance provided during my graduate thesis writing.

Besides my mentor I would like to thank Maksimilijan Mrak, MD for help with data collection.

Also I would like to thank the rest of my graduate committee: Prof. Davor Mijatović, MD, PhD and Tomislav Meštrović, MD, PhD

I would like to thank my parents, family, and friends for the unconditional support and help during my medical studies.

Last, but not least, I would like to thank all teaching personnel in School of Medicine, Medical Studies in English, for all the knowledge gained needed for being awarded with title Doctor of Medicine.

10. REFERENCES:

1. Luchetti R, Amadio P. Carpal tunnel syndrome. Berlin: Springer; 2007.
2. Gensoul (1836) Arch gé'n de mé'd XL: 187
3. Denny-Brown D, Brenner C (1944) Paralysis of nerve induced by direct pressure and by tourniquet. Archives Neurol Psychiatry 51(1):1 – 26
4. Hunt JR (1910) Occupation neuritis of the thenar branch of the median nerve: (a well defined type of neural atrophy of the hand). Trans Am Neurol Assoc 35:184
5. Poore GV (1873) On a case of writer's cramp, and subsequent general spasm of the right arm, treated by the joint use of the continuous galvanic current and the rhythmical exercise of the affected muscles. Practitioner 9:129 – 137
6. Amadio PC (1995) The first carpal tunnel release? J Hand Surg (British and European Vol.) 20B:I:40 – 41
7. Moore K, Dalley A, Agur A. Clinically oriented anatomy. Philadelphia: Wolters Kluwer Health/Lippincott Williams & Wilkins; 2010.
8. Presazzi A, Bortolotto C, Zacchino M, Madonia L, Draghi F. Carpal tunnel: Normal anatomy, anatomical variants and ultrasound technique. Journal of Ultrasound. 2011;14(1):40-46.
9. McLellan DL, Swash M (1976) Longitudinal sliding of the median nerve during movement of the upper limb. J Neurol Neurosurg Psychiatry 39: 566 – 570
10. Katz JN, Stirrat CR. A self-administered hand diagram for the diagnosis of carpal tunnel syndrome. J Hand Surg 1990; 15A: 360-363.
11. Emedicine.medscape.com., 'Carpal Tunnel Syndrome: Background, Pathophysiology, Epidemiology'. N.p., 2015. Web. 10 Dec. 2015.
12. M W. Carpal tunnel syndrome: pathophysiology and clinical neurophysiology. - PubMed - NCBI [Internet]. Ncbi.nlm.nih.gov. Available from: <http://www.ncbi.nlm.nih.gov/pubmed/12169318>
13. AL S. Carpal tunnel syndrome diagnosis. - PubMed - NCBI [Internet]. Ncbi.nlm.nih.gov. Available from: <http://www.ncbi.nlm.nih.gov/pubmed/24787330>
14. [Internet]. 2015]. Available from: http://www.turner-white.com/pdf/hp_jul00_tinel.pdf
15. Willimas M, Mackinnon SE et al. (1992) Verification of the pressure provocative test in carpal tunnel syndrome. Ann Plast Surg. 29: 8 – 11
16. AL S. Carpal tunnel syndrome diagnosis. - PubMed - NCBI [Internet]. Ncbi.nlm.nih.gov. 2015. Available from: <http://www.ncbi.nlm.nih.gov/pubmed/24787330>

17. André V e. [Clinical, electrophysiological and MRI correlations in carpal tunnel syndrome]. - PubMed - NCBI [Internet]. Ncbi.nlm.nih.gov. Available from: <http://www.ncbi.nlm.nih.gov/pubmed/10431272>
18. Deniz FE e. Comparison of the diagnostic utility of electromyography, ultrasonography, computed tomography, and magnetic resonance imaging in idiopathic carpal... - PubMed - NCBI [Internet]. Ncbi.nlm.nih.gov. 2015. Available from: <http://www.ncbi.nlm.nih.gov/pubmed/21869718>
19. Zinnuroglu M e. Carpal lock and the volar-supporting orthosis in mild and moderate carpal tunnel syndrome. - PubMed - NCBI [Internet]. Ncbi.nlm.nih.gov. 2015. Available from: <http://www.ncbi.nlm.nih.gov/pubmed/20581649>
20. Tomislav Crnković, Ranko Bilić, Robert Kolundžić. Carpal tunnel syndrome – modern diagnostic and therapy
21. Hall J, Guyton A. Guyton and Hall textbook of medical physiology. Philadelphia, PA: Elsevier; 2015.
22. Petravić D, Teletermografska analiza kontralateralnih korespondentnih učinaka funkcijskog bloka perifernog osjetnog živca u ljudi, doktorska disertacija, 2003, Zagreb
23. Palmer, Keith T. "Carpal Tunnel Syndrome: The Role Of Occupational Factors". *Best Practice & Research Clinical Rheumatology* 25.1 (2011): 15-29. Web. 5 Jan. 2016.

11.BIOGRAPHY

I was born in Novi Sad, Republic of Serbia on January 9th 1991. My parents Zoran Preveden MD, Consultant of Trauma and Orthopaedic surgery and mother assistant Ružica Preveden, MD, Consultant of Dermatovenerology moved to Slovenia when I was 6 years old. First 4 years of primary school I finished in primary school Grm, Novo mesto, 5th – 7th grade in primary school Hudinja, Celje and 8th grade in primary school Prule, Ljubljana. I finished my high school education at Gimnazija Bežigrad in Ljubljana and enrolled in the University of Zagreb School of medicine, Medical studies in English in the academic year 2010/2011.

All my free time was devoted to humanitarian work and surgery. I am member of humanitarian organization Rotaract Sesvete (Rotary youth) since 2011. Whenever I could I spent my free time I went to Department of Emergency medicine, Rebro and Department of Emergency medicine, Novo mesto, Slovenia, where whenever I could I did participate in assisting surgery or on the Department with suturing etc... In summer 2014 I have spend 2 months on Department of Plastic, Reconstructive and Esthetic Surgery in Novo mesto, Slovenia In summer 2015 I was 1 month in Germany, University of Heidelberg, Clinical Surgery, Department of Endovascular and Vascular surgery. For the clinical rotations I will spend 1 month in Novo mesto in the department of Anesthesiology and Reanimatology and one month in Austria, Vienna, AKH, Department for plastic, reconstructive and esthetic surgery. I have also participated in congresses and workshops.

I am fluent in speaking English, German, Slovenian, Croatian and Serbian language.