

# Modern approach in a meniscal injury treatment

---

Ivanišević, Arsen

Master's thesis / Diplomski rad

2014

Degree Grantor / Ustanova koja je dodijelila akademski / stručni stupanj: **University of Zagreb, School of Medicine / Sveučilište u Zagrebu, Medicinski fakultet**

Permanent link / Trajna poveznica: <https://um.nsk.hr/um:nbn:hr:105:043216>

Rights / Prava: [In copyright](#)/[Zaštićeno autorskim pravom.](#)

Download date / Datum preuzimanja: **2025-02-07**



Repository / Repozitorij:

[Dr Med - University of Zagreb School of Medicine Digital Repository](#)



UNIVERSITY OF ZAGREB  
SCHOOL OF MEDICINE

ARSEN IVANIŠEVIĆ

**MODERN APPROACH IN A MENISCAL  
INJURY TREATMENT**

**GRADUATE THESIS**



Zagreb, June 2014.

UNIVERSITY OF ZAGREB  
SCHOOL OF MEDICINE

ARSEN IVANIŠEVIĆ  
**MODERN APPROACH IN A MENISCAL  
INJURY TREATMENT**

**GRADUATE THESIS**

Zagreb, June 2014.

This graduate thesis was made at Clinic for Traumatology in CHC Sisters of Charity, mentored by Nikica Daraboš MD PhD and was submitted for evaluation in the academic year of 2013/2014.

AANA - Arthroscopy Association of North America  
ACL - anterior cruciate ligament  
AP – anteroposterior  
AD - arthroscopic debridement  
CAT - computerized axial tomography  
EMTG - European Meniscal Transplantation Group  
MAT – meniscal allograft transplantation  
MRI - magnetic resonance imaging  
OA - osteoarthritis  
PA - posteroanterior  
PCL – posterior cruciate ligament  
PLLA - poly-L-lactic acid  
ROM – range of motion  
SFA - French Arthroscopy Society

## **CONTENT**

1. SUMMARY
2. HISTORY OF MENISCUS TREATMENT
3. ANATOMICAL OVERVIEW
  - 3.1 Medial compartment
  - 3.2 Intercondylar notch
  - 3.3. Lateral compartment
  - 3.4. Vascularization
4. EPIDEMIOLOGY
5. STRUCTURE AND BIOMECHANICS
6. MECHANISM AND PATHOLOGY OF THE INJURY
7. CLINICAL PICTURE AND DIAGNOSTICS
8. TREATMENT
  - 8.1. CONSERVATIVE TREATMENT
  - 8.2. OPERATIVE TREATMENT
    - 8.2.1. Meniscectomy
    - 8.2.2. Meniscal repair
    - 8.2.3. All-inside technique
    - 8.2.4. Inside-out technique
    - 8.2.5. Outside-in technique
    - 8.2.6. Meniscal transplant
9. CONCLUSION
10. ACKNOWLEDGEMENTS
11. REFERENCES

## 1. SUMMARY

Meniscal injuries are one of the most common pathologies in the orthopedic clinic. It is an injury which occurs in abnormal knee movement or as a form of a degenerative process over years. The types of meniscal injury are various in means of severity, patient history, clinical presentation and patient age. Discoveries in the meniscal biomechanics proposed great changes for the general health of the knee joint and advancement in the treatment. Meniscal pathology is better understood and the progress in diagnostics and treatment allows preservation of the knee from developing symptoms and secondary osteoarthritic changes. It was not long ago that any suspicion of a meniscal lesion led to open meniscectomy, which in most cases was total. Magnetic resonance imaging in the second part of the 20th century made revolutionary progress in classification and lesion analysis. Arthroscopy allowed less invasive treatment options and has rapidly replaced open total to arthroscopic partial meniscectomy with parallel development of meniscal tissue sparing treatments coordinately to statistical results. New promising options raised in development of various techniques of meniscal repair and transplantation. Meniscal repair shows promising results in its ever-evolving techniques including inside-out, outside-in and all inside. In the 1990s began the era of meniscal replacement as a modern possibility in treating meniscal pathologies. Increased improvements in graft fixation and extended indications for meniscus allografting have widened the demand for meniscal allografts.

Keywords: meniscus injury, meniscectomy, repair, meniscus replacement

## 2. HISTORY OF MENISCUS TREATMENT

The meniscus was described as a functionless remnant of a leg muscle in 1897 by Sutton. In 1936, King realized the role of the meniscus is in joint stability, lubrication, congruity and chondroprotection. Fairbank in 1984 presented radiographic evidence, describing ridge formation, joint space narrowing and flattening of the femoral condyles after meniscectomy. Ever since, there is increase in understanding of the biomechanics and function of the meniscus together with the long-term consequences of its removal. [1] Some of the most advanced cultures, including the Egyptians, Greeks, Romans, and Arabs, saw the potential in direct imaging and made attempts to view accessible human body cavities using a variety of instruments such as spatulas and specula. This curiosity led to the discovery of the first endoscope, which was created in 1806 when Phillip Bozzini, a German-born urologist, constructed the „*lichtleiter*“. This endoscope used concave mirrors to reflect candlelight through an open tube into the esophagus, bladder, or rectum.[2]

The 18th century highlights merely outlined the clinical picture of injuries to the meniscus and the importance of this semilunar-cartilaginous structure of the knee-joint was generally not recognized. Reliable standards of sterility were imperative to obtain reproductive and satisfactory results in surgery of the knee-joint and this is why the discovery and implementation of antiseptic and aseptic principles play such an important role in joint and, in particular, in meniscal-surgery. The development of meniscal-surgery is dominated by a lengthy discussion about the way in which the injuries of the semilunar cartilages should be dealt with operatively. Fundamental techniques such as fixation of the cartilage by sutures, limited or total removal of the meniscus were established as early as 1895. Over a long period they existed concurrently and their adequate application remained cause for a highly controversial discussion until the end of the 20th century. Not before more detailed knowledge was gained about the exact morphology of the meniscus and the rising of arthroscopic surgery offered new surgical perspectives, it was possible to establish a widely accepted standard of meniscal surgery. [3] After Bozzini, in 19<sup>th</sup> century, a key role in the development of endoscopy is the one of Maximilian Carl-Friedrich Nitze (1848. – 1906. ), another German urologist, who achieved higher magnification by a series of lenses therefore producing the first



usable cystoscope in 1877. He demonstrated that it was possible to perform operations through this instrument. [2]

Hans Christian Jacobaeus performed the first thoracoscopy and laparoscopy using this cystoscope which in 1919 a Japanese professor Kenji Takagi adapted to arthroscopic use. Takagi was traditionally believed to have performed the first arthroscopic examination, which was recently disproved and the credits were given to a Danish surgeon Severin Nordentoft. He performed the first arthroscopic examination of the knee in 1912 and reported on the 41st Congress of German society of Surgeons in Berlin in his paper "Endoscopy of Closed Cavities by the Means of My Trokart-Endoscope". [4] Dr. Nordentoft had constructed an endoscope similar to the Jacobaeus thoracoscope, which contained a 5 mm diameter trocar, a fluid valve, and an optic tube. In addition to suprapubic cystoscopy and laparoscopy, he advised the use of such an endoscopic device in the knee joint, especially for early detection of meniscal lesions. He called the procedure „arthroscopia genu“ in which he used sterile saline or boric acid as an optic medium, with the optic portal on the lateral border of the patella. Dr. Nordentoft gave a detailed and credible description of the technique of the instrument use and the view of the anterior region of the knee, including the articular cartilage, synovial lining, villi, and plicae. Unfortunately, he did not express clearly if he performed arthroscopy on patients or on cadaver knees. This is the only known paper or presentation by Severin Nordentoft on the topic of arthroscopy. [5]

Kenji Takagi experimented with the use of a cystoscope for the visualization of the interior of the knee joint. In 1920 he developed a special device with a diameter of 7.3 mm for endoscopy of the knee joint. However, because of its thickness this instrument was not suitable for practical use. It was not until 1931 that he succeeded in developing an arthroscope with a diameter of 3.5 mm. Takagi expanded the interior of the knee joint by filling it with saline. The first publication concerning his arthroscope appeared in 1933 in the Japanese Journal of Orthopedic Surgery. [6] Eugen Bircher, another key figure in the history of arthroscopy, published several papers on diagnostic arthroscopy of the knee. He was a strong advocate of diagnostic arthroscopy as shown in scientific papers on the topic of internal derangements of the knee published between 1921 and 1926. During that time, he performed about 60 endoscopic procedures and arthroscopic treatment for surgical repair, removal of damaged tissue and meniscectomy. This might be considered the first time arthroscopy was used in a large scale for clinical purposes.

In 1922, Bircher published a paper on the pathology and diagnosis of endoscopically investigated menisci of 20 knee joints. Even at this point he successfully diagnosed eight out of nine meniscus injuries, afterwards confirming the diagnosis during subsequent surgery. At the end of the paper Eugen Bircher wrote:

"Arthroscopy allows us to examine the interior of the joint and identify pathological changes, i.e. the diagnosis is made by direct visualization of the lesion. It is therefore superior to all other methods of investigation and, like endoscopy of the bladder, can be used to define certain indications for surgery. It will meet with resistance, as did cystoscopy, but, like the latter procedure, will gain in popularity and develop to the point at which it becomes indispensable." [6]

The endoscopic tool he used was the Jacobaeus thoracolumboscopy, which had poor endoscopic qualities. It contained an electric lamp at the end of the optical device and was not mechanically protected creating danger of tissue damage by every manipulation within the joint space. The 90 degrees optical system presented a dim image. By the late 1920s, Bircher had developed the technique of double-contrast arthrography and finally gave up endoscopy by 1930. [7] King in 1936 saw the importance of the meniscus and its role in joint stability, lubrication, congruity, and chondroprotection. He performed studies on canines where the degenerative changes of postmeniscectomy knees were documented as well as the low healing potential of meniscal tears. Fairbank presented radiographic evidence of total meniscectomy in 1948, describing ridge formation, joint space narrowing, and fattening of femoral condyles in patients who underwent the operation. This brought closer attention and since continued to improve our understanding of meniscal biomechanics and long-term consequences of its removal. [1]

A Japanese surgeon Masaki Watanabe (1911–1995), MD, who trained under the guidance of Professor Kenji Takagi, was named the „founder of modern arthroscopy“ and receives primary credit for interventional surgery. Their work together was interrupted by the Second World War. In 1949 Dr. Watanabe became director of the Department of Orthopedic Surgery at Tokyo Teishin Hospital, where he had a strong desire to develop arthroscopy and came to be respected as the world’s leading exponent of the technique. In 1960, he developed the Watanabe Type 21 arthroscope, a device of outstanding efficiency that remained in function as such for nearly two decades as well as becoming a part of the official logo in the International Arthroscopy Association. In 1962, after great effort and research, he succeeded in performing the first arthroscopic meniscectomy. Many of the world’s finest surgeons,

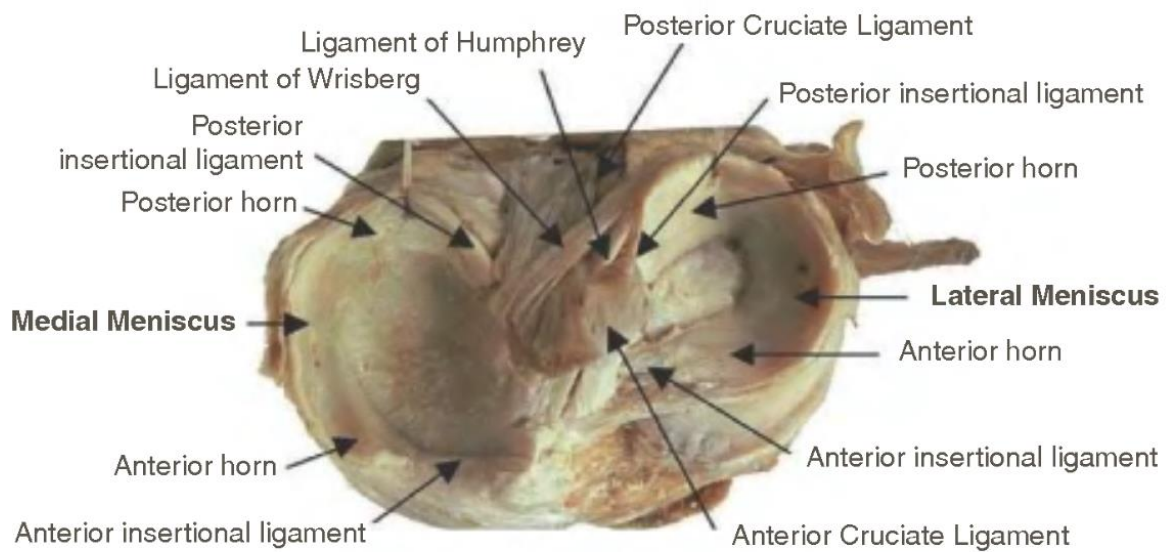
including Dr. Robert Jackson and Dr. Richard O'Connor, visited Tokyo Teishin Hospital to learn arthroscopy.

It was not long after that the teachings in arthroscopy and arthroscope of Professor Watanabe were passed in Japan but also in the world. He could hardly have foreseen the revolution that his engagement would create in the management of joint disorders or that arthroscopy would become one of the most frequently performed orthopedic operations. [8] In the 1960s the arthroscopic meniscectomy had been performed and improved until it finally replaced open meniscectomy. The latter operation required transection of the anterior horn, both medial and lateral to visualize the meniscal body. The procedure itself is deleterious to the function of the meniscus and today has been completely abandoned. [9]

A valuable element of modern arthroscopy, the video equipment, improved from the earliest black and white cameras, first used in 1968, to large color cameras, which were gradually miniaturized until their attachment to the scope was possible and the surgeons would work entirely off the monitor screen. The progress of arthroscopy as an interventional surgery method was highly dependent on technological progress, of which a striking example is flexible fiber optics in 1970s and 1980s. There was also constant development and production of new instrumentation, such as handheld knives and various types of grasping and cutting forceps with different purposes.

### 3. ANATOMICAL OVERVIEW

The knee is often viewed as consisting of the tibio-femoral and patello-femoral joints. The osseous components of the knee are the femur, tibia, patella and fibula. The tibio-femoral joint is divided into medial and lateral compartments. The femoral parts of the knee joint are the medial and lateral condyle, each of distinct shape corresponding to the tibial plateau. Here we observe the role of menisci to allow better placement of the femoral condyles by deepening the contour of the plateau allowing adequate movement of the tibia on the femur. [10]



[9] Gross anatomy of the menisci and associated structures.

The extensor mechanism is made in part of six muscles (rectus femoris, vastus intermedius, vastus lateralis, vastus medialis longus, and vastus medialis obliquus and articularis genu), one tendon (the quadriceps femoris) and the patellar ligament. The patella allows greater mechanical advantage in the extension of the knee and its stability is provided by the pull exerted by the: quadriceps muscle, the fat pad below the patellar tendon, patellofemoral and patellotibial ligaments. The synovial membrane develops from three separate pouches which merge in seams. These are termed plicae and are somewhat variable in nature. The plica courses medially beneath the extensor mechanism and runs with the medial patella border over the medial femoral condyle and attaches to the fat pad. [10]

### 3.1 MEDIAL COMPARTMENT

The medial compartment is supported by the extensor retinaculum, ligamentous stabilization, the pes anserinus group (sartorius, gracilis and semitendinosus muscle), the adductor magnus muscle and five branches of the semimembranosus muscle. The fibers attach to the medial meniscus and the tibia as well as providing support for the posterior capsule. The meniscus is a semicircular fibrocartilaginous structure with bony attachments at its anterior and posterior aspects to the tibial plateau. The medial meniscus is C-shaped. In addition to its bony attachments, the medial meniscus has a capsular attachment, known as the coronary ligament. The muscular attachment to the meniscus retracts the meniscus as the knee flexes. The medial meniscus is also closely attached to the capsular ligaments (menisiofemoral and meniscotibial ligament) that course from the tibial collateral ligament to the pes anserinus on the tibia. Another structure of the medial compartment is the posterior cruciate ligament, composed of posteromedial and anteromedial bundles is often referred the „main stabilizer“ of the knee. Its origin is in the intercondylar surface of the medial femoral condyle and attaches to the tibial fovea.[10]

### 3.2 INTARCONDYLAR NOTCH

The intracondylar notch accommodates both cruciate ligaments and is usually concealed by ligamentum mucosum. The PCL originates above the cartilaginous margin of medial condyle. The ACL insertion is in the line of the anterior horn of the lateral meniscus. The menisiofemoral ligaments can be seen in 70% of cases. The Humphrey (anterior) or Wrisberg (posterior) menisiofemoral ligaments can present together in around 6% of patients. The ligament of Humphrey is around one third of the thickness of the PCL. It attaches to the posterior horn of the lateral meniscus, runs anterior of the PCL and finds its insertion on the distal edge of the PCL femoral attachment. Wrisberg ligament is thicker – about half of the PCL thickness and runs from the lateral meniscus to the medial femoral condyle. [1]

### 3.3 LATERAL COMPARTMENT

Lateral compartment anatomy of the knee is fairly analogous to that of the medial compartment structures. Iliotibial band and iliotibial tract provide the muscular support. These structures attach anterolaterally onto the Gerdy's tubercle. The two heads of biceps femoris attach on the head of fibula and lateral condyle of the tibia. The popliteus muscle runs from the lateral femoral condyle to the postero-medial edge of the tibia. Its insertion is an important stabilizer of the posterior third of the lateral capsular ligament. The fibular collateral ligament crosses over the lateral capsular ligaments. In a similar fashion of the medial meniscus, the lateral capsular ligaments attach to the lateral meniscus and are divided into meniscomfemoral and meniscotibial sections of the lateral capsule. There is little static support from the anterior third of the lateral capsule. The anterolateral rotatory instability is prevented by the middle third of the lateral capsular ligaments. The arcuate complex supports the posterior lateral third of the lateral compartment. It is a group of: fibular collateral ligament, the popliteus tendon, the posterior third of the capsular ligament, and the arcuate ligament. The lateral meniscus is more semicircular and covers a greater surface on the tibial plateau. The meniscus is thick at its periphery and thin centrally. In 5% of patients discoid variants of the lateral meniscus can be seen and cover much of the lateral tibial plateau. The area that permits the popliteal tendon to run posterolaterally to the posterior insertion of the lateral meniscus is called the popliteal hiatus. The lateral meniscus, other than bony attachments, is connected to the knee capsule except in the area of the popliteal hiatus. Its capsular attachments are less well developed compared with the medial side, allowing for more motion of the meniscus with knee flexion-extension. [10]

### 3.4 BLOOD SUPPLY

Blood vessels could be found in the peripheral third of the menisci around the 22nd week of gestation. Perinatally, almost the whole meniscus is vascularized. In the second year of life, an area of the central part of the meniscus becomes avascular. Lateral and medial geniculate arteries provide the vascular supply to the menisci where they form a perimeniscal plexus with radial branches coursing towards the center of the joint. [11] How the geniculate arteries branch and supply the vascular zone was described by Arnoczky and Warren [12] who were the first to describe the perfusion of both menisci. They showed that the peripheral 20% to 30% medial meniscus and the peripheral 10% to 25% lateral are vascular. Synovial diffusion makes possible the nourishment of the avascular inner one-third of the menisci. The middle one-third of the menisci may have blood supply; however, most of the nourishment is likely to come from the synovial fluid. The healing is enhanced in the vascular regions, thus it has great clinical significance in meniscal repair surgery. [12, 13] The zones of the meniscus are classified by their vascularization. In this classification the vascularized, peripheral zone is called the red-red zone. The central, avascular part of the meniscus is referred to the white-white zone. Since the zone is deficient of a blood supply, the tears in this area are less likely to heal. The area between the red-red and the white-white zones is referred to as the red-white zone. It has a less predictable pattern of healing and depends on the vascularization and synovial fluid nourishment.[9]

#### 4. EPIDEMIOLOGY

Researchers found that the mean annual incidence of meniscal tears is about 60–70 per 100,000, with a male to female ratio ranging from 2.5:1 to 4:1. Meniscal pathology in younger patients is likely to be consequent to an acute traumatic event, while degenerative changes are more frequent at an older age. More than one third of all meniscal tears are associated with an anterior cruciate ligament injury, with a peak incidence in men aged 21–30 years and in girls and women aged 11–20 years. In the other spectrum, degenerative types of meniscal tears commonly occur in men aged between 40 and 60 years. [14]

In Copenhagen all the openly operated on meniscal lesions of the knee joint between 1982 and 1984 inclusive were reviewed. The mean annual incidence of meniscal lesions per 10,000 inhabitants was 9.0 in males and 4.2 in females. The highest incidences were seen in the 3rd, 4th, and 5th decades of life. Men have been found to have a higher trauma related frequency related to onset of symptoms (77%) compared to women (64%). Bucket-handle tear was most common in men (35%), where in women peripheral detachment was most frequently found (41%). A variable frequency of trauma inducing the lesions in males and females did not explain differences in type of meniscal lesion. [15]

Meniscus tears do not always occur in isolation. A study Poehling et al. found that one third of patients with an anterior cruciate ligament (ACL) injury had a meniscus tear as well. In the subset of patients with an acute ACL tear, the lateral meniscus is more commonly injured. This is likely due to anterolateral rotatory translation of the tibia at the time of injury, which puts the lateral meniscus at risk. In contrast, medial meniscus tears are more common in patients with chronic ACL tears. This may be attributed to the function of the medial meniscus as a secondary restraint to anteroposterior translation of the tibia. Increased stress is therefore placed on the medial meniscus in an ACL - deficient knee. Other injuries associated with meniscus tears include tibial plateau fractures and femoral shaft fractures.[1]



## 5. STRUCTURE AND BIOMECHANICS

The inner structure of the meniscus is directly connected to their function. [9] The main building scaffold of the menisci are collagen (mainly type 1), proteoglycans combined with the shock absorptive force of water create the meniscus ideal functional performance.[14] Two well differentiated regions of the menisci have been identified. The inner region covers two thirds of the central meniscus and contains collagen bundles in a primarily radial orientation parallel to the articular surface. The outer region covers one third of the peripheral meniscus and contains larger and circumferential fibers. Research has found the tensile strength of the radial fibers to be 1.7-3.6 MPa, while that of the circumferential is 80-125 MPa. The surface layer contains collagen bundles in a random orientation with a composition that resembles articular hyaline cartilage.[9] The collagenous fibers allow hoop stress resistance by the circumferential fibers and resistance to shear forces by radially oriented fibers. [14] As the meniscus is burdened in weight bearing, the meniscus fibers elongate while being pushed to the periphery.[16] The meniscus plays an important role in the knee function and its preservation, if possible is preferred in meniscal tear treatment. [9]

Table 1: Biochemical comparison of connective tissues. Collagen, proteoglycan, and elastin components are presented as percentage of dry tissue weight

	Meniscus [112]	Cartilage [61]	Invertebral disk [61]		Tendon [157]	Ligament [157]
			Annulus	Nucleus		
Water	70-78	65-80	78	85	65-70	65-70
Collagen	60-90 Type I	65-75 Type II	66 Type I & II	25 Type II	75-80 Type I	75-80 Type I
Proteoglycan	1.3-3.4	20	15-25	50	1-1.5	1-3
Elastin	<1	-	-	-	<3	<5

[17]

Understanding of gross and microanatomic characteristics which allow normal meniscal function is of essential importance in treatment of meniscal injury. By maintenance of its structural integrity it is possible to attain better load bearing, shock absorption, joint lubrication and joint stability.[18] The menisci carry great significance in the tibio-femoral load transmission, joint stability and proprioception as well as decrease contact stress and increase contact area and congruity of the knee. Motion adaptation is made between the

femoral and tibial articular surfaces in all knee flexion and rotation angles, since the menisci follow the motion of the opposing joint surfaces.[14] This meniscal function is made by the combination of material, geometry and attachments of the knee.[9] The Ahmed and Burke [19] showed that at full extension 50% of the forces across the knee are relieved by the menisci. At 90 degrees flexion, this figure increases to 85%. The strong attachments to the anterior and posterior entheses provide the load distributing function and prevent menisci from extruding from the joint during axial loading. High water content (74% of total weight of the meniscus) significantly contributes to joint lubrication and allows compressive force decrease by release of the water content into the joint space, assuring smooth gliding of the joint surfaces. Anterior tibial displacement is prevented by the menisci, therefore they act as secondary soft tissue restraints. The biomechanical changes have been presented in numerous studies. [14] The high stresses in post-meniscectomized knees create clinical changes. Fairbank first described the radiographic changes later confirmed in a study by Roos et al. [20]

Table 2: Classification (in percentages) of 1,215 lesions according to sex and trauma

Types of lesion	Bucket-handle	Peripheral	Horizontal	Parrot-beak	Contusion	Others	Total
Males	35**	31*	2.5	14	4.0	14	100
Females	21**	41*	3.0	12	7.0	16	100
Traumatic	35**	34	2.2	12	3.5	13	100
Nontraumatic	18**	35	3.7	15	8.8	20	100
All	30	34	2.6	13	4.9	15	100

\*\* $P < 0.001$ ; \* $P < 0.01$ .

[21]

## 6. MECHANISM AND PATHOLOGY OF THE INJURY

Activities of daily living, including squatting and deep knee flexion may produce meniscal tears in older patients. In the younger population, meniscal tears may occur as a consequence of twisting, cutting or hyperflexion injury. The meniscal injury of this age group is commonly associated to have ACL tear or tibial plateau fracture in conjunction.[22] Meniscal tears occur at different patient ages as well as different arthroscopic appearance. Bucket-handle tear is a tear propagating into the anterior horn. It can be unstable and often cause mechanical symptoms. With free body formation from a bucket-handle tear and displacement into the joint, there may be locking symptom may result. [1] Vertical longitudinal tears are associated with anterior cruciate ligament trauma and are more common in the medial meniscus, likely due to its firm attachments to the tibial plateau, capsule and deep medial collateral ligament. There is strong evidence, consistent in numerous case series studies that 70 to 90% of tears associated with acute ACL injuries are traumatic type tears - peripheral, longitudinal tears.[23] Oblique tears are occasionally referred to as flap or parrotbeak tears. They are most commonly found at the locus between the posterior and middle third of the meniscus and cause mechanical symptoms if the damaged part of the meniscus inserts between the femur and tibia [18]. Complex tears are commonly seen in older patients with degenerative knee changes. They mainly occur in the posterior horn and midportion of the body of the meniscus. The complex free fragments can lead to mechanical symptoms. [1, 16] Radial tears commonly occur at the junction of the posterior and middle thirds of the medial meniscus, middle third of the medial meniscus or at the posterior site of attachment of the lateral meniscus. Further peripheral propagation of the tear may cause loss of hoop stresses and lower the ability for meniscal load transmission.[1, 16, 18] Horizontal cleavage tears arise on the inner edge of the meniscus and radiate in a horizontal plane toward the periphery. They have an increasing occurrence with age and are associated with meniscal cysts.[18]

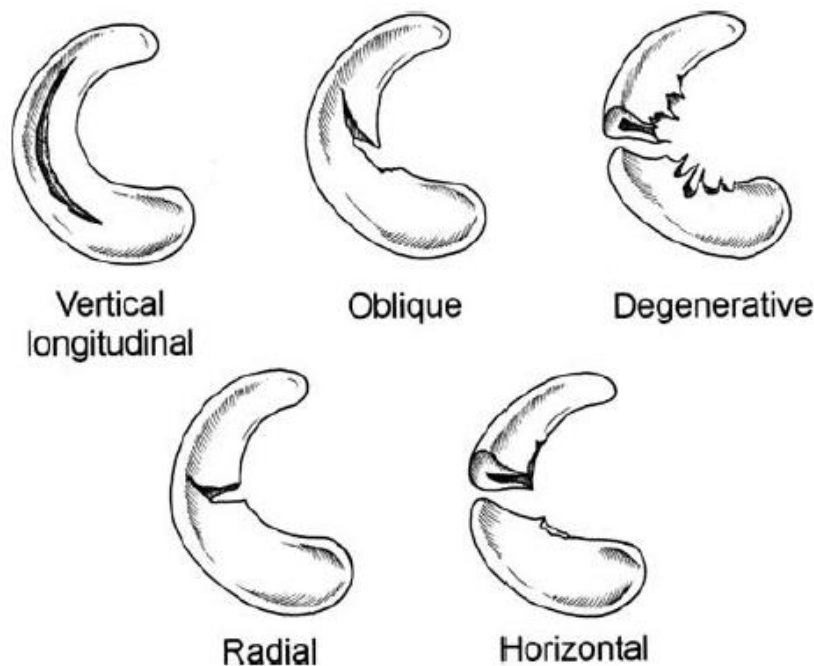


Figure 1: Classification of meniscal tears. [1, 24]

## 7. CLINICAL PICTURE AND DIAGNOSTICS

The patient with a meniscal injury presents with a swollen knee, pain or mechanical symptoms may require surgical intervention. The injury often occurs due to a rotational movement. It presents with sudden tearing sensation after squatting. Meniscal tears can also be associated with intermittent locking, snapping, or limitation of extension. Serous effusion and quadriceps atrophy are frequently associated with older meniscal lesions. These lesions can be associated with intermittent or constant block in knee extension. Acute tears are commonly occurring with acute trauma symptoms, hemarthrosis and possible capsuloligamentous injuries (torn collateral ligament, ruptured ACL). [25]

Knee examination begins with the inspection of the side where the traumatic event occurred. Evidence of effusion and quadriceps atrophy may be visible. The range of motion (ROM) should be evaluated next to see if there is a mechanical block in any position of flexion or extension of the knee joint. This should be followed by palpation of both medial and lateral joint lines to determine if tenderness or swelling are present associated with meniscal cyst. Integrity of the collateral and cruciate ligaments should be evaluated and ligamentous injury excluded. Joint-line palpation should be followed by specialized tests for eliciting symptoms

of a torn meniscus. Described maneuvers include McMurray test, the Apley grinding test and others.[1] Medial meniscopathy is indicated by positive McMurray test, Apley compression test, and the bounce home test [14]. The clinical evaluation, history and physical examination together with plain radiographs allow a diagnosis and indication for surgery. When the clinical findings are inconclusive, magnetic resonance can aid to confirm the clinical diagnosis.[18]

Radiographic imaging should be made in PA 45-degree flexion weight bearing of both knees, a lateral view image, followed by a sunrise view image. This radiographic imaging makes possible to evaluate joint spaces and bony structures.

Magnetic resonance imaging (MRI) is of great value in evaluation of a meniscus tear. MRI is accurate in diagnosis of meniscal tear and reported to be between 68% and 100% precise.[1] Tears are seen as high-grade signal areas within the substance of the meniscus. Radiologists use grading system to delineate these signal changes, with grade 0 being normal meniscus, grade 1 and 2 high signal intrameniscal areas that do not about the free meniscal edge, and grade 3 high signal area that tracks to the edge of the meniscus.[26] Grade 1 and 2 are rarely associated with arthroscopically visible findings.[9] Grade 3 changes are the only changes consistent with clinically significant meniscal tear and, for this reason, care must be used when interpreting MRI images and reports. Care must also be used when interpreting signal changes in a patient who has had previous meniscal surgery, as MRI is often unreliable in these cases. [26] Imaging techniques are a useful tool to engage in arthroscopic evaluation and examination which carries the final decision on operative treatment. During arthroscopic examination the final decision of treatment is made. The macroscopic appearance of the meniscus is observed (normal or degenerative). Zone of tear and type of tear are evaluated for determination of treatment with consideration of healing and prognosis.[9]

Table 3. Meniscus examination tests

<b>Finding/Test</b>	<b>Sensitivity</b>	<b>Specificity</b>
Joint Line Tenderness	71%	27%
McMurray	58.5%	93.4%
Apley	16%	80%
Thessaly 5°	66%Me, 81%La	96%Me, 91%La
Thessaly 20°	89%Me, 92%La	97%Me, 96%La
MRI	75-87%	87-93%

[27]

## 8. TREATMENT

When symptoms interfere with patients daily activities, such as sport participation or ability to work, treatment for a meniscus tear is undertaken. [1] Research has found a number of possible regenerative and surgical treatments for meniscal tear and degenerative changes but no single definitive. Among these are cell free scaffolds, gene therapy, biological glues for enhanced bonding of reparable tears, partial and total tissue engineered meniscus replacement. [28] Treatment is determined by the clinical and arthroscopic findings and the factors of the individual patient. The factors important for treatment evaluation in meniscal tears are: patient age, location of lesion, correlating the lesion with clinical findings, extent of lesion, concomitant cartilage damage and activity level.

### 8.1. CONSERVATIVE TREATMENT

Meniscal tears can present as asymptomatic, commonly found in elderly patients. Further, the symptoms of a meniscal tear may diminish or disappear with conservative treatment. The option of non-operative treatment should at least be discussed with the patient presenting with a meniscal tear. [1] A significant percentage of meniscal tear patients can be non-operatively treated. This is true for patients who do not experience: blocking of the knee joint, medicament non-responsive pain nor seemingly unstable meniscal lesions. These lesions are typically of partial thickness (under 5 mm), short radial tears (under 5 mm), and short full thickness vertical or oblique tears (under 5 mm). [28] The conservative treatment would include; modification of activity, anti-inflammatory medications and rehabilitation program. Patient with a full range of motion, especially an elderly patient, should be treated conservatively and evaluated for 3 months [22] if there are no mechanical symptoms[1]. The size of the tear and amount of displacement is inversely proportional to the chance of spontaneous healing of an acute injury and is impaired with concurrent ACL injury. Non-operative management is usually not recommended for athletes who wish to return to sports; over 90% of athletes with symptomatic tears are unable to due to recurrent symptoms. [22]

It has been found that quadriceps strengthening exercises produce a significant improvement and is a worthwhile recommendation for a non-operative treatment.[1]

## 8.2 OPERATIVE TREATMENT

Meniscus operations include meniscectomy, meniscal repair or meniscus transplantation. Meniscus tear pattern, geometry, site, vascularity, size, stability, tissue viability or quality and associated pathology are determining factors in decision of resection or repair of a meniscus lesion.[29] In the goal for better healing of the meniscal lesion, other methods of various complexities have also been suggested such as : needling, abrasion, trephination and gluing, synovial flaps, meniscal wrapping or application of fibrin clots.[28] Operative intervention is suggested in an active individual with acute injury and mechanical symptoms, without presence of degenerative changes. [1] In children and very young patients meniscal repair should be attempted. Extensive meniscal resection would benefit more the older patients, especially the ones with a medial meniscal lesion.[25] Elderly patients with an early cartilaginous degenerative change, who recollect a traumatic event associated with a mechanical symptoms are candidates for early surgical intervention.[1] Evaluating the location of the lesion shows important when there is a lateral meniscus lesion, due to greater necessity of preservation of the meniscus on the lateral side. Extensive resection of the lateral meniscus invariably leads to lateral compartment osteoarthritis. Importance of size or extent of meniscal lesion is noticeable when a lesion is larger than 1.5 cm. It is suggested that extensive tears be resected or repaired. [25]

### 8.2.1. MENISCECTOMY

For years in early meniscal surgery history, total meniscectomy was the golden standard. Research has later proven that total or subtotal meniscus excision ultimately leads to osteoarthritic changes 5-10 years after surgery. Ever since, it was advocated to preserve the maximal amount of meniscal tissue. [30] The resection of the meniscus is the most frequently performed arthroscopic procedure. It consists of removal of unstable, torn, degenerative, or heavily scarred areas of the meniscus. [25] Meniscal stability is an important factor to be determined. The tear is considered stable if it is of partial thickness, under 1 cm in length, or if the central part of the vertical tear cannot be displaced for more than 3mm from the intact



peripheral rim.[1] The wall of the meniscus alone decreases the forces transmitted from the femur to the tibia by more than 50% [31] Adequate arthroscopic resection became a „gold standard“.[9] Upon arthroscopy, meniscal examination is performed.

The meniscus is divided into anterior, middle (body) and posterior parts. With the anteromedial view, the meniscus should be palpated on its superior and inferior surface by a probe. The probe allows visualization of small tears but should be done gently, because vigorous manipulation may cause damage to the surrounding structures. A meniscal tear might be found incidentally during arthroscopy. These tears at times might be left untreated. [1] It has been suggested that nonpainful and nondisplaced meniscal tears should not be an indication for meniscectomy as retention of a torn meniscus did not have a harmful effect on the magnitude or distribution of the stresses in the knee.[32] Through the recent decades it has become noticeable how the meniscal excision affects the cartilage degeneration. Degenerative changes are found to be directly proportional to the amount of meniscus removed. Partial meniscectomy also results in increased stress when compared to a normal knee.[33]

Seedhom and Hargreaves have shown in an vitro study how removal of 16% to 34% of the meniscus results in a 350% increase in contact forces.[34] Therefore it has been suggested for the meniscal tissue removal to be minimized, repaired or replaced [33, 35] Clearly unstable incidental tears should, however, be treated with either repair or partial meniscectomy as indicated. [1] Other results after partial and total medial meniscectomy have also been reported. Partial medial meniscectomy has shown to decrease the contact area by 10% to 20% while increasing the contact forces by 40% to 70%. Complete meniscectomy lowers the contact surface by 40% to 75% with a force increase by 136% to 236% [19].

The high stresses in post-meniscectomized knees create clinical changes. Fairbank first described the radiographic changes in such postoperative knees. In a study of 107 post-total meniscectomy patients Roos et al. [20] confirmed these changes. The compromise for degenerative changes of the knee cartilage was significant. Cicuttini et al.[36] reported in the partial meniscectomy study a quantification of cartilaginous changes of 6.9% per year of cartilage loss increase in comparison to control knees. In long term follow-up studies it has been proven that a great number of meniscetomized knees have later developed arthritic changes. Arthritic changes in the studies have been shown to increase proportional to the amount of meniscal tissue removed. The resulting increase in contact stresses on the tibial plateau is regarded as the main reason for the frequent bone and cartilage changes found after meniscectomy. The stress distribution on a smaller area causes an increase in the trabecular

bone density in the proximal tibia, eventually leading to joint degeneration. [14] After total meniscectomy the shock-absorbing capacity has been found to decrease by 20%. A study was performed from 1973 to 1982 and reviewed all meniscectomized patients in Syracuse, New York. 61 meniscectomies were performed per 100,000 people. It has been found that men had 3 times higher affection than women. Medial meniscus injury was 81% versus lateral meniscus of 19%. [37] The unoperated knee was used as control. Radiographs showed only 0.23 grades worsening of the control knee. The radiographs of male patients gained better results than female, but not better functional scores. Medial and lateral meniscus was not significantly different. It has been shown that 88% of good and excellent results were obtained in anterior cruciate ligament stable knees. [38] The conclusions of recent randomized trials show the similarity of results between arthroscopically operated knees and knees that underwent sham surgery. Clinical evidence shows lack of efficacy for patients with knee osteoarthritis, including the patients with meniscus tears. A trial by evaluated by WOMET and Lysholm scores (primarily descriptive of daily living activities and perhaps inadequate to high level function) has extended to evaluate the meniscus tears treatment in knees without established osteoarthritis and found insignificant difference in the results of arthroscopic debridement and nonoperative treatment. [39] In a study by Kirkley 86 patients underwent surgery while the other 86 patients received only physical and medical therapy. The study concluded that arthroscopic surgery for osteoarthritis of the knee provided no additional benefit to optimized physical and medical therapy. [40] Previously it has been shown how arthroscopic debridement (AD) on the osteoarthritic knee may benefit the patient, but other recent studies have yielded conflicting results that suggest AD may not be effective. [41]

## 8.2.2 MENISCAL REPAIR

Meniscal repair is an arthroscopic procedure with origins in open surgery. [14] Meniscus repair has first been reported by Annandale, but due to lack of interest at the time was yet later to gain the deserved significance [42]. The first arthroscopic meniscus repair was by Ikeuchi in 1969[9]. Meniscal repair has shown to be successful in 70-80% of cases when correctly indicated. The French Arthroscopic Society (FSA) has shown by research that the repair is possible in a great minority of situations, not exceeding 3-5% limit. This suggests that there is space for constantly evolving surgical techniques to become less invasive, safer and easier to use. [9] The evolution of meniscal repair started in 1989 when Kohn and Siebert made a study on the biomechanical basis of meniscus repair. Second-generation devices show improvement in the basis of invasiveness, but have not achieved the biomechanical properties of the „golden standard“. In the 90s and first decade of this 21st century second and third-generation devices were presented. Third-generation flexible anchors, due to more complex criteria set by introduction of cyclic loading, allowed minimal invasiveness and biomechanical properties and stand together with all inside suture techniques as the first choice of meniscal repair techniques. [14] In 1998 Rubman and colleagues showed great results in a study of 198 knees where 159 (80%) of knees after repair presented with no symptoms at the follow-up.[43]

Meniscus repair is indicated when it is necessary to repair the main substance – vertical tear types in posterior horns or bucket-handle tears. [9] Horizontal cleavage and flap tears are generally not repairable. In the middle portion of the meniscus radial tears contain a poor healing potential. [44] Repair of the former is considered for delamination of the mid-segment of the lateral meniscus often in conjunction with meniscal cyst debridement. Peripheral tears are less frequent, more difficult to diagnose and often over-looked. Meniscal root tears are rare and cause an inability for a meniscus to translate forces, such like that of total meniscectomy. [9] Comparison study was made of meniscal repair and partial meniscectomy (partial meniscal resection). It has concluded that arthroscopic meniscal repair gives significantly improved results for isolated traumatic meniscal tears in regards to the long-term follow-up in osteoarthritis prophylaxis and sports activity recovery compared with partial meniscectomy. Eighty-one patients (repair: n = 42; meniscectomy: n = 39) were examined clinically (Lysholm score, Tegner score) and radiologically (Fairbank score, compared with

the uninjured knee). They were followed in midterm (3.4 years; n = 35) and long term (8.8 years; n = 46) and the latter shows that no osteoarthritic progress was detectable in 80.8% after repair in comparison with 40.0% after meniscectomy with significant benefit for the “young” subgroup. [45] Meniscal repair is best reserved for a young patient with meniscal pathology of a recent vertical tear within 3-4 mm from the peripheral edge and 1-2 cm in length inside of a stable or stabilized knee. [9] Similar results were found by a Croatian study when the „all inside" technique was applied with the use of intra-articular bioresorptive pins-Darts sticks or Meniscus Viper and bioresorptive string. The follow up was performed 2-6 months postoperatively and evaluated by the IKDC 2000 score and showed satisfactory results. [46]

Various techniques have been developed throughout the recent years of which selection depends on: lesion location, type, possible repair stability, operation time, instrumentation, costs and operator preference. Numerous studies have analyzed the stated factors and have concluded that a repair technique should have strong but not damaging affect, be applicable to a variety of tears, to be faster than meniscectomy, simplified, low cost and used by a single operator, have a good approximation with reversible fixation and minimal space occupation. [25] Some surgical principles have to be followed and are independent of the technique such as proper arthroscopic set-up and in-operation steps. Arthroscopic set up placed when the patient is in a supine position and regional or general anesthesia is induced. Anterolateral and anteromedial portals are established. The posterior part of the medial meniscus is made by inducing slight flexion in the knee and applying valgus stress. Posterior part of the lateral meniscus is by 90 degree flexion and applying varus stress in the Cabaud position. For removal of the fibrous tissue, debridement using a basket punch, a rasp, or a shaver is performed on the walls of the tear. Freshening is done on the outer part of the meniscus to promote healing and conserve meniscal tissue in zones of lesser healing. Techniques can be used to promote healing such as multiple needle perforations in the meniscal rim to induce bleeding through vascular channels. It is important to avoid gaps of more than 3-5mm with non-absorbable or slowly absorbable sutures. Bucket-handle tears require reducibility assessment due to the tendency of shrinkage which poses a threat of re-dislocation after reduction.[9]

The modern techniques of today are: all-inside technique, inside-out technique and outside-in technique. The methods have been scientifically evaluated of low complication by the AANA (Arthroscopy Association of North America) and SFA (French Arthroscopy Society). The complication rates are described as low as 1.8%.

Table 3. Indicative factors

Criterion	Repair	Ptl. Meniscectomy
Distance from rim	<3mm	>3mm
Mobility of fragment	Stable	Mobile
Age of injury	Recent	Old
Ret. To Play	Later	Sooner
Age of patient	Younger	Older

### 8.2.3. ALL-INSIDE TECHNIQUE

Most advantageous method today for repairable meniscal lesions seems to be all-inside fixation.[28] These specific implants are considered third and fourth generation devices. The third generation methods are performed by using the instruments like staples, tacks, anchors, screws etc. They are mostly bioabsorbable and composed of rigid poly-L-lactic acid (PLLA).

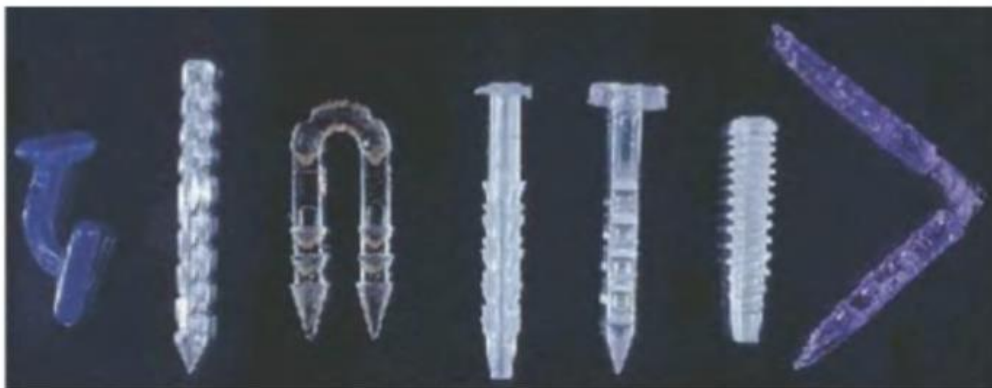

Figure 2: Meniscal repair devices. From left to right: J Fast, Dart, Biomet staple, BioStinger, Meniscus arrow, Clearfix screw and Sdsirb meniscal staple.

The method was first published by Albrecht-Olsen et al. using a bioabsorbable tack (Biofix meniscal arrow). [47] The implant with a T shaped arrow which penetrates the meniscus and its distal part is attached to distal meniscus and the „ T “head is applied to the axial part of the meniscus, commonly the superior surface. It is performed by inserting a cannula with the obturator through the common arthroscopic portals. The obturator is removed when the cannula is in its place. The meniscus is punctured by the perforator. At this point the needle is removed and the arrow is pushed through the cannula and hammered into its desired location in the meniscus. This allows the fixation of the axial meniscal fragment as it is attached to its peripheral counterpart. This procedure is repeated every 5 minutes and a gun may be used to decrease the operation time. [9] The procedure creates a possibility for an arthroscopist to place fixation of the meniscus without the risk to a nerve, vessel or posterior capsular entrapment found in both the „outside-in“and the „inside-out“technique. [48] The disadvantages of this method are the lower strength of the arrows in comparison to vertical sutures. Also it poses a threat of loose bodies, synovitis, cysts, and cartilage abrasion due to the head of the device at the surface of the meniscus.[9]

The „fourth generation“all-inside methods is a technique combining the suture techniques and third generation all-inside meniscal repair. These devices are self-adjusting and have many advantages. The principle is a combination of using an anchor behind the meniscus and a suture sliding knot compresses the axial meniscal part. [9] It is made possible by the introduction of new instrumentation which allows the surgeon to insert and tie the suture vertical knots under arthroscopic management. [48] The undesirable effects associated with these implants are the potential ability of deformation and movement during weight bearing and risk of chondral abrasion. [9] The anatomic proximity of the popliteal artery suggests possible damage of this structure. A penetration limiter is found to be a good preventive mechanism for the damage to the popliteal artery.[49] Also appropriate needle length and contralateral portal access allows a safer all-inside repair. Detection of vascular injury is essential and unusual, early pain must be noticed. Residual pain may also be caused by soft tissue injury. The development of all-inside meniscal repair lead to meniscal implants that are prone to fragmentation, formation of foreign body reaction leading to aseptic synovitis. Removal of the fragments and implants may be indicated. Some of the implants may lead to chondral damage and chondral grooving and are in contrast with the result of nearly 0% rate of chondral damage when using all inside suturing devices. Other complications may

be local irritation, implant breakage, foreign body reaction, cystic hematoma formation, and synovial cyst formation. To avoid complications the orthopedic surgeon must be an expert in method of repair as well as to know the complication of all inside devices. [9]

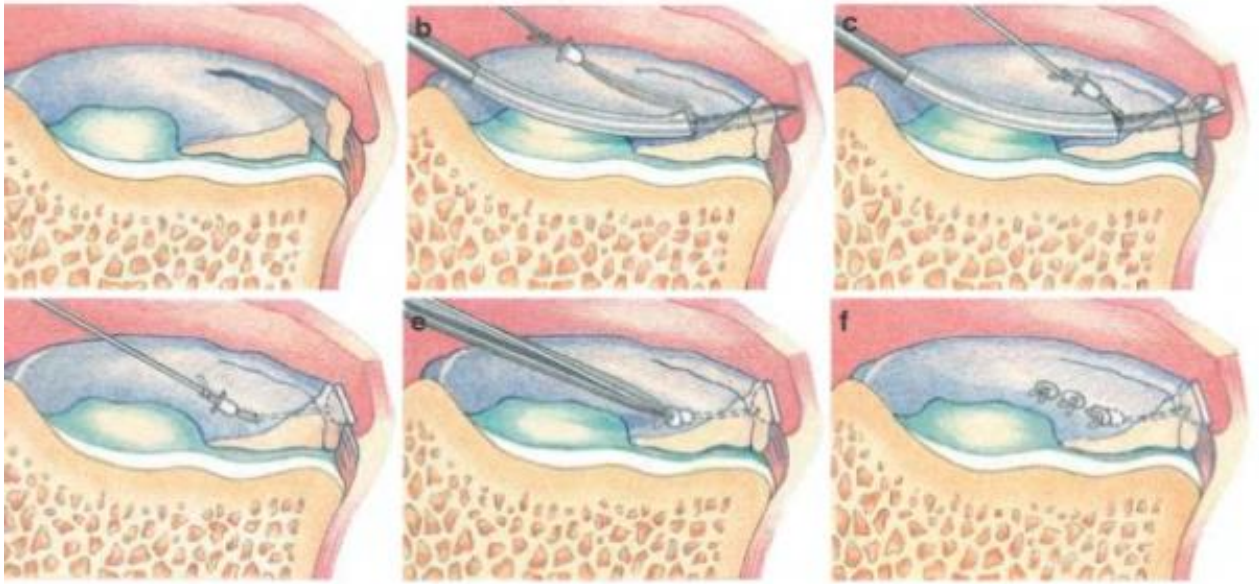


Figure 3. RapidLoc example of all-inside technique

#### 8.2.4. INSIDE-OUT TECHNIQUE

Inside-out repair method is best applicable to tears of the posterior horn, middle third, peripheral capsule, or with bucket handle tears. [1] The inside-out technique has previously been the gold standard for meniscal repair. Current generations of all-inside repair have a comparable result in most tears. [50] Inside-out method allows passing of sutures through cannulas to exit through strategically placed posterolateral or posteromedial accessory incision. The incisions are made prior to the passage to protect the neurovascular structures.[1] Inside –out technique consist of placement sutures on the meniscus inside the knee joint to be tied outside the joint capsule. [33] It is possible to perform using systems of long curved single or double-barrel cannulas. The sutures (absorbable or non-absorbable) of sizes 2-0 or 0 are guided from the inside to the outside to form vertical or horizontal mattress stitches. Through

the extra-articular posteromedial or posterolateral incision the sutures are then retrieved. The knots are tied externally and over the joint capsule. In this technique a large retractor is used to protect the neurovascular structures. [9]

The preparation for medial meniscus arthroscopic approach is as been described earlier. Patient is placed in the supine position, the knee is flexed, and the anteromedial and anterolateral ports are created. Additional ports may be made for more demanding posterior tears to enhance angles of cannula placement. To allow instrument passage the fat pad may require removal. The next step is debridement of granulation tissue of the meniscus, crucial for maximizing the healing response. Rasping or shaving the perimeniscal synovium increases vascular infiltration and contributes to meniscal healing response. [9, 50] After tear preparation, a posteromedial incision is made allowing needles to pass through the capsule. The knee is set in position of 20-30 degrees when the passage of the needle through the medial compartment is performed. The posteromedial incision is 4- to 6- cm and made just posterior to the medial collateral ligament, with one third over and two thirds below the joint line.

Dissection is further made anteriorly to the sartorius and semimembranosus musculature. Saphenous nerve in this moment is protected by the sartorius muscle and the flexed knee position. The deep dissection is created medially to the head of gastrocnemius, with an interval between posteromedial capsule and gastrocnemius may be developed. Exposure of the capsule allows placement of the popliteal retractor which allows better visualization and deflection of the exiting suture needles. Single-loaded or double-loaded 2-0 or 0 nonabsorbable suture needles are passed through the cannula to puncture the meniscus superiorly and inferiorly to the tear location to perform vertical mattress sutures. When both needles are passed sutures are put under tension while observing the arthroscopic image. The sutures are placed every 4-5 mm until stability is satisfactory. [1]

In the lateral meniscus approach the patient is in supine orientation, and 90 degree flexion is performed when entering the lateral compartment, for the peroneal nerve, popliteus, and lateral inferior geniculate artery to fall posteriorly. The inside-out repair of the lateral meniscus has a different posterior incision than the medial meniscus repair surgery. It is a 4- to 6- cm incision just posterior of the lateral collateral ligament, with one third superiorly and two thirds inferiorly of the joint line. Superficial dissection is between the iliotibial band posteriorly (with anterior traction) and biceps tendon complex (with posterior traction). Deep dissection is anterior to the lateral gastrocnemius head, while it's being retracted posteriorly for peroneal nerve protection.[1]



The side-effects of the treatment may involve unsuccessful healing, recurrent tears, infection, saphenous nerve and peroneal nerve injury, popliteal vessel injury, stiffness contracture or complex regional pain syndrome. A study on cadaveric limbs examined the anatomical significance of lateral meniscus repair with the inside-out and the outside-in methods. Computerized axial tomography (CAT) was then used to establish the proximity of the needles to the peroneal nerve. The inside-out needles were found to be compromising to unity of the peroneal nerve.[51] Other negative aspects of inside-out technique may be increased surgical time, postoperative pain and needle stick injury to the surgical team, what is less frequently seen with the all inside technique. [50]

Table 4.  
Indications, Contraindications, Risks, Tips, and Pitfalls of Inside-Out Technique

Indications	Similar to other meniscus repair indications Repairable tears involving posterior horn and body of meniscus
Contraindications	Degenerative tears with minimal healing capacity
Risks	Unsuccessful healing Recurrent tears Infection Saphenous nerve and peroneal nerve injury Popliteal vessel injury Stiffness contracture Complex regional pain syndrome
Pitfalls	Improper anatomic interval identification and retractor placement Neurovascular injury

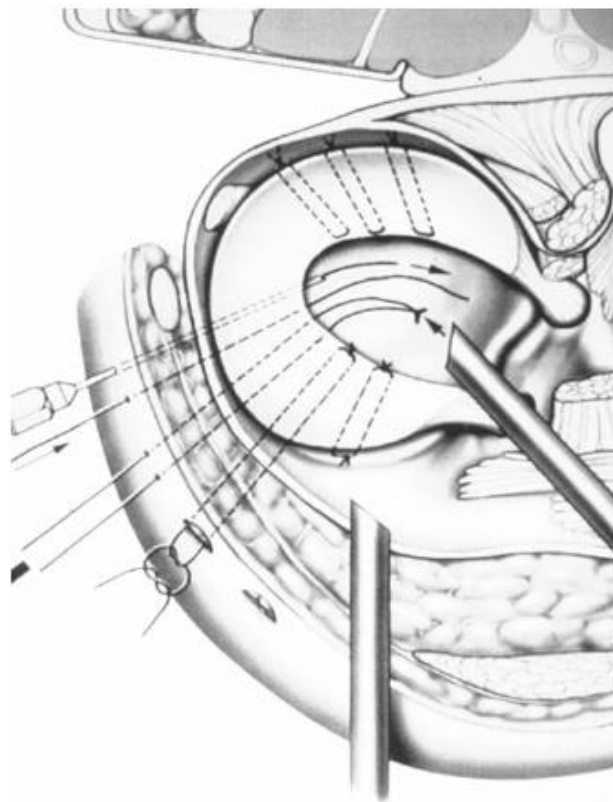
#### 8.2.5. OUTSIDE-IN TECHNIQUE

This technique was first described by Warren in 1985. [52] The surgeon uses an 18-gauge spinal needle and passes it from the outside-in. Once the needle is visible, the thread is then passed and pulled into the knee joint through the ipsilateral portal. An interference knot is then tied in the end of the suture and the thread is pulled back. The process is repeated and the thread is tied in pairs over the capsule until the tear is stabilized. The quality of the technique

is easy anterior accessibility. [9] Another advantage of this technique is a low risk of neurovascular injury, due to needle placement through the capsule. The disadvantage is a relative possibility of imprecise suture placement. [53] Outside-in repairs show success but are limited to the anterior portions of both medial and lateral menisci.[16] Morgan and Casscells have conducted a study with the outside-in repair and had excellent results (98.6% of 70 patients) with the patients on follow up 12-28 months.

Good anatomical knowledge of the surgeon and attention to the surgical technique and local anatomy prevents the event of complications. During needle passage or suture formation on the medial side, saphenous nerve may be damaged. Peroneal nerve injury is avoided by lower leg manipulation and flexion in 90 degrees. Other complication that needs to be addressed is infection that necessitates early aggressive treatment. Less common are limitation of extension due to posterior capsule entrapment, failure of healing due to e.g. inadequate vascularity, degenerative tissue or knee instability. Selection of patient and the applicable technique, as well as support and postoperative rehabilitation is important in minimizing operation failure. [54]

Figure 5. Outside-In Meniscal Repair: The arthroscopic outside-in surgical technique involves the placement of a suture to one side of the meniscus tear inside the joint and then sutures are tied on the joint capsule.



### 8.3. MENISCAL TRANSPLANT

After (sub)total meniscectomy the OA changes increase peak stresses and stress concentration on the articular cartilage and the inability for complete knee function becomes apparent. The lateral meniscus has a higher role in shock absorption when compared to the medial and thus a greater chance for OA when the lateral meniscectomy is performed. The changes are proportional to the amount of meniscus removed. In young patients with postmeniscectomy pain with no significant degeneration of the cartilage and an age contraindication for a arthroplasty – meniscal transplantation poses an option for treatment.[55] Other contraindications include diffuse subchondral bone damage, axial malalignment, and instability. If certain restoration procedures such as chondral resurfacing, osteotomy and ligament reconstruction are applied to correct the contraindications, meniscus transplantation may be possible.[56] In these cases meniscal transplant can be the best option, especially for the lateral knee compartment.

The indications by the European Meniscal Transplantation Group (EMTG) include:

a) disabling compartmental pain after a (sub)total meniscectomy b) the patient is under 50 years of age c) the knee must have natural alignment d) the joint must be stable or stabilized by concomitant anterior cruciate ligament (ACL) reconstruction e) the articular cartilage must not be severely deteriorated. The most commonly used types of grafts are cryopreserved or fresh meniscal allografts. Artificial meniscal prosthesis hold great potential for the future and the research is ongoing.[55] Deep-frozen cryopreserved and viable allografts have shown to provide 70% of satisfactory results in regards to stability.[9]

The fixation of the allograft is made by using bone plugs, bone bridges or bone tunnels. [57] The method of using bone plugs is very complex, while the remaining two are technically less difficult. Meniscal transplantation surgeries are performed arthroscopically. The anterior horn is fixated by a bone anchor into its anatomical locus, while the posterior horn is fixed through a 4 mm tunnel and eventually fixed by a bone anchor into the tibia. The allograft is the sutured in the inside-out technique to the capsule. This way the meniscus is places into its original position. Evaluation of meniscal allograft transplantation (MAT) is one of the treatment options for patients experiencing postmeniscectomy pain. With this in mind, researchers found improvement in the knee function, and good patient satisfaction if performed in the optimal candidate. On both subjective and objective evaluation improvement

has been found in patients without significant chondromalacia as a part of treatment for cartilage defects, limb malalignment, or knee instability. Medial and lateral meniscal allograft transplants showed no significant difference. Also, no significant difference was found in isolated MAT when compared to MAT performed with concomitant procedures. [58] Results validate that a percentage number of patients has excellent results. In the study of Yoldas E.A. [59] it was shown that twenty two of thirty one patients greatly improved, while eight slightly improved and one had no change. The average hop and vertical jump indices were both 85% of the contralateral extremity showing restoration of high level function in the MAT operated knee joint.

The current downside of the technique is that of it being a relative novelty in the field of surgery and studies claim of the necessity for generally more experimental and clinical data in the field of meniscal transplant. [60]

## 10. CONCLUSION

Physical examination and patient history have been improved by technological advancements. The question at hand is to evaluate each patient individually and create a treatment plan with one's experience and need. Arthroscopy has become a part of the standardly used therapeutic treatment technique, while at first was merely a diagnostic procedure. As the technique advanced, what sometimes used to be considered a part of the same pathology now became obvious to benefit from different and more challenging approaches. The meniscus is no longer considered a „vestigial" structure and as Eugen Bircher anticipated, arthroscopy received vast the popularity as the most commonly performed orthopedic procedure. As the arthroscope is a widely used tool in orthopedic surgery, there is a vast number of techniques leading to the need for re-education and further perpetuation of knowledge and skill of even the most adept arthroscopists.

Long-term results define the importance of the health of both menisci and ligamentous structures in the role for providing integrity of a stable, and weight bearing knee joint. Combined lesions have as well recently gained significant attention and been recognized in importance for preservation of the knee from secondary changes. Meniscal repair techniques allow diverse surgical tear treatment approaches depending on the complexity and location. The gold standard fourth-generation meniscal repair, inside-out, and outside-in are all techniques used in certain indications and the ultimate goal is to achieve strong repair. Many studies have concluded that arthroscopic meniscal repair gives significantly improved results for isolated traumatic meniscal tears in regards to the long-term follow-up in osteoarthritis prophylaxis and sports activity recovery compared with partial meniscectomy but are not applicable in such a wide pathological palette. The „slippery slope“ or dramatic resection with potential ligamentous instability may require an alternative treatment.

The successful and valuable has proved to be meniscal transplant surgery with cryopreserved and viable allograft transplant. Unfortunately, the case studies are low in numbers and these methods and techniques require further exploration, while holding great potential for withholding great stress, physiological strain and bearing loads in a meniscectomized knee. It is expected in the future, the use of meniscal allografts will probably be superseded by the development of artificial or tissue engineered meniscal replacements due to already potential demonstrated collagen-meniscus implants and polyurethane scaffolds.

1. McKeon, B.P.B.J.V.R.J.C. *Knee arthroscopy*. 2009; Available from: <http://dx.doi.org/10.1007/978-0-387-89504-8>.
2. Morgenthal, C.B., et al., *The role of the surgeon in the evolution of flexible endoscopy*. *Surg Endosc*, 2007. **21**(6): p. 838-53.
3. Rauschmann, M.A., et al., [*History of meniscus surgery. From excision of joint loose bodies to meniscus suture*]. *Orthopade*, 2000. **29**(12): p. 1044-54.
4. Nezhat Camran, M. *Nezhat's History of Endoscopy*. 2005; Available from: <http://laparoscopy.blogs.com/endoscopyhistory/>.
5. Kieser, C.W. and R.W. Jackson, *Severin Nordentoft: The first arthroscopist*. *Arthroscopy*, 2001. **17**(5): p. 532-5.
6. Henche, H.R., *Arthroscopy of The Knee Joint*. 1980.
7. Kieser, C.W. and R.W. Jackson, *Eugen Bircher (1882-1956) the first knee surgeon to use diagnostic arthroscopy*. *Arthroscopy*, 2003. **19**(7): p. 771-6.
8. Watanabe, M., S. Takeda, and H. Ikeuchi, *Atlas of arthroscopy*. 1979: Igaku-Shoin.
9. Beaufils, P. and R. Verdonk, *The meniscus*. 2010: Springer.
10. Blackburn, T.A. and E. Craig, *Knee Anatomy: A Brief Review*. *Physical Therapy*, 1980. **60**(12): p. 1556-1560.
11. Messner, K. and J. Gao, *The menisci of the knee joint. Anatomical and functional characteristics, and a rationale for clinical treatment*. *Journal of anatomy*, 1998. **193**(2): p. 161-178.
12. Arnoczky, S.P. and R.F. Warren, *Microvasculature of the human meniscus*. *Am J Sports Med*, 1982. **10**(2): p. 90-5.
13. DeHaven, K.E. and S.P. Arnoczky, *Meniscus repair: basic science, indications for repair, and open repair*. *Instr Course Lect*, 1994. **43**: p. 65-76.
14. Maffulli, N., et al., *Meniscal tears*. *Open Access J Sports Med*, 2010. **1**: p. 45-54.
15. Hede, A., et al., *Epidemiology of meniscal lesions in the knee: 1,215 open operations in Copenhagen 1982-84*. *Acta Orthopaedica*, 1990. **61**(5): p. 435-437.
16. Seddek, S. and T. Andrew, *Meniscal injuries: evaluation and management—current*.
17. Brown, G.A., *Load-bearing role of the human knee meniscus*. 1990, Massachusetts Institute of Technology.
18. Greis, P.E., et al., *Meniscal injury: I. Basic science and evaluation*. *J Am Acad Orthop Surg*, 2002. **10**(3): p. 168-76.
19. Ahmed, A.M. and D.L. Burke, *In-vitro measurement of static pressure distribution in synovial joints--Part I: Tibial surface of the knee*. *J Biomech Eng*, 1983. **105**(3): p. 216-25.
20. Roos, H., et al., *Knee osteoarthritis after meniscectomy: prevalence of radiographic changes after twenty-one years, compared with matched controls*. *Arthritis Rheum*, 1998. **41**(4): p. 687-93.
21. Hede, A., et al., *Epidemiology of meniscal lesions in the knee. 1,215 open operations in Copenhagen 1982-84*. *Acta Orthop Scand*, 1990. **61**(5): p. 435-7.
22. Miller, M.D.M.C.B.J.M., MBA, *Textbook of Arthroscopy*. 1st ed. 2004, Philadelphia: Elsevier.
23. Englund, M., *The role of the meniscus in osteoarthritis genesis*. *Med Clin North Am*, 2009. **93**(1): p. 37-43, x.

24. Katz, L.M. and P.P. Weitzel, *Partial Meniscectomy*, in *Knee Arthroscopy*. 2009, Springer. p. 11-23.
25. Strobel, M., *Manual of arthroscopic surgery*. 2002: Springer.
26. Crues 3rd, J., et al., *Meniscal tears of the knee: accuracy of MR imaging*. *Radiology*, 1987. **164**(2): p. 445-448.
27. Chivers, M.D. and S.D. Howitt, *Anatomy and physical examination of the knee menisci: a narrative review of the orthopedic literature*. *The Journal of the Canadian Chiropractic Association*, 2009. **53**(4): p. 319.
28. Scotti, C., et al., *Meniscus repair and regeneration: review on current methods and research potential*. *Eur Cell Mater*, 2013. **26**: p. 150-70.
29. Sgaglione, N.A., et al., *Current concepts in meniscus surgery: resection to replacement*. *Arthroscopy: The Journal of Arthroscopic & Related Surgery*, 2003. **19**(10): p. 161-188.
30. McGinity, J.B., L.F. Geuss, and R.A. Marvin, *Partial or total meniscectomy: a comparative analysis*. *J Bone Joint Surg Am*, 1977. **59**(6): p. 763-6.
31. Trillat, A., [*Traumatic lesions of the internal meniscus of the knee. Anatomical classification and clinical diagnosis*]. *Rev Chir Orthop Reparatrice Appar Mot*, 1962. **48**: p. 551-60.
32. Radin, E.L., F. de Lamotte, and P. Maquet, *Role of the menisci in the distribution of stress in the knee*. *Clin Orthop Relat Res*, 1984(185): p. 290-4.
33. Cavanaugh, J.T. and S.E. Killian, *Rehabilitation following meniscal repair*. *Current reviews in musculoskeletal medicine*, 2012. **5**(1): p. 46-58.
34. Seedhom, B. and D. Hargreaves, *Transmission of the Load in the Knee Joint with Special Reference to the Role of the Menisci Part II: Experimental Results, Discussion and Conclusions*. *Engineering in Medicine*, 1979. **8**(4): p. 220-228.
35. Macnicol, M. and N. Thomas, *The knee after meniscectomy*. *JOURNAL OF BONE AND JOINT SURGERY-BRITISH VOLUME-*, 2000. **82**(2): p. 157-159.
36. Cicutini, F.M., et al., *Rate of knee cartilage loss after partial meniscectomy*. *J Rheumatol*, 2002. **29**(9): p. 1954-6.
37. Baker, B.E., et al., *Review of meniscal injury and associated sports*. *Am J Sports Med*, 1985. **13**(1): p. 1-4.
38. Metcalf, M.H. and G.R. Barrett, *Prospective evaluation of 1485 meniscal tear patterns in patients with stable knees*. *Am J Sports Med*, 2004. **32**(3): p. 675-80.
39. Sihvonen, R., et al., *Arthroscopic partial meniscectomy versus sham surgery for a degenerative meniscal tear*. *N Engl J Med*, 2013. **369**(26): p. 2515-24.
40. Kirkley, A., et al., *A randomized trial of arthroscopic surgery for osteoarthritis of the knee*. *N Engl J Med*, 2008. **359**(11): p. 1097-107.
41. Laupattarakasem, W., et al., *Arthroscopic debridement for knee osteoarthritis*. *Cochrane Database Syst Rev*, 2008(1): p. Cd005118.
42. Annandale, T., *An Operation for Displaced Semilunar Cartilage*. *Br Med J*, 1885. **1**(1268): p. 779.
43. Rubman, M.H., F.R. Noyes, and S.D. Barber-Westin, *Arthroscopic repair of meniscal tears that extend into the avascular zone a review of 198 single and complex tears*. *The American journal of sports medicine*, 1998. **26**(1): p. 87-95.
44. Cannon, W., *Meniscal healing*. *Arthroscopic Meniscal Repair*, 1999: p. 7-12.
45. Stein, T., et al., *Long-Term Outcome After Arthroscopic Meniscal Repair Versus Arthroscopic Partial Meniscectomy for Traumatic Meniscal Tears*. *The American Journal of Sports Medicine*, 2010. **38**(8): p. 1542-1548.

46. Darabos, N., et al., *All-inside arthroscopic suturing technique for meniscal ruptures*. Acta Clin Croat, 2012. **51**(1): p. 51-4.
47. Albrecht-Olsen, P., G. Kristensen, and P. Tormala, *Meniscus bucket-handle fixation with an absorbable Biofix tack: development of a new technique*. Knee Surg Sports Traumatol Arthrosc, 1993. **1**(2): p. 104-6.
48. Morgan, C.D., "*All-inside*" arthroscopic meniscus repair. Operative Techniques in Sports Medicine, 1994. **2**(3): p. 201-207.
49. Cohen, S.B., L. Boyd, and M.D. Miller, *Vascular risk associated with meniscal repair using Rapidloc versus FasT-Fix: comparison of two all-inside meniscal devices*. J Knee Surg, 2007. **20**(3): p. 235-40.
50. Nelson, C.G. and K.F. Bonner, *Inside-Out Meniscus Repair*. Arthroscopy Techniques. **2**(4): p. e453-e460.
51. Jurist, K.A., P.W. Greene, 3rd, and A. Shirkhoda, *Peroneal nerve dysfunction as a complication of lateral meniscus repair: a case report and anatomic dissection*. Arthroscopy, 1989. **5**(2): p. 141-7.
52. Warren, R.F., *Arthroscopic meniscus repair*. Arthroscopy, 1985. **1**(3): p. 170-2.
53. Wheeless, C., *Wheeless' textbook of orthopaedics*. 1996.
54. Rodeo, S.A., *Instructional Course Lectures, The American Academy of Orthopaedic Surgeons-Arthroscopic Meniscal Repair with Use of the Outside-in Technique\**. The Journal of Bone & Joint Surgery, 2000. **82**(1): p. 127-41.
55. van Arkel, E. and P. Wilmes, *Meniscus transplantation; the Dutch experience*. Revue de Chirurgie Orthopedique et Traumatologique, 2009. **95**(8): p. 336-338.
56. Packer, J.D. and S.A. Rodeo, *Meniscal allograft transplantation*. Clin Sports Med, 2009. **28**(2): p. 259-83, viii.
57. Rijk, P.C., *Meniscal allograft transplantation--part I: background, results, graft selection and preservation, and surgical considerations*. Arthroscopy, 2004. **20**(7): p. 728-43.
58. Hergan, D., et al., *Meniscal Allograft Transplantation*. Arthroscopy. **27**(1): p. 101-112.
59. Yoldas, E.A., et al., *Arthroscopically assisted meniscal allograft transplantation with and without combined anterior cruciate ligament reconstruction*. Knee Surg Sports Traumatol Arthrosc, 2003. **11**(3): p. 173-82.
60. Rijk, P.C., *Meniscal allograft transplantation—part I: Background, results, graft selection and preservation, and surgical considerations*. Arthroscopy. **20**(7): p. 728-743.