

Early and late complications of cataract surgery

Ivić, Luka

Master's thesis / Diplomski rad

2021

Degree Grantor / Ustanova koja je dodijelila akademski / stručni stupanj: **University of Zagreb, School of Medicine / Sveučilište u Zagrebu, Medicinski fakultet**

Permanent link / Trajna poveznica: <https://um.nsk.hr/um:nbn:hr:105:864145>

Rights / Prava: [In copyright](#)/[Zaštićeno autorskim pravom.](#)

Download date / Datum preuzimanja: **2025-02-23**



Repository / Repozitorij:

[Dr Med - University of Zagreb School of Medicine Digital Repository](#)



UNIVERSITY OF ZAGREB

SCHOOL OF MEDICINE

Luka Ivić

**EARLY AND LATE COMPLICATIONS OF
CATARACT SURGERY**

Graduate thesis



Zagreb, 2022.

This graduate thesis was made at University Hospital Centre Zagreb, Department of Ophthalmology, mentored by prof.dr.sc Miro Kalauz, and was submitted for evaluation in the academic year 2021/2022.

Abbreviations

WHO – world health organization

D – diopter

ATP – adenosine triphosphate

PSC – posterior subcapsular cataract

ICCE – intracapsular cataract extraction

ECCE – extracapsular cataract extraction

Nd:YAG - neodymium-doped yttrium aluminium garnet

IOL – intraocular lens

MSCIS – manual small-incision cataract surgery

ACM – anterior chamber maintainer

UCVA – uncorrected visual acuity

BCVA – best corrected visual acuity

PHACO – phacoemulsification

FLACS – femtosecond laser assisted cataract surgery

FL – femtosecond laser

CCI – clear corneal incision

UDVA – uncorrected distance visual acuity

FS-AK - femtosecond laser-assisted arcuate keratometries

PCO – posterior capsular opacification

IOP – intraocular pressure

PCR – posterior capsular rupture

ACT – anterior capsular tear

PPV – pars plana vitrectomy

SCH – suprachoroidal hemorrhage

CME – cystoid macular edema

TASS – toxic anterior segment syndrome

APE – acute postoperative endophthalmitis

APB - aphakic pupillary block

RRD – rhegmatogenous retinal detachment

ACCS – anterior capsular contraction syndrome

CPE – chronic postoperative endophthalmitis

PBK – pseudophakic bullous keratopathy

Table of contents

1. Summary	
2. Sažetak	
3. Introduction	1
4. Epidemiology of cataracts	1
5. Lens.....	2
5.1. Embryonic development, anatomy and histology	2
5.2. Function and physiology.....	4
6. Etiopathogenesis of cataract formation	7
6.1. Congenital cataracts	7
6.2. Acquired cataracts.....	9
7. Cataract morphology and effect on vision.....	12
8. Cataract diagnosis.....	15
9. Indications for cataract surgery	15
10. Preoperative assessment and anesthesia.....	16
10.1. Preoperative assessment.....	16
10.2. Anesthesia.....	17
11. Modern day techniques of cataract surgery.....	18
11.1. Intracapsular Cataract Extraction (ICCE).....	18
11.2. Standard Extracapsular Cataract Extraction (ECCE).....	19
11.3. Manual Small-incision Cataract Surgery (MSICS).....	20
11.4. Phacoemulsification (PHACO).....	21
11.5. Femtosecond Laser Assisted Cataract Surgery (FLACS).....	23
12. Complications of cataract surgery	25
12.1. Preoperative complications	25
12.1.1. Mydriasis-induced acute angle closure glaucoma.....	25
12.1.2. Antisepsis-related complications	27
12.1.3. Anesthesia-related complications	27
12.2. Intraoperative complications	28
12.2.1 Posterior capsular rupture	29

12.2.2. Anterior capsular tear.....	30
12.2.3. Posterior dislocation of lens fragments.....	31
12.2.4. Zonular dehiscence	32
12.2.5. Posterior IOL dislocation.....	33
12.2.6. Suprachoroidal hemorrhage	35
12.3. Postoperative complications.....	36
12.3.1 Early postoperative complications	36
12.3.1.1. Corneal edema	37
12.3.1.2. Transient elevation of intraocular pressure.....	38
12.3.1.3. Postoperative hyphema	39
12.3.1.4. Postoperative anterior uveitis.....	40
12.3.1.5. Toxic anterior segment syndrome.....	42
12.3.1.6. Acute postoperative endophthalmitis.....	43
12.3.1.7. Aphakic pupillary block.....	45
12.3.2. Late postoperative complications	46
12.3.2.1. Posterior capsular opacification	46
12.3.2.2. Pseudophakic glaucoma.....	48
12.3.2.3. Postoperative dislocation of the IOL	49
12.3.2.4. Rhegmatogenous retinal detachment	50
12.3.2.5. Anterior capsular contraction syndrome	52
12.3.2.6. Cystoid macular edema.....	53
12.3.2.7. Chronic postoperative endophthalmitis.....	54
12.3.2.8. Pseudophakic bullous keratopathy.....	56
13. Conclusion.....	58
14. Acknowledgements	59
15. References	60
16. Biography.....	67

1. Summary

Luka Ivić

EARLY AND LATE COMPLICATIONS OF CATARACT SURGERY

Cataracts are defined as clouding of the crystalline lens which affects normal vision and are one of the most common causes of blindness worldwide, especially in developing countries. Even though incidence of cataracts increases in older age groups, multiple other factors can lead to premature lens opacifications, including genetic disorders, prenatal infections and trauma. Cataract formation is associated with deleterious effects on vision, such as myopic shift, monocular diplopia, reduction of contrast sensitivity and appearance of glare. Cataracts can be easily visualized using slit lamp examination. Indications for cataract extraction surgery include improvement of visual acuity and prevention of secondary complications, such as uveitis and glaucoma. Modern-day cataract extraction techniques can be divided into intracapsular and extracapsular. In general, cataract extraction surgery is very successful, with good patient outcomes and relatively low incidence of serious complications. Complications of cataract surgery can roughly be divided into preoperative, intraoperative and postoperative complications. Postoperative complications can further be classified as early (presenting <6 weeks after surgery) or late (presenting >6 weeks after surgery). Most of these complications can be adequately managed, with good expected outcomes.

Key words: cataract, cataract surgery, complications of cataract surgery

2. Sažetak

Luka Ivić

RANE I KASNE KOMPLIKACIJE OPERACIJE KATARAKTE

Katarakte se definiraju kao zamućenja kristalne leće koja utječu na normalan vid te su jedan od vodećih uzroka sljepoće diljem svijeta, posebice u zemljama u razvoju. Iako učestalost katarakte raste u starijim dobnim skupinama, postoje čimbenici koji mogu dovesti do prijevremenog zamućenja leće, poput genetskih poremećaja, prenatalnih infekcija i trauma. Razvoj katarakte povezan je sa štetnim učincima na vid, kao što su pomak prema kratkovidnosti, monokularna diplopija, smanjenje kontrastne osjetljivosti i pojava blještavila. Katarakte se lako uočavaju pregledom mikroskopom s prorezom. Indikacije za operaciju ekstrakcije katarakte uključuju poboljšanje vidne oštrine i prevenciju sekundarnih komplikacija, poput uveitisa i glaukoma. Suvremene tehnike ekstrakcije katarakte mogu se podijeliti na intrakapsularne i ekstrakapsularne. Općenito, operacija ekstrakcije katarakte vrlo je uspješna, s dobrim ishodima za pacijente i relativno niskom učestalosti ozbiljnih komplikacija. Komplikacije operacije katarakte mogu se ugrubo podijeliti na preoperativne, intraoperativne i postoperativne komplikacije. Postoperativne komplikacije se dodatno mogu podijeliti na rane (javljaju se <6 tjedana nakon operacije) i kasne (javljaju se >6 tjedana nakon operacije). Većina ovih komplikacija može se adekvatno liječiti, s dobrim očekivanim ishodima.

Ključne riječi: katarakta, operacije katarakte, komplikacije operacije katarakte

3. Introduction

World Health Organization (WHO) defines cataract as clouding of the crystalline lens affecting normal vision ¹. The term ‘cataract’ is derived from Latin word ‘cataracta’, meaning waterfall. It is thought that cataract has been named after its white appearance, being similar to the rapidly running water of waterfalls. The earliest depiction of cataract is believed to be 4500-year-old wooden statue of a priest reader with a white patch curved into the pupil of left eye, found in Cairo. Earliest surgical attempts at treating cataracts include couching, a procedure that involved dislodging of the lens towards the back of the eye using a needle. This procedure was first described by Indian surgeon Maharshi Sushruta some 800 years before Christ ².

Cataracts are one of the most common causes of blindness around the world, especially in developing countries with poor access to surgical treatment. In the Eastern Mediterranean region, cataracts are responsible for more than 51% of blindness. There is no known prevention for the development of cataract, and the number of people with cataract is anticipated to grow due to aging population ¹. Cataracts are most commonly seen in elderly patients, but can also be present at birth (congenital cataracts). However, pathogenesis of cataract formation is multivariable, with many different factors possibly leading to its development ³.

In developed countries, cataracts are successfully treated with modern surgical techniques. Advent of new technology involving new surgical techniques, better instruments and more advanced implantable lenses has made cataract extraction one of the most successful modern-day surgeries. However, numerous preoperative, intraoperative and postoperative complications are possible, and will be discussed in this paper.

4. Epidemiology of cataracts

Despite almost always being a curable disease, cataracts are still one of the most common causes of reversible visual impairment and blindness around the world. This especially holds true in developing countries, where surgical services may be inadequate or poorly available. WHO estimates that there are more than 40 million people worldwide living with blindness, with more than 20 million of these cases being caused by cataracts ⁴. Cataracts are commonly viewed as a natural consequence of aging. However, certain genetic and environmental

factors, as well as certain diseases, increase the risk of cataract development. Commonly mentioned environmental factors include cigarette smoking and ultraviolet light exposure. Medical conditions associated with an increased risk of cataract development include diabetes mellitus, acute and chronic uveitis, regular application of intraocular pressure lowering medication, corticosteroid use and previous ocular trauma or eye surgery ⁵.

The prevalence of cataracts is strongly correlated with increasing age. The Framingham Eye Study, conducted in the United States of America in 1977, reported overall incidence of age-related cataracts of 15.5% for all age groups, compared to 45.9% in age group of older than 75 years. Another study, The Beaver Dam Eye Study, likewise conducted in United States in 1992, reported similar proportions: 38.8% of men and 45.9% of women older than 74 years showed signs of cataract formation with vision loss of 6/9 or worse ⁴. On the other hand, younger populations show lower incidence of cataract formation. A 2020 meta-analysis examined pooled prevalence estimate of cataracts in different age groups. Pooled prevalence estimate of cataracts in 20-39-year, 40-59-year and over-60-year age groups was 3.01%, 16.97% and 54.38%, respectively ⁵. Due to the continuous aging of the population, the incidence of age-related cataracts is expected to increase in the following years.

Congenital cataracts, defined as opacities of the lens present at birth or developing during the first year of life, are the most common cause of treatable childhood blindness worldwide. According to the WHO standards, it is classified as a rare disease (having a prevalence of <6.5/10,000). Estimated 200,00 children worldwide are affected with bilateral cataracts, with many more suffering from partial or progressive cataracts causing visual difficulties. A 2016 meta-analysis estimated global prevalence of congenital cataracts, ranging from 2.2/10,000 to 13.6/10,000, with the overall pooled prevalence of 4.24/10,000 children. The highest congenital cataract prevalence was estimated in Asia, at 7.43/10,000 children ⁶.

5. Lens

5.1. Embryonic development, anatomy and histology

The embryonic development of the eye starts at around 28 days after conception. As the optic vesicle approaches the surface ectoderm, the ectoderm elongates to form the lens placode at 6 weeks of gestation. The lens placode subsequently invaginates to form the lens pit. Lens vesicle is then formed as the contact with the overlying surface of the ectoderm is lost. Cells at the anterior portion of the lens vesicle subsequently give rise to lens epithelium, while the

cells from the posterior portion elongate to form primary fiber cells. Primary fiber cells fill the lumen of the lens vesicle between the seventh and eight weeks of pregnancy, forming the embryonic nucleus. Secondary fiber cells are derived from epithelial cells found at the lens equator and are continuously added as outer layers after birth ⁷.

The lens is a transparent biconvex structure, situated posterior to the iris and anterior to the vitreous humor of the vitreous body. An adult lens has the diameter of 8.8-10 mm, and axial length of about 4 mm. Its size and shape are subject to change due to accommodation process and constant growth throughout a person's lifetime. The anterior surface of the lens is curved around a larger diameter (10 mm) compared to the posterior surface (6 mm). The most convex portion of the anterior surface, the anterior pole, sits 3-4 mm posteriorly to the cornea. Similarly, posterior pole is the most convex portion of the posterior surface of the lens. The marginal circumference of the lens is known as the lens equator. Lens equator serves as an attachment point for the suspensory ligaments of the lens – a fibrous tissue ring attaching the lens to the ciliary muscle, hence allowing for changes in lens shape during accommodation. The lens is avascular and lacks innervation – an important feature ensuring its transparency ⁸.

The lens has three major parts: lens capsule, lens epithelium, and lens fibers. Lens capsule is a typical epithelial basal membrane, produced slowly by the epithelial cells anteriorly and fiber cells posteriorly. It acts as a barrier against diffusion and contributes to the overall lens shape during accommodation. Lens capsule is composed of type IV collagen, laminin, entactin, perlecan, type XVII collagen, heparin sulfate and fibronectin. The capsule is at its thinnest at the equator and poles and is thickest laterally to the poles. Lens epithelium covers the anterior and equatorial surface of the lens. Three separate epithelial zones are recognized: central, intermediate, and equatorial. Central zone is found in the vicinity of anterior pole and contains polygonal epithelial cells. The intermediate zone is the source of new epithelial cells, due to the mitotic activity of cuboidal epithelial cells. Lastly, in the equatorial zone, lens epithelial cells differentiate into lens fibers. Lens fibers are specially modified, 8-20 mm long cells constituting much of the lens volume. First differentiated in the equatorial region, they migrate towards the nucleus. An adult lens contains 2100-2300 lens fibers ^{8,9}.

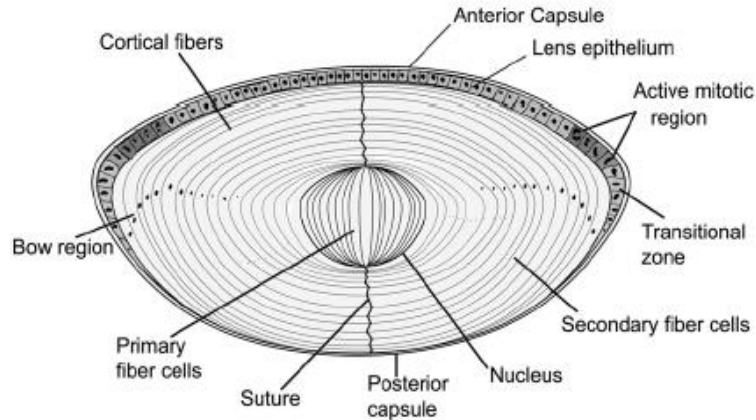


Figure 1. Schematic representation of lens histology (Source: Sharma and Santhoshkumar, 2009.)¹⁰

5.2. Function and physiology

The basic function of the crystalline lens is to transmit and focus light onto the retina. To achieve this, the lens is highly transparent, owing to its special tissue properties. It is also capable of changing its refractive power in a process known as accommodation.

Most of the refractive power of the eye is provided by the cornea, accounting for three-quarters of the total optical power¹¹. However, unlike the cornea, lens can alter its refractive power. The optical power of the lens is determined by its surface curvatures, the refractive index differences at the lens-aqueous and lens-vitreous interface, and the refractive index gradient distribution within the lens itself⁷. During accommodation, the surface curvature radius of the lens is changed. The most widely accepted theory of accommodation is the Helmholtz theory. According to this theory, when viewing a far object, the ciliary muscle is relaxed, allowing the tension of zonule fibers and suspensory ligaments to flatten the lens, thereby increasing the radius of the curvature of the anterior and posterior lens surface. This produces a decrease in lens refractive power (estimated at 19.11 diopter(D) at rest). On the other hand, when viewing a near object, the ciliary muscle contracts. This contraction causes the ciliary attachments of the zonular fibers to move anteriorly and inwards, allowing the lens to assume a rounder shape, increasing its optical power. Tendency of the lens to assume a rounder shape is a consequence of its collagen-rich capsule. During accommodation, anterior surface of the lens experiences the largest change of curvature radius, decreasing from 10 mm at rest to 6 mm during near sight. Posterior surface is subjected to much smaller changes, decreasing from 6 mm radius of curvature at rest to 5.5 mm during accommodation to near

objects. Due to these changes, the refractive power of the lens is altered from 19.11 D during rest up to 33.06 D during maximal accommodation. Time required for full accommodation from far sight to near sight is around 0.5 seconds, while the opposite process takes slightly longer^{7,12}.

In order to adequately transmit and focus light onto the retina while preventing excessive light scattering, crystalline lens is highly transparent. Such transparency is a result of its lack of vasculature, absence of intracellular organelles, highly ordered cellular architecture, close matching of the refractive index of fiber cell membrane and cytoplasm, and high concentration of crystallin proteins. Early in its embryonic development, the lens is supplied by tunica vasculosa lentis, derived from the hyaloid artery. Tunica vasculosa lentis is an extensive capillary network enveloping the anterior and posterior surface of the lens and ensuring its nutrition. It regresses during the subsequent development, so that by the fetal period the lens is completely avascular, relying on the aqueous humor for its nutrition. As mentioned earlier, the lens fiber cells differentiate from the epithelial cells in the equatorial region. The organelles of the lens fiber cell, including ribosomes, mitochondria, endoplasmic reticulum and nucleus are degraded during the process of differentiation. This results in formation of organelle-free zone. Throughout a person's lifetime, the secondary lens fiber cells in the cortex are continuously differentiated and packed in a geometrically ordered array. Furthermore, plasma membrane exhibits a characteristic hexagonal cross-section. Such architecture allows for minimal extracellular space and preservation of tissue transparency despite a refractive index mismatch between cortical fiber cell plasma membrane and its cytosol. As secondary lens fibers continue their differentiation and migration towards the lens nucleus, the orderly geometrical organization is gradually lost. Since mature lens fibers lose their organelles, they are unable to synthesize new proteins. The preexisting proteins undergo post-translational modifications, changing the cell shape and function. In the lens nucleus, most of the previously found geometrical order is lost, and the plasma membrane surface becomes irregular. Here, the minimization of light scattering is no longer the result of orderly architecture. Instead, the changes of cell proteins and lipids lead to closely matching refractive indices of fiber cell plasma membrane and cytoplasm. Such similarity between optical properties reduces the physical basis for light scattering, ensuring transparency⁷. Finally, lens contains very high concentration of crystallin proteins – transparent refractive proteins contributing to the focusing power of the human lens. These proteins comprise nearly 90% of the lens dry mass. Crystallins are divided into two major families, α and $\beta\gamma$,

grouped together based on their common function. These proteins have evolved to resist strong interprotein reactions which could lead to formation of aggregates, reducing the transparency of the lens. Furthermore, crystallins are extremely soluble and highly resistant to degradation. After being synthesized during early development of the lens fiber cell, they are never replaced, due to fiber lens cells lack of organelles. Hence, once synthesized, these proteins need to maintain their function throughout person's lifetime to ensure lens transparency¹⁴.

Due to its absence of blood supply and lack of organelles, lens requires a specialized transport system allowing for delivery of nutrients and antioxidants, removal of metabolic waste, maintenance of negative membrane potential required to maintain volume of the fiber cells and prevention of excessive water influx into the cells due to high concentration of crystallins. Due to its size, lens cannot rely exclusively on passive diffusion of substances to and from the aqueous humor. Hence, the lens microcirculation system has evolved to fulfill these roles. Microcirculation is driven via the difference in electromotive potential between surface cells (epithelial cells and newly differentiating fiber cells) and inner fiber cells. Surface cells contain sodium/potassium pumps and potassium channels, creating a negative electromotive potential. On the contrary, deeper fiber cells lack these pumps channels. Negative membrane potential of deeper cells is therefore maintained via gap junctions, linking them to the surface cells. The electrical current flows as a result of this electrical connection, as well as due to difference in membrane characteristics between surface and deeper cells. Such circulating current then creates a flow of solutes (mainly sodium ions), which in turn generates fluid flow. This fluid flow enters at the lens poles, leaving the lens at its equator. Lens's main source of energy is glucose from the aqueous humor. Due to lack of organelles in lens fiber cells, including mitochondria, the majority of glucose is metabolized via lactic fermentation pathway: one molecule of glucose is metabolized into two molecules of lactic acid and two molecules of adenosine triphosphate (ATP). Despite being an energetically poor process, it is adequate since the energy needs of the lens are so low. The most important antioxidant protecting the lens against oxidative damage is glutathione. It is critically important in prevention of protein cross-linking, aggregation of crystallins, and resulting light scattering. Reduction in glutathione concentrations in the lens is one of the first signs of cataract development^{3,7}.

6. Etiopathogenesis of cataract formation

6.1. Congenital cataracts

Congenital cataracts are lens opacifications presenting immediately at birth or within the first year of life, with the majority being present immediately at birth. The exact pathophysiological processes leading to congenital lens opacification are not yet fully understood. However, negative effects of metabolic disorders on the developing lens, as well as oxidative damage to the lens and adjacent structures via oxygen derived free radicals have been implicated ¹⁵.

Congenital cataracts can be further classified as inherited or acquired. Inherited congenital cataracts are a consequence of genetic mutations or chromosomal variations. It is believed that 8.3-25% of all congenital cataracts are inherited. Out of these, 70% of congenital cataracts are not associated with other ocular anomalies or multisystem genetic disorders, with the lens alone being affected – also known as isolated inherited congenital cataracts. Another 15% of congenital cataracts are associated with ocular anomalies, including microphthalmia, ptosis, keratoconus, microcornea, keratolenticular adhesions, ectopia of the lens and pupil, iris colobomas and many other. Finally, the last 15% of congenital cataracts are believed to be a part of multisystem genetic disorders, including chromosomal abnormalities such as Down syndrome, Edwards syndrome and Patau syndrome; metabolic syndromes such as Lowe syndrome and Fabry disease; and various other multisystem disorders such as neurofibromatosis type II ^{16,17}. The most commonly discovered mutated genes code for proteins involved in lens metabolism and transparency, with more than 50% of these genes coding for crystallins. Other genes commonly associated with congenital cataracts include genes coding for connexins (accounting for 25% of known gene mutations), heat shock transcription factor-4, aquaporin-0 and beaded filament structural protein-2. Although some correlation between the specific mutant protein and morphology of resulting cataract exists, radically different cataract severity and morphology are seen in practice, both within the same family, as well as different ones ¹⁶. Therefore, phenotypically identical cataracts can be a consequence of various gene mutations, while a single specific mutation can give rise to an array of different cataract phenotypes.

Acquired congenital cataracts are a consequence of external influences other than genetic makeup, including maternal and fetal factors. Maternal factors associated with congenital cataracts include malnutrition during pregnancy, intrauterine infections, maternal drug use,

exposure to ionizing radiation, and endocrine and metabolic abnormalities. Animal studies have shown that rats fed a diet low in tryptophan and vitamin E through gestation gave birth to offspring with higher incidence of cataracts¹⁸. Additionally, avitaminosis B and D have both been proposed as a potential cause of congenital cataracts¹⁷. Various pathogens causing intrauterine infections are known causes of congenital cataracts, including *Toxoplasma gondii*, Cytomegalovirus, Varicella zoster, Herpes simplex virus, Rubella, Epstein-Barr virus, and *Treponema pallidum*. First trimester rubella infection is particularly serious, as it is associated with highest incidence of congenital cataracts (in up to 50% of cases)¹⁹. Alcohol, corticosteroid and thalidomide use during pregnancy have also been mentioned as a potential maternal factors responsible for congenital cataract formation²⁰. On the other hand, fetal factors include anoxia due to placental hemorrhage, metabolic disorders such as galactosemia, hypocalcemia and hypoglycemia, birth trauma, and malnutrition in early infancy¹⁹. Despite being a rare cause of congenital cataracts, galactosemia should be considered as a differential diagnosis, since early initiation of galactose-free diet may lead to clearing of the lens opacities. This disorder is characterized by deficiency of one of the three enzymes involved in the metabolism of galactose: galactokinase, galactose-1-phosphate uridylyl transferase, or galactose-4-epimerase. Galactitol, a product of galactose metabolism, accumulates in the lens, leading to an osmotic shift of water into the lens. Osmotic shift results in swelling and rupture of the lens fibers, vacuole formation and lens opacification. Bilateral lamellar or ‘oil-drop’ cataracts are characteristic. With proper dietary interventions, these opacities are reversible at the stage of cortex involvement, but become irreversible once nucleus is opacified.²¹ Cataracts associated with hypocalcemia are a consequence of hypoparathyroidism or pseudohypoparathyroidism, and are related to increased permeability of the lens capsule. They present as lamellar opacities with punctate cortical dots. Finally, hypoglycemia can be a cause of transient lamellar opacities in perinatal period. If the hypoglycemia is recurrent, opacities may persist for a longer time¹⁵.

Despite the recent advances in understanding of pathophysiological mechanisms of congenital cataract origin and its development, most cataracts remain without a known cause – idiopathic. It is estimated that two thirds of congenital cataracts belong in this category. Risk factors associated with idiopathic congenital cataracts include low birth weight (<2000 g) and advanced maternal age (>40 years of age)²².

6.2. Acquired cataracts

Acquired cataracts are lens opacities presenting after the first year of life. They include age-related cataracts, traumatic cataracts, complicated cataracts, metabolic cataracts, toxic cataracts, and cataract caused by radiation or electrical energy.

Age-related cataracts are a consequence of lenticular changes associated with aging. These changes include breakdown and aggregation of lens proteins, deficiency of glutathione, accumulation of oxidative damage, elevated levels of sodium and calcium, damage to the fiber cell membrane, abnormal migration of lens epithelial cells, and many more²⁰. Age-related changes of the lens can be further compounded by external factors, such as smoking, dehydration and hypertension²⁰. Compared to people who never smoked tobacco, current smokers have a 50% increased risk of developing nuclear cataracts over the subsequent 10 years. Furthermore, current smokers tend to develop nuclear cataracts, on average, 2 years earlier than non-smokers. This is also associated with earlier need for cataract surgery – on average 3.7 years earlier than non-smokers. Tobacco smoke increases levels of oxidative stress in the lens, leading to oxidative damage. Furthermore, it is hypothesized that heavy metals present in cigarette smoke, such as cadmium, copper and lead accumulate in the lens, causing direct toxicity to the lens tissue²³. Additionally, an association between history of dehydration crisis (including life-threatening diarrheal disease and/or heatstroke) and risk of lens opacities is observed. The risk of cataract development is 3 times higher in those previously exposed to severe diarrheal disease compared to those not exposed. The relative risk seems to be associated with the number of exposures, with 2 or more exposures carrying a 12-fold increase, and being even higher if previously exposed to both severe diarrhea and heatstroke. Diarrhea, acidosis, malnutrition, dehydration and increased urea levels are associated with osmotic imbalance, leading to accumulation of cyanate and reduction in glutathione levels and further increasing the risk of subsequent cataract development^{23,24}. Thirdly, hypertension has been linked to increased risk of posterior subcapsular cataract development. It is believed that increased levels of systemic inflammation (as are seen in hypertensive patients) predispose to development of lens opacities. Additionally, hypertension is linked to conformational changes of lens protein structure, further predisposing to cataract development²⁵.

Traumatic cataracts are a result of blunt ocular trauma, perforating ocular trauma, or chemical injury due to intraocular foreign body. Contusion cataracts are a consequence of blunt object

trauma to the eye. Aqueous humor and iris are pushed posteriorly towards the lens, causing the lens to move posteriorly towards the vitreous. On its recoil forward, the lens hits the iris, causing trauma to both anterior and posterior lens surface. Such trauma can cause rupture of the lens capsule leading to opacification due to the aqueous humor entering the lens. Lens capsule ruptures are most commonly found at the posterior pole region, where the lens is at its thinnest. Perforation cataracts are associated with sharp object trauma, commonly leading to anterior capsule rupture. Lens opacification and expansion are abrupt, possibly causing disruption of trabecular meshwork drainage of aqueous humor, leading to development of secondary glaucoma. In case of more severe trauma, posterior capsule can be involved. Chemical damage caused by copper or iron leaching from intraocular foreign bodies is another possible mechanism of injury. Pure copper or copper alloys containing >85% of copper provoke severe tissue reaction. On the other hand, alloys with less than 85% of copper are associated with chalcosis. Chalcosis is a mild ocular inflammation characterized by 'sunflower cataract' (deposition of copper below anterior lens capsule), Kayser-Fleischer rings (copper depositions in Descemet membrane), green discoloration of iris and green pigment deposition in the retina. Foreign bodies containing less than 70% of copper are relatively inert. Iron contained in intraocular foreign bodies is first deposited into lens epithelial cells, making the lens take on a yellow-brown or rusty appearance. With time, focal rusty-brown subcapsular nodules may appear, with possible progression to cortical or nuclear opacity²⁶.

Complicated cataracts are cataracts occurring secondary to other intra-ocular diseases. Majority of complicated cataracts are a result of chronic intraocular inflammation and the use of corticosteroids during its treatment. Such conditions include iridocyclitis, pars planitis, posterior uveitis, hypopyon corneal ulcers and endophthalmitis. Inflammatory conditions most commonly lead to development of posterior subcapsular cataracts. Posterior subcapsular cataracts can also be caused by degenerative conditions, such as iris atrophy, retinitis pigmentosa and myopic chorioretinal degenerations. An episode of increased intraocular pressure can lead to grey or white opacities of epithelium and anterior cortex. Finally, cataracts can be caused by retinal detachment and various intraocular tumors, including retinoblastoma, melanoma and metastatic tumors involving the anterior eye segment or the choroid²⁷.

Metabolic cataracts are a consequence of endocrine disorders and metabolic abnormalities. As mentioned previously, galactosemia can lead to cataract development if proper dietary

interventions are not implemented. Furthermore, diabetes mellitus is also linked to cataract formation. More than 60% of diabetic patients have some evidence of lens opacification. Uncontrolled hyperglycemia is associated with non-enzymatic protein glycation and osmotic and oxidative stress in lenticular tissues, leading to opacity formation. Strict control of blood glucose levels is paramount in prevention of cataract formation in these patients. Additionally, cataractous changes are associated with hypocalcemia due to parathyroid gland atrophy or their accidental removal during thyroidectomy. Such cataracts are also called tetanic cataracts. Hepatolenticular degeneration, also known as Wilson's disease, is a hereditary error of copper metabolism leading to copper deposition in the body, including ocular tissues. As mentioned earlier, copper deposition in the lens can lead to formation of 'sunflower cataracts'. Finally, several other metabolic disorders are associated with increased risk of cataract development, including aminoaciduria, Fabry's disease, Hurler's disease, homocystinuria, Lowe's syndrome and many other^{20,28}.

Toxic cataracts are lens opacifications secondary to long term use of various drugs, exposure to toxins, or alcohol consumption. Corticosteroids are the most common cause of drug induced cataracts, accounting for 4.7% of all cataract surgeries. When compared to systemic administration, topical application is less likely to lead to opacification. The mechanism of corticosteroid-induced cataract development is still unknown, but osmotic imbalance, disruption of lens growth factors, oxidative damage and disruption of cellular proliferation and differentiation of lens epithelial cells have been proposed. Bilateral posterior subcapsular cataracts are characteristic. Time period needed for cataract development depends on the dosage used, with doses equivalent to 10-20 mg of prednisone a day requiring several years before significant opacification occurs. With daily doses of <10 mg prednisone, already existing cataracts are not expected to progress^{20,29,30}. Other drugs implicated in cataract development include thiazolidinediones, amiodarone, chlorpromazine, carbamazepine, long-acting cholinesterase inhibitors, quinolone, oral contraceptives, methotrexate, and many more. Various metals and minerals, in certain dosages and forms, can lead to lens opacification – mercury, cadmium, bromine, iridium, nickel, thallium, zinc sulfate and several other have been described. Acetone, dinitrophenol and cresol are examples of organic compounds linked to cataract formation. Lastly, heavy alcohol consumption (defined as daily intake of more than 20 g of alcohol, or weekly intake of 140 g) is associated with 1.26 times higher incidence of cataracts. Alcohol increases the risk of cataract development by increasing the production of free radicals, as well as increasing the concentration of calcium

within the lens. On the contrary, moderate alcohol consumption (defined as more than 0 g but less than 20 g daily) may be protective ³¹.

Cataracts caused by infrared radiation are observed in glassworkers and workers in metal industry, both exposed to very high temperatures. Heat is absorbed by the iris and the ciliary body, leading to indirect lenticular damage. Cataract begins developing at the posterior cortical region of the lens, eventually involving the whole cortex. ³² Microwave radiation exposure can lead to formation of anterior and/or posterior subcapsular cataracts via deformation of heat-labile enzymes, such as glutathione peroxidase, leading to oxidative damage. Additionally, thermoelastic expansion and resultant pressure waves in the aqueous humor damage the lenticular cells. Similarly, ionizing radiation (such as X-rays and gamma rays) can cause posterior subcapsular cataracts, however, via slightly different pathways. Damage to the cell membrane, cell deoxyribonucleic acid damage, decrease in protective enzyme production and altered protein concentrations in the lens have all been proposed. Ocular tumor treatment may involve ionizing radiation, increasing the likelihood of cataract development. ³³ Lastly, cataracts can be caused by electrical energy, either from lightning strike or industrial sources. Anterior and posterior subcapsular cataracts are observed after lightning strikes, while superficial anterior cortical opacities are seen with industrial accidents. Early changes include subcapsular vacuole formation, later progressing into linear, punctiform or rosette opacities of the lens ³⁴.

7. Cataract morphology and effect on vision

Cataracts can be roughly classified into three primary categories: nuclear sclerotic, cortical and posterior subcapsular cataracts. While this categorization serves as a gross oversimplification, it is useful when conducting clinical research and trials. Furthermore, these types can present solely or in a combination with other types.

Nuclear sclerotic cataracts are a consequence of exaggerated process or normal lens aging. During aging, new layers of fibers are added to the lens nucleus, with nucleus becoming compressed and harder (sclerotic). These cataracts tend to progress slowly, over several years. Nuclear opacifications are diffuse and uniform. Nuclear sclerosis is associated with myopic shift due to increase in refractive index of the nucleus, commonly referred to as the 'second sight'. This stands in contrast to the mild hypermetropic shift of the healthy eye. With time, urochrome pigment is deposited into the lens, causing a yellowish-golden hue

which can later progress to brown or black discoloration (*cataracta nuclearis brunescens et nigra*). Lens discoloration causes loss of color discrimination, especially affecting the red spectrum, due to lens pigment filtering these wavelengths.

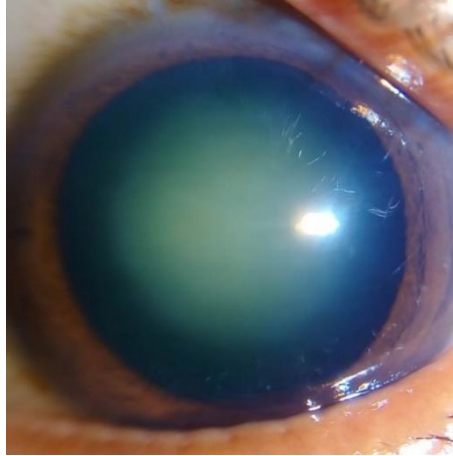


Figure 2. Nuclear sclerosis cataract (image acquired from https://eyewiki.aao.org/File:Nuclear_Sclerosis.jpg , accessed on 9.6.2022.)

Cortical cataracts are a consequence of changes in cortex hydration. Opacities start as cleft and vacuoles developing between the lens fibers. These clefts are initially filled with clear liquid, later becoming cloudy. Such changes can involve anterior, posterior or equatorial cortex. Wedge-shaped (cuneiform) opacities are characteristic, and are most commonly found in inferonasal quadrant. Glare is a common symptom, especially prone to occur during the night. It is a consequence of forward scattering of the light. Glare tends to be most troublesome when the light source is close to the object being observed. When advanced, a cortical cataract can project a shadow onto the retina, causing an identifiable defect in the peripheral field. Additionally, cortical cataracts can cause monocular diplopia due to cortical spoke prismatic effect.




Figure 3. Cortical cataract (image acquired from https://eyewiki.aao.org/File:Retroillumination_of_cortical_cataract.jpg , accessed on 9.6.2022.)

Posterior subcapsular cataracts (PSC) present as granular or plaque-like opacities anterior to the posterior capsule. Due to their position within the axis of the light rays travelling to retina, posterior subcapsular opacities have a great effect on vision. Glare is very pronounced and is worsened by miosis. Furthermore, PSC causes the largest contrast sensitivity reduction of all cataract types. Patients have trouble distinguishing large objects of low contrast difference, thus driving vision may be impaired while ability to read is not affected.

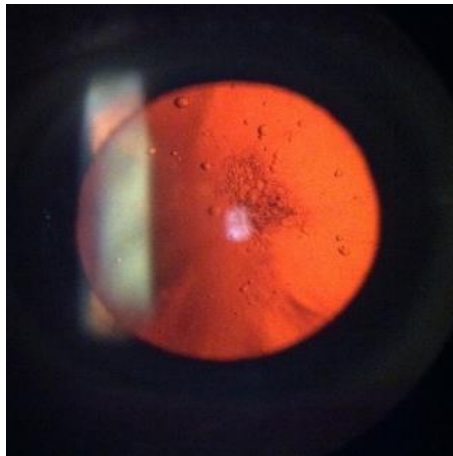


Figure 4. Posterior subcapsular cataract (image acquired from <https://eyewiki.aao.org/File:Psc.jpg> , accessed on 9.6.2022.)

Other types of cataracts mentioned in the literature include anterior and posterior capsular, anterior subcapsular, supranuclear and anterior and posterior polar cataract.

All morphological types of cataracts have deleterious effects on vision, including myopic shift, monocular diplopia, contrast sensitivity reduction, appearance of glare, color shift towards higher wavelengths, field loss and reduction in visual acuity. However, as mentioned above, some types of cataracts are more commonly associated with certain visual defects than others ^{11,19,35,36}.

8. Cataract diagnosis

Visual acuity testing, oblique illumination, test for iris shadow, direct ophthalmoscopy and slit lamp examination are all used to diagnose the presence of cataract and describe its attributes. Depending on the cataract stage of maturation, the visual acuity may vary. In the earliest stages of cataract formation, visual acuity may be preserved, later degrading until only perception of light is left. On gross inspection using oblique illumination, different stages of cataract may show different colors. Early cataracts tend to be grey, later becoming milky white or dirty white with brown, black or red spots. By pointing an oblique beam of light on the pupil, a crescent shadow of the pupillary margin of the iris will be observed on the grey opacity of the lens. Such shadow is not observed if the lens is either completely transparent or completely opaque. Hence, this shadow is a sign of immature cataract. Furthermore, distant direct ophthalmoscopy with dilated pupils can provide information on lens opacities. Any opacity of the lens will be visible as black shadow in the red glow of the retina. By asking the patient to move the eye up and down and observing the movement of the shadow, we can determine the position of the opacity in relation to the pupillary plane. Opacities in the pupillary plane will be stationary on eye movement, while opacities anterior and posterior to the pupillary plane will move in the direction of the eye movement and opposite to it, respectively. Finally, slit lamp examination will reveal the complete morphology of the lens, including opacity size, shape, site, color and hardness ¹¹.

9. Indications for cataract surgery

Indications of cataract surgery can be divided into 2 categories: visual indications and medical indications. Visual improvement is the most common indication for cataract surgery. Successful cataract extraction surgery will improve visual acuity and reduce visual disturbances such as glare, light sensitivity and decreased ability to discriminate colors and faces. Formal visual function questionnaires have been developed to objectively assess the visual function in cataract patients, such as the Visual Function Index 14. This questionnaire

consists of 18 questions covering 14 different aspects of visual function being negatively affected by cataracts. It is divided into 2 parts, first one examining the ability of general functioning such as difficulty of reading small print, books, large print, recognizing people faces, seeing steps or stairs, reading traffic signs, watching television, cooking and more. Second part of the questionnaire is concerned with day and night driving difficulties, as well as with possible complete abandonment of driving due to severe vision deterioration. All activities are scored with a value from 0 to 4. The sum of values is then multiplied by 25, giving a final score ranging from 0 to 100. The lower the score, the higher the disability of the patient is – hence the higher probability of that patient will require surgery.

Medical indications include prevention of secondary complications such as uveitis, glaucoma and lens dislocation, as well as the improvement of the clarity of ocular media required for proper monitoring or treatment of posterior eye segment pathology ^{11,37-39}.

10. Preoperative assessment and anesthesia

10.1. Preoperative assessment

A detailed and comprehensive preoperative assessment prior to cataract surgery includes both systemic and ophthalmic evaluation. Systemic evaluation is particularly important when general anesthesia is planned, and should include general examination, blood urea and electrolyte levels, blood glucose, full blood counts, chest X-ray and electrocardiogram. Current medication and possible allergies are recorded. However, for cataract surgery performed with local anesthesia, most of these tests are not usually required. Ophthalmic evaluation is then performed, and should include visual acuity testing, biometry, assessment of ocular adnexa, cornea, anterior chamber, pupil, lens, fundus and sclera, as well as details of current refractive status. Visual acuity is tested via a Snellen chart. However, additional testing should be provided with glare and contrast sensitivity measurement since preoperative visual acuity alone is a poor predictor of postoperative visual acuity and patient satisfaction. To determine the ideal intraocular lens power, biometry is used. It includes measurement of anterior corneal surface curvature (keratometry) and axial length of the eye. These two parameters are then used in various formulae to calculate the intraocular lens power required to achieve a specific refractive outcome. Any ocular adnexa pathology, including dacryocystitis, conjunctivitis, ectropion, entropion, lagophthalmos, blepharitis and tear film abnormalities, needs to be managed before the cataract surgery. Corneal endothelial cell counts should be assessed via specular microscopy and pachymetry since corneal

decompensation may occur after cataract surgery in cases of low endothelial cell counts. Anterior chamber depth and red reflex are checked, because deep anterior chamber or poor red reflex may make the surgery more difficult. Pupillary dilation is also inspected, since poor dilation may require intensive mydriatic drops, intracameral injection of mydriatic or mechanical dilation. If afferent pupillary defect is observed, posterior pole pathology needs to be considered and investigated. Next, lens opacity morphology and color are assessed. Nuclear cataracts, especially if brown or black, are known to be extremely dense. In such cases extracapsular cataract extraction may be preferred to phacoemulsification. Pseudoexfoliation may be noticed, and is associated with poor mydriasis, fragile capsule and weak lens zonules, possibly leading to phacodonesis (lens wobble). Fundus must be examined for pathologies that may affect the final visual outcome. Ultrasound may be required in eyes with dense opacities that prevent fundus examination via ophthalmoscope. Peribulbar and retrobulbar anesthesia need to be avoided in cases where scleral encircling band was used during prior retinal detachment surgery, or if the eye is big and sclera is thin – seen in high myopic eyes. Finally, preoperative refractive status is obtained. Combined with keratometry findings, it is used to guide the choice of intraocular lens. Postoperative emmetropia is usually desired, with many surgeons aiming for small degree of myopia (about -0.25 D), correcting for possible biometry errors^{11,40}.

10.2. Anesthesia

Today, most of cataract surgeries are performed under local anesthesia. In some circumstances, general anesthesia is still used. Such circumstances include operation of children and young adults, patients unable to cooperate (very anxious patients, patients with learning disabilities, epilepsy, dementia or head tremor), patients with history of allergic reactions to local anesthetics, and patients unable to tolerate local anesthesia procedures.

Local anesthesia is associated with less frequent complications, allows for faster patient recovery and is more financially viable. Local anesthetic techniques include retrobulbar, peribulbar, sub-Tenon, topical and intracameral anesthesia. Retrobulbar anesthesia is achieved via injection of 3.5 mL to 5.0 mL of anesthetic into the retrobulbar space, providing good ocular akinesia and analgesia. It is used primarily for longer operations in eyes having less stable anterior chamber. Peribulbar anesthesia uses several injections external to the muscle cone to provide good akinesia and anesthesia. It can lead to reduction in pulsatile blood flow and intraocular pressure, which are sometimes desired. It is the anesthesia of

choice in complex cataract cases requiring total akinesia. Risk of globe penetration is very low, but rates of chemosis are higher due to need for several injections. Retrobulbar and peribulbar techniques should not be used in highly myopic cases, due to risk of globe penetration. In Sub-Tenon block anesthesia, a blunt-tipped canula is inserted through an incision on conjunctiva and Tenon capsule, passed around the globe, injecting the anesthetic beyond the equator of the eye. Anesthesia is good, but akinesia is variable. This procedure is associated with high incidence of conjunctival swelling (39.4%) and subconjunctival hemorrhage (32% to 56%). Topical anesthesia is another commonly used method of providing anesthesia during the cataract surgery. While it does not provide akinesia, most patients are adequately cooperative during the surgery. Tetracaine, lidocaine, bupivacaine, proparacaine or benoxinate eyedrops into the fornix are used. Alternatively, gels such as lidocaine 2% can also be used. Care must be taken when using local topical anesthetics, since high or prolonged doses are toxic to corneal epithelium, possibly leading to erosions and clouding. Since topical anesthesia provides anesthesia for cornea and conjunctiva only, it is usually used for short surgeries in cooperative patients. However, other anterior segment structures such as iris remain unanesthetized. This can lead to discomfort and pain during iris manipulation and stretching ciliary tissues. In such cases intracameral anesthesia can be used as an adjunct. By injecting a preservative-free lidocaine 1% into the anterior chamber, sensory blockage of the iris and ciliary body is achieved ^{11,41}.

11. Modern day techniques of cataract surgery

11.1. Intracapsular Cataract Extraction (ICCE)

ICCE is a surgical technique which involves removal of both the crystalline lens and its lens capsule through a single corneoscleral incision. First developed in the 18th century, it has since been refined and is still in use today. After performing a retrobulbar block to provide akinesia and anesthesia of the eye, a 12-14 mm corneoscleral incision is created to access the anterior chamber. Peripheral iridotomy is then performed, allowing easier removal of the lens. Next, the lens and its capsule are extracted using a cryoprobe, first invented by Polish ophthalmologist Tadeusz Krwawicz in 1960. By cooling a metal cryoprobe to temperatures as low as -70 degrees Celsius and applying it to the surface of the lens, the lens and its capsule are frozen solid, and are attached to the tip of the cryoprobe. They can then be gradually delivered using gentle rotational and rocking motions. Zonulolysis can be facilitated with injection of α -chymotrypsin into the posterior chamber of the eye – so called

‘enzymatic zonulolysis’. Previous to the invention of cryoprobe, special forceps were used to deliver the lens. Because the lens capsule is also delivered, IOL can only be implanted in the anterior chamber or into the ciliary sulcus. After the lens and lens capsule are delivered and IOL is placed, 6-7 single sutures are placed. Alternatively, a longer continuous suture can be used. At the end of the procedure, subconjunctival dexamethasone and garamycin injections are given. Physiological solution or air are injected into the anterior chamber before sutures are placed. Operated eye is closed, and is opened on the next day for postoperative checkup.

Due to its prolonged wound healing and higher frequency of postoperative complications, ICCE has largely been replaced by newer and safer methods. Commonly mentioned complications include iris prolapse, retinal ablation, vitreous loss, cystoid macular edema, surgery-induced corneal astigmatism, expulsive hemorrhage and others. However, despite its shortcomings, ICCE is still in use in a limited number of clinical scenarios. ICCE may be preferred method in patients with mature or hypermature cataracts with very dense nuclei in eyes with zonular weakness or absence, where it may reduce the risk of lens dislocation compared to extracapsular cataract extraction. Conditions associated with zonular weakness include pseudoexfoliation syndrome, ocular trauma, complications of previous cataract surgeries, retinitis pigmentosa, and connective tissue disorders including Marfan syndrome. Pseudoexfoliation syndrome and ocular trauma are by far the most common indications for ICCE, accounting for 42.2% and 19.4% of causes of ICCE, respectively ⁴²⁻⁴⁴.

11.2. Standard Extracapsular Cataract Extraction (ECCE)

Standard ECCE is a commonly used technique of cataract extraction, especially in the developing world where phacoemulsification may not be available due to its much higher cost. In contrast to ICCE, it involves the removal of lens through an opening in anterior lens capsule, with the retention of an intact posterior capsule. During ECCE the lens is delivered through a large, 10-12 mm limbal incision. Initially, a smaller (3-3.5 mm) incision is created to access the anterior capsule. Anterior capsulotomy can then be performed using either a cystotome or a neodymium-doped yttrium aluminium garnet (Nd:YAG) laser. Nd:YAG laser capsulotomy is indicated in cases of zonular weakness due to previous trauma, occurrence of zonular dehiscence during previous surgery, or thickening of the anterior capsule. In a large portion of the world laser assisted capsulotomy may not be available due to economic reasons. Diameter of capsulotomy should not exceed 6-7 mm due to the risk of damaging lens zonular fibers. After capsulotomy, the limbal incision is widened up to 10-12 mm. Lens

nucleus is then mobilized via hydrodissection, allowing it to be prolapsed and later expressed. Using blunt instruments pressure is applied to the globe, slowly expressing the nucleus through the incision, when it is extracted using forceps or a needle. Before the cortex is aspirated, a semi-closed system needs to be created by closing off one half of the incision using 9-0 or 10-0 sutures. This allows the maintenance of anterior chamber volume. Afterwards, cortex is aspirated using aspiration-irrigation instrument. Complete lens mass needs to be aspirated to prevent formation of iritis or increase in intraocular pressure. A rigid intraocular lens (IOL) can then be implanted. The surgery ends with placing of corneoscleral sutures, followed by dexamethasone and garamycin subconjunctival injection. Before the incision is closed, air or physiological solution are injected into the anterior chamber. Operated eye is closed off until the postoperative control, on the subsequent day ^{45,46}.

Since ECCE confers many advantages over ICCE, it has largely replaced it, other than in a few clinical indications as described earlier. A smaller corneoscleral incision leads to less corneal endothelial trauma and lower risk of postoperative corneal decompensation. Furthermore, an intact posterior capsule reduces iris and vitreous mobility with movement (endophthalmodonesis), lowers the incidence of cystoid macular edema, corneal edema and retinal detachment, and diminishes the movement of IOL with eye movements (pseudophacodonesis). Likewise, intact posterior capsule acts as a barrier to bacteria and other microorganism accidentally introduced into the eye during surgery, leading to lower incidence of endophthalmitis. However, zonular integrity and intact posterior capsule are a prerequisite for successful ECCE with capsular IOL implantation. If proper zonular support is lacking, ICCE may be preferred ⁴⁷.

11.3. Manual Small-incision Cataract Surgery (MSICS)

MSICS is a variant of extracapsular approach to cataract extraction. In 1987, Blumenthal and Moisseiev described a manual ECCE technique variation 'Mininuc' using anterior chamber maintainer (ACM) and smaller incisions, which later became basis for modern day MSCIS development. ACM allows the majority of the operation to be performed under positive irrigation pressure, improving the operation safety. 'Mininuc' technique involved placement of ACM cannula, followed by the creation of side port and subsequent capsulotomy. 6.5-7 mm superior scleral tunnel incision is also created. Hydrodissection was then performed, mobilizing the nucleus from the epinucleus. The tip of the cannula was placed behind the nucleus and was used to move the nucleus towards the anterior chamber. Next, a glide was

introduced into the anterior chamber, which helped deliver the nucleus, also being helped by the positive pressure generated by the ACM. Afterwards, cortex was aspirated via a side port aspirating cannula, with ACM still providing continuous irrigation. Finally, IOL was implanted. In 1999 Ruit et al described the MSICS method similar to the one used today. It is able to achieve excellent outcomes at lower cost and lower surgical time compared to phacoemulsification. Unlike Blumenthal technique, it involves creation of a 6.5-7 mm temporal scleral tunnel 2 mm posterior to the limbus. Side-port incision is also created to allow further intraocular manipulation. After capsulotomy and hydrodissection viscoelastic is injected above and behind the nucleus. Lens nucleus can then be prolapsed into anterior chamber and extracted via serrated irrigating Simcoe cannula inserted below the nucleus. After the nucleus is delivered through the scleral tunnel, cortex is aspirated using Simcoe irrigation-aspiration cannula. IOL is then implanted into the capsular bag, and scleral incision is confirmed to be watertight. Various further variations in incision and nucleus delivery exist, but are beyond the scope of this paper ⁴⁸.

Compared to traditional ECCE, MSICS is associated with better postoperative visual outcomes and lower risk of surgically induced astigmatism. 48% of MSICS group achieved postoperative uncorrected visual acuity (UCVA) 6/18 or better, compared to 37% in the ECCE group. Likewise, UCVA of 6/12 better was achieved in 34% and 14% for the MSICS and ECCE group, respectively. However, there was no difference in best corrected visual acuity (BVCA). Furthermore, surgically induced astigmatism was greater in ECCE group (mean induced astigmatism 1.77 ± 1.65) compared to MSICS (1.1 ± 0.95). However, slightly fewer intraoperative and postoperative complications are observed after ECCE compared to MSICS, including posterior capsule tears, posterior capsule opacifications, Descemet membrane folds, corneal edema and iritis. Due to its better visual outcomes and comparable cost with ECCE, MSICS may be the preferred method of cataract extraction where phacoemulsification is not available ⁴⁹.

11.4. Phacoemulsification (PHACO)

Phacoemulsification is a modern-day cataract surgery method which uses ultrasound handpiece to emulsify the lens, which is then aspirated from the eye. It was first successfully used in 1967 by Doctor Charles D. Kelman. Modern-day PHACO handpieces use piezoelectric crystals to produce ultrasonic energy at frequencies of 30-60 kHz. Propagation of ultrasound waves leads to cavitation, fragmenting the lens. Continuous irrigation and

aspiration are provided by the same handpiece and needle, allowing the continuous maintenance of anterior chamber while fragmenting and aspirating the lens.

Before the surgery, the pupil must be properly dilated. Most commonly used medications include tropicamide and phenylephrine eyedrops. After a proper anesthetic method is used, an initial incision is made. Various methods of incisions were developed and described, with their choice depending on the experience level of the surgeon. Most common techniques include limbal incision, scleral tunnel and corneal tunnel. After the initial incision is made, an additional 1.5 mm corneal incision is created to allow the anterior chamber access to instruments used by other hand. Viscoelastic is injected into AC to prevent its collapse and offer protection of the corneal endothelium. Continued capsulotomy, also called capsulorrhexis, is then performed, and is one of the most difficult steps in PHACO surgery. Using a bent needle or cystotome, an initial cut is created. This allows the surgeon to peel away the circular opening in the anterior capsule using forceps. Capsulorrhexis maintains the integrity of capsular bag, allowing for easier and safer further steps. After capsulorrhexis is completed, the lens nucleus needs to be separated from the epinucleus and cortex. By injecting physiological solution below the anterior capsule, lens nucleus is separated from the cortex - also known as hydrodissection. This will allow the nucleus to be rotated, a sign that surgeon has successfully completed this step. Hydrodelimitation follows next, as physiological solution is injected into the lens nucleus itself. This will separate the outer and softer portion (epinucleus) from the central, hardened part of the nucleus. Finally, lens nucleus can be phacoemulsified using various available techniques. Different techniques use distinct combinations of ultrasound and mechanical fracturing. Commonly mentioned techniques include 'divide-and-conquer', 'phaco-chop', 'chip-and-flip', 'stop-and-chop, and many others. By using a separate handpiece, equipped with continuous irrigation and aspiration but lacking ultrasound probe, cortex is aspirated. Lens epinucleus is aspirated in the same way as cortex, unless it is hard and requires phacoemulsification, which is not usually the case. Before a foldable IOL is implanted, anterior chamber is once again filled with viscoelastic. After the implantation the viscoelastic is aspirated from the anterior chamber using a handpiece. If scleral or corneal tunnels are used, no suturing is necessary. The eye is closed, and is opened on the next day ^{11,50,51}.

When compared to other techniques, PHACO is associated with better postoperative visual outcomes and lower frequency of complications. At 3 weeks postoperatively, 33% of patients treated with PHACO achieved unaided visual acuity 6/9 or better, compared to 11% in the

ECCE group. In the same timeframe, 87% and 68% of patients had best corrected visual acuity of 6/9 or better in PHACO and ECCE groups, respectively. Similar results were found 12 weeks after the surgery, with 69% and 63% of patients having unaided visual acuity of 6/9 or better, and 91% and 86% of patients having best corrected visual acuity of 6/9 or better – in PHACO and ECCE groups, respectively. Furthermore, PHACO is associated with lower incidence of intra and post operative complications. Minor difficulties including anterior chamber prolapse or bleed, anterior capsule tear and incomplete capsulorrhexis are found in 7% of ECCE surgeries, compared to 2% of PHACO surgeries. Likewise, iris prolapse is very rarely seen in PHACO, while it can be seen in up to 7% of ECCE procedures. Postoperative corneal opacities are noted in 29% of ECCE procedures, compared to only 20% with PHACO. During the 3 months of postoperative follow-up, sutures had to be cut in 37% of ECCE patients to control astigmatism or due to their protrusion. In PHACO group, only 3.3% needed their sutures cut ⁵². Finally, the amount of surgically induced astigmatism varies widely between ECCE and PHACO procedures. In ECCE, the average induced astigmatism was 1.77 D, compared to only 0.77 D in the PHACO group ⁵³. Due to these advantages, PHACO is the mainstay of cataract extraction in the developed world, where countries can ensure the higher investment associated with PHACO equipment.

11.5. Femtosecond Laser Assisted Cataract Surgery (FLACS)

Femtosecond lasers (FL) are lasers capable of delivering ultrashort pulses in the range of 10^{-15} seconds. FLs used in ophthalmology deliver a beam of photons with wavelength of 1053 nm (infrared range), which are not absorbed by the corneal or anterior capsular tissue. By delivering ultrashort pulses of energy, FLs create multiple micro-cavitation bubbles with minimal adjacent tissue damage, allowing the laser to cut the tissue with great accuracy. This level of accuracy allows surgeon to create cuts within the anterior segment without causing trauma to corneal endothelium, iris, or posterior capsule. Development of femtosecond technology has allowed surgeons to automate 4 steps of cataract surgery, including creation of main incision and side ports on the cornea, reduction of corneal astigmatism via arcuate cuts within the peripheral corneal stroma, creation of anterior capsulotomy and fragmentation of the lens.

At the beginning of the operation, FL can be used to create clear corneal incisions (CCI) to allow access to the anterior chamber. CCIs created via FL demonstrate greater levels of architectural stability (lower incidence of Descemet membrane folds, tears or detachments)

when compared to incisions created manually via a keratome. Furthermore, lower endothelial cell losses have been reported. 1-day postoperative wound leakage on pressure is also less likely compared to using keratome. Despite these benefits, it has been reported that the majority of surgeons utilizing FLACS do not routinely perform FL CCIs. Another benefit of FL lies in its ability to correct the corneal astigmatism. Corneal astigmatism is commonly noted in patients undergoing cataract surgery: 40% of patients have more than 1 D, and 10% have more than 2 D of corneal astigmatism. Failing to address corneal astigmatism can lead to poorer postoperative uncorrected distance visual acuity (UDVA) which is associated with reduced quality of life. Manual methods of reducing corneal astigmatism during cataract surgery include placing the main incision 'on-axis' with or without opposite CCIs and limbal relaxing incisions. However, these incisions lack reproducibility, sometimes leading to unpredictable results. By employing femtosecond laser-assisted arcuate keratotomies (FS-AK), steepest meridian of corneal astigmatism can be precisely incised and flattened. Research shows that 44% of patients treated with FS-AK retain postoperative cylinder of <0.5 D, compared to 20% in group treated with limbal relaxing incisions. Third possible step of automatization involves anterior capsulotomy. Compared to manual continuous curvilinear capsulotomy, FL capsulotomy is more centered and circular which may allow for better IOL centralization, which may further be important when implanting multi-focal IOLs. However, studies have not found significant difference in postoperative spherical equivalent refractive error between the two methods. Potential benefit of better IOL centralization may be reduced risk of posterior capsule opacifications (PCO) due to more consistent overlap between IOL and capsulotomy edge. PCOs requiring Nd:YAG laser are observed in 11.6% of eyes treated with FLACS, compared to 15.2% of eyes treated with conventional phacoemulsification surgery. It is worth mentioning that the risk of anterior capsular tear may be higher when using FL capsulotomy, but more research is needed. Finally, the FL can be used to pretreat the lens, thereby reducing the effective phacoemulsification time required to complete the surgery. Cataracts pretreated with FL require, on average, 84% less phacoemulsification energy to be removed. Seeing how delivery of phacoemulsification energy is associated with endothelial cell damage, limitation of such energy is paramount. Lower delivered doses of energy are associated with lower amounts of oxidative stress and free radical production, leading to less corneal endothelial cell injury and postoperative corneal decompensation. After these four steps are made by a FL, the rest of cataract surgery is completed similarly as in conventional phacoemulsification surgery.

Despite its potential benefits, FLACS is still not the mainstay of cataract surgery. It is associated with increased length of surgery, leading to lower efficiency. A potential solution for this problem is the 'hub-and-spoke' model to allow for high volume cataract surgeries. This model involves running multiple parallel FLs before the patient is brought to operating room, shortening the total operating room time. However, even when using this model, FL is not as cost effective as conventional PHACO. Furthermore, the initial capital investment is high, limiting its widespread use. This technology may become more prevalent in the future as new techniques are developed and adopted ⁵⁴.

12. Complications of cataract surgery

12.1. Preoperative complications

12.1.1. Mydriasis-induced acute angle closure glaucoma

Acute angle closure glaucoma is an ophthalmological emergency occurring as a result of obstructed aqueous humor drainage. Various groups of drugs can trigger angle closure glaucoma, including mydriatics used in cataract surgery. Incidence of acute angle closure glaucoma following pupil dilation for diagnostic or operative procedure has been estimated at 0.03%. Topical mydriatic agents, including phenylephrine, cyclopentolate and tropicamide, are used before and during cataract surgery to dilate the pupil, enabling a surgeon easier access to the lens. Pupillary block due to mydriatic agents is the most common mechanism of angle closure in the preoperative period. When pupil is dilated with mydriatic agents it can come into contact with the lens, obstructing the aqueous outflow from the posterior chamber towards the anterior chamber. This results in increase in pressure within the posterior chamber, causing anterior bowing of the peripheral iris which consequently blocks the trabecular meshwork, leading to rise in the intraocular pressure (IOP). Risk factors for acute angle closure glaucoma include advanced age, positive family history, female gender and hypermetropia. Anatomical features such as narrow iridocorneal angle and thick crystalline lens further increase the risk. Patients with known anatomical differences should be referred for further investigation with gonioscopy. Most attacks will occur in patients unaware of their high risk.

Patients with acute angle closure glaucoma can be asymptomatic or present with blurred vision, headache, presence of haloes around the lights and ocular pain. In 90% of the cases, presentation is unilateral. Nausea and abdominal pain may also occur. On examination,

conjunctival hyperemia, shallow anterior chamber and corneal edema can be observed. Visual acuity is reduced <6/60 in 50% of the cases. During the attack, IOP may reach very high values (50-80 mmHg). Following the attack, IOP may be lowered due to ciliary body shutdown and intense treatment. During the acute angle closure, prompt reduction of the IOP is required to avoid optic nerve damage. First-line treatment includes 500 mg of acetazolamide intravenously if IOP is >50 mmHg or orally if IOP is <50 mmHg. Patient should lie down in a supine position, causing the lens to shift posteriorly under the influence of gravity. Then, a single dose of apraclonidine 0.5% or 1%, timolol 0.5% and prednisolone 1% (or dexamethasone 0.1%) is applied into the affected eye. 3-5 minutes should be allowed to pass between the individual applications. One drop of pilocarpine 2% should be instilled and repeated after 30 minutes, unless IOP is >40 mmHg. All of the above medication, or a combination of them should be continued according to the response, until the attack subsides. Mannitol 20% 1-2g/kg intravenously should be given over one hour in resistant cases. Nd:YAG laser iridotomy is performed once the attack has subsided, indicated by the clarity of the cornea and lowering of IOP. Despite immediate and adequate treatment, some 3-12% of patients will develop severe long-term visual impairment due to optic neuropathy. Timing of presentation is the most important factor in prognosis, with patients presenting >3 days after the onset of the attack having the worst prognosis ^{11,55-57}.

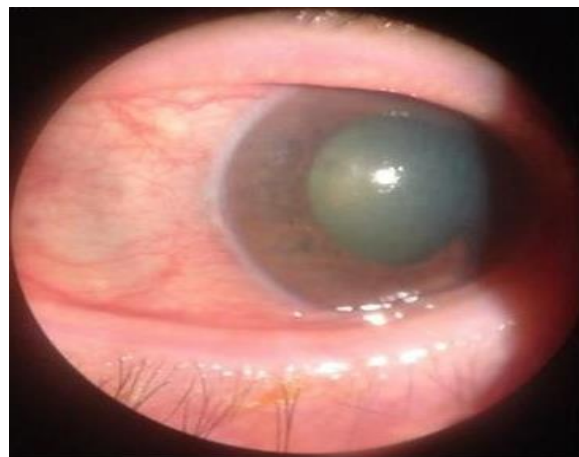

Figure 5. Drug-induced acute angle closure glaucoma (image acquired from https://eyewiki.aao.org/Drug-induced_Acute_Angle_Closure_Glaucoma , accessed on 9.6.2022.)

12.1.2. Antisepsis-related complications

Preoperative antisepsis is of paramount importance in preventing serious infectious complications of cataract surgery, such as acute postoperative endophthalmitis. Various aerobic and anaerobic bacteria form the commensal flora of the conjunctiva. The most common bacterial species found on the ocular surfaces include Gram-positive bacteria (*Staphylococcus epidermidis* being the most common), *Propionibacterium acnes* and diphtheroids. Fungal colonization of the conjunctiva is less common, seen in up to 8% of the cases with *Aspergillus* being the most common isolated pathogen. Methods of decreasing postoperative infection rate include preoperative antisepsis using povidone-iodine and aqueous chlorhexidine. Preoperative topical antibiotics have not been shown to decrease the risk of postoperative endophthalmitis. Povidone-iodine is the mainstay of preoperative antisepsis in cataract surgery. It is a complex of iodide and polyvinylpyrrolidone carrier, capable of penetrating bacterial membrane and acting bactericidally. Povidone-iodine has a broad-spectrum of activity, being efficient against various bacteria, fungi, viruses and protozoa. 5% solution of povidone-iodine assures most of the microorganisms are killed within 60 seconds of application. The European Society of Cataract and Refractive Surgeons recommends application of 5%-10% povidone-iodine to the periocular skin, conjunctival sac and cornea for minimum of 3 minutes prior to surgery. This protocol has been found to reduce the incidence of postoperative endophthalmitis. Despite its efficacy as an antiseptic agent, povidone-iodine is associated with complications in a small subset of patients. Up to 4% of patients will develop a severe chemical burn if their skin is exposed to povidone-iodine for long periods. Furthermore, some 0.4% of patients will develop true contact dermatitis upon exposure. Finally, rare cases of anaphylaxis have been associated with use of povidone-iodine during non-ophthalmological surgeries. According to the literature, no reports of anaphylaxis due to topical ophthalmic use of povidone-iodine have been noted. Use of 0.05% concentration of aqueous chlorhexidine is an alternative to povidone-iodine in patients with iodine sensitivity and allergy. It carries a broad-spectrum activity against bacteria, fungi and some viruses. However, it is not effective against spores. Additional research is required to determine its efficacy as prophylaxis for postoperative endophthalmitis⁵⁸⁻⁶¹.

12.1.3. Anesthesia-related complications

As mentioned earlier in this paper, the majority of modern-day cataract extractions are performed under local anesthesia. On average, about 95% of all cataract extractions are done using local anesthesia. This mode of anesthesia is safer, more efficient and maximizes patient

comfort. However, even methods of local anesthesia carry a risk of complications. Topical anesthesia is the most frequently used technique of anesthesia employed in cataract extraction surgery. It avoids the possibility of needle-associated complications seen in other techniques. However, since it does not provide anesthesia of iris and ciliary body, 78% of patients will experience mild pain or discomfort during surgery. Additionally, risk of epithelial and endothelial toxicity due to topical anesthetics is present. Sub-Tenon block is the second most commonly used technique of anesthesia, but is associated with an increased risk of intraoperative and postoperative complications when compared to topical anesthesia. Furthermore, cases of retrobulbar hemorrhage, globe perforation, trauma of the rectus muscle, intraocular hemorrhage, orbital cellulitis and central retinal artery occlusion have been reported following the use of this technique. Finally, sub-Tenon block is associated with lower intraoperative pain, but higher postoperative pain at 24 hours, compared to topical anesthesia. Retrobulbar anesthesia is the oldest developed method of ocular anesthesia, but has been largely replaced by newer and safer methods. Today, it is employed in less than 1% of cataract extractions. This largely stems from its numerous described complications, ranging from mild to severe, which occur in 1-3% of retrobulbar blocks. Sight-threatening complications of retrobulbar block include retrobulbar hemorrhage, peribulbar hemorrhage, globe penetration and perforation, injury to the optic nerve, retinal vascular spasm and myotoxicity. Even more serious are possible life-threatening complications, including brainstem anesthesia, cranial nerve blocks and acute seizures. Peribulbar anesthesia is an equally effective, but safer alternative to retrobulbar anesthesia. Risk of globe perforation and retrobulbar hemorrhage is lower compared to retrobulbar block. However, rates of conjunctival chemosis are higher^{62,63}.

Generalized anesthesia accounts for <5% of all cataract extraction cases and is associated with higher risk of complications compared to local anesthesia. Possible complications are vast and are beyond the scope of this paper. However, potential complications worth noting include respiratory complications (atelectasis, aspiration, bronchospasm), renal dysfunction, nausea and vomiting, malignant hyperthermia, anaphylaxis and many more⁶⁴.

12.2. Intraoperative complications

Most commonly seen intraoperative complications of cataract surgery include posterior capsular rupture, anterior capsular tear, posterior lens dislocation, zonular dehiscence, posterior IOL dislocation and suprachoroidal hemorrhage.

12.2.1 Posterior capsular rupture

Posterior capsular rupture (PCR) is the most common intraoperative complication of cataract surgery. Its incidence ranges from less than one percent to 4.1%. In the United Kingdom, the incidence of this complication is 1.92%⁶⁵. Similarly, Canadian cataract surgeons report posterior capsular tears in only 0.9% of operations⁶⁶. On the other hand, experiences from surgeons in Tehran Province, Iran, show PCR rates of 3.55%⁶⁷. Risk factors associated with higher incidence of PCR include age >90 years, male gender, diabetic retinopathy, pseudoexfoliation syndrome, phacodonesis, small pupil size, great axial length (>26 mm) and other. Furthermore, some types of cataract confer a higher risk of PCR, such as congenital posterior polar cataracts. PCR can be cause at any point during the surgery, but is most commonly seen during phacoemulsification of the lens nucleus and aspiration of the cortex due to inadvertent touch of the phacoemulsification probe or secondary instruments. Less common causes include excessive hydrodissection, trauma during IOL insertion, and accidental punctures during intracameral injections. Rupture that occurs earlier during the surgery tends to be more problematic than one occurring during later steps. PCR manifests with sudden deepening or shallowing of the anterior chamber, pupillary dilatation, posterior dislocation of the nucleus (making it inaccessible by the phacoemulsification tip) and possible vitreous prolapse.

Proper management of PCR begins with injection of dispersive viscoelastic. If a complete or nearly nucleus remains, conversion to ECCE may be beneficial. If required, vitreous fragments can be removed at this point using a vitrector. Next, a lens glide can be passed behind the lens fragments, covering the capsular defect. Residual nuclear fragments are removed using low aspiration flow rate, followed by filling of anterior chamber with cohesive viscoelastic allowing easier aspiration of residual cortex. Finally, all the vitreous fragments are removed from the anterior chamber and the wound, aided by instillation of trypan blue or triamcinolone. If the PCR is small, implantation of posterior chamber IOL may be possible. On the other hand, large PCR necessitate anterior chamber IOL implantation, which is in itself associated with higher risk of bullous keratopathy, hyphema and pupillary irregularities.

PCR is a potentially serious complication which may be further complicated by vitreous loss, posterior loss of lens fragments, difficulties with IOL placement and expulsive hemorrhage. If inappropriately managed, vitreous loss can lead to cystic macular edema, endophthalmitis,

retinal detachment, uveitis, glaucoma, vitreous wick syndrome, updrawn pupil and posterior dislocation of IOL^{11,65-67}.

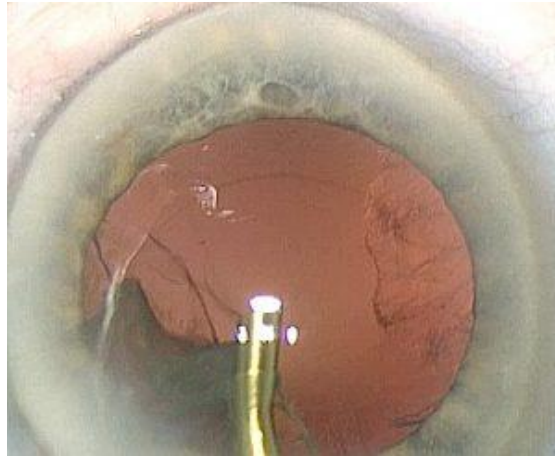


Figure 6. Posterior capsular rupture during cataract surgery (image acquired from <https://www.eurotimes.org/when-posterior-capsule-rupture-strikes/> , accessed on 9.6.2022.)

12.2.2. Anterior capsular tear

Anterior capsular tear (ACT) can occur during any stage of the cataract operation, but is most commonly seen during initial capsulorrhexis. The incidence of this complication is estimated at 0.79%. ACT used to be more common in the past, when ‘can-opener’ capsulotomies were performed as a standard. It remains a potentially serious complication due to potential extension of the tear into the posterior capsule, compromising the capsular bag. Such extension is observed in 48% of the cases. As mentioned earlier, posterior capsular tears may result in vitreous loss, posterior loss of lens fragments and suboptimal IOL implantation location. The size of the capsulorrhexis may contribute to the risk of ACT – too small of an opening may predispose the capsule to be snagged by the phacoemulsification handpiece. On the other hand, too large of an opening may involve proximal zonular fibers – 67% of the tears extend to the zonules. When the tear is identified early, anterior chamber can be stabilized with viscoelastic. Nucleus removal is slowly completed, using low AFR. Portion of the cortex adjacent to the tear can be left in place. In the majority of cases, ACT is compatible with posterior chamber IOL implantation. 1-piece acrylic IOLs are preferred due to their soft haptics and lower risk of extension of the tear. 3-piece IOL placement in the anterior chamber, ciliary sulcus or iris fixation are reasonable alternatives. Surgeons performing PHACO need to be familiar with anterior vitrectomy techniques to manage the possible vitreous prolapse due to posterior capsule tears, which is seen in 19% of the ACT cases⁶⁸.

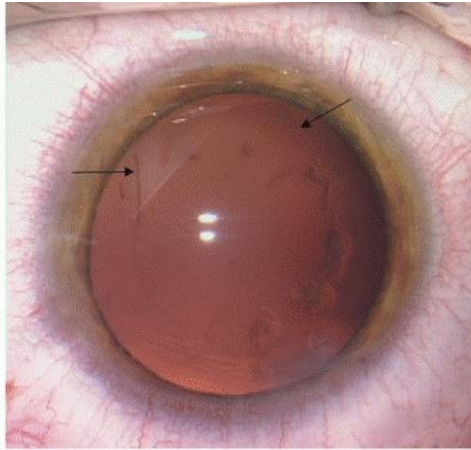


Figure 7. Anterior capsular tear (image acquired from <https://entokey.com/intraoperative-and-postoperative-complications/> , accessed on 9.6.2022.)

12.2.3. Posterior dislocation of lens fragments

Dislocation of lens fragments into the vitreous cavity can occur after posterior capsular rupture or zonular dehiscence. It is a rare complication occurring in 0.3 to 1.1% of cataract surgeries, depending on the surgeon experience. Retained lens material in the vitreous cavity may result in persistent intraocular inflammation, corneal edema, cystoid macular edema, endophthalmitis, retinal detachment and secondary glaucoma. All of these possible sequelae carry a risk of permanent vision loss. Posterior lens dislocation risk is higher in patients of advanced age, patients with corneal opacities, floppy iris syndrome, increased axial length, poor pupillary dilation, posterior polar cataracts, pseudoexfoliation syndrome, and previous ocular trauma or prior vitrectomy.

Early recognition of possible posterior capsular rupture or zonular dehiscence can prevent further extension of the tear and loss of lenticular fragments. Technique for dealing with PCR with or without vitreous prolapse is described above. If lens fragments have descended into anterior vitreous, the posterior assisted levitation technique can be employed. It involves insertion of cyclodialysis spatula through pars plana sclerotomy in attempt to suspend the nuclear fragments towards the anterior chamber. Alternatively, dispersive viscoelastic can be used for the same purpose. Retained lens material is then emulsified and aspirated, or manually extracted via corneal incision. In cases when lens material has descended into the posterior vitreous, a help of posterior segment surgeon is required. It is important to determine the type of dislocated lens material – lens nucleus is poorly tolerated, while epinucleus and cortex cause less irritation. Size of the fragments also plays a role: fragments

<2 mm in size can be managed conservatively with corticosteroids and intraocular pressure lowering drops. If medical management is chosen, patient has to be closely monitored to detect possible complications, such as secondary phacoantigenic uveitis, glaucoma, or corneal decompensation, all of which require emergent surgical care. On the other hand, fragments >2 mm always require vitreoretinal intervention.

Optimal timing of the vitreoretinal surgery after posterior dislocation of the lens is a matter of debate. Vitreoretinal intervention can be schedule early (within 1 week) or late (later than 1 week). Several studies report better visual acuity and lower rate of complications when performing pars plana vitrectomy at the time of cataract surgery. This may decrease post-operative inflammation and improve patient satisfaction. However, this approach may be logistically difficult. Other studies suggest no difference in final visual acuity between early and late vitrectomy after complicated cataract surgery. A standard 3 port pars plana vitrectomy (PPV) is usually employed. In cases of extremely dense lens fragments, manual extraction may be necessary. Using suction, fragments are brought into middle portion of the vitreous and are secured to the fragmatome tip using ultrasound. They can then be removed by extracapsular extraction. Prognosis of visual acuity is good, with 56-68% of patients reaching visual acuity of 20/40 or better ^{11,69}.

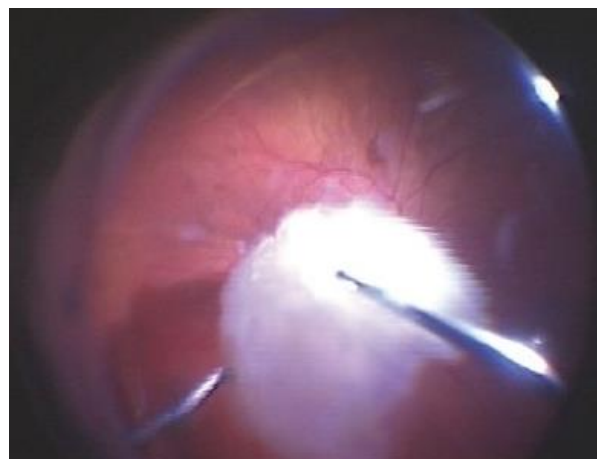


Figure 8. Posterior dislocation of lens nucleus (image acquired from <https://www.retinalphysician.com/issues/2007/march-2007/removing-retained-lens-fragments-following-catarac> , accessed on 9.6.2022.)

12.2.4. Zonular dehiscence

Zonular dehiscence is a relatively common complication of cataract surgery, seen in about 0.46% of surgeries. It can result in posterior loss of lens fragments into the vitreous cavity,

which may later result in glaucoma, uveitis, retinal detachment or cystoid macular edema. Hence, preoperative assessment is important in assessing lens stability and potential presence of weak zonules. In patients with weak zonules, such as those with Marfan syndrome, pseudoexfoliation syndrome, very old patients and patients with history of ocular trauma, capsulorrhexis may prove to be difficult. Surgical trauma causing zonular dehiscence may be caused by excessive traction during lens rotation or unintentional aspiration of the peripheral capsule via phacoemulsification probe. Depending on the severity of lens instability, iris hooks or capsular tension ring may be inserted to provide additional stability. Capsular tension ring is placed within the lens capsule at the equator. It serves to spread the tension on the zonules. In cases of greater than 180-degree loss of zonules, a Cionni ring can be used. It is a variation of the capsular tension ring, which is additionally sutured to the sclera. Finally, Ahmed segment is a capsular tension ring segment (less than 360-degrees) which can also be placed inside the capsular bag. However, capsular tension ring can only be placed if posterior capsule is intact. After the capsule is stabilized, the IOL can be safely implanted into the capsular bag ⁶⁵ .

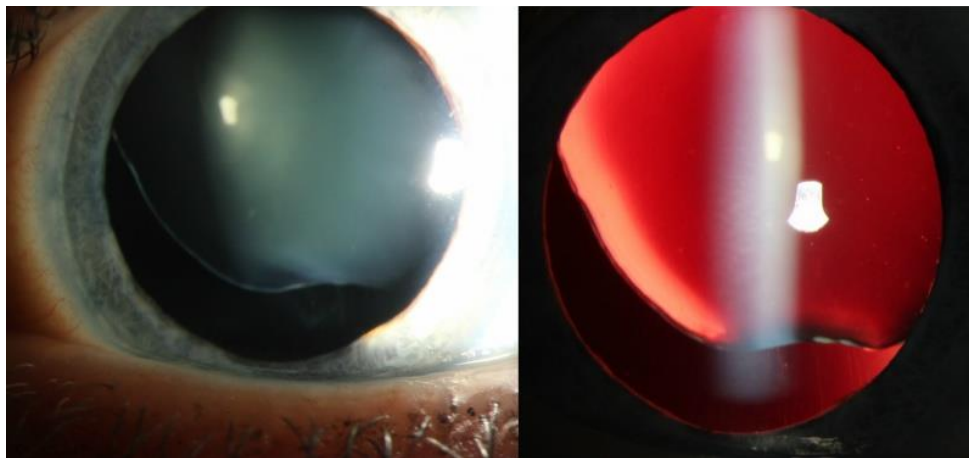


Figure 9. Subluxated crystalline lens due to stretching of zonular fibers (image acquired from [https://eyewiki.aao.org/Zonulopathy: Evaluation and Surgical Management](https://eyewiki.aao.org/Zonulopathy:_Evaluation_and_Surgical_Management) , accessed on 9.6.2022.)

12.2.5. Posterior IOL dislocation

Dislocation of IOL into the vitreous cavity is a rare complication of cataract surgery with incidence ranging from 0.02 to 0.09% ⁶⁷. IOL dislocation can occur due to posterior capsule tears, or the whole capsular bag can dislocate posteriorly, as may be seen in patients with pseudoexfoliation syndrome. Early IOL dislocations (within 3 months of initial surgery) are

most commonly caused by pseudoexfoliation syndrome. On the other hand, late IOL dislocations (after 3 months of initial surgery) are usually caused by trauma⁷⁰. Complications of IOL dislocation include vitreous hemorrhage, retinal detachment, chronic cystoid macular edema and uveitis.

Treatment modalities for IOL dislocation range from IOL reposition within the capsular bag to pars plana vitrectomy with IOL removal, depending on the status of capsular support. If capsular support is adequate, surgeon may choose to reposition the IOL within the capsular bag. In cases where capsular support is inefficient, pars plana vitrectomy with IOL removal is indicated. During this procedure, IOL is freed from any vitreous adhesions, allowing it to float to retinal surface. Surgeon can then grasp it with forceps or engage it with soft-tip cannula, bringing the IOL to pupillary plane. By extending the superior sclerotomy, IOL can be removed from the eye. After the implanted lens is removed from the eye, the retina needs to be examined for potential breaks, which are treated with cryopexy or laser photocoagulation. Surgeon may decide to implant the anterior chamber IOL during the same procedure (primary implantation), or at a later date (secondary implantation). Primary implantation is performed more commonly (54% and 46%, respectively). This is largely a surgeons choice. Pars plana vitrectomy with anterior chamber IOL implantation carries great prognosis, with 92% of patients having improved visual acuity after the surgery. About 8% of patients will experience worsening of vision due to postoperative retinal detachment, pseudophakic bullous keratopathy and macular holes⁷¹.

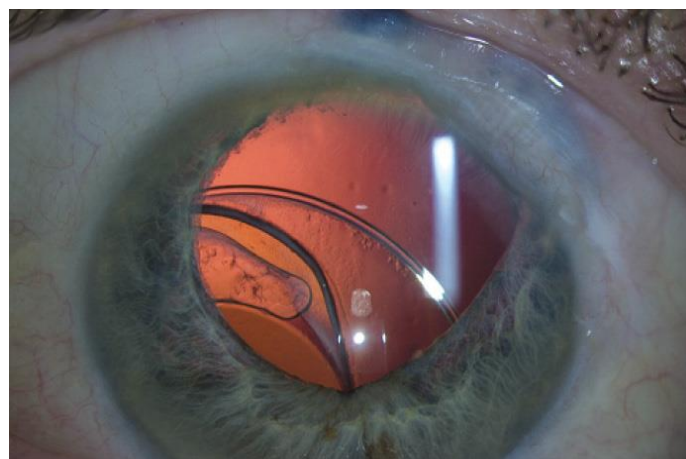


Figure 10. Posteriorly dislocated IOL (image acquired from <https://crstoday.com/articles/2016-jun/dislocated-iol-in-an-eye-with-a-history-of-trauma/> , accessed on 9.6.2022.)

12.2.6. Suprachoroidal hemorrhage

Suprachoroidal hemorrhage (SCH) is defined as presence of blood within the suprachoroidal space. Suprachoroidal space is a potential space between the choroid and sclera, normally containing 10 μ L of fluid. Although rare, SCH is a dreaded and devastating complication. It can be seen during any type of intraocular procedure. With older methods of cataract extraction, the overall incidence of SCH was estimated to be approximately 0.2%. Owing to the advent of newer techniques including phacoemulsification with topical anesthesia and clear corneal incisions, its incidence has been dramatically lowered. Due to less pronounced fluctuations in IOP and need for less manipulation of the globe, only 0.03% to 0.06% of phacoemulsifications are complicated by SCH. Risk factors include advanced age, increased axial length, systemic cardiovascular disease (hypertension and atherosclerosis), vitreous loss, glaucoma, coagulation defects and conversion from phacoemulsification to ECCE.

Several theories about mechanism of SCH have been developed. Hypotony seems to be the precipitating factor, leading to ciliochoroidal effusion, causing separation of the choroid and the sclera. This separation then causes stretching and rupture of posterior choroidal artery, precipitating massive bleeding. SCHs can be categorized based on their size, timing and precipitating events. Suprachoroidal hematomas represent small, benign collections of blood in the suprachoroidal space associated with intraocular surgery. They are self-limiting and resolve spontaneously. On the other side of the spectrum are massive SCHs, which can lead to central retinal apposition. If massive SCHs occur during the surgery, an *expulsive SCH* can occur. Such hemorrhage causes expulsion of intraocular contents through the surgical wound. *Delayed or postoperative SCH* develops in the postoperative period, and is not associated with expulsion of ocular contents. It is more commonly seen in glaucoma filtration surgery.

Signs of intraoperative SCH include shallowing of the AC, prolapse of the iris, increased IOP with firming of the globe, loss of red reflex, and possible vitreous prolapse. If SCH is suspected, immediate closure of the sutures or application of digital pressure is required. Closure of the eye will allow the IOP to rise, eventually causing tamponade of the bleeding vessel. If intraocular contents are expelled, they need to be repositioned. Anterior chamber saline or air injection is recommended to prevent vitreous entrapment into the surgical wound, which increases the risk of retinal detachment. Sedation of the patient, lowering of systolic blood pressure and intravenous hyperosmotic agents may be helpful in controlling the bleeding. If postoperative IOP is elevated, aggressive therapy with topical beta-blocker

and oral carbonic anhydrase inhibitor is necessary. Topical and systemic steroids can be used to control the intraocular inflammation. Pain may be severe due to stretching of the ciliary nerves, but analgesia must not include non-steroidal anti-inflammatories or aspirin due to risk of further bleeding. If spontaneous absorption of large hemorrhage does not occur, a drainage should be performed 7-14 days later. Additionally, PPV may be required if retinal detachment, vitreous hemorrhage, dislocated lens fragments or vitreoretinal traction is observed. This is usually performed at the same time as SCH drainage. To prevent SCH in high-risk patients, several prophylactic measure have been described. This measures include lower IOP before incision, avoidance of rapid decompression of the globe, avoidance of anticoagulants before surgery (if possible), control of systemic hypertension, and preventing possible ocular hypotony.

Unfortunately, expulsive SCH carries a bad prognosis, with severe visual loss expected in four out of five patients. Only one out of five patients will achieve visual acuity greater than 20/200, despite of early surgical treatment and drainage. Furthermore, 27.5% of patients will have no light perception on the affected eye ^{11,72}.

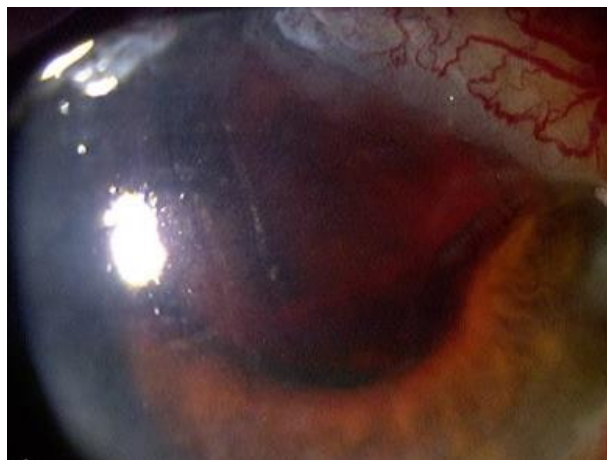


Figure 11. Suprachoroidal hemorrhage (image acquired from <https://www.columbiaeye.org/education/digital-reference-of-ophthalmology/lens-cataract/surgery-complications-0/suprachoroidal-and-vitreous-hemorrhage-post-ecce> , accessed on 9.2.2022.)

12.3. Postoperative complications

12.3.1 Early postoperative complications

Early postoperative complications are complications arising within the first 6 weeks after cataract surgery. Most common early postoperative complications of cataract surgery include

corneal edema, transient intraocular pressure elevation, postoperative hyphema, postoperative anterior uveitis, toxic anterior segment syndrome, acute postoperative endophthalmitis and aphakic pupillary block.

12.3.1.1. Corneal edema

Corneal edema is defined as the increase in the corneal thickness due to accumulation of fluid within the corneal epithelium and stroma, resulting in loss of transparency. It is one of the most common early postoperative complications of cataract surgery, seen in 35-44% of patients on first postoperative day, decreasing to 3.8% by postoperative day 7. In the large majority of cases, it is self-limiting. Only 0.62% of patients are hospitalized for permanent corneal edema or transplantation within the first 4 years of phacoemulsification surgery. Corneal endothelial cells ensure transparency of the cornea by constantly dehydrating the stroma via ATP driven pumps. Furthermore, endothelium itself acts as a barrier. Water influx rate into the cornea normally equals the metabolic pump rate, maintaining a 78% water content in the stroma. Corneal edema develops when endothelial cell counts fall below the critical level of around 600 cells / mm², making it unable to effectively pump water out of the stroma. Corneal endothelium in adults cannot replicate. Instead, endothelial cells migrate, enlarge and undergo metaplasia to fibroblast-like cells in order to re-establish the intercellular junctions. Additionally, number of pump sites per cell may increase. Postoperative corneal edema may result from various reasons, including surgical trauma, inflammation and chemical injury. Surgical trauma is the most common cause of endothelial cell loss in patients undergoing cataract extraction. Ultrasound energy, irrigating solutions, air bubbles, IOLs, lens fragments and instrument contact all cause endothelial cell damage. Postoperative ocular inflammation is associated with transient dysfunction of the endothelial pumps, leading to corneal edema in susceptible eyes. Finally, chemical injury to the endothelial cells can be a result of antiseptic solutions, topical anesthetics, irrigating solutions, viscoelastics, detergent residues on surgical instruments, preservatives and air. Certain ocular diseases, such as Fuchs endothelial dystrophy, can result in low endothelial cell reserves, further predisposing to postsurgical corneal decompensation. Likewise, elevations of IOP lead to higher rates of water influx into the corneal stroma, increasing the risk of corneal edema.

Luckily, the majority of postoperative corneal edema cases will resolve spontaneously. For the small minority of permanent cases, treatable causes should first be eliminated. These causes include ocular inflammation, IOL malposition, endophthalmitis, high IOP and

Descemet membrane detachment. Majority of these causes can be dealt with medical treatment. Surgical intervention may be necessary for malpositioned IOLs and Descemet membrane detachment. After eliminating all treatable causes of corneal edema, hypertonic sodium chloride solutions (5%) can be used to improve the corneal transparency. This is especially beneficial in the morning when edema is at its highest. If all medical therapy is unsuccessful, keratoplasty will be required^{73,74}.

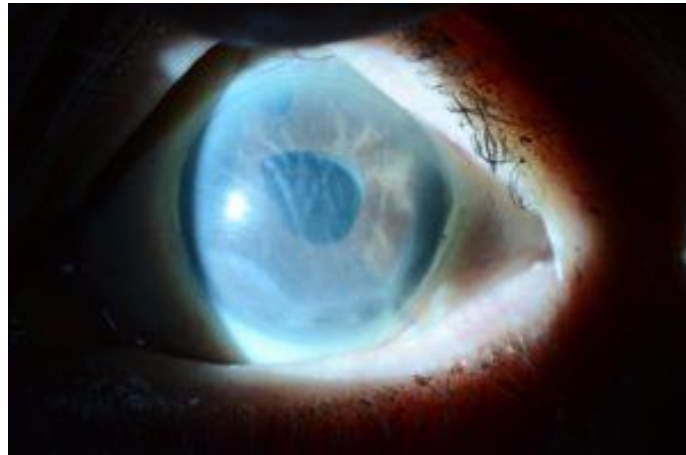

Figure 12. Postoperative corneal edema (image acquired from <https://www.willseye.org/corneal-swelling-following-cataract-surgery/> , accessed on 9.6.2022.)

12.3.1.2. Transient elevation of intraocular pressure

Transient elevations of IOP in the early postoperative period are a common adverse event of cataract surgery. IOP values exceeding 30 mmHg are defined as IOP spikes. These spikes are usually transient and do not influence the long-term vision. However, they can be more dangerous in eyes with already present optic nerve damage due to glaucoma or atherosclerosis-related ischemia. In general population, the incidence of early IOP increase by 10 mmHg is estimated at 9.8%. However, in high-risk populations, the incidence of early IOP increase above 28 mmHg may be up to 46.4%. Risk factors for increased early postoperative IOP include pseudoexfoliation syndrome, axial length >25 mm, application of topical steroids, residual viscoelastic material in the anterior chamber, resident performing surgery and low surgeon experience (defined as <200 procedures). IOP peaks 3-7 hours after surgery, and remains elevated during the first 24 hours. The first 3-4 hours are the most troublesome, as IOP elevation of >30 mmHg may be observed. Early rise of IOP is a result of prostaglandin release due to anterior chamber inflammation.

The necessity of IOP spike treatment is questionable since the majority of nonglaucomatous eyes will not suffer any damage to the optic nerve during transient pressure increase. However, a combination of dorzolamide and timolol in high-risk patients, especially ones with preexisting optic nerve damage, is recommended ⁷⁵.

12.3.1.3. Postoperative hyphema

Hyphema, defined as accumulation of red blood cells within the anterior chamber, can present in the early postoperative period. Incidence of postoperative hyphema following cataract extraction surgery has been estimated at 1.25% to 18.7%, depending on the author. This complication is most commonly seen between the 3rd and 6th postoperative day, with the peak on 5th day after surgery. This timeline coincides with period of formation of new blood vessels within the eye, which can be damaged by the slightest trauma or ocular strain. Rarely, a malpositioned or rotating anterior chamber IOL can result in chronic inflammation, iris neovascularization and recurrent hyphemas. This constellation of symptoms is known as uveitis-glaucoma-hyphema syndrome. Finally, postoperative hyphema has been reported to occur with use of Nd:YAG laser for peripheral iridotomy, resulting in self-limiting, mild hyphema. Patients using anticoagulation therapy and patients with clotting disorders are at a higher risk of developing postoperative hyphema. Patients with sickle cell anemia or carrying sickle cell trait are at an especially high risk of severe complications. In these patients erythrocytes can sickle within the anterior chamber, leading to occlusion of the trabecular meshwork and subsequent elevation of the intraocular pressure. Additionally, sickled erythrocytes can cause severe vaso-occlusive events, such as central retinal artery occlusion and ischemic optic neuropathy.

Patients presenting with postoperative hyphema will complain of blurry vision and ocular distortion. If secondary intraocular pressure elevation is present, patients may complain of pain, headache and photophobia. Possible complications include elevated intraocular pressure due to trabecular meshwork obstruction, peripheral anterior synechiae, posterior synechiae and corneal bloodstaining. Patients with hyphema require a complete ophthalmic workup, including gonioscopy to evaluate the condition of iridocorneal angle. Workup can be delayed until at least the 5th postoperative day to avoid the high-risk period. Height and color of the hyphema are documented. Height is measured in millimeters, starting from the inferior corneal limbus. Color can vary from red to black, depending on the timing (clotted blood will appear darker). About 95% of patients with hyphema can be managed conservatively. This

includes using an eye shield, limiting activity and rest with head elevation of at least 45 degrees. Such elevation will allow red blood cells to settle to the inferior portion of the anterior chamber, thereby avoiding central visual obstruction and limiting the damage to the corneal endothelium and trabecular meshwork. Most patients can be managed in outpatient setting. However, patients with bleeding diathesis or severe intraocular pressure elevations should be hospitalized. During pain control nonsteroidal anti-inflammatory drugs should be avoided to prevent further bleeding. Corticosteroids may be used in cases with severe inflammation. If intraocular pressure is severely elevated, topical beta-blockers and alpha-agonists are employed. Systemic carbonic anhydrase inhibitors and hyperosmotic agents are an alternative used in refractory cases. Care should be taken when using these medications, due to increased risk of red blood cell sickling in patients with sickle cell anemia. Some 5% of patients with hyphema will require surgical treatment, due to uncontrolled glaucoma, corneal blood staining, active bleeding within the anterior chamber or persistence of large hyphema. Possible surgical methods include anterior chamber washout, trabeculectomy, vitrectomy and peripheral iridectomy^{76,77}.

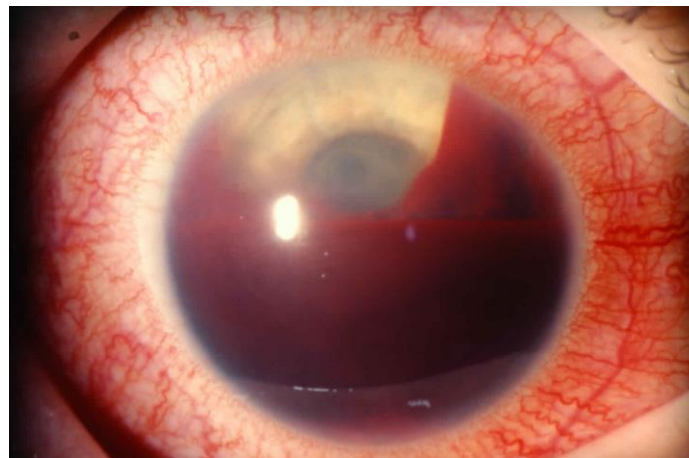


Figure 13. Postoperative hyphema (image acquired from <https://healthjade.net/hyphema/> , accessed on 9.6.2022.)

12.3.1.4. Postoperative anterior uveitis

Postoperative anterior uveitis is an inflammation of the anterior uveal tract, including the iris and the pars plicata of the ciliary body, occurring after intraocular surgery. Anterior uveitis is a relatively common complication of cataract surgery, observed in 1.75% of all patients. If patients with positive history of ocular inflammatory or autoimmune diagnosis are excluded, the incidence falls to 1.2%. Post-operative uveitis encompasses 10% of all uveitis cases,

while almost 50% of those cases being seen following cataract extraction with IOL implantation. Surgery-induced trauma is a common trigger of anterior uveitis. It results in breakdown of the blood-aqueous barrier allowing leukocytes and inflammatory mediators to enter the eye, causing an inflammatory state. The post-operative inflammatory state peaks within the first week, and will slowly decrease back to baseline after 2-3 weeks. It is usually well controlled with steroid regimens. However, inflammation can rebound after steroid taper, accompanied by acute exacerbation of anterior uveitis. Risk factors for persistent or rebound uveitis include patients of African American descent, diabetes, and use of pupil expanding device during surgery. Furthermore, improper post-operative anti-inflammatory medication regimen, improper response of the eye to the anti-inflammatory regimen, and presence of lens material in the anterior chamber angle additionally predisposes to anterior uveitis.

Patients with anterior uveitis will present with rapid onset of unilateral vision loss, redness of the eye, ocular pain, photophobia, watery discharge and ocular discomfort. Ciliary injection is characteristic, with circumcorneal hyperemia of the conjunctiva. Due to pupillary sphincter spasm, miosis may be observed. This predisposes to formation of posterior synechiae. Slit lamp examination will reveal presence of leukocytes in the anterior chamber. Keratic precipitates, inflammatory cells deposits on corneal endothelium may also be seen. IOP may be both reduced and increased. Dilated fundus examination is mandatory to assess for posterior uveitis or panuveitis. Management of postoperative anterior uveitis includes topical corticosteroid regimen combined with cycloplegics. Topical steroids are the treatment of choice, with prednisolone 1% or dexamethasone 0.1% being most commonly used. Commonly mentioned topical corticosteroid regimen consists of administration of 'one drop hourly for 3 days, then every 2 hours for 3 days, then four times a day for 1 week, then three times a day for 1 week, then twice a day for 1 week, then once a day for 1 week and stop.'¹¹ In total, treatment will take 5-6 weeks. Common complications of topical steroids include elevated IOP, secondary bacterial or fungal keratitis, corneal melting and reactivation of herpetic keratitis. For non-compliant patients, a sub-Tenon administration of depot steroid preparations may be used. Intraocular triamcinolone acetonide (0.4 mg in 0.1 mL) is used in cases of anterior uveitis complicated by cystoid macular edema (CME). In refractory cases, systemic steroids may rarely be required. Cycloplegic agents are used alongside steroids to prevent formation of posterior synechiae and promote comfort by relieving spasms of the ciliary and pupillary muscle. Cyclopentolate, homatropine and atropine are most commonly

used. Additionally, phenylephrine may be used in the acute stage to supplement the anticholinergic drugs. Patients should be followed weekly, until <5 cells per high power field are seen in the anterior chamber. Cycloplegics can then be discontinued^{11,78}.

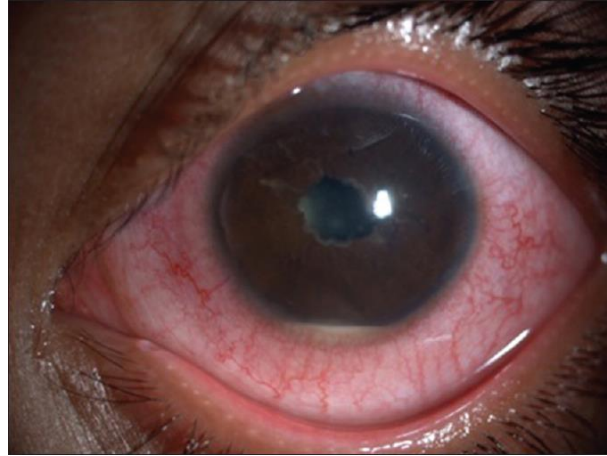


Figure 14. Hypopyon seen in postoperative anterior uveitis (Source: Bajoria and Biswas, 2018.)⁷⁹

12.3.1.5. Toxic anterior segment syndrome

Toxic anterior segment syndrome (TASS) is characterized by sterile postoperative inflammation of the anterior eye segment. It is most commonly seen after cataract surgery, but can also be triggered by keratoplasty or posterior segment surgeries. The overall incidence of postoperative TASS is estimated at 0.22%. Major causes of TASS include inadequately cleaned surgical instruments, adverse drug reactions, and contaminated surgical instruments or IOLs. Furthermore, incorrect pH or osmolarity of irrigating solutions, detergent residues on ophthalmic instruments, incorrect drug concentration or preservatives in medication solutions have all been implicated as potential triggers. The hallmark of this syndrome is toxic anterior segment damage due to severe acute inflammatory response. Due to corneal endothelium susceptibility to toxic damage, cornea is the most affected anterior segment structure.

Hallmark of TASS is an inflammatory process most commonly starting within 24 hours of cataract surgery, characterized by ocular pain, conjunctival injection and blurry vision. If anterior segment inflammation is severe, a hypopyon may be seen. Due to widespread endothelial damage, a diffuse 'limbus-to-limbus' corneal edema may be observed. When severe, TASS can result in permanent iris damage, causing a dilated, irregular pupil. Also, trabecular meshwork damage may lead to subsequent ocular hypertension or secondary

glaucoma. When discussing TASS, the main differential diagnosis to keep in mind is acute postoperative endophthalmitis. The mainstay of TASS treatment involves intense topical steroid regimen, consisting of prednisolone acetate 1% drops every 1-2 hours. Patient should be closely monitored for signs of improvement or deterioration. IOP should also be carefully followed, due to potential rise several days after the initial insult due to trabecular meshwork damage. The clinical course and outcome of TASS patient depends on the type and amount of substance introduced into the eye, the duration of exposure, and timing of the treatment. Patients with mild and moderate cases are expected to completely recover with no residual corneal edema. In contrast, patients with severe TASS may develop permanent, nonclearing corneal edema, secondary glaucoma, iris damage and cystoid macular edema. Due to potential complications of this syndrome, its prevention is of paramount importance. It includes careful cleaning and sterilization of ophthalmic instruments, proper handling and use of ocular medications, and adequate education of the entire surgical team^{80,81}.

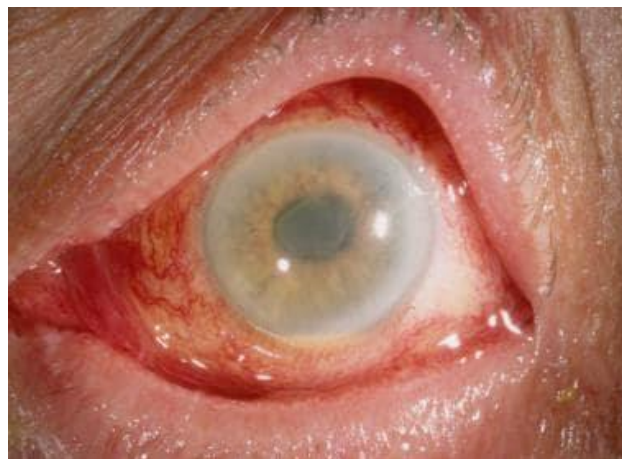

Figure 15. Toxic anterior segment syndrome (Image acquired from <https://emedicine.medscape.com/article/1190343-overview> , accessed on 9.6.2022.)

12.3.1.6. Acute postoperative endophthalmitis

Acute postoperative endophthalmitis (APE) is a dreaded complication of cataract surgery, characterized by severe inflammatory response within the eye caused by the introduction of microorganisms into the eye during the surgery or immediately following the surgery. It presents within the first 6 weeks after cataract surgery. The incidence of APE is declining steadily, and is currently ranging from 0.03% to 0.2%. Gram-positive bacteria are responsible for 90% of cases, with *Staphylococcus epidermidis* being the most common isolated pathogen. Other common pathogens include *Staphylococcus aureus* and various

Streptococcus species. Even though the exact source of the infection cannot be determined with certainty, it is thought that flora of the eyelids and conjunctiva, contaminated instruments and solutions, and operating room air are the most frequent sources. Toxins produced by invading bacteria, along with host inflammatory response are responsible for rapid and possibly irreversible photoreceptor damage. Risk factors for development of APE include patient adnexal disease, diabetes mellitus, immunocompromised patients, contact lens wear, intraoperative complications (e.g., posterior capsular rupture, vitreous loss), prolonged procedure time, use of clear corneal sutureless incisions, wound leak and delayed postoperative use of antibiotics.

APE presents with rapid onset of visual loss and pain, often accompanied by visible hypopyon. Eyelid swelling, chemosis, conjunctival discharge, ciliary injection, corneal haze vitritis are also observed. APE is diagnosed based on clinical picture and further confirmation by culturing aqueous humor and vitreous samples. Negative culture does not exclude the infection, and treatment should be continued until APE is ruled out. B-scan ultrasound should also be performed to exclude possible retinal detachment. Differential diagnosis includes toxic anterior segment syndrome, retained lens fragments, postoperative uveitis and vitreous hemorrhage. Treatment of APE needs to be emergent and precise. Vitreous tap or PPV are done to obtain culture samples, debulk the vitreous from toxins, inflammatory cells and microorganisms, and to provide space for intravitreal antibiotic injections. Intravitreal antibiotics are the mainstay of treatment, and should be administered immediately after culture samples are taken. The combination of vancomycin (1 mg / 0.1 mL) and ceftazidime (2 mg / 0.1 mL) covers for most of the Gram-positive and Gram-negative pathogens. Alternatively, amikacin (0.4 mg / 0.1 mL) can be used in penicillin-allergic patients, but it is more toxic to the retina. In addition to antibiotics, corticosteroid therapy is used in order to reduce host inflammation and resultant tissue destruction. Topical prednisolone acetate 1% should be frequently instilled. Furthermore, subconjunctival injection of dexamethasone (4 mg) is administered at the same time as initial antibiotic therapy. Oral prednisolone 1 mg/kg daily may be considered in severe cases if fungal infection has been excluded. Lastly, Intravitreal steroids can be used to quickly reduce the inflammation, but do not influence the final visual outcome^{11,82}.

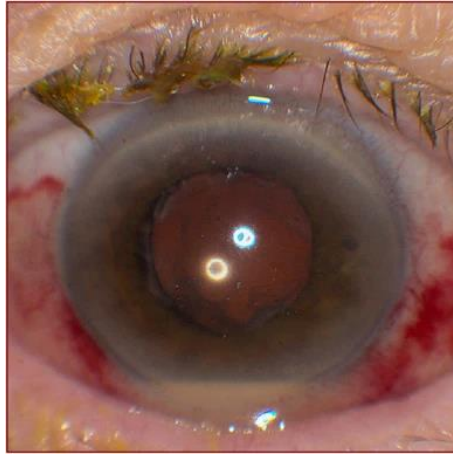


Figure 16. Hypopyon, purulent discharge and conjunctival injection seen in acute postoperative endophthalmitis (Source: Maguire, 2008.)⁸³

12.3.1.7. Aphakic pupillary block

Aphakic pupillary block (APB) is an uncommon complication of cataract surgery, occurring when the flow of aqueous humor from the posterior chamber towards anterior chamber is obstructed. Possible causes of aqueous flow obstruction include adhesion of the iris to the vitreous or to the posterior lens capsule, excessive postoperative inflammation with formation of posterior synechiae, and alteration of anterior chamber angle due to lens placement into the ciliary sulcus or inversed implantation of the IOL. This prevents the physiological flow of aqueous humor from the posterior chamber to the anterior chamber. Accumulated aqueous pushes the iris anteriorly, closing the iridocorneal angle and possibly leading to acute angle-closure glaucoma. APB is an uncommon complication following posterior capsular IOL implantation, seen in 0.09% of patients. Diabetic patients and patients with diabetic retinopathy are at higher risk (0.6% and 3.5%, respectively) due to abnormalities in the blood-aqueous barrier permeability. Furthermore, iris-fixation lenses are especially prone to development of this complication since they are placed in close proximity to the pupil and normal route of aqueous flow. Reported incidence of pupillary block with the use of such lenses is estimated at 3%-8%. Use of anterior chamber or iris-fixated lenses requires creation of peripheral iridectomy to facilitate aqueous humor drainage. Besides IOL design, intraoperative complications such as vitreous loss and operative hyphema further increase the risk of APB.

Patients with pupillary block will typically present within the 48 hours of surgery with decreased visual acuity and ocular pain. Shallow anterior chamber and iris bombe (anterior

bowing of the iris) can be visualized when examining the anterior eye segment. Tonometry will show IOP elevation, IOP often being above 40 mmHg. Once the diagnosis is made, miotics should be discontinued and mydriatics administered. Additionally, topical or systemic carbonic anhydrase inhibitors and hyperosmotic agents may be used to decrease the IOP. Nd:YAG laser iridectomy or surgical iridectomy may be necessary to facilitate aqueous humor outflow, thereby decreasing the IOP and improving the visual acuity^{84,85}.

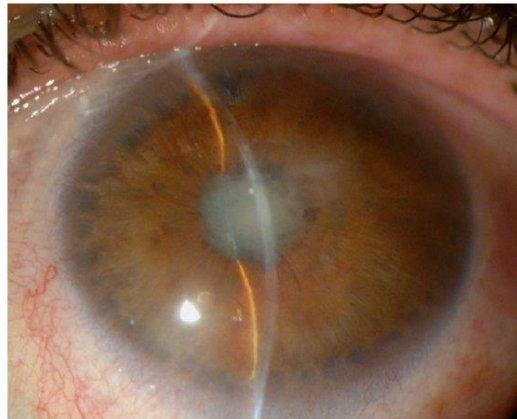


Figure 17. Iris bombe, as may be seen in aphakic pupillary block (Source: Muñoz-Negrete, Moreno-Montañés, Hernández-Martínez, Rebolleda, 2015.)⁸⁶

12.3.2. Late postoperative complications

Late postoperative complications are complications arising later than 6 weeks after cataract surgery. Most common late postoperative complications of cataract surgery include posterior capsular opacification, pseudophakic glaucoma, postoperative IOL dislocation, rhegmatogenous retinal detachment, anterior capsular contraction syndrome, cystoid macular edema, chronic postoperative endophthalmitis and pseudophakic bullous keratopathy.

12.3.2.1. Posterior capsular opacification

Posterior capsular opacification (PCO), also known as ‘*secondary cataract*’, is the most common late complication of uneventful cataract surgery. Its incidence increases steadily over the first five 5 postoperative years, and is seen in up to 25% of adults after cataract surgery. The overall incidence of PCO at 1,3 and 5 years postoperatively is 11.8%, 20.7% and 28.4%, respectively. PCO is an especially major problem in pediatric surgery, where its incidence approaches 100%.

PCO is caused by proliferation of lens epithelial cells which have remained in the capsular bag following cataract surgery. In the normal lens, epithelial cells are found at the anterior and equatorial region. Epithelial cells at the central zone have minimal mitotic activity, unlike the epithelial cells at equatorial regions which are a source of new lens fibers throughout life. Most cases of PCO are caused by the excessive proliferation of equatorial zone cells and their subsequent migration onto the posterior capsular surface. Several patterns of opacification have been described, including vacuolated (pearl-type) PCO, Soemmering ring, and fibrosis-type PCO. Vacuolated (pearl-type) opacifications consist of clusters of proliferating, swollen, opacified, bullous-like cells (Wedl cells) which have migrated from the equatorial region. When grouped into clusters at the edges of capsulotomy, they are commonly termed 'Elschnig pearls'. Proliferation of equatorial cells can also lead to formation of Soemmering ring, a whitish annular or donut-shaped lesion in the periphery of the capsular bag. Soemmering ring used to be seen more commonly seen following older methods of cataract surgery, but is rare today. Lastly, a fibrosis-type PCO is a consequence of fibrous metaplasia of lens epithelial cells originating from the central region. Equatorial epithelial cells can also contribute to formation of fibrous PCO, especially when cataract surgery has been delayed.

PCO presents with slowly worsening blurring and glare, with variably reduced visual acuity. Observed amount of PCO does not always correlate with the visual symptom severity. If the opacities are visually significant, a Nd:YAG laser posterior capsulotomy is employed. Using laser power initially set at 1 mJ/pulse, a series of punctures is created in circumferential or cruciate patterns. The created opening should match the size of physiologically dilated pupil (4-5 mm). Posterior capsulotomy is rarely associated with complications including transient risk in IOP, retinal detachment, CME, IOL damage, pitting or subluxation, endophthalmitis and vitreous prolapse. Hence, higher threshold of treatment should be adopted in high-risk patients, such as patients with high myopia, history of uveitis and pseudoexfoliation syndrome. Furthermore, total energy used should be less than 80 mJ, reducing the risk of significant IOP spike ^{11,87,88}.

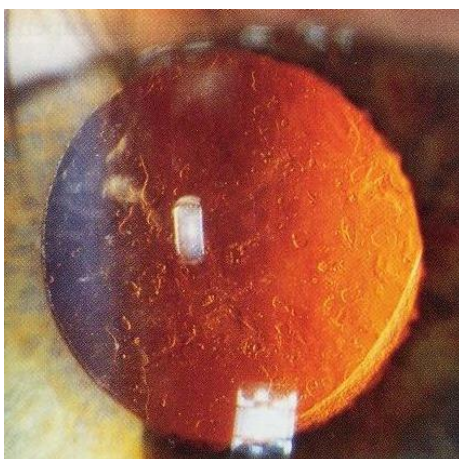


Figure 18. Posterior capsular opacification (image acquired from https://hr.m.wikipedia.org/wiki/Datoteka:Posterior_capsular_opacification_on_retroillumination.jpg , accessed on 9.6.2022.)

12.3.2.2. Pseudophakic glaucoma

Pseudophakic glaucoma is a secondary glaucoma developing after cataract surgery with IOL implantation. Even though transient increases in IOP are seen in up to 50% of patients on the first postoperative day, chronic pseudophakic glaucoma is much less common, seen in 2.1% - 4% of patients. Many different mechanisms are involved in postsurgical increase in IOP. Additionally, the combination of several different mechanism is possible. In the past, previous cataract surgery techniques were associated with distortion of the anterior chamber angle, negatively affecting the aqueous outflow. Modern cataract surgeries actually deepen the anterior chamber, reducing the intraocular pressure. Viscoelastic substances used during cataract surgery are associated with increases in postsurgical IOP due to obstruction of the trabecular meshwork. Compared to cohesive viscoelastics, dispersive viscoelastics are more likely to increase IOP. Excessive postoperative inflammation or uveitis-glaucoma-hyphema syndrome may lead to obstruction or fibrosis of the trabecular meshwork, preventing the aqueous outflow and leading to rise in IOP. Other possible causes of trabecular meshwork obstruction include iris pigment dispersion, use of alpha-chymotrypsin enzymatic zonulolysis previously used for intracapsular cataract removal, small cortical or nuclear pieces of lens obstruction, and ghost cell glaucoma – a condition in which red blood cells lacking hemoglobin obstruct the aqueous outflow. Additionally, IOP may rise due to pupillary block, as described earlier. Finally, Nd:YAG laser posterior capsulotomy can in rare cases lead to long term increase in IOP.

Diagnostic workup of pseudophakic glaucoma patient is similar to that of phakic eye. Gonioscopy is used to visualize angle morphology and check for presence of lens fragments. Biomicroscopy is employed to visualize anterior eye segment. Close monitoring of IOP is carried out with applanation tonometry. Medical treatment is preferred in cases of late postoperative glaucoma. Medications including carbonic anhydrase inhibitors, prostaglandin analogs, alpha 2 antagonists or beta blockers are used. In cases where medical management is insufficient, surgical treatment is employed, including iridotomy, trabeculectomy and vitrectomy. Unfortunately, trabeculectomy failure rates are, on average, 4.6 times higher in pseudophakic patients. Finally, glaucoma drainage devices may be used to provide continuous IOP depression ⁸⁹.

12.3.2.3. Postoperative dislocation of the IOL

Postoperative dislocation of the IOLs is one of the most commonly encountered complications arising after cataract surgery, reported at a rate of 0.2% to 3%. It may occur as an early or late complication. Early dislocation occurs within three months of IOL implantation as is associated with poor fixation of the IOL or capsular/zonular rupture during the surgery. On the other hand, late dislocation is a consequence of progressive zonular insufficiency and contraction of the anterior capsule. Dislocation of the IOL may present as pseudophacodonesis, decentration within the bag or sulcus, partial subluxation, or complete dislocation. Complete dislocation can further be divided into out-of-the-bag dislocation, where IOL slides out of the bag, and in-the-bag dislocation, whereas the entire IOL within the capsular bag dislocates. IOL dislocation risk is related to the integrity of the capsular bag and lens zonules. Capsular bag instability and zonular weakness are more common in patients with history of previous ocular surgery, trauma, uveitis, retinitis pigmentosa, diabetes mellitus, atopic dermatitis, older patients, patients with axial myopia and patients with connective tissue diseases such as pseudoexfoliation syndrome, Marfan syndrome and Ehlers-Danlos syndrome. Pseudoexfoliation syndrome is the most common risk factor, present in more than 50% of cases.

Patients with IOL dislocation may present with decrease in visual acuity, diplopia, glare, ocular pain and headaches. A detailed and complete examination of anterior and posterior chamber is required for the diagnosis. In cases where IOL subluxation is minimal and without impact on vision and surrounding ocular structures, observation may be a suitable management. If vision is affected or there is damage to the ocular structures, surgery is

indicated. Most common indications for surgery include monocular diplopia, decreased visual acuity, halos, retinal detachment, glaucoma and uveitis-glaucoma-hyphema syndrome. Surgery usually involves PPV to remove the dislocated lens, followed by secondary IOL implantation. IOL exchange is the most common surgical option. If adequate capsular support is present, IOL may be placed in the posterior chamber or sulcus. However, if lens capsule is inadequate to support the IOL, anterior chamber IOLs can be used instead. Possible complications of IOL dislocation include recurrent dislocation, retinal detachment, hypopyon, bleeding, corneal damage, CME, and elevation of the intraocular pressure. Despite the possible complications, patients with IOL dislocation have good post-surgical outcomes, with more than 85% of patients achieving 20/40 or better acuity. Close follow-up may allow for avoidance of possible complications ^{11,90}.

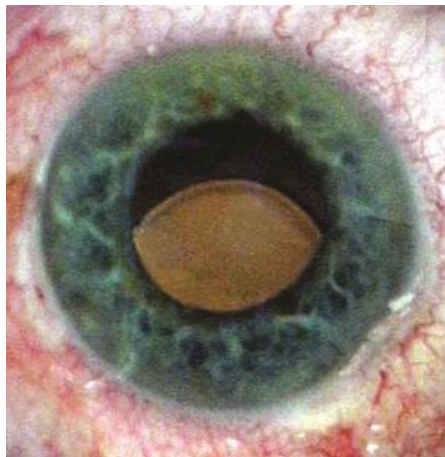


Figure 19. Dislocated IOL (image acquired from

<https://www.reviewofophthalmology.com/article/how-to-manage-dislocated-iols> , accessed on 9.6.2022.)

12.3.2.4. Rhegmatogenous retinal detachment

Rhegmatogenous retinal detachment (RRD) is a term used to describe detachment of neurosensory retina from the underlying retinal pigment epithelium due to retinal tear which allows vitreous humor to penetrate under the retina. The incidence of RRD is estimated between 0.6% and 1.7% within the first postoperative year. When compared to general population, RRD is four times more common in cataract surgery patients. Certain patient factors, such as male sex, young age, presence of lattice degeneration, retinal breaks and high myopia increase the risk of RRD following surgery. Myopia is especially significant, with shortsightedness up to -3 D and more than -3 D increasing the risk fourfold and tenfold,

respectively. Likewise, intraoperative posterior capsular rupture and vitreous loss predispose to RRD development.

Most patients will report visual phenomena before the onset of retinal detachment. Possible phenomena include newly formed opacities, flashes of light, gray or black shadows and significant worsening of vision (if detachment reaches the optic fovea). On fundoscopy, a 'dune-like' appearance and mobility of the retina can be appreciated. In about 80% of patients the retinal hole can be visualized. In other 20% the hole is located peripherally and is easy to overlook. Despite these visual phenomena, it is estimated that 50% to 70% of patients will present too late, already at the stage of detached macula. Such patients have unfavorable prognosis. The treatment includes laser coagulation or cryocoagulation for scar induction, or scleral buckling or vitrectomy for hole closure. Laser light heats the retinal pigment epithelium to 60 °C, leading to coagulation necrosis. Similarly, cryocoagulation induces necrosis by freezing the eyeball from the outside to the retina by a cryoprobe cooled to -80 °C. Both procedures induce scar formation, but are only viable if the sensory retina is in contact with retinal pigment epithelium. Scleral buckling and vitrectomy are used when the retina has already detached from pigment epithelium. Before scleral buckling is performed, the holes are treated with cryopexy. Scleral buckling involves reducing the traction exerted on the holes by the vitreous by using a foam sponge or silicone band placed around the eyeball, with reattachment rates of up to 90%. Vitrectomy is an alternative, which begins by removal of the vitreous causing the detachment. Subretinal fluid is then displaced using a tamponade, and scarring of the retina is achieved via laser or cryocoagulation. Finally, vitreous is replaced by a tamponade which presses the retina against retinal pigment epithelium, preventing further detachment. A mixture of air/gas or silicone oil tamponade can be used for this purpose. Air/gas mixture (sulfur hexafluoride, perfluoroethane, perfluoropropane) are chosen in simpler situations, and have the advantage of spontaneous absorption over time. However, it carries a risk of overexpansion and pressure decompensation, so the patient should avoid changes in altitude. Furthermore, it results in massive refraction changes (up to -50 D). On the other hand, silicone oil is used in more complicated cases, with its stability being a major advantage. The disadvantage of using silicone oil is the need for additional surgery to remove it. Reattachment rates of up to 90% are achievable when using vitrectomy ^{11,91,92}.

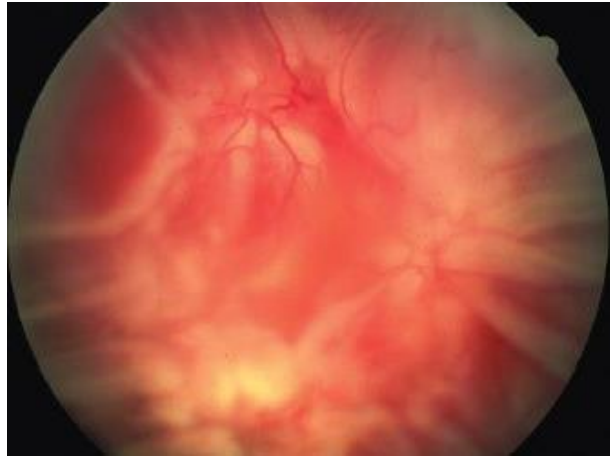

Figure 20. Rhegmatogenous retinal detachment, as may be seen following cataract extraction surgery (image acquired from <https://entokey.com/50-rhegmatogenous-retinal-detachment/> , accessed on 9.6.2022.)

12.3.2.5. Anterior capsular contraction syndrome

Anterior capsular contraction syndrome (ACCS), also known as capsular phimosis, is defined as exaggerated reduction of the capsular bag diameter, resulting from the contact of lens epithelial cells with the IOL near the edge of continuous curvilinear capsulorrhexis. ACCS most commonly develops within the first 3 months of surgery, with estimated incidence of 0.21% to 1.4%. Risk of capsular phimosis is correlated to type of implanted IOLs, with silicone IOLs leading to a greater contraction rates when compared to their acrylic counterparts. Known risk factors include pseudoexfoliation syndrome, small capsulorrhexis, retinitis pigmentosa, uveitis, history of retinal surgery and diabetic retinopathy. Patients with pseudoexfoliation syndrome can have postoperative rates of anterior capsule contraction of up to 25%.

If significant contraction of the anterior capsule occurs, the capsular opening may become smaller than the pupillary area, thereby limiting the amount of light entering the eye. Small area of the anterior capsular opening is associated with significant reduction in contrast sensitivity, but not with a decrease in visual acuity. If ACCS becomes visually significant, Nd:YAG anterior capsulotomy is employed. By creating 4 or 6 radial relaxing incisions, the anterior capsular opening is significantly enlarged, improving contrast sensitivity^{11,93,94}.

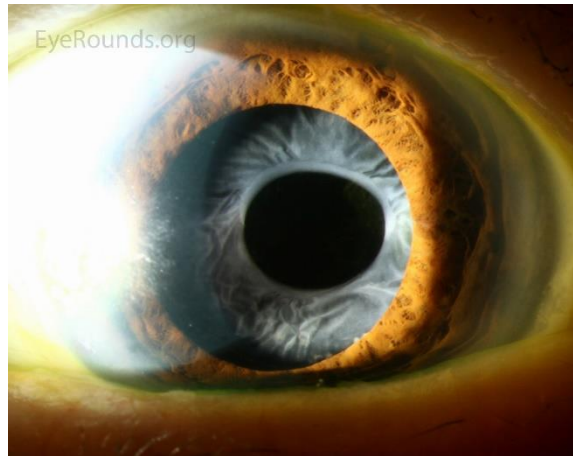


Figure 21. Contraction of the anterior capsule (image acquired from <http://www.eyerounds.org/atlas/pages/Capsular-Phimosis/index.htm> , accessed on 9.6.2022.)

12.3.2.6. Cystoid macular edema

Cystoid macular edema is a retinal thickening of the macula caused by accumulation of fluid within the outer plexiform and inner nuclear layers of retina, with formation of cyst-like cavities. Fluid is initially accumulated in Muller cells, which subsequently rupture. Retinal thickening and fluid collection lead to distortion of the photoreceptor architecture, causing central vision loss. CME is associated with several causes, including ocular surgery, retinal vascular disease, ocular inflammation, use of topical prostaglandin derivatives, retinal dystrophies and more. Postoperative CME is observed in 0.1-1% of modern cataract surgeries, with peak incidence at 6-10 weeks following the surgery. Operative complications which increase the risk of postoperative CME include posterior capsular rupture with vitreous loss, implantation of anterior chamber IOL and need for secondary IOL implantation.

Patients with CME may be completely asymptomatic, or may develop symptoms including blurring, which is especially prominent when performing near tasks, positive central scotomas, micropsia and metamorphopsia (distortion of shape of the object). Amsler chart will demonstrate the central blurring and distortion. On fundoscopy, loss of foveal depression, retinal thickening and cystoid areas will be observed. Furthermore, optic disc swelling can sometimes be noticed. Optical coherence tomography will show loss the retinal thickening along with cystic, hyporeflective spaces. Finally, when fluorescent angiography is performed, a 'petaloid' pattern will be seen due to dye accumulation in the cystic spaces within the outer plexiform layer of the retina. Treatment of CME involves one or combination of several modalities, including Nd:YAG laser, medical therapy and PPV.

Nd:YAG laser is used to cut any vitreous strands extending to the cataract incision. Topical nonsteroidal anti-inflammatory drugs, including diclofenac, ketorolac, bromfenac and nepafenac may be beneficial. However, treatment may take up to several months. Periocular or intravitreal injections of triamcinolone acetate can also be used. Finally, PPV may be useful for cases refractory to medical therapy ^{11,95}.

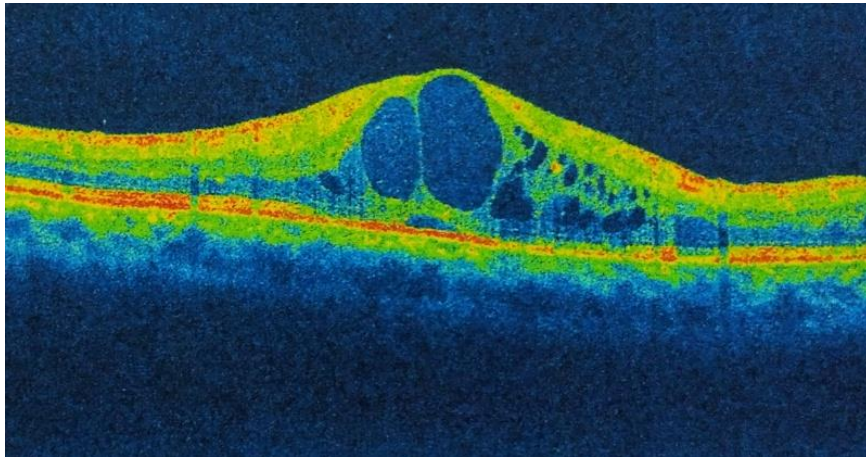


Figure 22. Intraretinal cystoid spaces visualized via optical coherence tomography (image acquired from https://eyewiki.aao.org/File:Cystoid_Macular_Edema.jpeg#filelinks , accessed on 9.6.2022.)

12.3.2.7. Chronic postoperative endophthalmitis

Chronic postoperative endophthalmitis (CPE) is an intraocular inflammation presenting later than 6 weeks post-surgery, with a mean onset of 9 months. It is an uncommon complication with incidence ranging from 0.01% to 0.37%, depending on the surgical procedure and geographical location. Unlike APE, the CPE is caused by organisms of low virulence, including indolent bacteria and fungi. *Propionibacterium acnes*, a small gram-positive rod, is the most common causative agent seen in 48.3% of cases. It is largely resistant to eradication within phagocytes, leading to chronic inflammatory response. Fungi cause additional 21% of CPE, with *Candida* species being the most common. Their resistant fungal cell walls shield them from immune attack and antibiotic therapy, making fungal cases particularly resistant to treatment. Finally, other possible causative agents include other gram-positive organisms (16%), gram-negative species (6.4%), mycobacteria (3.2%) and mixed infections (4.8%). Possible routes of microbial entry include irrigation fluids, surgical instruments and intraocular lenses. Posterior capsular tears, Nd:YAG laser capsulotomy and diabetes mellitus are all known predisposing factors of developing CPE.

CPE presents with mild progressive visual degeneration and visible floaters. Unlike in APE, pain is not present. On clinical examination low-grade anterior uveitis, vitritis and capsular plaque may be observed. Uveitis initially involves the anterior chamber with later progression to the vitreous. Inflammation initially responds to topical steroids, but recurs when treatment is stopped. Paradoxically, in cases of fungal CPE the steroids may worsen the clinical picture. When CPE is suspected, analysis of aqueous and vitreous samples should be done. Differential diagnoses of CPE include noninfectious causes, such as lens-induced uveitis secondary to retained lens material, IOL-induced uveitis secondary to malposition, and other causes of uveitis which are unrelated to surgery. Intravitreal antibiotics are the first line treatment of CPE, but are often inadequate when used in isolation, particularly with *P.acnes* which is associated with high recurrence rate (up to 90%) when treated with antibiotics alone. In such cases pars plana vitrectomy with capsulotomy and IOL exchange may be required. Intravitreal vancomycin (0.1 mg in 0.1 mL) is the antibiotic of choice due to its broad gram-positive coverage. In cases of fungal CPE, current approach consists of PPV, intravitreal amphotericin (5-10 mg/0.1 mL) and a systemic antifungal drug. Voriconazole is an alternative to amphotericin. Prolonged systemic treatment (6 weeks up to 6 months) may be required. In cases of corneal involvement, topical treatment with 5% natamycin can be started. Overall, bacterial CPE carries better prognosis, with 50-54.5% of patients having visual acuity 20/40 or better. In comparison, only 38.5% of patients with fungal CPE will have visual acuity of 20/40 or better. Furthermore, visual acuity of <5/200 is more commonly seen after fungal than bacterial CPE (23% vs. 10%-12%, respectively) ^{11,96}.

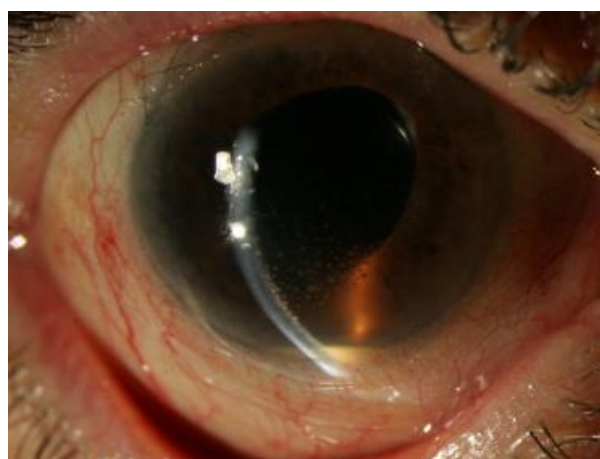


Figure 23. Hypopyon and granulomatous corneal precipitates associated with chronic endophthalmitis caused by *P.acnes* (Source: Themes, 2017.) ⁹⁷

12.3.2.8. Pseudophakic bullous keratopathy

Pseudophakic bullous keratopathy (PBK) is a clinical condition characterized by irreversible corneal edema which develops after cataract surgery. PBK can be seen after any intraocular surgery, but is most commonly reported following phacoemulsification. Current reported rates of this complication are estimated at 0.1%. The incidence is higher when anterior chamber lenses or iris fixated lenses are used (1.2% and 1.5%, respectively). PBK is triggered by the endothelial cell loss which occurs during ocular surgery, due to high energy use during phacoemulsification and high irrigation and aspiration. Diseases affecting corneal endothelium, such as Fuchs endothelial dystrophy, diabetes mellitus and pseudoexfoliation syndrome further predispose to postoperative PBK development. Due to endothelial cell loss, the cornea loses the ability to maintain its transparency. In a healthy cornea, the endothelial cells prevent water and electrolyte influx via sodium/potassium ATP pumps located in their lateral cell membranes. Approximately 700 cells/mm² are required to maintain corneal transparency. At birth, average of 7500 cells/mm² are present, with the number dropping to 2700 cells/mm² by adulthood. After the age of 20, 0.5% of cells are lost each year. 1000 cells / mm² is considered a critical level, below which a high risk of decompensation is present. When the cell density reaches 300 to 500 cells/mm², PBK develops. An estimated 5.5% - 10% of endothelial cells are lost during phacoemulsification, greatly accelerating the decline in numbers which is seen with normal aging. Hence, patients at risk (old age, Fuchs dystrophy) need to be informed about potential corneal clouding after cataract extraction. After the initial endothelial cell insult, there is progressive swelling of the corneal stroma, finally reaching subepithelial and epithelial layers and resulting in bullae formation.

PBK is a progressive disease presenting with gradually progressive blurring and vision loss. Other possible symptoms and signs include ocular pain, photophobia, ocular irritation, foreign body sensation, halos around the light and redness. Blurring tends to be more severe in the morning, and improves during the day. Biomicroscopy of the anterior segment will reveal epithelial defects, edema, microcysts and bullae. Subepithelial and stromal layer scarring and hazing, and Descemet folds will also be visible. Fuchs dystrophy and other endothelial dystrophies should be searched for on both eyes. Specular microscopy is a mean of photographic mapping of the corneal endothelium, which can give us information about corneal cell density. Likewise, ultrasound pachymetry will show thickening of the cornea due to edema. Management of PBK includes topical medication, contact lenses and surgical interventions. Hyperosmotic agents such as 5% sodium chloride solution act by forming a

hypertonic tear film, dehydrating the cornea. Antiglaucoma drugs, including beta-blockers and alpha agonists, work by reducing intraocular pressure, thereby reducing corneal edema. Carbonic anhydrase inhibitors should be avoided due to their toxicity towards epithelium. Topical steroids can be used to reduce acute inflammation, but epithelial defects need to be excluded before starting a steroid regimen. Lubricants, such as artificial tears and gels, are used to lubricate the cornea and prevent irritation and dryness. Soft contact lenses can be helpful in management of patients with PBK by alleviating pain, protecting against infectious keratitis, and improving visual acuity (especially when used in conjunction with hypertonic saline solution). Medical treatment is mostly used for symptomatic relief, with corneal transplantation being a definite treatment. Gunderson conjunctival flaps and amniotic membrane grafts can be used to cover the defective corneal epithelium, thereby aiding in healing. Unfortunately, many patients eventually require corneal transplantation. PBK is one of the most common indications for corneal transplantation. Transplantation options include full thickness transplant (penetrating keratoplasty) or lamellar transplant (Descemet stripping automated endothelial keratoplasty). Proper and timely keratoplasty in PBK cases carries a good prognosis^{98,99}.

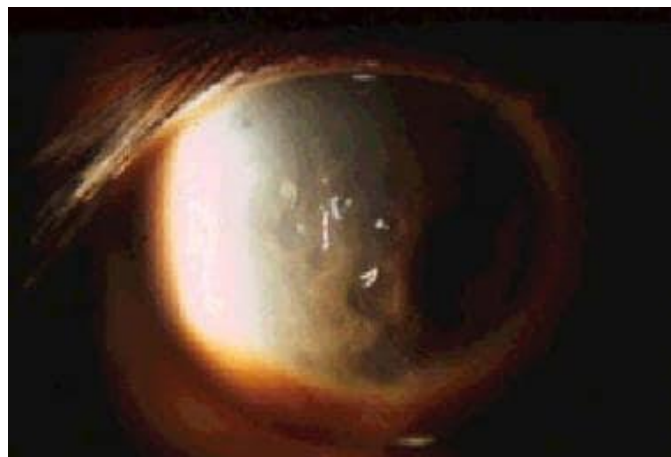

Figure 24. Pseudophakic bullous keratopathy (image acquired from <https://emedicine.medscape.com/article/1193218-overview> , accessed on 9.2.2022.)

13. Conclusion

Cataracts, defined as clouding of the crystalline lens, are one of the most common causes of visual impairment worldwide, accounting for more than 20 million cases of blindness. Due to advanced age being the most important risk factor for development of cataracts, their number is expected to increase in the future due to aging of the general population. Based on the time of onset, cataracts can be classified as congenital (presenting at birth or within the first year of life) or acquired (presenting after the first year of life). The exact pathogenetic process of cataract formation has not been fully understood. However, it is known that certain factors, including genetic mutations, intrauterine infections, exposure to ionizing radiation, endocrine and metabolic abnormalities, ocular trauma and drug exposure increase the risk of cataract formation. Morphologically, cataracts can be divided into 3 groups: nuclear sclerotic, cortical and posterior subcapsular cataracts. This is a gross oversimplification, but is useful in research and clinical practice. Patients with cataracts may experience myopic shift, monocular diplopia, contrast sensitivity reduction, appearance of glare, color shift towards higher wavelengths, field loss and reduction in visual acuity.

Since the modest beginnings of cataract extraction surgery in ancient India, surgical technique has been highly refined. Today, modern-day cataract extraction surgery promises good visual outcomes, shorter recovery times and lower incidence of operative complications. Despite these advances, preoperative, intraoperative and postoperative complications are still possible and are regularly seen in practice. The goal of ophthalmologic profession and its professionals should be to reduce the incidence of surgical complications, refine their management, and improve the outcomes in affected patients.

14. Acknowledgements

I would like to express my deepest thanks to prof.dr.sc. Miro Kalauz for his consultation, guidance and allocated time in writing this thesis. I would also like to thank my family for their understanding and patience during my studies. Finally, I would like to thank Klara for her unlimited support in everything I do.

15. References

1. WHO EMRO | Cataract | Health topics. *World Health Organization - Regional Office for the Eastern Mediterranean* [Internet]. [Cited on 1.6.2022.]. Available from: <http://www.emro.who.int/health-topics/cataract/>.
2. Mandal, A. Cataract History. *News-Medical.net* [Internet]. February 2019. [Cited on 1.6.2022.] Available from: <https://www.news-medical.net/health/Cataract-History.aspx>.
3. Čupak, K. Starenje i katarakta. In: Čupak K, ed. *Oftalmologija*. Zagreb: Nakladni zavod Globus; 2004. p.569–570. (Second edition)
4. Asbell, P. A. *et al.* Age-related cataract. *Lancet Lond. Engl.* **365**, 599–609 (2005).
5. Hashemi, H. *et al.* Global and regional prevalence of age-related cataract: a comprehensive systematic review and meta-analysis. *Eye Lond. Engl.* **34**, 1357–1370 (2020).
6. Wu, X., Long, E., Lin, H. & Liu, Y. Prevalence and epidemiological characteristics of congenital cataract: a systematic review and meta-analysis. *Sci. Rep.* **6**, 28564 (2016).
7. Donaldson, P. J., Grey, A. C., Maceo Heilman, B., Lim, J. C. & Vaghefi, E. The physiological optics of the lens. *Prog. Retin. Eye Res.* **56**, e1–e24 (2017).
8. Čupak, K. Leća. In: Čupak K, ed. *Oftalmologija*. Zagreb: Nakladni zavod Globus; 2004. p.567-569. (Second edition).
9. Hejtmancik, J. F. & Shiels, A. Overview of the Lens. *Prog. Mol. Biol. Transl. Sci.* **134**, 119–127 (2015).
10. Sharma, K. K. & Santhoshkumar, P. Lens Aging: Effects of Crystallins. *Biochim. Biophys. Acta* **1790**, 1095–1108 (2009).
11. John F. Salmon. *Kanski's Clinical Ophthalmology, A Systematic Approach*. Elsevier; 2020. (Ninth edition).
12. Štriga, M. Fizikalna svojstva leće. In: Čupak K, ed. *Oftalmologija*. Zagreb: Nakladni zavod Globus; 2004. p.109-111. (Second edition)
13. Motlagh, M. & Geetha, R. Physiology, Accommodation. in *StatPearls* (StatPearls Publishing, 2022).
14. Roskamp, K. W., Paulson, C. N., Brubaker, W. D. & Martin, R. W. Function and Aggregation in Structural Eye Lens Crystallins. *Acc. Chem. Res.* **53**, 863–874 (2020).
15. Lloyd, I. C. *et al.* Neonatal cataract: aetiology, pathogenesis and management. *Eye Lond. Engl.* **6 (Pt 2)**, 184–196 (1992).
16. Hejtmancik, J. F. Congenital cataracts and their molecular genetics. *Semin. Cell Dev. Biol.* **19**, 134–149 (2008).

17. Čupak, K. Etiologija kongenitalne katarakte. In: Čupak K, ed. Oftalmologija. Zagreb: Nakladni zavod Globus; 2004. p.580-582. (Second edition).
18. Kumar, D., Lim, J. C. & Donaldson, P. J. A link between maternal malnutrition and depletion of glutathione in the developing lens: a possible explanation for idiopathic childhood cataract? *Clin. Exp. Optom.* **96**, 523–528 (2013).
19. A.K. Khurana. *Comprehensive ophthalmology, fourth edition*. New Age International; 2007.
20. Gupta, V. B., Rajagopala, M. & Ravishankar, B. Etiopathogenesis of cataract: An appraisal. *Indian J. Ophthalmol.* **62**, 103–110 (2014).
21. Stambolian, D. Galactose and cataract. *Surv. Ophthalmol.* **32**, 333–349 (1988).
22. Haargaard, B., Wohlfahrt, J., Rosenberg, T., Fledelius, H. C. & Melbye, M. Risk factors for idiopathic congenital/infantile cataract. *Invest. Ophthalmol. Vis. Sci.* **46**, 3067–3073 (2005).
23. Tan, J. S. L. *et al.* Smoking and the long-term incidence of cataract: the Blue Mountains Eye Study. *Ophthalmic Epidemiol.* **15**, 155–161 (2008).
24. Minassian, D. C., Mehra, V. & Verrey, J. D. Dehydrational crises: a major risk factor in blinding cataract. *Br. J. Ophthalmol.* **73**, 100–105 (1989).
25. Yu, X., Lyu, D., Dong, X., He, J. & Yao, K. Hypertension and risk of cataract: a meta-analysis. *PloS One* **9**, e114012 (2014).
26. Čupak, K. Traumatske katarakte (cataracta traumatica). In: Čupak K, ed. Oftalmologija. Zagreb: Nakladni zavod Globus; 2004. p.600-603. (Second edition).
27. Shaw, E. & Patel, B. C. Complicated Cataract. in *StatPearls* (StatPearls Publishing, 2022).
28. Čupak, K. Katarakte povezane sa sustavnim bolestima. In: Čupak K, ed. Oftalmologija. Zagreb: Nakladni zavod Globus; 2004. p.591-595. (Second edition).
29. James, E. R. The etiology of steroid cataract. *J. Ocul. Pharmacol. Ther. Off. J. Assoc. Ocul. Pharmacol. Ther.* **23**, 403–420 (2007).
30. Čupak, K. Kortikosteroidna katarakta. In: Čupak K, ed. Oftalmologija. Zagreb: Nakladni zavod Globus; 2004. p.594-595. (Second edition)
31. Gong, Y., Feng, K., Yan, N., Xu, Y. & Pan, C.-W. Different amounts of alcohol consumption and cataract: a meta-analysis. *Optom. Vis. Sci. Off. Publ. Am. Acad. Optom.* **92**, 471–479 (2015).
32. Čupak, K. Katarakta izazvana toplinskim (infracrvenim) zrakama. In: Čupak K, ed. Oftalmologija. Zagreb: Nakladni zavod Globus; 2004. p.603. (Second edition).

33. Lipman, R. M., Tripathi, B. J. & Tripathi, R. C. Cataracts induced by microwave and ionizing radiation. *Surv. Ophthalmol.* **33**, 200–210 (1988).
34. Čupak, K. Katarakta izazvana električnim šokom. In: Čupak K, ed. *Oftalmologija*. Zagreb: Nakladni zavod Globus; 2004. p.603. (Second edition).
35. Brown, N. A. P. The morphology of cataract and visual performance. *Eye* **7**, 63–67 (1993).
36. Čupak, K. Senilne katarakte. In: Čupak K, ed. *Oftalmologija*. Zagreb: Nakladni zavod Globus; 2004. p.586-588. (Second edition).
37. Moshirfar, M., Milner, D. & Patel, B. C. Cataract Surgery. in *StatPearls* (StatPearls Publishing, 2022).
38. Superstein, R. Indications for cataract surgery. *Curr. Opin. Ophthalmol.* **12**, 58–62 (2001).
39. Steinberg, E. P. *et al.* The VF-14. An index of functional impairment in patients with cataract. *Arch. Ophthalmol. Chic. Ill 1960* **112**, 630–638 (1994).
40. See, C. W., Iftikhar, M. & Woreta, F. A. Preoperative evaluation for cataract surgery. *Curr. Opin. Ophthalmol.* **30**, 3–8 (2019).
41. Malik, A., Fletcher, E. C., Chong, V. & Dasan, J. Local anesthesia for cataract surgery. *J. Cataract Refract. Surg.* **36**, 133–152 (2010).
42. Sugihara, K., Tanito, M., Takai, Y. & Ohira, A. Causes of intracapsular cataract extraction, explantation of intraocular lenses and suture scleral fixation of intraocular lenses in the modern era. *Acta Ophthalmol. (Copenh.)* **96**, e262–e263 (2018).
43. Čupak, K. Intrakapsularna ekstrakcija katarakte. In: Čupak K, ed. *Oftalmologija*. Zagreb: Nakladni zavod Globus; 2004. p.612-614. (Second edition).
44. Koenig, S. B. Intracapsular cataract extraction for the management of dense cataracts and zonular weakness. *J. Clin. Ophthalmol.* **3**, (2019).
45. Rajkarnikar, S. *et al.* Comparative Study of Extra Capsular Cataract Extraction (ECCE) and Small Incision Cataract Surgery (SICS): Experience on Cataract Surgery in a Tertiary Center of Army Hospital, Kathmandu. *Nepal. J. Ophthalmol. Biannu. Peer-Rev. Acad. J. Nepal Ophthalmic Soc. NEPJOPH* **10**, 162–167 (2018).
46. Čupak, K. Ekstrakapsularna ekstrakcija katarakte. In: Čupak K, ed. *Oftalmologija*. Zagreb: Nakladni zavod Globus; 2004. p.614-617. (Second edition).
47. Dizon Ocampo, V. V. & Foster, C. S. What is the role of extracapsular cataract extraction in the treatment of senile cataract (age-related cataract)? [Internet]. March 2021. [Cited on 15.5.2022.]. Available from: <https://www.medscape.com/answers/1210914->

161517/what-is-the-role-of-extracapsular-cataract-extraction-in-the-treatment-of-senile-cataract-age-related-cataract.

48. Venkatesh R, Chang DF, Muralikrishnan R, Hemal K, Gogate P, Sengupta S. Manual Small Incision Cataract Surgery: A Review. *Asia-Pacific Journal of Ophthalmology*. 2012;1(2):113–9.
49. Ang, M., Evans, J. R. & Mehta, J. S. Manual small incision cataract surgery (MSICS) with posterior chamber intraocular lens versus extracapsular cataract extraction (ECCE) with posterior chamber intraocular lens for age-related cataract. *Cochrane Database Syst. Rev.* CD008811 (2014) doi:10.1002/14651858.CD008811.pub3.
50. Linebarger, E. J., Hardten, D. R., Shah, G. K. & Lindstrom, R. L. Phacoemulsification and Modern Cataract Surgery. *Surv. Ophthalmol.* **44**, 123–147 (1999).
51. Gabrić, N., Čupak, K., Dekaris, I. & Karaman-Martinović, Ž. Fakoemulzifikacija. In: Čupak K, ed. *Oftalmologija*. Zagreb: Nakladni zavod Globus; 2004. p.655-665. (Second edition).
52. Minassian, D. C. *et al.* Extracapsular cataract extraction compared with small incision surgery by phacoemulsification: a randomised trial. *Br. J. Ophthalmol.* **85**, 822–829 (2001).
53. George, R. *et al.* Comparison of endothelial cell loss and surgically induced astigmatism following conventional extracapsular cataract surgery, manual small-incision surgery and phacoemulsification. *Ophthalmic Epidemiol.* **12**, 293–297 (2005).
54. Roberts, H. W., Day, A. C. & O’Brart, D. P. Femtosecond laser-assisted cataract surgery: A review. *Eur. J. Ophthalmol.* **30**, 417–429 (2020).
55. Flores-Sánchez, D. B. C. & Tatham, M. A. J. Acute angle closure glaucoma. *Br. J. Hosp. Med.* **80**, 6 (2019).
56. Ah-kee, E. Y., Egong, E., Shafi, A., Lim, L. T. & Yim, J. L. A review of drug-induced acute angle closure glaucoma for non-ophthalmologists. *Qatar Med. J.* **2015**, 6 (2015).
57. Iftikhar, M. *et al.* Pharmacologic interventions for mydriasis in cataract surgery. *Cochrane Database Syst. Rev.* **2021**, CD012830 (2021).
58. Zaharia, A.-C., Dumitrescu, O.-M., Rogoz, R.-E., Dimirache, A. E. & Zemba, M. Preoperative antisepsis in ophthalmic surgery (a review). *Romanian J. Ophthalmol.* **65**, 120–124 (2021).
59. Grzybowski, A., Kanclerz, P. & Myers, W. G. The use of povidone-iodine in ophthalmology. *Curr. Opin. Ophthalmol.* **29**, 19–32 (2018).

60. Wykoff, C. C., Flynn, H. W. & Han, D. P. Allergy to povidone-iodine and cephalosporins: the clinical dilemma in ophthalmic use. *Am. J. Ophthalmol.* **151**, 4–6 (2011).
61. Lachapelle, J.-M. Allergic contact dermatitis from povidone-iodine: a re-evaluation study. *Contact Dermatitis* **52**, 9–10 (2005).
62. Thevi, T. & Godinho, M. A. Trends and complications of local anaesthesia in cataract surgery: an 8-year analysis of 12 992 patients. *Br. J. Ophthalmol.* **100**, 1708–1713 (2016).
63. Reddy, S. C. & Thevi, T. Local anaesthesia in cataract surgery. *Int. J. Ophthalmic Res.* **3**, 204–210 (2017).
64. Harris, M. & Chung, F. Complications of general anesthesia. *Clin. Plast. Surg.* **40**, 503–513 (2013).
65. Chan, E., Mahroo, O. A. R. & Spalton, D. J. Complications of cataract surgery. *Clin. Exp. Optom.* **93**, 379–389 (2010).
66. Low, S. A. W., Braga-Mele, R., Yan, D. B. & El-Defrawy, S. Intraoperative complication rates in cataract surgery performed by ophthalmology resident trainees compared to staff surgeons in a Canadian academic center. *J. Cataract Refract. Surg.* **44**, 1344–1349 (2018).
67. Hashemi, H. *et al.* Intraoperative Complications of Cataract Surgery in Tehran Province, Iran. *Optom. Vis. Sci. Off. Publ. Am. Acad. Optom.* **93**, 266–271 (2016).
68. Marques, F. F., Marques, D. M. V., Osher, R. H. & Osher, J. M. Fate of anterior capsule tears during cataract surgery. *J. Cataract Refract. Surg.* **32**, 1638–1642 (2006).
69. Venkateswaran, N., Mendez, C. M. & Amescua, G. Perioperative Management of Dropped Lenses: Anterior and posterior segment considerations and treatment options. *Int. Ophthalmol. Clin.* **60**, 61–69 (2020).
70. Hazzazi, M. A. & Rashaed, S. A. Outcomes and Determinants of Posterior Dislocated Intraocular Lens Management at a Tertiary Eye Hospital in Central Saudi Arabia. *Middle East Afr. J. Ophthalmol.* **26**, 223–228 (2020).
71. Steinmetz, R. L., Brooks, H. L. & Newell, C. K. Management of posteriorly dislocated posterior chamber intraocular lenses by vitrectomy and pars plana removal. *Retina Phila. Pa* **24**, 556–559 (2004).
72. Chu, T. G. & Green, R. L. Suprachoroidal hemorrhage. *Surv. Ophthalmol.* **43**, 471–486 (1999).
73. Liovic Milec, M., Sekelj, S. & Konjevic-Pernar, S. Postoperative Corneal Edema After Phacoemulsification. *Southeast. Eur. Med. J. SEEMEDJ* **6**, 113–120 (2022).

74. Yi, D. H. & Dana, M. R. Corneal edema after cataract surgery: incidence and etiology. *Semin. Ophthalmol.* **17**, 110–114 (2002).
75. Grzybowski, A. & Kanclerz, P. Early postoperative intraocular pressure elevation following cataract surgery. *Curr. Opin. Ophthalmol.* **30**, 56–62 (2019).
76. W.Oldham, G. Hyphema - EyeWiki. [Internet] March 2021. [Cited on 20.5.2022.] Available from: <https://eyewiki.aao.org/Hyphema>.
77. Mathur, K. N., Awasthy, P. & Mathur, J. S. Hyphaema after cataract operation. *Indian J. Ophthalmol.* **12**, 119 (1964).
78. Neatrou, K., McAlpine, A., Owens, T. B., Trivedi, R. H. & Poole Perry, L. J. Evaluation of the etiology of persistent iritis after cataract surgery. *J. Ophthalmic Inflamm. Infect.* **9**, 4 (2019).
79. Bajoria, S. K. & Biswas, J. Recent approach in diagnosis and management of anterior uveitis. [Internet]. January 2018. [Cited on 9.6.2022.]. Available from: <https://www.jcor.in/article.asp?issn=2320-3897;year=2018;volume=6;issue=1;spage=36;epage=41;aulast=Bajoria>.
80. Mamalis, N. *et al.* Toxic anterior segment syndrome. *J. Cataract Refract. Surg.* **32**, 324–333 (2006).
81. Park, C. Y., Lee, J. K. & Chuck, R. S. Toxic anterior segment syndrome-an updated review. *BMC Ophthalmol.* **18**, 276 (2018).
82. Pathengay, A. *et al.* Acute Postoperative Endophthalmitis Following Cataract Surgery: A Review. *Asia-Pac. J. Ophthalmol. Phila. Pa* **1**, 35–42 (2012).
83. Maguire, J. I. Postoperative endophthalmitis: optimal management and the role and timing of vitrectomy surgery. *Eye* **22**, 1290–1300 (2008).
84. Werner, D. & Kaback, M. Pseudophakic pupillary-block glaucoma. *Br. J. Ophthalmol.* **61**, 329–333 (1977).
85. Fang, A., Wang, P., He, R. & Qu, J. Surgical peripheral iridectomy via a clear-cornea phacoemulsification incision for pupillary block following cataract surgery in acute angle closure. *BMC Ophthalmol.* **18**, 120 (2018).
86. Muñoz-Negrete, F., Moreno-Montañés, J., Hernández-Martínez, P. & Rebolleda, G. Current Approach in the Diagnosis and Management of Uveitic Glaucoma. *BioMed Res. Int.* **2015**, 742792 (2015).
87. Pandey, S. K., Apple, D. J., Werner, L., Maloof, A. J. & Milverton, E. J. Posterior Capsule Opacification : A Review of the Aetiopathogenesis, Experimental and Clinical Studies and Factors for Prevention. *Indian J. Ophthalmol.* **52**, 99 (2004).

88. Schaumberg, D. A., Dana, M. R., Christen, W. G. & Glynn, R. J. A systematic overview of the incidence of posterior capsule opacification. *Ophthalmology* **105**, 1213–1221 (1998).
89. Dersu, I. I. & Antonova, N. Pseudophakic and Aphakic Glaucoma - EyeWiki. [Internet]. May 2022. [Cited on 25.5.2022.]. Available from: https://eyewiki.aao.org/Pseudophakic_and_Aphakic_Glaucoma#Etiology.
90. Garabet, C., Hwang, F. S., Cho, S. & Gasparian, S. A. Dislocated Intraocular Lens - EyeWiki. [Internet]. October 2021. [Cited on 26.5.2022.]. Available from: https://eyewiki.aao.org/Dislocated_Intraocular_Lens.
91. Haug, S. J. & Bhisitkul, R. B. Risk factors for retinal detachment following cataract surgery. *Curr. Opin. Ophthalmol.* **23**, 7–11 (2012).
92. Feltgen, N. & Walter, P. Rhegmatogenous Retinal Detachment—an Ophthalmologic Emergency. *Dtsch. Ärztebl. Int.* **111**, 12–22 (2014).
93. Hartman, M., Rauser, M., Brucks, M. & Chalam, K. V. Evaluation of anterior capsular contraction syndrome after cataract surgery with commonly used intraocular lenses. *Clin. Ophthalmol. Auckl. NZ* **12**, 1399–1403 (2018).
94. Hayashi, K. & Hayashi, H. Effect of anterior capsule contraction on visual function after cataract surgery. *J. Cataract Refract. Surg.* **33**, 1936–1940 (2007).
95. Rossetti, L. & Autelitano, A. Cystoid macular edema following cataract surgery. *Curr. Opin. Ophthalmol.* **11**, 65–72 (2000).
96. Maalouf, F., Abdulaal, M. & Hamam, R. N. Chronic Postoperative Endophthalmitis: A Review of Clinical Characteristics, Microbiology, Treatment Strategies, and Outcomes. *Int. J. Inflamm.* **2012**, 313248 (2012).
97. Themes, U. F. O. Delayed- Versus Acute-Onset Endophthalmitis After Cataract Surgery. *Ento Key*. [Internet]. January 2017. [Cited on 9.6.2022.]. Available from: <https://entokey.com/delayed-versus-acute-onset-endophthalmitis-after-cataract-surgery-2/>.
98. Gurnani, B. & Kaur, K. Pseudophakic Bullous Keratopathy. in *StatPearls* (StatPearls Publishing, 2022).
99. Walkow, T., Anders, N. & Klebe, S. Endothelial cell loss after phacoemulsification: relation to preoperative and intraoperative parameters. *J. Cataract Refract. Surg.* **26**, 727–732 (2000).

16. Biography

I was born on 12.9.1997. in Zagreb. After I finished elementary school 'Bukovac', I enrolled and graduated from III. Gymnasium. During my Medical studies I have discovered my interest in the field of Ophthalmology and have decided to write my thesis in the same field. I am a proficient user of English language.