

# PERSONALIZED MEDICINE AND NEW TECHNOLOGIES FOR THE PATIENT WITH EPIDERMOLYSIS BULLOSA (EB)

---

**Sedlić, Martina**

**Master's thesis / Diplomski rad**

**2018**

*Degree Grantor / Ustanova koja je dodijelila akademski / stručni stupanj:* **University of Rijeka, Faculty of Medicine / Sveučilište u Rijeci, Medicinski fakultet**

*Permanent link / Trajna poveznica:* <https://urn.nsk.hr/urn:nbn:hr:184:951465>

*Rights / Prava:* [In copyright](#) / [Zaštićeno autorskim pravom.](#)

*Download date / Datum preuzimanja:* **2024-04-25**



*Repository / Repozitorij:*

[Repository of the University of Rijeka, Faculty of Medicine - FMRI Repository](#)



Image not found or type unknown

SVEUČILIŠTE U RIJECI  
MEDICINSKI FAKULTET  
INTEGRIRANI PREDDIPLOMSKI I DIPLOMSKI  
SVEUČILIŠNI STUDIJ MEDICINE



Martina Sedlić

**PERSONALIZED MEDICINE AND NEW TECHNOLOGIES FOR THE PATIENT WITH  
EPIDERMOLYSIS BULLOSA (EB)**

Diplomski rad

Rijeka, 2018.

SVEUČILIŠTE U RIJECI  
MEDICINSKI FAKULTET  
INTEGRIRANI PREDDIPLOMSKI I DIPLOMSKI  
SVEUČILIŠNI STUDIJ MEDICINE



Martina Sedlić

**PERSONALIZED MEDICINE AND NEW TECHNOLOGIES FOR THE PATIENT WITH  
EPIDERMOLYSIS BULLOSA (EB)**

Diplomski rad

Rijeka, 2018.

Mentor rada: doc.dr.sc. Sven Maričić,

Komentorica: izv.prof.dr.sc. Vanja Vasiljev Marchesi

Diplomski rad ocjenjen je dana 02.07.2018. na Medicinskom fakultetu Sveučilišta u Rijeci  
pred povjerenstvom u sastavu:

1. prof.dr.sc. Tomislav Rukavina
2. prof.dr.sc. Amir Muzur
3. izv.prof.dr.sc. Iva Rinčić

Rad sadrži 44 stranica, 10 slika, 8 tablica, 33 literaturnih navoda.

# PROLOGUE

I would most like to thank my dear assist. prof. Sven Maričić on support, advice and understanding. His knowledge and experience in this field of science has greatly contributed to the development of this work.

In the same way, I am very grateful to my comentor assoc. prof. Vanja Vasiljev Marchesi.

Great gratitude goes to beloved Toma Babić for his large knowledge and patience in order to find the best solution for this patient. He helped me in developing the ideas of implementing new technologies in medicine.

Thank to everyone who in any way contributed to the formation of this graduate paper. Special thanks goes to Matija Zmazek, Dajana Rakić and Ćina Josipović.

# TABLE OF CONTENTS

LIST OF ABBREVIATIONS	1
INTRODUCTION	2
<i>Personalized medicine (PM)</i>	2
<i>Application of new technologies: 3D scanner and 3D printer</i>	4
<i>Epidermolysis bullosa (EB)</i>	8
<i>Definition and classification:</i>	8
<i>Epidemiology:</i>	10
<i>Pathophysiology:</i>	11
<i>Diagnosis:</i>	12
<i>Clinical features:</i>	12
<i>Epidermolysis bullosa dystrophica (DEB)</i>	13
<i>Dominant dystrophic epidermolysis bullosa (DDEB)</i>	14
<i>Recessive dystrophic epidermolysis bullosa (RDEB)</i>	16
<i>Generalized severe RDEB or Hallopeau-Siemens RDEB</i>	16
<i>Generalized intermediate RDEB</i>	17
<i>Therapy of Epidermolysis bullosa (EB):</i>	17
PURPOSE OF WORK	19
CASE REPORT	20
<i>Anamnesis</i>	20
<i>Physical and dermatological status</i>	21
<i>Personalized approach to patient M.Z.</i>	22
MATERIALS AND PROCEDURES	24
<i>Materials</i>	24
<i>Procedures</i>	29
RESULTS	31
DISCUSSION	35
CONCLUSION	37
SUMMARY	38
SAŽETAK	39
LITERATURE	40
CURRICULUM VITAE	44

# LIST OF ABBREVIATIONS

**EB-** Epidermolysis bullosa

**EBS-** Epidermolysis bullosa simplex

**JEB-** Epidermolysis bullosa junctionalis

**DEB-** Epidermolysis bullosa dystrophica

**DDEB-** Dominant dystrophic epidermolysis bullosa

**RDEB-** Recessive dystrophic epidermolysis bullosa

**BMZ-** Bazal membrane zone

**PM-** Personalized medicine

**KS-** Kindler syndrome

**CAD-** Computer aided designing

**CAM-** Computer aided manufacturing

# INTRODUCTION

In the last few years there have been a lot of studies that show the importance of a personalized approach in medicine and it starts to be the cornerstone of treating patients. Medicine is a scientific discipline that deals with human lives, thus it is reserved for early implementation of a new technologies. In this paper new technologies involve the use of 3D printer and 3D scanner, as well as the use of new materials that are complement with requirements of the patient.

*Epidermolysis bullosa* is an inherited bullosis skin disease and a part of rare genodermatosis that is characterized by skin fragility. The cause of this condition lies in defective structural proteins of the skin and most often it occurs in early childhood. There are a lot of complications and many organs can be affected by it. This disease is difficult to cure and it involves only supportive therapy. Considering all this, these patients may have significantly lower quality of life.

## ***Personalized medicine (PM)***

Personalized medicine (PM), also called precision medicine is a relatively new concept in contemporary medicine in which medical decisions, procedures and treatments are adapted to the individual. Besides that, authors Horne et al. and Flores et al. cite PM as 4P medicine which includes predictive, preventive, personalized and participatory medicine [1]. To sum up, the key concept behind PM is based on: the right medicine, for the right patient in the right dose at the right time.

Due to new technologies and advancements in medicine, as well as changed perspective on patient treatment, patient is becoming center of therapy. The essential principle of modern medicine is to treat every patient as the case for themselves, and not



just to treat diagnosis. Each patient is an unique individual with his own desires and needs. Moreover, he should be treated as such and that is exactly what medicine of today should be oriented towards.

Contribution of different sciences in medicine has enabled medical doctors to act in a personalised way to their patients, but medicine is still not as personalised as it should be. Partially, the fault lies in the fact that PM is expensive. Also nowadays, health systems across the globe are overwhelmed and there is physically no time for personalized approach.

For now, methodology of PM is used only in rich countries that can provide enough financial resources to fund personalized projects. For example, thanks to genetic testing, each person can know how his organism is dealing with environment, what food should he eat, which allergies does he have or which disease he can acquire. That is one big step in PM and how patients of future will be treated.

Pharmacogenomics plays the most important role in development of PM that has also been named genomic medicine. It has become one of the leading and potentially most actionable areas of the PM. Exponential growth of molecular medicine in the last 20 years has resulted with development of gene testing, target therapy drugs, diagnostic approaches and growth of new informatics. We live in the era when the trend of biomedical research is increasing and scientists have discovered that not all patients respond on the same way to the same medicine (drug). Furthermore, metabolism of the drug is interindividual and determined by variability of genes and it throws another light on drug treatment. Another key point of personalized medicine is early engagement with patients and their families what will help ensure that attention is directed to person. “Unlike clinicians, who may typically see a patient with a same rare disease once or twice a year, patients and families live with their condition 24/7” [2]. Important to realize is that

partnership between patients and doctors as well as doctors and other team members are the foundation for achieving optimal treatment results. When it comes to treatment of rare illnesses, the great results and outcomes are expected from pharmacogenomics and pharmacogenetics.

### ***Application of new technologies: 3D scanner and 3D printer***

As already mentioned, medicine is a lifetime subscriber for implementation of new technologies. Moreover, medicine of today depends on technology and without it, so called “western” medicine, it would be much slower in its development and thus less reliable. Implementation of additive manufacturing known as 3D printing, and technology of 3D scanning will be discussed through this research paper.

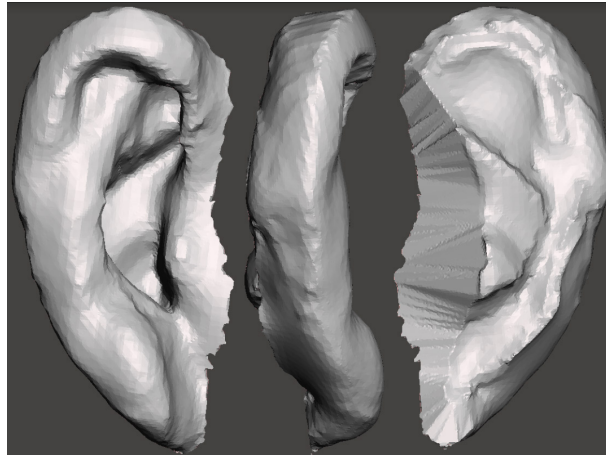
A 3D scanning is the process in which real-world object or environment is analyzed to collect data about its shape, texture, and/or colour. Many technologies can be used to build scanning devices, so variety of applications is mandatory. The purpose of scanning is to create a 3D model that can be used in a software. Later possibilities are numerous and scanners are broadly used in industrial design, digitization of cultural artefacts, prosthetics, orthotics and many more. Handheld structured light 3D scanner was used for this research because of its versatility, so a few sentences about these scanners will be told. Handheld scanner is one that can be used using your own hands without the need for rotating table or similar tools. Structured light means that it projects pattern of light and, using a camera, analyzes the deformities of the pattern and sculpts a 3D model.

Additive manufacturing or three dimensional (3D) printing is a manufacturing method in which objects are created by fusing or depositing materials layer by layer. Materials used for 3D printing are plastic, metal, ceramics, powders, liquids, or even living cells. Computer Aided Design and Manufacturing (CAD/CAM) are necessary for model

design and a process of 3D printing. The first 3D printer was developed in early 1980s by Charles Hull. The first commercialized printer called SLA-250 was developed and released for sale by 3D Systems in 1988. This technology was primarily developed for fast prototyping, and methodology of 3D printing is inverted methodology of all other manufacturing processes. Instead of modelling an object that results with waste material, 3D printing is building object layer by layer just like buildings are being created and there is no waste material. There are almost no limitations for this technology except for price and printing dimensions.

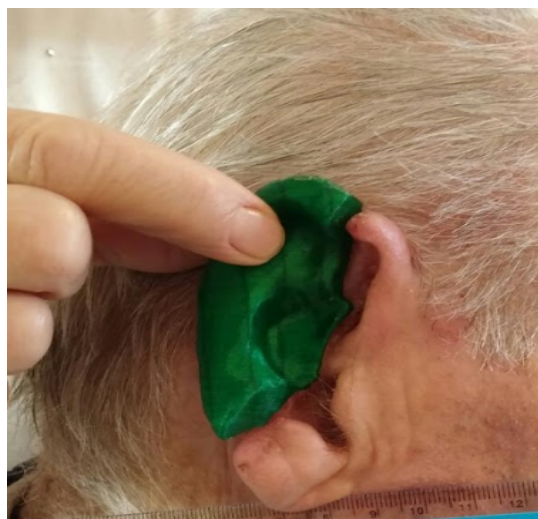Medical applications for additive manufacturing are expanding promptly and are expected to revolutionize healthcare system [3]. Medical use of additive manufacturing, can be organized into several categories: tissue and organ fabrication; prosthetics, implants, and anatomical models; and pharmaceutical research regarding drug dosage forms, delivery, or discovery [4].

For example, more than 90% of hearing aids are custom-made using 3D printing. [5] Each person's ear canal and auricula are shaped differently, and the use of 3D printing allows us to create hearing aid that will perfectly fit ear canal [5]. From University of Rijeka stems a project in which auricular epithesis was created for a patient that had a part of the outer ear removed due to melanoma. Model of epithesis was created in collaboration with Centre for biomodelling and innovations in medicine from Faculty of Medicine and Clinical Hospital Center Rijeka. Leader of model design and manufacturing was asist.prof. Sven Maričić from Faculty of Medicine, and leaders of project from clinical aspect were the representatives from Clinical Hospital Center of Rijeka asist.prof. Dubravko Manestar and asist.prof. Mitja Velepč.



**Figure 1:** *Auricular epithesis, CAD model. Source: Faculty of Medicine, KBC Rijeka*

Epithesis prototype was developed using CAD software (Figure 1) and after testing prototype and analysis of residence place, a real model was manufactured which was then implanted in the patient by otorhinolaryngologists mentioned above. Besides that, another important application of 3D technologies in medicine is in education of anatomy or surgical procedures. The learning method can be simpler and more interesting when having a tangible model in one's own hands.



**Figure 2:** *Auricular epithesis testing, analysis of the residence place. Source: Faculty of Medicine - Center for Biomodeling and Innovations in Medicine, KBC Rijeka*

Using technology of 3D printing in tissue engineering and regenerative medicine is called 3D bioprinting. Although 3D printing is a novel tissue engineering strategy, it keeps great

potential to play a key role in engineering of tissue, and personalized medicine [6].

Bioprinting methods with its advantages and disadvantages are shown in Table 1.

**Table 1:** Bioprinting methods; description, advantages, disadvantages, effects and cost  
Source: *Bishop ES, 3D bioprinting technologies in tissue engineering and regenerative medicine: Current and future trends*, Genes and Diseases, 2017.

Bioprinting method	Inkjet 3D bioprinting	Microextrusion 3D bioprinting	Laser-assisted 3D bioprinting	Stereolithography
<b>Description</b>	Thermal, piezoelectric, or electromagnetic forces expel successive drops of bioink onto a substrate	Mechanical or pneumatic forces dispense bioink through nozzle	Bioink and cells are suspended on the bottom of a ribbon and when vaporized by laser pulse, are propelled to a receiving substrate	Use digital light to cure bioink in a layer by layer fashion
<b>Advantages</b>	High speed Availability Low cost	Ability to use high viscosity bioink and print high cell density	High precision and resolution Ability to use high viscosity bioink and print high cell density	High degree of fabrication accuracy Low printing time
<b>Disadvantages</b>	Lack of precision in droplet placement and size Need for low viscosity bioink	Distortion of cell structure	Time consuming High cost	Use of high intensity UV light Lengthy post-processing Lack of compatible materials
<b>Effect on cells</b>	>85% cell viability	As low as 40% viability	>95% viability	>90% viability
<b>Cost</b>	Low	Medium	High	Medium

3D bioprinting means 3D printing of biological structures what can be easily concluded. The process involves dispensing cell onto a biocompatible matrix using technique of 3D printer, and layer-by-layer tissue-like 3D structure is being generated [7]. As a material for 3D bioprinting bioink is used. Bioink is material that is consist of cellular

elements, supportive scaffold, and additives that include growth factors, signalling molecules, etc.

Technologies of 3D printing and bioprinting could have important role in the development of personalized medicine and very soon, these technologies will be the cornerstone in treating patients.

## ***Epidermolysis bullosa (EB)***

As already mentioned, EB is a genetic skin disorder characterised by blister formation in response to mechanical trauma. Symptoms are depending on the type and subtype of disease. Since it starts from early childhood and skin of these children is fragile, in some literature skin is described as onion skin, and these children are colloquially known as butterfly children. It has to be emphasized that their quality of life can be severely reduced and doctors of today are obliged to help them improve it. More about Epidermolysis bullosa will be described in the next chapter where more about classification, epidemiology, pathophysiology, diagnosis, clinical features and therapy will be pointed out.

### **Definition and classification:**

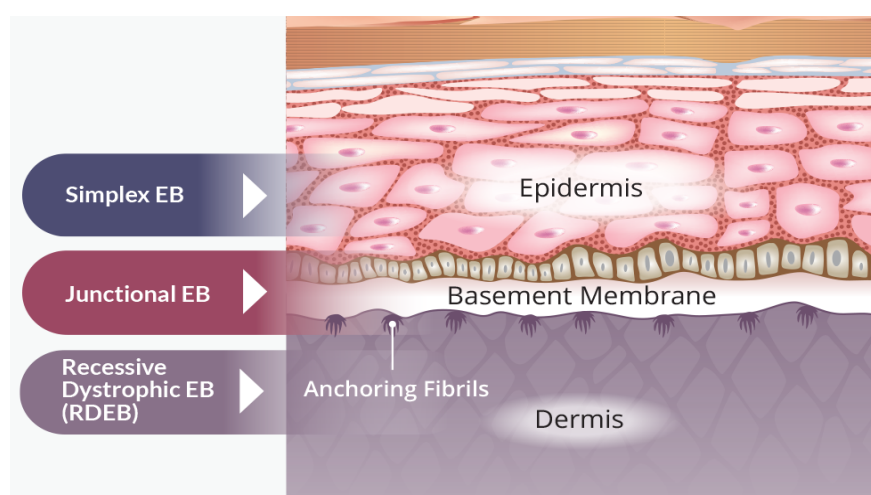
“Epidermolysis bullosa (EB) is a genetic skin condition that results in fragility of the skin and/or mucosal membranes with the subsequent formation of blisters, after minor trauma or appearing spontaneously [8].” It is described for first time by renowned German dermatologist dr. Koebner in 1886 [9].

During the Third International Consensus Meeting on Diagnosis and Classification of EB in 2008, EB is divided into four major types, depending on the level of the epidermal-dermal junction where the formation of blisters appears: 1. *Epidermolysis*

*bullosa hereditaria simplex (EBS)*, also known as epidermolytic EB because of the appearance of blisters inside the epidermis; 2. *Epidermolysis bullosa hereditaria junctionalis (JEB)* in which blisters are located in the dermal-epidermal junction or basement membrane zone (BMZ), specifically inside the lamina lucida and that is why it is called lucidolytic; 3. *Epidermolysis bullosa hereditaria dystrophica (DEB)*, in other words dermolytic EB, is a condition where blisters are formed between the BMZ and the dermis, or more precisely in sub-lamina densa; 4. *Kindler syndrome (KS)*, which was added to the EB classification in 2008, is a mixed pattern and an extremely rare condition in which the defect can occur at any of the three previously described sites.

These four main types are divided in up to 24 subtypes which will also not be separately described here. As could be noticed, all of these types are inherited. However, there is also the acquired form of the disease, *Epidermolysis bullosa acquisita*. It is a very rare chronic autoimmune subepidermal disease that can be found in dog and goat species too [10]. This form of disease will not be further elaborated in this paper.

In this article main focus will be put on DEB due to the reason that patient which is subject of this research has that type of disease.



**Figure 3:** Representation of the main types of the disease by the place of origin of the blister

Source: [http://www.sderm.com/patients-and-families-2/about-eb/?doing\\_wp\\_cron=1529536848.9938020706176757812500](http://www.sderm.com/patients-and-families-2/about-eb/?doing_wp_cron=1529536848.9938020706176757812500),

Access: 2018, May 26

## **Epidemiology:**

“EB is a rare disease; it is estimated that 500 000 people worldwide are suffering from this disease [11].” “All types and subtypes of EB are rare; the overall incidence is approximately 1 in 50 000 live births [12], and the prevalence is 1:20 000– 1:100 000 in the USA and Europe [8].”

**Table 2:** The prevalence of the Epidermolysis bullosa according to the National Epidermolysis Bullosa Registry

Source: Pfendner E, Epidermolysis bullosa carrier frequencies in the US population, Journal of Investigative Dermatology. 2001.

Access: 2018, Apr 24

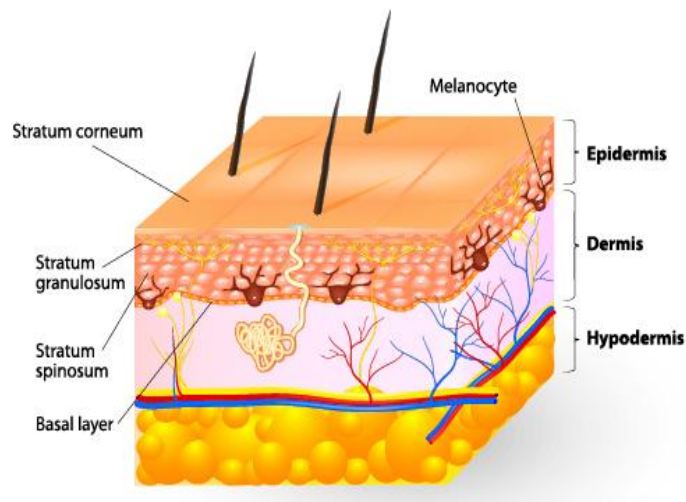
Country	Per million live births	Country	Per million live births
Norway	54	Australia	10,3
Italy	15,4	Croatia	9,6
USA	11,07	Japan	7,8

“Statistically, EB simplex (EBS) represents 92% of the total of EB cases, 5% are dystrophic EB (DEB), 1% are junctional EB (JEB), whereas the remaining 2% are still unclassified [8].” Observing gender frequencies no significant differences have been noted [13], while differences depending on ethnic affiliation are noticed as seen in Table 2.



### **Pathophysiology:**

Normal skin has an outer layer known as the epidermis and a main layer known as the dermis (Figure 4). Between those two layers is a BMZ which consist of the lamina lucida and lamina densa.



**Figure 4:** The layers of human skin

Source: <http://anatomysciences.com/human-skin-layers>

Access 2018, May 19

“This disease is caused by specific mutations in one of at least 18 genes responsible for the production of proteins vital to the structural integrity of the skin [8].” The inherited types of this group of diseases are autosomal dominant or autosomal recessive. Pathogenesis of the EBS is based on mutations on the gene which encode keratin-5, keratin-14, plectin, plakophilin-1 and  $\alpha 6\beta 4$  integrin and which has in most cases autosomal dominant pattern of inheritance.

The cause of JEB is mutation within the lamina lucida in the genes encoding synthesis of plectin, antigens of pemfigoid bullosus, laminin-332 (5), collagen type XVII or integrin  $\alpha 6\beta 4$ . All diseases of this group are inherited autosomal recessive.

DEB is caused by separation in the upper part of papillary dermis which is characterized by mutation of gene for collagen VII on 3p21 chromosome [14]. This type of Epidermolysis bullosa can be inherited autosomal dominant, (DDEB) and autosomal

recessive (RDEB). Moreover, it is the main division of DEB according to the classification from 2008. All DEB subtypes are caused by mutations in COL7A1, which encodes type VII collagen, a major component of anchoring fibrils, that may be abnormal, diminished, or absent [14]. These fibrils are essential to the functional integrity of the dermoepidermal junction.

KS is caused by mutations in the gene encoding the structural kindlin-1 protein.

### **Diagnosis:**

From a clinical point of view, intraepidermal blisters are usually flaky and widen to the pressure while the blisters inside the lamina lucida are tense and whole atrophy, but without scarring. On the other hand, blisters of the sublamina densa are full of scarring and forming milestones [15].

Two main methods for diagnosing EB are examination of skin biopsy sample with the help of transmission electron microscopy, which is the gold standard for EB diagnosis, or using immunofluorescent mapping of antigen antibodies. When it comes to biopsy, it is important that specimens should be sampled from the anterior edge of a fresh or an opened bulla [16].

Finally, the diagnosis is based on anamnesis, clinical picture, histological examination, electron microscopic examination and antigen mapping findings.

### **Clinical features:**

Clinical features of these patients have wide spectrum of cutaneous and extracutaneous presentation and it is in correlation with type and subtype of disease. In principle, they are all associated with mechanically all fragile skin and with the appearance of blisters.

There is a wide range of severity within the types. EBS is usually milder severity. JEB can result from mutations in any of six different BM components and can be rang from mild to fatal in early life. DEB can be in a mild dominant form (DDEB) or a more severe recessive one (RDEB) [17].

In short, classical presentation of the EB is development of skin wounds that are painful, often infected and lead to scarring [17].

For the requirements of the paper, only DEB is described in detail while other types and subtypes of disease as well as their main cutaneous and extracutaneous manifestation are described in Table 3. (on the next page)

### ***Epidermolysis bullosa dystrophica (DEB)***

Because of many possible complications and difficult clinical features, DEB holds a significant socio-medical meaning. In order to help that population, in 1980s was established The Dystrophic Epidermolysis Bullosa Research Association (DEBRA); international medical research organization which is dedicated to supporting individuals and families affected by EB.

DEB is presenting with trauma induced blisters and healing with scarring that typically leads to deformities of the skin. Those deformities specifically include pseudosyndactyly which refers to coalescence of the fingers, nail changes and milia formation. It is worth to mention that each hand deformation is distinct and different from the type of the disease.

The main division of the DEB is based on the type of inheritance so it can be distinguished between *Recessive dystrophic epidermolysis bullosa* (RDEB) and *Dominant dystrophic epidermolysis bullosa* (DDEB). According to the third international consensus

meeting and classification of EB; DEB is subdivided into three types, (to enumerate): 1. Generalized DDEB, 2. Generalized severe RDEB and 3. Generalized intermediate RDEB.

The cause of this condition lies in several hundred mutations in the COL7A1 gene coding for type VII collagen.

### **Dominant dystrophic epidermolysis bullosa (DDEB)**

DDEB is second in frequency behind EBS and it is the most common type of DEB. Due to absent or rare extracutaneous characteristic of disease and rare severe deformities of the limbs, this form is a milder than RDEB. Another key point is that DDEB has reduced expression type VII collagen.

“This type of DEB starts at birth though it decreases in intensity with advancing age [13].” Although bullae in DDEB are generalized, they are localized mostly on the lower limbs, elbows or knees while in the case of RDEB it occurs through whole body [16].

“The prototypic DDEB patient has generalized blistering at birth which, with time, is associated with milia, atrophic or less commonly, hypertrophic scarring and nail dystrophy. [18].”

**Table 3:** Description of the main subspecies of the disease and its clinical manifestations. Names in parentheses are formerly known names. EBS-Epidermolysis bullosa simplex, JEB-Epidermolysis bullosa junctionalis, KS-Kindler syndrome.

Types of EB	Major subtypes of EB	Clinical features	
		Cutaneous	Extracutaneous
<b>1. EBS</b>	Severe generalized EBS (Dowling-Meara)	Generalized (with relative sparing of palms and soles) Blisters Diffuse keratoderma (palms and soles) Atrophic scarring and Dystrophic or absent nails are possible Milia	Growth retardation Soft-tissue abnormalities Constipation Anemia
	Intermediate generalized EBS (non-Dowling-Meara)	Generalized Blisters Focal keratoderma (palms and soles)	Soft-tissue abnormalities Rare ocular disorders Very rare malignant melanoma
	Localized EBS (Weber-Cockayne)	Blistering of palms and soles in early childhood Focal keratoderma of palms and soles in some cases	Localized intraoral erosions or blisters
<b>2. JEB</b>	Severe generalized JEB (Herlitz JEB)	Blisters (often with hemorrhagic fluid) Atrophic scarring Dystrophic or absent nails Granulation tissue on face, armpits and back Milia	Delayed puberty Anemia Growth retardation Enamel hypoplasia, caries Gastrointestinal, ocular, respiratory and renal complications Risk of squamous cell carcinoma
	Intermediate generalized JEB (non-Herlitz JEB)	Blisters Dystrophic or absent nails Diffuse alopecia Milia	Enamel hypoplasia Caries Soft-tissue abnormalities Squamous cell carcinoma
	Localized JEB	Dystrophic or absent nails Blisters	Enamel hypoplasia Caries
<b>3. KS</b>	-	Generalized blistering Keratoderma Skin atrophy Poikiloderma Photosensitivity	Gingival hyperplasia Colitis, esophagitis Ectropion, caries Urethral strictures Rarely mental retardation Bone abnormalities

Major subtypes of DDEB are generalized DDEB, acral DDEB, pretibial DDEB, DDEB pruriginosa, DDEB nails only and DDEB bullous dermolysis of the newborn [19].

In general, patient with this disease have a good prognosis and relatively good quality of life.

### **Recessive dystrophic epidermolysis bullosa (RDEB)**

RDEB is subdivided into severe generalized RDEB (new name for Hallopeau-Siemens), generalized intermediate (new name for non-Hallopeau-Siemens), RDEB inversa, localized RDEB, pretibial RDEB, RDEB pruriginosa, RDEB centripetalis and bullous dermolysis RDEB of the newborn [19].

#### ***Generalized severe RDEB or Hallopeau-Siemens RDEB***

“It is the most severe of all RDEB subtypes because it is caused by the marked reduction or complete loss of type VII collagen expression [20].” Consequently, anchoring fibrils are damaged or completely disappeared. As a result of separation in upper papillary dermis, skin is extremely fragile with formation of blister and milia, granulation tissue in chronic wounds, atrophic scarring, dystrophic or absent nails, EB nevi as well as scalp abnormalities [14, 21].

These patients have a numerous extracutaneous manifestations such as involvement of gastrointestinal tract, ocular system (abrasions, scars, pannus of the cornea, blisters and ectropion of the eyelids, conjunctival blisters and symblepharon [22] and cardiovascular system (cardiomyopathy).

Gastrointestinal complications are the most common extracutaneous manifestation which comes in form of oral cavity blisters and ulcers, fixation of the tongue, GERD which can be complicated with recurrent esophageal blistering and erosions, leading to

progressive dysphagia, esophagitis with esophageal strictures formation, and fissures of the anus and constipation [23, 24].

Furthermore, these patients often have soft-tissue abnormalities and defective teeth with excessive caries. Comparatively, patients with DDEB have normal teeth [13].

“Due to chronic blood loss, inflammation, infection, and poor nutrition, they can develop severe anemia, delayed puberty, growth retardation and osteoporosis [25].”

Among these patients, it is common to experience contractures or even ankylosis of the elbow, knee or joints of the arms and feet. Likewise, risk of infection can be high due to large areas of open wounds [26].

Additionally, they have a high risk of developing glomerulonephritis, renal amyloidosis or IgA nephropathy which can lead to chronic renal failure.

The worst fact to be mentioned is that these patients have a high risk of developing the cutaneous squamous cell carcinoma that mainly occurs between age of 15 and 35, which is characterized by multiple localization, quick growth and metastasis, and unfortunately, this is the main cause of death.

### ***Generalized intermediate RDEB***

A slightly different form previously known as non-Hallopeau-Siemens, whose clinical manifestations are similar to generalized severe, but the blistering is less severe, because type VII collagen expression is present, although reduced. Patients usually have a better prognosis than that of RDEB, generalized severe [27].

### ***Therapy of Epidermolysis bullosa (EB):***

Treatment of EB is a challenge, especially the most severe forms, because of the lack of opportunities for the direct influence on the disease process. Furthermore, the main goal is to heal the existing cutaneous manifestations and to prevent, as much as

possible, the occurrence of extracutaneous manifestation. Therapy is based not only on prevention methods, but also focuses on treating pain and itching that are everyday obstacle of these patients.

First of all, prevention methods include optimal nutrition due to the reason that poor nutritional status have more wounds with subsequent slower healing that are more painful [17]. Because of that, it is of particular importance to inject sufficient protein, since the need for protein intake is up to 100% higher than in healthy people of the same age [15]. In addition, it is also important to control and, if necessary, to compensate for iron and zinc because they are involved in the wound healing process. Due to reduced mineralization, vitamin D and calcium should be taken to prevent the development of osteopenia and osteoporosis [28] while selenium and carnitine are important in preventing dilated cardiomyopathy [29].

Some studies show that clinically effective drugs are: topical sucralfate suspension for treating oral cavity blisters and ulcers [30], budesonide solution to treat esophageal strictures [31] and using of polyethylene glycol for constipation [32].

Medicament that are recommended for treating pain are NSAIDs, cannabinoids, acetaminophen and opioids such as tramadol and methadone. “Non-adhesive dressings such as silicone based products are very helpful in reducing skin-trauma pain [17].” It is, also, recommended to use as less as possible local antibiotic and corticosteroid creams due to the frequent appearance of bacterial resistance and sensitization. In support of this it is also said that the first resistance to local antibiotic mupirocin is described precisely in EB [15]. Other pharmacological treatment of skin and wound pain is non specific, no study has shown the advantage of one drug over the other [17]. Consequently, the best recommendation is the individualization of therapy and that is why this condition is a good example of the importance of that type of therapy.



Although the treatment is supportive and is based primarily on the treatment of wounds and blisters, it prevents or reduces complications and increases the quality of life. To summarize, this disease requires teamwork and a multidisciplinary approach of experts of various specialties. It is of great importance to the good education of patients, family members and wider communities. In future, there are great expectations of personalized gene therapy.

## PURPOSE OF WORK

The idea of this research is to present possible applications of new technologies and their implementation in medicine. Those technologies will be used as tool to create a model of personalized solution for the patient. In this case, hand orthosis was designed and manufactured with the help of 3D printer and 3D scanner for the patient who suffers from a genetic skin disease called *Epidermolysis bullosa hereditaria dystrophica recessiva* (RDEB).

As already described, Epidermolysis bullosa can be a severe disease to live with and patients are experiencing a lot of difficulties and problems through their life. Moreover, the process of creating personalized multi-functional orthosis for patients suffering from EB has not been described yet. The purpose of this work is presenting methodology behind manufacturing personalized orthosis so it can be easily scalable and recreated all over the world. Furthermore, the aim of this project was to present the basic features of this severe and rare disease, as well as raise the awareness of people about this disease.

The future of medicine and of science in general is in fusioning different fields of science into one project. The best and the most commonly used diagnostic approaches in medicine, such as ultrasound (US), magnetic resonance (MRI) or computerized

tomography (CT), are developed in collaboration with physicists and engineers. Thanks to creativity of doctors in the past, some of the tools used in surgical room are the same as the ones used on a building site. Using the strategy of fusioning, results are far better because they result with synergy. Synergy is the creation that is greater than the sum of its pieces and that is the second purpose of this work, to accentuate how synergy involving medicine can greatly improve the quality of a patient's life.

## CASE REPORT

### *Anamnesis*

Patient M.Z. was born on June 7th 1983 in Zagreb. He finished the School of Applied Arts following normal programme with an individualized approach. Now, he's 36 and he lives alone. In nursery, he was diagnosed with epidermolysis bullosa, and later through biopsy it was concluded to be *Epidermolysis bullosa hereditaria recessiva*, formerly known as *RDEB Hallopeau-Siemens*. Genetic analysis of both parents has shown that they are both carriers of a mutated COL71A gene. Pregnancy was normal, as well as the birth, during which the basic disease was discovered. M. Z.'s psychomotor development was also normal, so he walked and talked at the age of 1. At the age of 5, he underwent the base of tongue surgery because he experienced speech difficulties as a result of accretion of tongue within the basic disease.

Patient does not go to regular checkups, and last time he was hospitalized 4 years ago in emergency room due to anemia, hypoalbuminemia, and bilateral pleural effusion. Since discharge, he has been feeling well, he is watching his diet, he regularly eats meat (300g/day), eggs (1pc/day), cow cheese (500g/day), milk (1dcl/day), honey with

supplements, chokeberry juice, and various fruits and vegetables. Since there are increased needs for proteins and calories, he was recommended a high-calorie vitamin beverage for enteral nutrition *Ensure*(1pc/day). Appetite is good, stool and urine are normal. He has received vaccinations according to the calendar for Republic of Croatia. He does not smoke, does not consume alcohol, and denies having allergies.

## ***Physical and dermatological status***

Patient is normally developed, he is thin and pale, with normal vital functions. Heart frequency is around 80/min, and RR is 110/65 mmHg. His weight is 54 kg, and height 180 cm. Accordingly, BMI is 16,67kg/m<sup>2</sup>. Despite regular and adequate diet, he has got a chronic anemia.

His scalp is of somewhat thinning hair, with pityriasiform and lamellar desquamations. There is also ectropion of eyelids on the patient's eyes, macula corneae, and light sensitivity. The patient does not take any eye protection products. Epiphora is present, as well as rhinorrhea and sialorrhea. Teeth are defective, partly repaired. Oral mucosa erosions are also visible. Auscultation heart is normal, symmetrically weakened respiration noise is heard dorsally above lungs. Stomach is normal, liver and spleen do not palpate.

Hands are deformed; during lifetime M.Z. have had six fist operations, last surgery was in November of 2010. On that surgery, both hands underwent the procedure by ZSRP method (Zagreb Surgical Reconstructive Procedure), since, as the patient claims, he has experienced significantly weakened function. All dexter fingers are imprisoned in a skin bag, and 4th proximal phalanx is protruding. On the left hand, thumb is only present,

while all other fingers are grown together in skin bag. The patient is usually right-handed, but due to the above described difficulties he is using his left hand more since the left thumb is still functioning. Ankylosis of the radiocarpal joint, as well as of other joints of hands and fingers, is present, while elbows are in contracture due to reduced ability of extension.

Right leg is 2 cm shorter than the left, which makes his walk somewhat unstable, but the patient walks independently. He is able to walk around 1 km during which dyspnea is not imminent, but the patient claims to get tired. Patient is complaining on ache of joints, bones and wounds as well as itching of the whole body. There are numerous wounds on his torso and extremities, ranging from the size of a coin to size of a hand. There are blisters, crusts and milia on the skin. Itching at times becomes intense in the late evening, so the patient applies cream or oil. Usually, those are the spots where skin heals, or the areas covered in milia. He takes a shower twice a week, when he dresses all the wounds. He usually rinses the wounds with tap water, he does not rip off dried out crusts because he thinks his skin heals faster that way. He uses Mepilex and Mepilex Lite compresses, and he refuses using any kind of antiseptics, antibiotics, or analgesics. Instead of conventional therapy, he puts neem tree and turmeric powders on the wounds.

### ***Personalized approach to patient M.Z.***

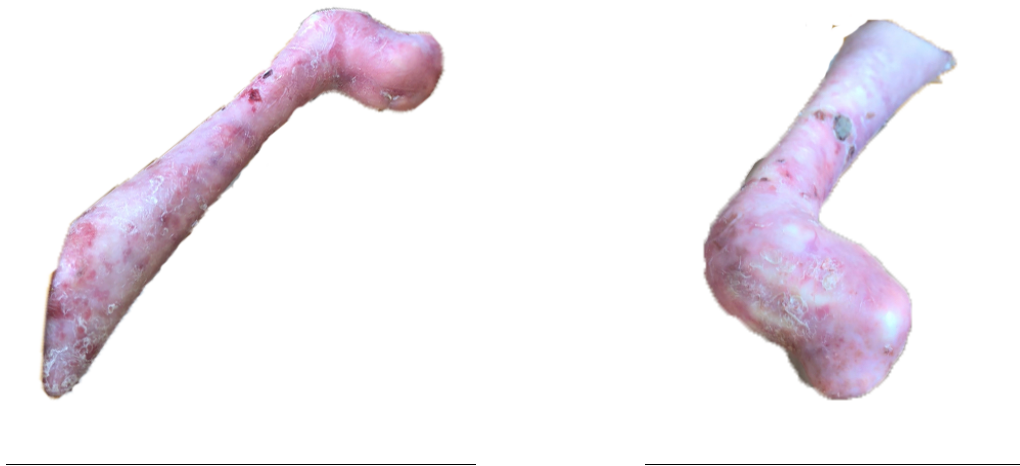Despite above mentioned difficulties and lessened quality of life, M.Z. has kept a positive attitude. He is completely independent in his everyday activities, which is only supported by the facts that he drives a car and lives alone. One of his most difficult

problems is the deformation of the hand, which makes his everyday activities harder, such as feeding, writing, cutting, using a mobile phone or computer. Consequently, this condition greatly contributes to a reduction of his life quality.

Before the helping aids were manufactured, patient was talked to on multiple occasions, regarding his needs and wishes. In the very beginning of the conversation and cooperation, M.Z. has mentioned that he does not want to be a bionic man, appealing to the use of technology as less as possible, in the final manufacturing. He would like to have an aid which is easily taken off and put on again, and which would help him in above mentioned everyday activities.

It is important to emphasize that the ability to write and draw are of great importance to this patient, since he is an artist by vocation. He likes cooking, but it takes up a lot of his time, so adequate use of kitchen utensils would be of great help. For that reason, a kind of orthosis was made for the patient, with multiple functions and applicational abilities. Orthosis will serve its purpose as an extension of the hand, which will enable him to hold a pen, drawing tools, kitchen utensils, and other objects.

Light and inert materials were used so that the patient may adapt to the helping aid, as well as to increase the functionality of the orthosis.



**Figure 5.** Photographs of patient's right hand

## **MATERIALS AND PROCEDURES**

### ***Materials***

Materials used for this research paper are divided in two major groups: hardware and software. Hardware includes: computer, 3D scanner, 3D printer, materials used for manufacturing orthosis (PLA, FilaFlex, Steel plate, Neodymium magnets, a ribbon used for orthosis placement, circular bands for surrounding objects, silk).

Computer aided designing requires use of computer and for that purpose *Apple Macbook Pro Retina 15"* was used from mid 2015 with *2,2 GHz Intel Core i7* processor, *16GB 1600MHz DDR3* memory and *Intel Iris Pro 1536MB* graphics. With the aid of the computer scanning, modeling, designing and preparing for manufacturing was done.

For scanning process, *Artec Eva* structured light 3D scanner was used. Scanner is light, fast and versatile and is one of the best handheld scanners for this kind of use. It captures precise measurements in high resolution and can capture texture of model. It encounters when scanning reflexible or dark objects since light is being reflected or absorbed. Mentioned problems can be solved using talcum powder or light spray.

As 3D printer *Prusa i3 MK2S* with *Multi-material upgrade* was used. The *Prusa i3 MK2S* is one of the most popular 3D printers in the world and thanks to great features like the heatbed and support of wide range of materials *MK2S* is the 3D printer of the year 2017 and 2018 in MAKE: Magazine. *Prusa i3 MK2S* is great printer for this purpose because it is not expensive, it provides great accuracy while using multiple materials and it can print appropriate size for hand orthosis. Most important features of this 3D printer are shown in Table 4. *Multi-material upgrade* is add-on for machine that enables the usage of up to four materials using same nozzle during the one print. This feature most 3D printers of this level do not have and that makes this printer so versatile and user friendly.

**Table 4:** *Prusa i3 MK2S* most important specifications

Source: <https://shop.prusa3d.com/en/3d-printers/59-original-prusa-i3-mk2-kit.html>  
Access: 2018, Jun 15

<b>Technology</b>	FFF (Fused Filament Fabrication) FDM (Fused Deposition Modeling)
<b>Mechanical arrangement</b>	Cartesian-XZ-Head
<b>Printable materials</b>	ABS, HIPS, Nylon, PETG, PLA, Flex, Carbon, Wood, PVA
<b>Filament diameter</b>	1,75 mm
<b>Print size millimeters (xyz)</b>	250 x 210 x 200 mm
<b>Accuracy</b>	10 x 10 x 5 Microns
<b>Layer resolution</b>	50 - 350 Microns
<b>Nozzle size</b>	0,4 mm (0,6 mm optional)
<b>Max. extruder temperature</b>	280 °C
<b>Max. heated bed temperature</b>	120 °C
<b>Max. print speed</b>	100 mm/s
<b>Slicing</b>	Slic3r, Cura, KISSlicer, Simplify3D

Materials used for manufacturing the orthosis was PLA (poly-lactic acid), PVA (polyvinyl alcohol), and FilaFlex. Orthosis was compound of PLA and FilaFlex so appropriate firmness along with elasticity could be achieved. PLA gives rigidity to the product while FilaFlex gives ability to be adaptable. PVA was used as a support material that is soluble in water so easier removability is guaranteed. Support material had to be used because of overhangs (>75 degrees), which cannot be appropriately printed on *Prusa i3 MK2S* without the use of support. PLA, PVA, and FilaFlex specifications are shown in Table 5.

**Table 5:** *Specifications of used materials; PLA, PVA and FilaFlex*

Material	PLA	PVA	FilaFlex
Filament diameter	1,75 mm	1,75 mm	1,75 mm
Printing temperature	180 - 220 °C	190 - 210 °C	210 - 230 °C
Bed temperature	0 - 90 °C	50 - 60 °C	0 °C
Printing speed	30 - 90 mm/s	5 - 30 mm/s	5 - 100 mm/s

During the process of printing steel plate was inserted in orthosis. After the printing was done, neodymium magnet was placed into socket on orthosis. Neodymium magnets are strongest commercially available permanent magnets developed in 1982 by General Motors and Sumimoto Special Metals. It is made from an alloy of neodymium, iron and boron to form tetragonal crystalline structure. Specifications of used magnets and steel plates are presented in Table 6 and 7. Neodymium magnets that was used in this research are all coated with Nickel-plated with *N35 Ni* label. As it can be seen on Table 7, pull force of magnet that was used within the orthosis is 3198 g. On distance of 2 mm (1 mm from fabric on band + 1 mm of plastic thickness above foreseen socket) pull force towards ferromagnetic object is 1029 g.



**Table 6:** *Summary of steel plates used in orthosis and bands*

Steel plate	Orthosis	Bands		
No.	1	1 per band	1 per band	2 per band
Shape	Cuboid	Cuboid	Cuboid	Ring
Dimensions	40 x 15 x 1,5 mm	40 x 15 x 1,5 mm	20 x 10 x 1 mm	5-10 x 1 mm

The pull force of the magnet while located between two steel plates, multiplies by almost four times. That is the reason the orthosis will have steel plate and one smaller magnet instead of two or more magnets.

**Table 7:** *Summary of neodymium magnets used in orthosis and bands*

Neodymium magnet	Orthosis	Bands		
No.	1	2 per band	2 per band	2 per band
Shape	Cuboid	Cuboid	Disk	Ring
Dimensions	20 x 20 x 2,5mm	20 x 20 x 2,5mm	20 x 2,5mm	5,5-10 x 3mm
Pull force (distance=0mm)	3 198 g	3 198 g	2 898 g	1 519 g
Pull force (distance=2mm)	1 029 g	1 029 g	866 g	226 g
Pull force between two steel plates (distance=2mm)	3 864 g	3 864 g	2 889 g	340 g

Moreover, adjustable bands with magnet and steel plate were designed to be used for objects of patients interest. For example, shorter band for a pencil and blonger band for a glass and similar shaped objects. Bands can be adjusted, easily migrated and used

on different objects. What's more, bands were classified by colors indicating strength of the magnet inside. The warmer the color, the stronger the magnet, as the color gets cooler, the magnets are weaker (red - strongest, blue - weakest) (Figure 6).



**Figure 6:** Example of green (low-intermediate strength) circular velcro band.

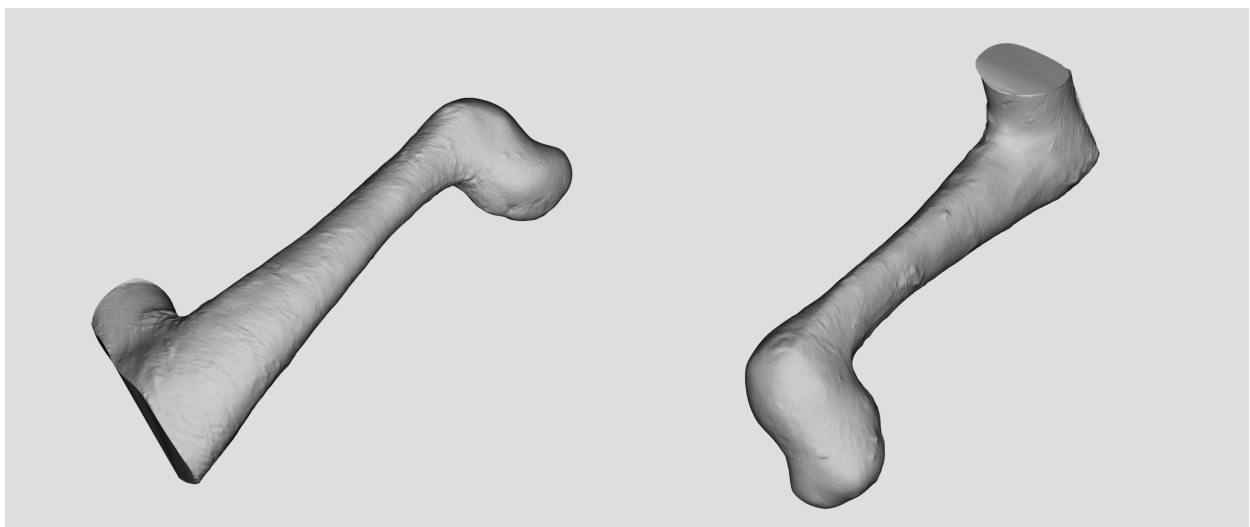
Socket for magnet was located on medial wall of prosthesis at the distal part. Steel plate socket was placed on proximal part of fist part of the orthosis. Silk was used for embroidering the orthosis from the inside to prevent high friction and reduce the risk of superinfection [33].

Software used for manufacturing orthosis was *Artec Studio* for scanning and modeling scanned model, *Fusion 360* for creating and designing the orthosis and *Slic3r Prusa Edition* to slice the model and prepare it for 3D printer. *Artec Studio* is powerful software that enables easy use of the scanner. It has the ability to track scanning in real time and helps the user with the process. *Fusion 360* is first software that has integrated Computer aided designing, manufacturing and engineering in one tool. Creating and designing of the model was done. After that, testing and engineering analysis was conducted. Furthermore, preparation for 3D printing is last process but for that purpose,

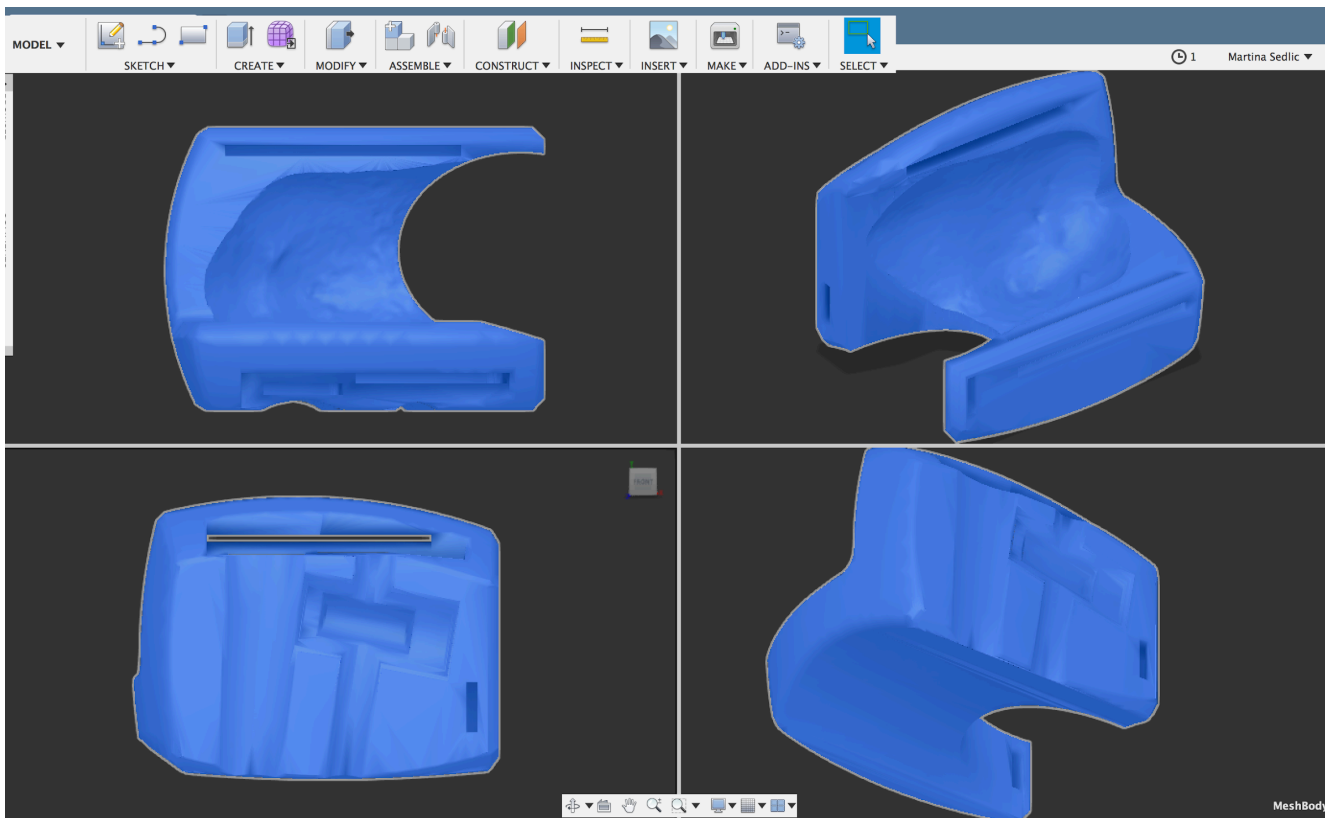
*Slic3r Prusa Edition* was used because it is the best slicer software for this printer. *Slic3r* creates gcode which is then used to control 3D printer. Gcode is numerical programming language for manufacturing machines.

## **Procedures**

The process involves scanning of the limb, creating 3D model of limb and orthosis in computer software and then manufacturing with the use of 3D printer. For scanning *Artec Eva* structured light handheld scanner was used along with complementary software *Artec Studio*. The scanning process is not complex but it is not easy as well. During the scanning, object needs to be still and the scanner has to be moved around the object. Best results can be achieved using rotating table but when patient is being scanned it is impossible to place him on table. Object should be lightened evenly without the use of sunlight. Scanner should be moved in constant speed and within field of view to perform the best results. Software has auto tracking feature so even though the user of scanner is not so experienced he can easily create quality model. After the scan is over, optimizing the result was done using *Artec Studio* (Figure 7). According to results of the scan, orthosis was designed using *Fusion 360* (Figure 8).




**Figure 7:** Obtained 3D model of patient's hand using *Artec Eva* and *Artec Studio*



**Figure 8:** *Designing model of orthosis using Fusion 360; multiple views*

Except for orthosis, a few docking stations were designed. Docking station is portable box of objects of user's interest. They were designed with the idea of easy access to all objects while using the orthosis. Docking stations are small and can be placed in a backpack. They are categorized by the objects that can be found inside. For example station with pen, felt-tip pen and pencil (Figure 9) or station with cooking tools. When station is placed, user has easy access to all objects that are contained within station. Using magnetic forces objects are drawn out of station, or can be detached without problem when placed back. To finalize the process, *Slic3r Prusa edition* was used for creating gcode. Using *Slic3r* slicing features were arranged. For printing orthosis three different materials were used to assure best quality of print and model.



**Figure 9:** *Designing model of “pencil box” using Fusion 360*

Steel plate was placed on predicted place during the process of printing. After the printing was done, neodymium magnet was placed in its socket. Socket was then closed with the use of thermoplastic glue. Furthermore, bands were placed so the orthosis can be used by the patient itself and without the help of others. To finalize the process, the silk was coated from the inside of EBility.

To summarize, this process brings personalized access options in the form of better design, flexibility, customer satisfaction and easier customization.

## RESULTS

As mentioned above, the main purpose of this work was to invent and produce hand orthosis for the patient M.Z. who has skin disease Epidermolysis bullosa. Besides

that, we sought to establish a new methodology for designing, manufacturing and using orthosis of that kind.

There are three main features that must be accomplished. Firstly, orthosis should be as simple as possible, which means that it can be easily and independently set up and removed. Secondly, in the same way, it should enable patient to pick up and lift in order to provide appropriate use of things like pen, pencil, spoon, fork, keys, knife, glass, bottle, toothbrush or mobile phone. Last but not least, to prevent the destruction of already fragile skin, materials which were used for production of orthosis had to be lightweight, comfortable and inert.

The ultimate product is called *EBility*; name comes from abbreviation of the Epidermolysis bullosa and the word “ability“. In order to improve abilities in everyday activities, this orthosis can be easily transformed to the other patients with the DEB.

Namely, *EBility* is 3D printed tool that enabling the usage of surrounding objects using magnetic force.

Beforehand, patient M.Z., who had been diagnosed with RDEB at his birth, was introduced. Anamnesis was taken, patient was examined and dermatological status has been written. During the conversation and examination, his needs and wishes were determined and according to those wishes orthosis was designed and created.

At the beginning, patient's hand was scanned using structured light 3D scanner and 3D model of the hand was processed using *Artec Studio*. Shortly after, according to obtained 3D model of the hand orthosis was designed in *Fusion 360*. Orthosis model was designed following contours of the fist to ensure perfect fit. Also, four holes for two ribbons were created. Furthermore, two sockets for steel plate and neodymium magnet had been designed according to its dimensions. Position of sockets are located on medial wall of fist part; on the proximal side there is steel plate and on the distal is

neodymium magnet. Additionally, on that part are designed two canals. First canal is on part where steel is placed and it serves for better writing technique. Second canal was located on magnetic plate and it serves to simplify the use of cutlery. Lastly, two bands are attached that serves to close the orthosis.

When designing was finished, .stl file was exported from *Fusion 360*. Then, file was imported to the *Slic3r*, and printing settings were adjusted as presented in Table 8.

**Table 8:** *Slic3r* settings for 3D printer

<b>Layer height</b>	0,1 mm	<b>Printing speed</b>	20 mm/s
<b>Wall thickness</b>	1 mm	<b>Infill</b>	50%
<b>Solid layers top/bottom</b>	5	<b>Extrusion</b>	0,95
<b>Support</b>	Custom support	<b>Retraction</b>	Disabled

For printing EBility, support had to be generated because *Prusa i3 MK2S* is not able to print overhanging objects (>75 degree from printing plane). Slicing settings were adjusted according to data collected from developers about used materials best performance. Soon, materials were placed in different extruders; FilaFlex in first, PLA in second, and PVA in third. Afterwards, orthosis was manufactured and put in bucket full of water to dissolve support material.

Nevertheless, first prototype was made out of PLA because it is easier and more effective material for prototyping (Figure 10). The time required for printing was 17 hours and 20 minutes.



**Figure 10:** *The first prototype of EBility*

The steel plate and the magnet were placed in foreseen sockets. Ribbons were attached to orthosis to ensure easy set up or take off.

Simultaneously, different type of circular velcro (adhesive) bands were created. Design of circular bands provided use of different objects of interest for the user. The free parts of the band were brought together and combined so they cannot be separated but yet, tightening or loosening of the band is enabled. On these bands second steel plate with attached neodymium magnets are woven at the end of the band.

When neodymium magnet N35 of this size is located between two steel plates (one plate on orthosis and second on a band) it's pull force is multiplied by four. The proximal part where the steel plate is located serves for retrieval of non-metallic objects and it is used with the already mentioned circular band that is placed around a subject. Magnet located in orthosis is used for ferromagnetic objects like spoon, fork, steel knife or keys which can be placed in guided canal designed on the orthosis.



For the end of orthosis arrangement, silk was embossed from inside because it is recommended for patients suffering from EB to wear material like silk cause of its inert ability. Besides that, whole process of designing, slicing and manufacturing was repeated for something like pencil box. Using that thing, easy access and removal of pens and pencils was enabled. Finally, orthosis was finished as well as all appurtenant tools.

Patient tried the orthosis that was perfect fit and soon first results of testing will be acquired. Quality of life was expected to improve greatly because the patient could easily use pens and pencils for his work since he is an artist by vocation.

## **DISCUSSION**

Prior researches with this subject were not documented yet so new methodology of personalized approach and new way of designing and manufacturing was suggested. For this reason and because of significantly lower quality of life of patients suffering from EB, this research paper was written. However, with the use of new technologies, their needs can be fulfilled and quality of life can be improved. In this research, we tested application of CAD/CAM in creating personalized orthosis for patient suffering from generalized severe RDEB. Using 3D scanner, 3D printer and appurtenant software orthosis was designed and manufactured. It was upgraded with two ribbons, steel plate and neodymium magnet to provide orthosis possibility of bearing objects using magnetic force. Likewise, circular velcro bands with magnets and steel plates were created for easier utilization of everyday objects in patients activity. When using objects with circular bands, magnet is located between two steel plates what in this case, multiplies pull force by four times.

EBility was embossed from inside with silk in order to avoid skin reactions and infections. In the meantime, “pencil box” was designed to easily attach or detach pens, pencils and crayons which greatly improved quality of patients life since patient is artist.

These EBility designing and manufacturing processes are a kind of extension of earlier applications of new technologies in medicine and they show an example of personalized approach to the patient. In addition, the biggest benefit provided with EBility is that it may be replicated across a wide range of patients.

CAD/CAM technologies have wide application in orthotics. However, this research is the first example of its appliance in helping a patient suffering from EB. Our results provide compelling evidence for improving patient’s quality of life. It means helping them in following activities of daily living: eating, drinking, writing, holding a cell phone or toothbrush. Therefore, we hope that the proposed methodology will soon become the backbone of assisting patients suffering from DEB or similar diseases to become more effective in day-to-day activities and thus improve the quality of their life.

Notable to mention are the limitations of proposed methodology. Some magnets that were used in research are too strong and they may interfere with some surrounding objects and may perhaps be able to cause problems in working of mobile phone or possibly credit card. Another limitation is relatively low-speed of manufacturing that should be overcome in next studies if technology does not solve this problem by itself thanks to its fast development. The main limitation of EBility is that it is not possible to retrieve or attract all objects from the environment, but only those metal ones and those that can be fitted with a magnet and circular band.

Future work on this orthosis should include the development of prosthetic thumb that could handle some of the objects from the environment that are not possible by using EBility. Moreover, best achievement should be realised by applying knowledge on

robotics in the development of these types of orthosis. Eventually, we expect that this would greatly improve the quality of life and consequently life expectancy would also be increased.

## **CONCLUSION**

In this research new methodology of designing, manufacturing and way of using orthosis is proposed and presented. Personalised approach was achieved with the usage of 3D scanning and printing technology and that approach has provided us with promising results. These technologies were applied in the case of the patient suffering from generalized severe type of RDEB. As the effect of the illness, patient M.Z. has deformative hands with only one functioning finger on both hands, his left thumb. Thus his day-to-day possibilities are reduced or take away a lot of time to do, which contributes to reduction of the quality of life. Therefore, given results show that expected improvements in quality of life were valid and that proposed methodology is worth of improving and expanding its usage. Possible incorporation of robotics into this field could raise the orthosis to the next level. With robotic hand, users will be as effective as healthy population.

To sum up, the future of medicine is personalised approach in which patient and his needs are in the center of treatment. That approach is relieved with the use of new technologies like 3D scanning and printing. Structured light 3D scanning provides fast and high quality representation of model and use of CAD/CAM along with 3D printer ensure that almost everything can be manufactured.

That leads us to a conclusion that new technologies can greatly help in improving of patients life and that synergy of different sciences lead us to results which are beyond expected.

# SUMMARY

In the last few years importance of personalized approach in treating patients started to be a backbone of medicine. Medicine as a science is reserved for early implementation of new technologies. That implies the implementation of 3D scanning and 3D printing technologies in the case of patient suffering from *Epidermolysis bullosa dystrophica recessiva* with severe deformities of the hand. It is a rare cutaneous disease characterized by the presence of blisters with skin and mucous fragility.

After initial talks with the patient as well as taking anamnesis and physical examination, the orthosis named EBility was designed according to patient's preferences. Soon, using CAM software model of orthosis was prepared and then manufactured with 3D printer. EBility has steel and neodymium magnet plates placed in foreseen sockets. The steel plate is combined with circular velcro bands while magnet plate serves to attract ferromagnetic objects. Velcro bands have steel plate with magnets embroidered and they can be put on different objects so orthosis is able to pick those objects up using magnetic force. In addition, neodymium magnet of used shape and size located between two steel plates, has its pull force multiplied and on that physical law functioning of EBility is based.

Furthermore, docking station for pencils is created to ease usage of those tools since patient who participated in research is artist. To summarize, synergy involving mechanical engineering and medicine greatly improved patients quality of life what leads us to conclusion that collaboration between these two scientific disciplines needs to be augmented.

# SAŽETAK

U posljednjih nekoliko godina važnost personaliziranog pristupa u liječenju pacijenta počela je biti kamen temeljac medicine. Medicina kao znanost rezervirana je za ranu implementaciju novih tehnologija. U ovom slučaju to znači korištenje tehnologije 3D skenera i 3D tiska u službi pacijenta koji boluje od recesivne distrofične bulozne epidermolize te ima teške deformacije ruku. To je rijetka bolest kože koja je karakterizirana prisutnošću mjehura uz krhkost kože i sluznica.

Nakon inicijalnog razgovora s pacijentom uzeta je anamneza i fizikalni status te je prema pacijentovim prioritetima dizajnirana ortoza nazvana EBility. Nakon toga, koristeći CAM software model ortoze je bio spreman za izradu s 3D tiskom. EBility na sebi ima dva utora u kojima se nalaze čelična i magnetna pločica. Ta čelična pločica se kombinira s kružnim čičak trakama dok magnetna pločica služi za privlačenje feromagnetičnih objekata. Trake s čičkom na sebi imaju čelične pločice s utkanim magnetima koje mogu biti postavljene na različite predmete i koje omogućuju ortozi da korištenjem magnetne sile privuku predmete. Nadalje, neodimijski magnet korištenog oblika i veličine postavljen je između dviju čeličnih pločica čime se privlačna sila umnožava i na tom se zakonu fizike temelji funkcioniranje EBility-a.

Štoviše, kreirana je stanica za držanje olovaka kako bi olakšala uporabu tih predmeta budući da je pacijent koji je sudjelovao u istraživanju umjetnik. Ukratko, sinergija inženjerstva i medicine znatno je poboljšala kvalitetu života pacijenata pri čemu se iz navedenih činjenica u ovom diplomskom radu može zaključiti kako znanstveni trendovi donose daljnje širenje ovog područja i sve bližu interdisciplinarnu suradnju.

# LITERATURE

1. Gaitskell K. Personalised Medicine Approaches to Screening and Prevention. New Bioeth 2017
2. Kent A. Risk and Benefit in Personalised Medicine: An End User View. New Bioeth. 2017
3. Schubert C, Van Langeveld MC, Donoso LA. Innovations in 3D printing: A 3D overview from optics to organs. Br J Ophthalmol. 2014
4. Klein GT, Lu Y, Wang MY. 3D printing and neurosurgery--ready for prime time? World neurosurgery. 2013
5. Banks J. Adding value in additive manufacturing: Researchers in the United Kingdom and Europe look to 3D printing for customization. IEEE Pulse. 2013
6. Bishop ES, Mostafa S, Pakvasa M, Luu HH, Lee MJ, Wolf JM, et al. 3-D bioprinting technologies in tissue engineering and regenerative medicine: Current and future trends. Genes and Diseases. 2017
7. Singh D, Singh D, Han SS. 3D printing of scaffold for cells delivery: Advances in skin tissue engineering. Polymers. 2016
8. Maldonado-Colin G, Hernández-Zepeda C, Durán-McKinster C, García-Romero M. Inherited epidermolysis bullosa: A multisystem disease of skin and mucosae fragility. Indian J Paediatr Dermatology. 2017
9. Glicenstein J, Mariani D, Haddad R. The hand in recessive dystrophic epidermolysis bullosa. Hand Clin [Internet]. 2000 Nov [cited 2018 Apr 12];16(4):637–45. Available from: <http://www.ncbi.nlm.nih.gov/pubmed/11117053>
10. Xu L, Chen M, Peng J, O'Toole EA, Woodley DT, Chan LS. Molecular cloning and characterization of a cDNA encoding canine type VII collagen non-collagenous

- (NC1) domain, the target antigen of autoimmune disease epidermolysis bullosa acquisita (EBA). *Biochim Biophys Acta - Mol Basis Dis* [Internet]. 1998 [cited 2018 May 5]; 1408 (1): 25–34. Available from: <https://www.sciencedirect.com/science/article/pii/S0925443998000490?via%3Dihub>
11. Rashidghamat E, McGrath JA. Novel and emerging therapies in the treatment of recessive dystrophic epidermolysis bullosa. *Intractable Rare Dis Res*. 2017
  12. Yucel O. Annals of Clinical Case Reports Dystrophic Epidermolysis Bullosa with Laryngotracheal Involvement: Abscess on the Vocal Cords. *Ann Clin Case Rep* [Internet]. 2017 [cited 2018 May 19];2. Available from: <http://anncaserep.com/>
  13. Eswara U. Dystrophic epidermolysis bullosa in a child. *Contemp Clin Dent* [Internet]. 2012 Jan [cited 2018 May 5];3(1):90–2. Available from: <http://www.ncbi.nlm.nih.gov/pubmed/22557906>
  14. AB J and associates. *Dermatovenerologija. Medicinska naklada*; 2014. 824 p.
  15. Pustišek N, Kljenak A, Ilić MK, Višnjić S, Striber N, Cvitković B, et al. Update on the classification, diagnostics and therapy of epidermolysis bullosa hereditaria . *Paediatr Croat*. 2005
  16. Agranovich OE, Buklaev DS, Tikhonenko TI, Tikhonenko TI, Tikhonenko TI, Ivanovcha TT. Dystrophic epidermolysis bullosa associated with congenital contractures of the upper and lower limbs: literature review. *Pediatr Traumatol Orthop Reconstr Surg* [Internet]. 2015 Dec 15 [cited 2018 May 8];3(4):51. Available from: <http://journals.eco-vector.com/index.php/turner/article/view/967>
  17. Goldschneider KR, Good J, Harrop E, Liossi C, Lynch-Jordan A, Martinez AE, et al. Pain care for patients with epidermolysis bullosa: Best care practice guidelines. *BMC Med*. 2014

18. Fine J-D. Inherited epidermolysis bullosa. Orphanet J Rare Dis [Internet]. 2010 May 28 [cited 2018 May 19];5:12. Available from: <http://www.ncbi.nlm.nih.gov/pubmed/20507631>
19. Fine JD, Eady RAJ, Bauer EA, Bauer JW, Bruckner-Tuderman L, Heagerty A, et al. The classification of inherited epidermolysis bullosa (EB): Report of the Third International Consensus Meeting on Diagnosis and Classification of EB. J Am Acad Dermatol. 2008
20. Intong LRA, Murrell DF. Inherited epidermolysis bullosa: New diagnostic criteria and classification. Clin Dermatol. 2012
21. Fine JD, Bruckner-Tuderman L, Eady RAJ, Bauer EA, Bauer JW, Has C, et al. Inherited epidermolysis bullosa: Updated recommendations on diagnosis and classification. J Am Acad Dermatol. 2014
22. Tong L, Hodgkins PR, Denyer J, Brosnahan D, Harper J, Russell-Eggitt I, et al. The eye in epidermolysis bullosa. Br J Ophthalmol. 1999
23. Murat-Sušić S, Husar K, Skerlev M, Marinović B, Babić I. Inherited epidermolysis bullosa - the spectrum of complications. Acta Dermatovenerologica Croatica. 2011
24. Fine JD, Johnson LB, Weiner M, Suchindran C. Gastrointestinal complications of inherited epidermolysis bullosa: Cumulative experience of the national epidermolysis bullosa registry. J Pediatr Gastroenterol Nutr. 2008
25. Zidario APC, Dutra ES, Leão DOD, Costa IMC. Nutritional aspects of children and adolescents with epidermolysis bullosa: literature review. An Bras Dermatol [Internet]. 2015 [cited 2018 Apr 25];90(2):217–23. Available from: <http://www.ncbi.nlm.nih.gov/pubmed/25830992>
26. Downe A. The effect of current economic cuts to wound dressings and its impact on patients with epidermolysis bullosa: A case study. Wounds UK. 2017



27. Shinkuma S. Dystrophic epidermolysis bullosa: a review. Clin Cosmet Investig Dermatol [Internet]. 2015 [cited 2018 Apr 10];8:275–84. Available from: <http://www.ncbi.nlm.nih.gov/pubmed/26064063>
28. Kawaguchi M, Mitsuhashi Y, Kondo S. Osteoporosis in a patient with recessive dystrophic epidermolysis bullosa. Br J Dermatol [Internet]. 1999 Nov [cited 2018 May 19];141(5):934–5. Available from: <http://www.ncbi.nlm.nih.gov/pubmed/10583187>
29. Melville C, Atherton D, Burch M, Cohn A, Sullivan I. Fatal cardiomyopathy in dystrophic epidermolysis bullosa. Br J Dermatol [Internet]. 1996 Oct [cited 2018 Apr 8];135(4):603–6. Available from: <http://www.ncbi.nlm.nih.gov/pubmed/8915155>
30. Marini I, Vecchiet F. Sucralfate: A Help During Oral Management in Patients With Epidermolysis Bullosa. J Periodontol [Internet]. 2001 May [cited 2018 Apr 25];72(5):691–5. Available from: <http://www.ncbi.nlm.nih.gov/pubmed/11394407>
31. Dohil R, Aceves SS, Dohil MA. Oral viscous budesonide therapy in children with epidermolysis bullosa and proximal esophageal strictures. J Pediatr Gastroenterol Nutr. 2011
32. Belsey JD, Geraint M, Dixon TA. Systematic review and meta analysis: Polyethylene glycol in adults with non-organic constipation. International Journal of Clinical Practice. 2010
33. Khan MT. Podiatric management in epidermolysis bullosa. Dermatologic Clinics. 2010

# CURRICULUM VITAE

Martina Sedlić was born on November 11th, 1992 in Bjelovar. From 2007 to 2011 she attended the Natural and Mathematics Department of Gymnasium in Bjelovar. She was studying medicine at the University of Rijeka from 2012 to 2018.

In August 2015 she completed her professional exchange program. The student worked in the department of head and neck surgery in Surakarta, Indonesia.

April 2016- completed education about 3D printing and 3D modeling, Rijeka, Porin d.o.o

From May to November of 2016 she developed her business idea in Startup Incubator Rijeka. Namely, she is one of the co-founders of the *Braille Riddles* project, which deals with assisting in the education of blind and visually impaired people.

In November 2016 and 2017, as a member of the team "*Solution*", she won a case study competition "*Realizator*" organized by the Foundation of the University of Rijeka.

In November 2017 she completed the education of EU project preparation and implementation in Porin d.o.o.

Since March 2018 she is the president of the Association for education of blind and partially sighted people *Braille Academy*. She speaks Spanish at the basic level (A2) while German (B1) and English language are at the intermediate level of knowledge (B2).