

Wide QRS complex

Stridbeck, Curt Tobias

Master's thesis / Diplomski rad

2019

Degree Grantor / Ustanova koja je dodijelila akademski / stručni stupanj: **University of Zagreb, School of Medicine / Sveučilište u Zagrebu, Medicinski fakultet**

Permanent link / Trajna poveznica: <https://um.nsk.hr/um:nbn:hr:105:096765>

Rights / Prava: [In copyright / Zaštićeno autorskim pravom.](#)

Download date / Datum preuzimanja: **2024-04-24**



Repository / Repozitorij:

[Dr Med - University of Zagreb School of Medicine
Digital Repository](#)



**UNIVERSITY OF ZAGREB
SCHOOL OF MEDICINE**

Tobias Stridbeck

Wide QRS-Complex Tachycardia: Diagnostic Approach and Treatment

GRADUATE THESIS



Zagreb, 2019

This graduate thesis was made at Sestre milosrdnice University Hospital Center, Department for Cardiology mentored by MD, PhD, Assistant Professor Matias Trbušić and was submitted for evaluation 2019.

Abbreviations:

AV – Atrio-ventricular

BBB – Bundle-branch block

ECG – Electrocardiography

ECMO – Extracorporeal Membrane Oxygenation

EP – Electrophysiological

ES – Electrical Storm

ICD – Implantable Cardioverter Defibrillator

LBBB – Left Bundle-branch block

LVEF – Left Ventricular Ejection Fraction

LV – Left Ventricle

MI – Myocardial Infarction

RBBB – Right Bundle-branch block

RF – Radiofrequency

RV – Right Ventricle

RWPT – R-wave peak time

VA-ECMO – Venoarterial Extracorporeal Membrane Oxygenation

VF – Ventricular Fibrillation

VT – Ventricular tachycardia

SCD – Sudden Cardiac Death

STEMI – ST Elevation Myocardial Infarction

SVT – Supraventricular tachycardia

WCD – Wearable Cardioverter Defibrillator

WPW – Wolff-Parkinson-White

Contents

1. Summary.....	5
2. Sažetak.....	6
3. Introduction.....	7
4. Etiology.....	8
5. Clinical assessment.....	10
6. Electrocardiography.....	12
7. Algorithms.....	16
8. Treatment.....	19
9. Acknowledgments.....	24
10. References.....	25
11. Biography.....	27

Wide QRS complex tachycardia: Diagnostic approach and treatment.

Tobias Stridbeck

Patients with wide QRS complex tachycardias are a challenge for physicians when they are presenting in the emergency department. Symptoms associated with tachycardia can vary, from mild symptoms as lightheadedness, weakness, chest discomfort, excessive sweating and palpitations, to more severe such as dizziness, angina, pulmonary edema, pre-syncope or syncope, coming from hemodynamic instability.

It is important to differentiate between the aetiologies since some of the initial treatment for tachyarrhythmia with SVT as etiology can be lethal for a patient with VT. If the patient is hemodynamically unstable urgent synchronised electrical cardioversion, or defibrillation in the case of pulseless VT, is the first line initial therapy. If the patient is hemodynamically stable the physician should use clues to differentiate etiology of wide QRS complex tachycardia. These clues are present in the medical history, physical examination and echocardiography in order to verify structural heart disease if present.

Of crucial importance is high quality ECG interpretation including rate, rhythm, axis and morphology of the QRS complex using provided ECG criteria that helps us to differentiate VT from SVT. Until proven otherwise, any wide QRS complex tachycardia should be managed as a VT.

In the case of VT the drugs of choice are procainamide and amiodarone with some advantage of procainamide. While ICD is used regularly for secondary prevention of SCD, there is under investigation a new concept of wearable cardioverter defibrillator indicated for patients with poor left ventricular function who are at risk for SCD but are not candidates for an ICD. Catheter ablation is an effective treatment option for patients with repetitive VT and structural heart disease. It can reduce the number of ICD shocks, but there is still not clear mortality benefit. VA-ECMO is a new and interesting approach for patients with VT and electrical storm as a rescue bridge to other treatment options.

Key words: wide QRS complex tachycardia, ventricular tachycardia, supraventricular tachycardia, differential diagnosis, electrocardiogram, criteria, treatment.

Tahikardija širokog QRS kompleksa: dijagnostički postupci i liječenje

Tobias Stridbeck

Bolesnici s tahikardijom širokog QRS kompleksa izazov su za liječnika u hitnoj službi. Simptomi mogu varirati od blagih kao slabost, nelagoda u prsima, prenožavanje i palpitacije do ozbiljnijih poput angine, plućnog edema, presinkope i sinkope u okviru hemodinamske nestabilnosti.

Važno je razlikovati uzrok tahikardije širokog QRS kompleksa jer neki lijekovi koji se koriste u liječenju supraventrikulske tahikardije (SVT) mogu uzrokovati pogoršanje i smrt bolesnika s ventrikulskom tahikardijom (VT). Ako je inicijalno bolesnik hemodinamski nestabilan indicirana je elektrokardioverzija ili, u slučaju VT bez pulsa, defibrilacija. Ako je bolesnik hemodinamski stabilan, tada je potrebno na temelju specifičnih pokazatelja postaviti točnu dijagnozu tahikardije širokog QRS kompleksa. Ti pokazatelji nalaze se u anamnezi, fizikalnom pregledu i ehokardiografiji koja se izvodi s ciljem da se dokaže strukturna bolest srca ako je prisutna.

Od ključne važnosti je kvalitetna interpretacija elektrokardiograma uključujući frekvenciju, ritam, električnu os i morfologiju QRS kompleksa koristeći postojeće EKG kriterije za razlikovanje VT od SVT. Dok se ne dokaže suprotno, na bilo koju tahikardiju širokog QRS kompleksa treba gledati kao VT i tako ju i liječiti.

U slučaju VT lijek izbora su prokainamid i amiodaron s time da je prema nekim studijama prokainamid u prednosti. ICD se redovito koristi za sekundarnu prevenciju iznenadne srčane smrti (ISS), ali je sada u istraživanjima novi koncept vanjskog kardioverter defibrilatora indiciranog u bolesnika sa reduciranom funkcijom lijeve klijetke koji su pod rizikom za iznenadnu srčanu smrt, a nisu kandidati za ICD. Kateter ablacija je učinkovit oblik liječenja za ponavljajuće VT kod bolesnika sa strukturnom bolešću srca koja može smanjiti broj ICD šokova, ali još uvijek nije jasno da li smanjuje smrtnost. VA-ECMO nov je i zanimljiv pristup za bolesnike s VT i električnom olujom kao spašavajući most do drugih mogućnosti liječenja.

Introduction

Wide QRS complex tachycardia is a common arrhythmia to encounter in the emergency department and it often presents as a diagnostic challenge. Wide QRS complex tachycardia can be defined as a tachycardia having a QRS duration of greater than 120 milliseconds or 0.12 seconds, which is the upper limit of normal QRS duration.(1) When presented with a wide QRS complex tachycardia it is important to decide whether it is ventricular tachycardia (VT), supraventricular tachycardia (SVT) with aberrancy, typically with a functional right or left bundle-branch block (BBB), or a pre-exited tachycardia using an accessory atrioventricular (AV) pathway to conduct the stimuli to the ventricles. It is not only an academic problem with diagnosing the different etiologies but it can lead to inappropriate treatment which can be potentially lethal, especially if VT is misdiagnosed as SVT.(2)

The differentiation between SVT and VT is very important due to SVT having generally a good prognosis and VT being potentially lethal if not properly managed. In a study by Morady et al (3) it was shown that physicians have a tendency to favor the diagnosis of SVT with aberrancy and underdiagnose VT when the patient is hemodynamically stable.

Etiology

In the healthy heart an electrical stimulus is generated in the sinoatrial node which activate the atria then the stimulus propagates to the atrioventricular node and continue to the bundle of His, which is divided into the right and left bundle branches, in to the specialised Purkinje network in the ventricles. Normally the ventricles are depolarised simultaneously and it is accomplished within 80 to 120 milliseconds. Prolongation of the depolarisation time occurs if the ventricles are not depolarised simultaneously which occurs in case of bundle branch block, VT or ventricular activation through an accessory pathway. It can also occur in case of electrolyte disturbances (i.e. hyperkalemia) or drugs.

Wide QRS complex tachycardia can be divided in to three groups.

- SVT with bundle branch block. The BBB might be pre-existing or can occur when the refractory period of one of the bundle branches is reached because of the heart rate of the SVT. The causes with BBB can be found in patients with atrial tachycardia, atrial flutter, atrial fibrillation, atrioventricular nodal tachycardia.
- SVT with atrioventricular conduction over an accessory atrioventricular pathway. This may occur in patients with atrial tachycardia, atrial flutter, atrial fibrillation, atrioventricular nodal tachycardia and antidromic circus movement tachycardia. The most common condition of SVT with accessory pathway is the Wolff-Parkinson-White Syndrome which uses the Kent bundle, most commonly located in the left free wall, which leads to the ventricles being activated prematurely.(1)
- VT, which is the most common cause of wide QRS complex tachycardias.(4) Ventricular tachycardia is defined as three or more consecutive ventricular beats with a rate of 100 beats per minute or more. VT can be non-sustained, if it lasts less than 30 seconds, or sustained if it lasts longer than 30 seconds, presents with hemodynamic symptoms (e.g. syncope) or if it requires therapy to stop it. VT can also be classified as being monomorphic, meaning the QRS complexes are uniform in any given lead, or polymorphic where the QRS complexes morphology changes continuously in a single lead.(5) One form of polymorphic VT is Torsade de Pointes which is typically characterised with a change in amplitude and twisting of the QRS complexes. Torsades is associated with prolonged QT intervals which can be congenital or acquired. Monomorphic is typically encountered when there is an underlying

structural pathology in the heart, for example scarring, hypertrophy, cardiomyopathy or an old infarct. In such a case the electrical impulse moves slowly through the defective tissue giving the healthy tissue time to repolarize after which it becomes activated again from the slow moving impulse from the defective tissue.

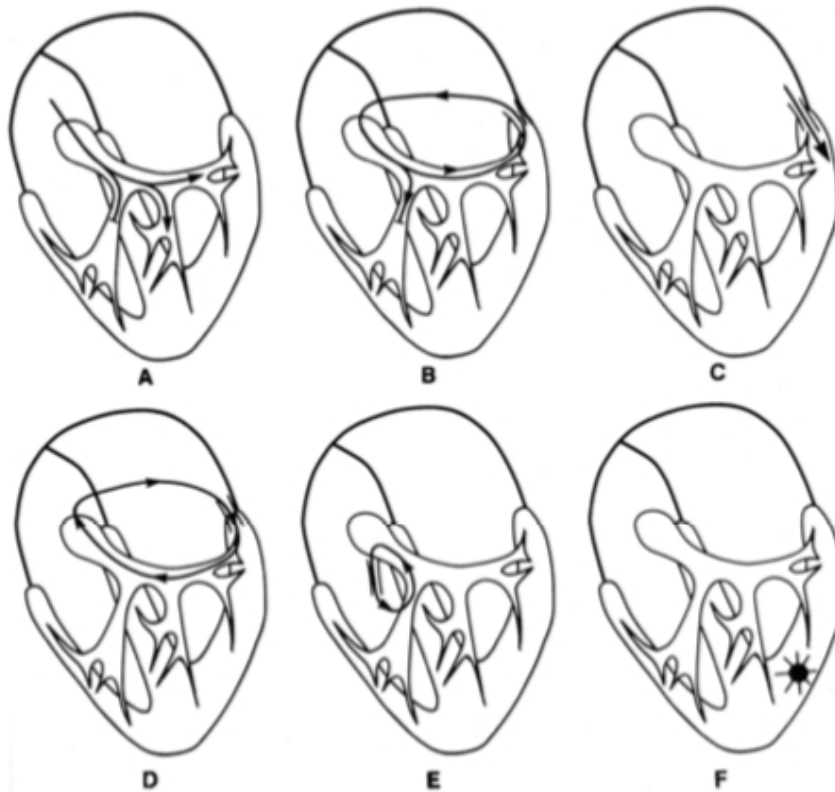


Illustration 1: Illustrations showing different etiologies of WCT. A: SVT with pre-existing BBB. B: CMT with pre-existing BBB. C: SVT with AV conduction over accessory pathway. D: CMT with AV conduction over accessory pathway. E: Tachycardia with anterograde conduction over noduventricular fibers. F: VT.(1)

Clinical Assessment

In dealing with any patient and any disease a proper history is giving a lot of valuable clues, so is the case with wide QRS complex tachycardias. as well. It is important to find out if the tachyarrhythmia has happened before and if the patient is aware of the etiology. Structural heart disease, coronary artery disease (CAD), old myocardial infarctions and congestive heart failure greatly points to that VT is the cause. VT is more common to occur amongst older patients whereas SVT is more likely to be in younger patients without previous heart disease. In greater than 98% of patients with previous myocardial infarction presenting with wide complex tachycardia the cause is VT, where patients with SVT only 7% showed old myocardial infarction.(4) It can also be of great value to know if the patient has a pacemaker or implantable cardioverter-defibrillator (ICD) as that could be a possible cause but more important it shows that the patient is at risk for VT. In case of pacemaker-mediated wide QRS complex tachycardia a pacemaker magnet can be held over the pacemaker generator which can terminate the abnormal rhythm and is in such case both diagnostic and therapeutic.(1)

The duration of the tachyarrhythmia is also important to know, if it has been present for longer than three years or has been recurring since childhood it is more likely to be caused by SVT. (6) Whereas if it is the first occurrence after a myocardial infarction it suggests VT. It is important to know what medications the patient is taking since some medications can affect the QRS complex. Such as dofetilide, quinidine and erythromycin that can cause Torsade de pointes, which is a form of polymorphic VT. Drugs that can affect the electrolyte balance such as diuretics or ACE-inhibitors can lead to an electrolyte disbalance, mainly hypokalemia, hyperkalemia and hypomagnesemia, that can predispose the patient to VT.(7)

Symptoms associated with tachyarrhythmia can vary, from mild symptoms as lightheadedness, weakness, chest discomfort, excessive sweating and palpitations, to more severe such as dizziness, angina, pulmonary edema, pre-syncope or syncope, coming from hemodynamic instability. The symptoms comes from the increased heart rate, heart disease and left ventricular function, not from the underlying mechanism of tachyarrhythmia.(4) Since SVT usually occurs in younger patients with no heart disease and functioning left ventricle it rarely shows symptoms of hemodynamic instability unless there is a presence of valvular or congenital heart disease. Hemodynamic instability is commonly misunderstood, it is not based on the QRS complex width nor heart rate and hemodynamic instability does not aid in differentiating the diagnosis. A patient with wide QRS complex tachycardia is stable or unstable depending on the effect on end organ

perfusion.(1)

Atrioventricular dissociation is rarely seen in SVT however it is present in 60% to 75% of patients with VT. When the atria and ventricle contractions are not synchronised and the atria contracts against a closed tricuspid valve the blood is forced up in to the jugular veins in irregular pulsations called cannon A waves. The asynchrony of the atria and ventricles also results in variability in regularity and intensity of the heart sounds.

Laboratory studies

It is useful to assess the electrolyte levels of patients with wide QRS complex tachycardia since the underlying cause might be an electrolyte disbalance. Including serum potassium, magnesium, calcium and phosphate levels. A common cause of VT is hypokalemia, especially in patients taking diuretics. Hypokalemia, hypomagnesemia and hypocalcemia all can trigger predisposed patients to both monomorphic and polymorphic VT. Troponin I or T serum levels or other cardiac markers may be useful to see if there is ongoing ischemia of the myocardium.

Echocardiography

Echocardiography is used for patients at high risk for serious ventricular arrhythmias or sudden cardiac death. Echocardiography can provide an estimation of left ventricular (LV) systolic function, regional wall contraction abnormality suggestive to ischemic heart disease or prior scar. Echocardiography may also show findings indicative to myocardial infiltrative process such as amyloidosis. Especially is important to verify valvular heart disease because in this case every form of tachycardia can be more hemodynamically important. Imaging of the right ventricle (RV) may be more limited, and other imaging techniques like magnetic resonance may be required.(8) The high-risk group consists of patients with any of the following:

- Dilated, hypertrophic or RV cardiomyopathy
- A history of acute myocardial infarction
- Inherited disorders associated with sudden cardiac death

Electrocardiography

The most important tool for diagnosing and correctly identifying the etiology of the wide QRS complex tachycardia is the 12-lead surface electrocardiogram. The use of a single lead rhythm strip is not recommended because it can be very misleading, the wide QRS complex can not be present in some leads or even appear as a narrow QRS complex. Therefore it is important to make use of the 12-lead echocardiogram. If possible it is very helpful to compare the ECG recording with a recording during sinus rhythm. If the recording is showing a shift in the axis and significant change in the QRS morphology it strongly points towards being VT. If the axis and QRS morphology is similar it suggests SVT. If the sinus rhythm recording shows a bundle branch block pattern and the same pattern is present in the new ECG recording it is likely SVT with bundle branch block.(4)

Rhythm

Irregularity in rhythm has been described in SVT but is not as common in VT. A highly irregular rhythm wide QRS complex tachycardia is most commonly present in atrial fibrillation with aberrant conduction, atrial fibrillation with conduction over an accessory pathway or irregular VT.(9)

Rate

Rates between 170 beats per minute and 200 beats per minute are more common in SVT, whereas in VT it is more frequent with rates between 130 bpm and 170 bpm. But rates over 200 bpm can be present in both groups so there is too much overlap between the groups to have heart rate as a useful criterion.

Atrioventricular dissociation

It may be difficult to distinguish P waves during wide QRS complex tachycardia but they may be seen dissociated from the QRS complex. If a sinus impulse reaches the AV-node and ventricles during an ectopic beat or VT beat it produces a fusion complex, which is a strong indicator for VT.

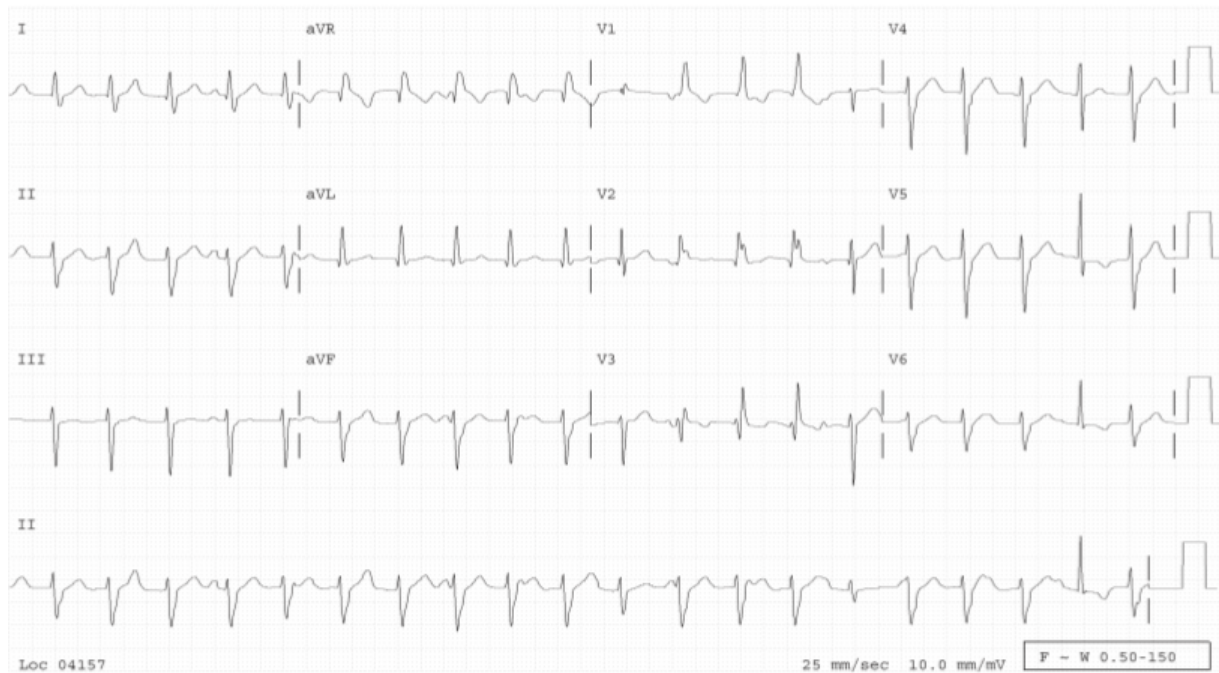

Illustration 2: ECG of patient with VT. Showing AV dissociation, some P waves fall within or before the T waves. Lead II also shows fusion complexes.(1)

QRS complex duration

The duration of the QRS complex may be of importance, a QRS complex duration of more than 140 milliseconds are more frequent in VT. A QRS complex of more than 160 milliseconds can be present in an SVT with preexisting BBB. Certain drugs may also slow the conduction in the ventricles, prolonging the QRS complex, mainly class Ia and Ic antiarrhythmic drugs and amiodarone.(10) The duration of the QRS complex also gives a clue to the origin of the arrhythmia, if the origin is close to the interventricular septum it leads to more simultaneous contraction of the ventricles and a shorter duration and if the origin is further from the septum it leads to a sequential activation of the ventricles and a longer duration of the QRS complex.(11)

QRS concordance

When all the QRS complexes in the precordial leads are either positive or negative it is called positive or negative concordance. Concordance is rarely seen in SVT and therefore strongly favors the diagnosis of VT. Negative concordance, when the QRS complexes in the precordial leads

are predominantly negative, is diagnostic for VT that is originating in the anterior apical part of the left ventricle. Whereas positive concordance, when the QRS complexes are predominantly positive in the precordial leads, is most often occurring in VT originating from the basal posterior part of the left ventricle or during an arrhythmia with a left posterior accessory pathway.(1)

QRS morphology

In wide QRS complex tachycardia with right bundle branch block (RBBB) morphology one can distinguish differences in leads V1 and V6. The presence of a qR or R complex in lead V1 points towards a ventricular origin, whereas a three phasic, RSR, pattern points to SVT. In lead V6 when the R:S ratio is <1 suggests VT.(9)

In left bundle branch block (LBBB) morphology if lead V1 shows a positive QRS deflection of over 30 milliseconds and a notching of the S wave it is suggestive of VT. A qR pattern in lead V6 also favors the diagnosis of VT. In SVT lead V1 shows a small r wave and a rapid sloping of the S wave.(12) A rapid change in morphology of the QRS complexes is suggestive for VT.

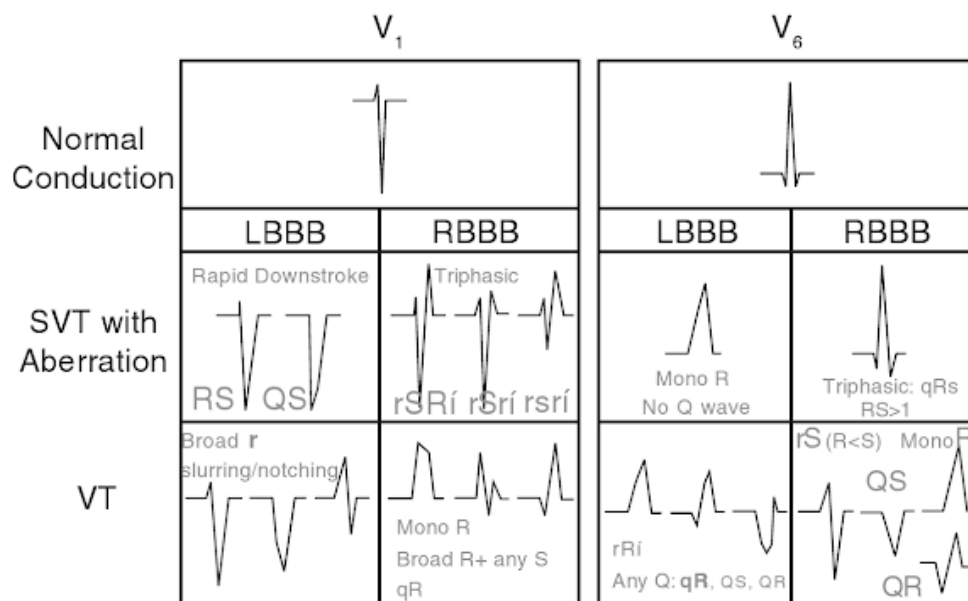


Illustration 3: QRS complex morphology in wide QRS tachycardia.(7)

QRS axis

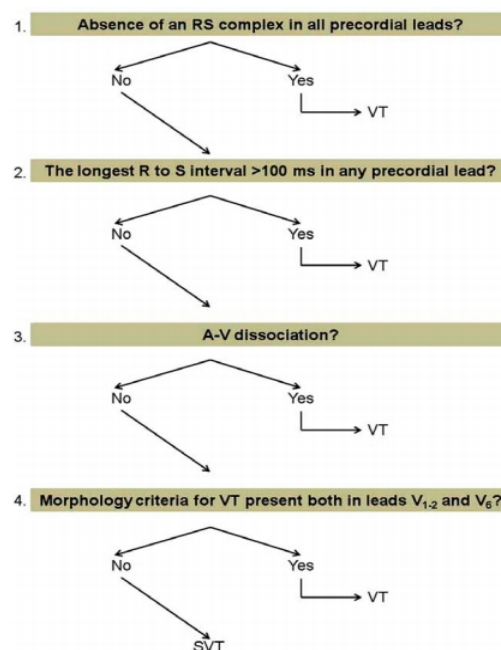
When the mean QRS axis is in the normal range it is suggestive for SVT, where a left deviation or right deviation of the axis points towards VT.(4) The axis can also help in determining the site of origin, a VT with its origin in the apical part in the ventricles has a superior axis and a VT that originates in the basal part has an inferior axis.(11)

Algorithms

There has been several criteria and algorithms researched and constructed to aid the physician in the diagnosis of wide QRS complex tachycardia. Some of the most commonly used ones are the Brugada algorithm, aVR algorithm, Griffith algorithm and lead II R-wave peak time criterion.

Brugada algorithm

Brugada et al. Formed an algorithm in 1991 in the form of a decision tree in 4 steps. The Brugada algorithm is the most known and most used algorithm in differentiating VT from SVT. In the first step the precordial leads are analysed for the absence of an RS complex, which indicates VT with a sensitivity of 21% and specificity of 100% for VT. Next step is when there is an RS complex present in one or several precordial leads and the R-S interval is measured, if it is longer than 100 milliseconds it indicates VT with a sensitivity of 66% and specificity of 98% for VT. The next step is to look for AV dissociation and if it is present it indicates the diagnosis of VT with a sensitivity of 21% and specificity of 100%. In the last step the morphology is analysed in leads V1-2 and V6.(13)



*Illustration 4: The brugada algorithm. Explained in the text.
(10)*

aVR algorithm

In the aVR algorithm published by Vereckei et al. only the aVR lead is analysed in a decision tree style. In the first step for the presence of an initial R wave, which would indicate VT. In the next step is the presence of an initial q or r wave which is wider than 40 milliseconds, which would indicate VT. The third step is to look for the presence of notching on the descending limb and a predominantly negative QRS complex, which would indicate VT. The next step is to see if the ratio between V_i and V_t is smaller than 1, it is diagnostic for VT.(10)

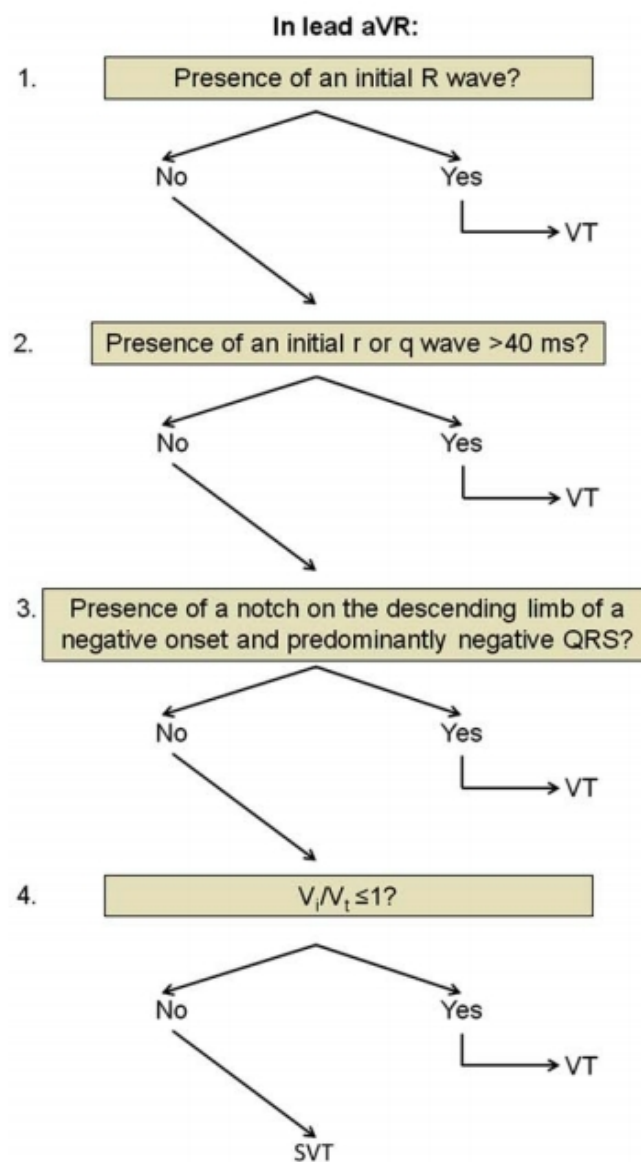


Illustration 5: Vereckei's aVR algorithm. Explained in the text.(10)

Griffith algorithm

The Griffith algorithm focuses on SVT instead of VT, where the ECG is analysed for signs consistent with SVT with VT as a diagnosis of exclusion. It analyses the QRS morphology in leads V1 and V6, first it is determined if there is a RBBB or LBBB type complexes, for RBBB type it is analysed if there is an rSR morphology in V1, if there is an RS complex in V6 and if the R/S ratio in V6 is >1 . For LBBB it is analysed if there is an rS or QS complex in V1, if the time to S nadir is <70 ms in V1 and if there is absence of a Q wave in V6. If all criteria is negative the diagnosis is VT. Because the algorithm defaults to the diagnosis of VT its sensitivity is high but the specificity is lower.(14)

Lead II R-wave peak time criterion

Lead II R-wave peak time (RWPT) was published by Pava et al. and it focuses on a single lead without regard to morphology. It is to analyse the time interval from the onset of QRS to the first change in polarity in lead II, if it is 50 milliseconds or more it indicates VT. It is reported to have a sensitivity of 93.2% and a specificity of 99.3%.(10)

Criteria comparison

In 2012 Marek Jastrzebski et al. published an article where they made a comparison between the most common algorithms used to diagnose wide QRS complex tachycardias to see the different sensitivities, specificities and diagnostic accuracy. They analysed retrospectively 260 wide QRS complex tachycardias from 204 patients. It was the first independent head-to-head comparison of several different ECG diagnostic criteria. They found the different criteria to have very similar accuracy (77.5% - 68.8%), but there were differences in the specificity and sensitivity amongst the algorithms. The algorithm with the highest specificity was Lead II RWPT with 82.7% and the lowest was Griffith with 39.8%. As for sensitivity the highest was Griffith with 94.2% and the lowest was Lead II RWPT with 0.60%. They concluded that there is no one algorithm that can be recommended. It is more useful for the physician to use the algorithm they know and are comfortable with.(15)

Treatment

Initially hemodynamic status of the patient must be assessed, if the patient is hemodynamically unstable (hypotension, angina, chest discomfort, lightheadedness) synchronised cardioversion should be performed immediately, VT is in many cases converted with 50 joule, and energy up to 200 joule will convert 72% of patients with SVT.(16) Unconscious and pulseless patients are managed with advanced cardiac life support. If the patient is hemodynamically stable the ECG may be studied in more detail and attempt to treat the arrhythmia pharmacologically.

In an unstable patient with regular VT or pre-excited tachycardia synchronised cardioversion is the first line treatment, if the VT is pulseless and recurrent or shock resistant the patient is given amiodarone in a 300 mg IV bolus with an additional 150 mg bolus if needed and a continuous infusion of 1 mg per minute for 6 hours and then 0.5 mg per minute for 18 hours. If the VT is with a pulse the dosing of amiodarone is 150 mg for the initial bolus and 150 mg for the second followed by the same infusion. As an alternative to amiodarone lidocaine can be used and it is dosed at 1-1.5 mg per kilo IV with supplemental doses of 0.5-0.75 mg per kilo in the case of pulseless VT, if the VT is with pulse the dose of lidocaine is 0.5-0.75 mg per kilo.(17)

In the stable patient with regular VT or pre-excited tachycardia the first line drug is procainamide which not only is very effective in terminating the VT but also blocks possible accessory pathways in pre-excited tachycardia. ECG and blood pressure monitoring is required during procainamide infusion the recommended dosing is an infusion of 20 mg per minute until the max dose 17 mg per kilo or until the arrhythmia is terminated or the patient experience hypotension, QRS prolongation, acceleration of the tachycardia. Amiodarone can also be used in the stable patient in the dose of 150 mg over 15 minutes followed by an infusion of 1 mg per minute over 6 hours. Lidocaine is less effective but can also be given in a stable patient as an IV bolus of 0.5-1.5 mg per kilo over 2 minutes followed by an infusion of 1-4 mg per minute to a max dose of 3 mg per kilo.(18)

Many guidelines recommend amiodarone in a bolus dose as first line treatment for a pharmacologic termination of hemodynamically stable VT, however a study made at the John Radcliffe Hospital between 2003 and 2006 of 41 patients with hemodynamically stable VT showed that amiodarone in bolus doses was relatively ineffective, terminating the VT in less than 20% of patients within 20 minutes and 29% of patients within 1 hour and because of its inherent risks for hemodynamic deterioration 17% of patients required electrical cardioversion.(19)

In a study from 2015 compared intravenous procainamide and amiodarone to determine the

efficacy and safety in stable wide QRS complex tachycardia, 62 patients were randomly assigned the drugs. Within 40 mins 3 out of 33 patients given procainamide and 12 out of 29 patients given amiodarone reached the predetermined end point due to adverse effects, the tachycardia was terminated within 40 minutes in 22 of the procainamide patients and in 11 of the amiodarone patients and within 24 hours adverse effects occurred in 18% of the patients given procainamide and in 38% in the patients given amiodarone. Showing that procainamide is associated with less cardiac adverse effects and higher proportion of arrhythmia termination.(20)

In patients with SVT with aberrant conduction it is as well important to assess the hemodynamic stability, in unstable patients electrical cardioversion is the first line therapy. SVTs may be terminated with vagal maneuvers (carotid massage or valsalva) otherwise the drug of choice is adenosine, an AV nodal blocker, at an initial bolus dose of 6 mg followed by 12 mg and if there is no effect after a few minutes another bolus of 12 mg can be given, caution should be taken to make sure that the arrhythmia is not caused by pre-excitation since AV nodal blockers may induce VT or VF. If adenosine is unsuccessful diltiazem, a calcium channel blocker, can be given as a bolus of 0.25 mg per kilo over 2 minutes with additional boluses of 0.35 mg per kilo in 15 minute increments if needed. If the heart rate is controlled by the bolus it can be maintained with an infusion of 5-15 mg per hour or with oral diltiazem. An alternative to calcium channel blocking agents are beta-adrenergic blocking agents, commonly used are metoprolol and atenolol. Metoprolol is given in a 5 mg slow IV push which can be repeated every 5 minutes to a maximum of 15 mg. Atenolol is given 5 mg IV over 5 minutes with a second dose after 10 minutes of 5 mg over 5 minutes if the initial dose was well tolerated. In calcium channel- and beta adrenergic blocking agents it is important to have cardiovascular monitoring since they may induce bradycardia, hypotension and pulmonary edema.(18,21)

In patients with irregular VT it is important to be prepared for aggressive resuscitation since they have a tendency to progress into VF, in hemodynamically unstable patients with irregular VT the first line treatment is electrical cardioversion, in stable patients the QT interval should be evaluated to distinguish between torsades de pointes and polymorphic VT with normal QT interval. Myocardial ischemia is the most common etiology of polymorphic VT with normal QT interval and it is treated with beta-blockers, amiodarone and early cardiac catheterization.(8) Patients with polymorphic VT with long QT interval should have their electrolytes rapidly investigated and given magnesium sulfate in a 2 g bolus dose which can be repeated if necessary, lidocaine can also be given as a bolus of 1-1.5 mg per kilo over 2 minutes with additional doses of 0.5-0.75 mg per kilo every 5-10 minutes to a max dose of 3 mg per kilo if necessary, amiodarone should be avoided in torsades de pointes since it may prolong the QT interval and worsen the condition.(18)

Implantable cardioverter defibrillator

Implantable cardioverter defibrillator (ICD) is a device capable of detecting ventricular tachyarrhythmias and terminate them through defibrillation. ICDs has been used in clinical practice for more than 30 years, originally it was implanted via thoracotomy and leads were connected to the ventricles which occasionally still is the case but a vast majority of the ICDs used today have transvenous leads implanted predominantly in the right heart. In the case of problems accessing the heart through the vascular system there is an ICD that can be placed subcutaneously outside the thoracic cavity with electrodes placed at the left parasternal border and over the fifth intercostal space.(21) According to the American College of Cardiology Foundation guidelines ICD is used as management in most patients with hemodynamically unstable VT, prior MI and hemodynamically stable sustained VT, unexplained syncope where an arrhythmia is presumed and most patients with genetic sudden death syndromes whit unexplained syncope.(22) Three studies that compared ICD and antiarrhythmic drug therapy, the Antiarrhythmics Versus Implantable Defibrillators (AVID), the Canadian Implantable Defibrillator Study (CIDS) and the Cardiac Arrest Study Hamburg (CASH), showed better survival with ICD therapy than antiarrhythmic therapy. A meta analysis of the three studies demonstrated a 50% reduction in arrhythmic mortality and a 28% reduction in total mortality.(23) ICD is not indicated in patients with VT occurring during an acute STEMI, patients with reversible drug induced VT or patients with low expected survival because of co-morbidities. ICDs are commonly used in conjunction with antiarrhythmic drugs or with catheter ablation to reduce the need for ICD shocks.

Wearable cardioverter defibrillator

The wearable cardioverter defibrillator (WCD) is a device in form of a vest worn over the chest with a monitor carried in a holster on the waist, it is worn under the clothes and contains four non adhesive electrodes giving a continuous 2 lead ECG reading which is recorded and analysed in the monitor unit, in the vest is also three defibrillator electrodes in the configuration of 1 anterior and 2 posterior for defibrillation. The monitor unit detects arrhythmias using several parameters, such as heart rate, dual lead comparison, rhythm stability analysis and arrhythmia duration, shock delay and thresholds can be tailored by the treating physician individually for the patient. When a treatable arrhythmia is detected an alarm alerts the patient who then has the ability to abort or delay the shock in case consciousness is not impaired. The shock delivered is up to five sequential

biphasic shocks programmable between 75 – 150 joules, the unit attempts to synchronise the shocks with the R wave but if it is not possible after 3 seconds an unsynchronised shock is delivered.(24)

In current guidelines the WCD is recommended for patients with poor left ventricular function who are at risk for sudden arrhythmic death but are not candidates for an ICD (peripartum cardiomyopathy, active myocarditis, arrhythmia in early post MI phase)(21) it should also be considered for patients where the risk of ventricular arrhythmia is temporary or when it can be used as a bridge to more definite treatment. A study of patients with left ventricle dysfunction after an MI, the Defibrillator in Acute Myocardial Infarction Trial (DINAMIT) followed patients 6 to 40 days after an MI with reduced LVEF $\leq 35\%$ failed to show an improvement in mortality using ICD, it showed a reduction in deaths caused by ventricular arrhythmia but an increase in non sudden cardiac death. The Vest Prevention of Early Sudden Death Trial (VEST) was a multicenter randomised trial to investigate if the WCD reduces the ventricular arrhythmia death in the first 90 days after an MI with LVEF $\leq 35\%$, there was no difference in death due to ventricular arrhythmia but it showed a decrease in total mortality. There are not many true contraindications for WCD, implanted pacemakers can produce artifacts that leads to inappropriate shock delivery, since the WCD gives a warning before shocking with sound and light so the patient can abort the shock, caution should be used in patients with depressed visual or audio senses or patients that can not themselves use the abort button due to motor or cognitive impairment, and WCD should not be used in patients that are pregnant.(24)

A study was made between 2012 and 2016 to investigate the quality of life in 109 patients treated with WCD, with a questionnaire they reported that mobility was severely reduced in 2% and mildly in 30% of the patients, self care was reduced severely in 1% of patients and mildly in 16%, problems in managing daily routine activities were diminished severely in 1% and mildly in 24%, severe pain was found in 5% of patients and mild pain in 31%, 43% of the patients reported having mild mental health issues (anxiety, depression). 29% of patients reported being afraid of receiving shocks and only 64% felt adequately protected by the WCD.(25)

Catheter ablation

Ablative therapy is based on that the arrhythmia arise from a focal origin and if that focal region is destroyed the arrhythmia will no longer occur spontaneously. An invasive electrophysiological (EP) study is made to give a precise diagnosis and locate the focal origin of the arrhythmia. An invasive EP study is made by placement of multielectrode catheters in the atria, ventricles or coronary sinus, then the arrhythmia is provoked pharmacologically or electrical

stimulation and the area is mapped to locate the origin of the arrhythmia. Radiofrequency is the most commonly used energy source for ablation, cryoablation is used as an alternative to minimize injury to the AV node.(26) RF energy produces a small necrotic lesion by heating the tissue. Indications for catheter ablation therapy includes symptomatic SVT due to AV nodal reentrant tachycardia, WPW, VT from previous MI, idiopathic monomorphic VT that is resistant to drug therapy or as adjunctive therapy in patients with ICD. VT is a major cause for mortality and morbidity in patients with structural heart disease and ICDs have been shown to reduce sudden death due to arrhythmias but they do not prevent recurrent arrhythmias. With advancement in the technology of catheter ablation it has become an increasingly used adjunctive treatment for patients with VT, patients still tend to be referred to ablation late in their disease course although studies have shown that early referral has been associated with improved long term VT suppression, abolishing ES and preventing ICD shock administration.(27)

Extracorporeal membrane oxygenation

Venoarterial extracorporeal membrane oxygenation (VA-ECMO) can be used as a treatment or a bridge to treatment in patients with VT and electrical storm (ES). ES is a life threatening condition which is defined as three or more episodes of VT, VF or ICD shocks in a 24 hour period, the pathophysiology of ES is not fully understood and it has an incidence of 10-20% in patients with ICD and may also affect patients with dilated cardiomyopathy and other structural heart diseases. Traditional treatment of ES is based on trigger approach, antiarrhythmic drugs, sedation and catheter ablation, a newer option to consider is ECMO, in many cases the treatment of choice is catheter ablation however often the patients hemodynamic instability does not allow it and in this sense ECMO can act as a bridge to therapy or as circulatory support during the EPS, ECMO can also be used in order to optimise antiarrhythmic treatment by ensuring tissue perfusion, it can reduce myocardial oxygen consumption and increase coronary perfusion to decrease heart cell irritability in arrhythmias, ECMO can as well allow for a safe transfer of the patient to a better equipped hospital. The benefits of ECMO must be weighed against the risks which can be hemorrhagic complications, thrombosis, embolism, infections amongst other.(28)

Acknowledgment

I would like to thank my mentor MD, PhD, Assistant Professor Matias Trbušić for taking time out of his busy schedule to aid me with this paper.

I would also like to thank all my family and friends that have supported me throughout my studies.

References

1. Garmel GM. Wide Complex Tachycardias: Understanding this Complex Condition: Part 1 - Epidemiology and Electrophysiology. *West J Emerg Med*. 2008;9(1):28–39.
2. Stewart RB, Bardy GH, Greene HL. Wide Complex Tachycardia: Misdiagnosis and Outcome After Emergent Therapy. *Ann Intern Med*. 1986 Jun 1;104(6):766.
3. Gupta AK, Thakur RK. Wide QRS Complex Tachycardias. *Med Clin North Am*. 2001 Mar 1;85(2):245–66.
4. Akhtar M, Shenasa M, Jazayeri M, Caceres J, Tchou PJ. Wide QRS complex tachycardia. Reappraisal of a common clinical problem. *Ann Intern Med*. 1988 Dec 1;109(11):905–12.
5. Waldo AL, Akhtar M, Brugada P, Ward DE. The Minimally Appropriate Electrophysiologic Study for the Initial Assessment of Patients With Documented Sustained Monomorphic Ventricular Tachycardia*. Vol. 6, *Journal of the American College of Cardiology*. 1985.
6. Atunes E, Brugada J, Steurer G, Andries E, Brugada P. The Differential Diagnosis of a Regular Tachycardia with a Wide QRS Complex on the 12-Lead ECG: Ventricular Tachycardia, Supraventricular Tachycardia with Aberrant Intraventricular Conduction, and Supraventricular Tachycardia with Anterograde Conduction O. *Pacing Clin Electrophysiol*. 1994 Sep 1;17(9):1515–24.
7. Griffin BP, Kapadia SR, Rimmerman CM. The Cleveland Clinic cardiology board review. Wolters Kluwer/Lippincott Williams & Wilkins Health; 2013.
8. Zipes DP, Camm AJ, Borggrefe M, Buxton AE, Chaitman B, Fromer M, et al. ACC/AHA/ESC 2006 Guidelines for Management of Patients With Ventricular Arrhythmias and the Prevention of Sudden Cardiac Death. *J Am Coll Cardiol*. 2006 Sep 5;48(5):e247–346.
9. Wellens HJJ, Bär FWHM, Lie KI. The value of the electrocardiogram in the differential diagnosis of a tachycardia with a widened QRS complex. *Am J Med*. 1978 Jan 1;64(1):27–33.
10. Vereckei A. Current algorithms for the diagnosis of wide QRS complex tachycardias. *Curr Cardiol Rev*. 2014;10(3):262–76.
11. Wellens HJ. Electrophysiology: Ventricular tachycardia: diagnosis of broad QRS complex tachycardia. *Heart*. 2001 Nov 1;86(5):579–85.
12. Sousa PA, Pereira S, Candeias R, De Jesus I. The value of electrocardiography for differential diagnosis in wide QRS complex tachycardia. *Rev Port Cardiol*. 2014;33(3):165–73.
13. Brugada P, Brugada J, Mont L, Smeets J, Andries EW. A new approach to the differential diagnosis of a regular tachycardia with a wide QRS complex. *Circulation*. 1991;83(5):1649–59.
14. Garner JB, Miller JM. Wide Complex Tachycardia – Ventricular Tachycardia or Not Ventricular Tachycardia, That Remains the Question. *Arrhythmia Electrophysiol Rev*. 2013;2(1):23.
15. Jastrzebski M, Kukla P, Czarnecka D, Kawecka-Jaszcz K. Comparison of five electrocardiographic methods for differentiation of wide QRS-complex tachycardias. *Europace*. 2012;14(8):1165–71.
16. Lown B. Electrical reversion of cardiac arrhythmias. *Br Heart J*. 1967 Jul;29(4):469.
17. Baltazar RF. Basic and bedside electrocardiography. Wolters Kluwer Health/Lippincott Williams & Wilkins; 2009.
18. Raj Subramanian AN, Brady WJ, Herman LK, Marill KA, Professor A, Mattu A, et al. Wide Complex Tachycardia: Diagnosis And Management In The Emergency Department Editor-in-Chief Associate Editor Editorial Board International Editors. 2008.

19. Tomlinson DR, Cherian P, Betts TR, Bashir Y. Intravenous amiodarone for the pharmacological termination of haemodynamically-tolerated sustained ventricular tachycardia: Is bolus dose amiodarone an appropriate first-line treatment? *Emerg Med J*. 2008;25(1):15–8.
20. Ortiz M, Martin A, Arribas F, Coll-Vinent B, Del Arco C, Peinado R, et al. Randomized comparison of intravenous procainamide vs. intravenous amiodarone for the acute treatment of tolerated wide QRS tachycardia: The PROCAMIO study. *Eur Heart J*. 2017;38(17):1329–35.
21. Priori SG, Blomström-Lundqvist C, Mazzanti A, Blom N, Borggrefe M, Camm J, et al. 2015 ESC Guidelines for the management of patients with ventricular arrhythmias and the prevention of sudden cardiac death. *Eur Heart J*. 2015 Nov 1;36(41):2793–867.
22. Russo AM, Stainback RF, Bailey SR, Epstein AE, Heidenreich PA, Jessup M, et al. ACCF/HRS/AHA/ASE/HFSA/SCAI/SCCT/SCMR 2013 Appropriate Use Criteria for Implantable Cardioverter-Defibrillators and Cardiac Resynchronization Therapy: A Report of the American College of Cardiology Foundation Appropriate Use Criteria Task Force, Heart Rhyt. *J Am Coll Cardiol*. 2013 Mar 26;61(12):1318–68.
23. Connolly S. Meta-analysis of the implantable cardioverter defibrillator secondary prevention trials. *Eur Heart J*. 2000 Dec 15;21(24):2071–8.
24. Sandhu U, Rajyaguru C, Cheung CC, Morin DP, Lee BK. The wearable cardioverter-defibrillator vest: Indications and ongoing questions. *Prog Cardiovasc Dis*. 2019 May;62(3):256–64.
25. Lackermair K, Schuhmann CG, Kubieniec M, Riesinger LM, Klier I, Stocker TJ, et al. Impairment of Quality of Life among Patients with Wearable Cardioverter Defibrillator Therapy (LifeVest®): A Preliminary Study. *Biomed Res Int*. 2018;2018:1–6.
26. Caldwell MA, Calkins H, Conti JB, Deal BJ, Mark NA, Iii E, et al. 2015 ACC/AHA/HRS guideline for the management of adult patients with supraventricular tachycardia. *Hear Rhythm*. 2016;13:136–221.
27. Liang JJ, Santangeli P, Callans DJ. Long-term Outcomes of Ventricular Tachycardia Ablation in Different Types of Structural Heart Disease Diagnostic Electrophysiology & Ablation. *Diagnostic Electrophysiol Ablation*. 2015;177–83.
28. Uribarri A, Bravo L, Jimenez-Candil J, Martin-Moreiras J, Villacorta E, Sanchez PL. Percutaneous extracorporeal membrane oxygenation in electrical storm: five case reports addressing efficacy, transferring allowance or radiofrequency ablation support. *Eur Hear journal Acute Cardiovasc care*. 2018;7(5):484–9.

Illustration 1: Garmel GM. Wide Complex Tachycardias: Understanding this Complex Condition: Part 1 - Epidemiology and Electrophysiology. *West J Emerg Med*. 2008;9(1):28–39.

Illustration 2: Garmel GM. Wide Complex Tachycardias: Understanding this Complex Condition: Part 1 - Epidemiology and Electrophysiology. *West J Emerg Med*. 2008;9(1):28–39.

Illustration 3: Griffin BP, Kapadia SR, Rimmerman CM. The Cleveland Clinic cardiology board review. Wolters Kluwer/Lippincott Williams & Wilkins Health; 2013.

Illustration 4: Verecke A. Current algorithms for the diagnosis of wide QRS complex tachycardias. *Curr Cardiol Rev*. 2014;10(3):262–76.

Illustration 5: Verecke A. Current algorithms for the diagnosis of wide QRS complex tachycardias. *Curr Cardiol Rev*. 2014;10(3):262–76.

Biography

Tobias Stridbeck is a medical student currently studying in the 6th year at Zagreb Medical University. Born and raised in Knivsta, a small town outside of Uppsala in Sweden. Before going in to medical school he studied nursing at the University of Karlstad, and in the time between graduating high school and starting to study medicine he was working with assisting people at Arlanda Airport outside of Stockholm and traveled. Traveling has always been a passion, along with numerous shorter travels there has been two long travels, one to Southeast Asia and one to South America both 7 months long. Tobias also loves sailing and other outdoor activities and has recently taken up golf as a new hobby.

In the future Tobias plans to specialise in Family Medicine, he found that calling after doing his clinical rotation in a primary care centre in Sigtuna, Sweden.