

Problems in surgical treatment of pediatric vessel injuries

Flockenhaus, Lea Catharina

Master's thesis / Diplomski rad

2021

Degree Grantor / Ustanova koja je dodijelila akademski / stručni stupanj: **University of Zagreb, School of Medicine / Sveučilište u Zagrebu, Medicinski fakultet**

Permanent link / Trajna poveznica: <https://um.nsk.hr/um:nbn:hr:105:536063>

Rights / Prava: [In copyright](#) / [Zaštićeno autorskim pravom.](#)

Download date / Datum preuzimanja: **2025-02-07**



Repository / Repozitorij:

[Dr Med - University of Zagreb School of Medicine Digital Repository](#)



**UNIVERSITY OF ZAGREB
SCHOOL OF MEDICINE**

Lea Catharina Flockenhaus

**Problems in Surgical Treatment of Pediatric
Vessel Injuries**

GRADUATE THESIS



Zagreb, 2021

This graduate thesis was made at the Department of Surgery, Clinical Hospital Center Zagreb, under the mentoring role of doc.dr.sc. Tomislav Meštrović, MD, PhD. Thesis paper "Problems in Surgical Treatment of Pediatric Vessel Injuries" was submitted for evaluation in the academic year 2020/2021.

Abbreviations

ABI – ankle brachial index

AVF – arteriovenous fistula

CA – conventional angiography

CPB – cardiopulmonary bypass

CT – computed tomography

CTA – computed tomography angiography

ECG – electrocardiography

ECMO – extracorporeal membrane oxygenation

FFP – fresh frozen plasma

GSV – greater saphenous vein

ICU – intensive care unit

IV – intravenous

MESS – Mangled Extremity Severity Score

MRI – magnetic resonance imaging

PDS – polydioxanone

PPH – pink pulseless hand

PSA – pseudoaneurysm

PTFE – polytetrafluoroethylene

rFVIIa – recombinant activated factor VII

SAE – serious adverse events

TEVG – tissue engineered vascular graft

Uclips – atraumatic vascular clips

US – ultrasound

Content

Summary

Sažetak

1	Introduction	1
2	Differences to adult patients.....	2
2.1	Anatomical differences	2
2.2	Physiological differences	2
3	Etiology	3
3.1	Iatrogenic.....	3
3.2	Non-iatrogenic	4
3.2.1	Warzone	5
3.2.2	Violence	7
3.2.3	Falls	7
4	Complications	8
4.1	Hemorrhage.....	8
4.2	Arteriovenous fistula	11
4.3	Pseudoaneurysm.....	13
4.4	Vascular occlusion.....	18
4.4.1	Thrombosis	18
4.4.2	Vasospasm.....	19

4.4.3	Acute arterial ischemia.....	21
4.4.4	Chronic arterial ischemia	22
4.5	Compartment syndrome	22
4.6	Amputation	23
4.7	Pink pulseless hand.....	24
5	Follow-up	25
6	Prevention.....	26
7	Limitations.....	28
7.1	Multidisciplinary approach	28
7.2	Graft types.....	29
7.3	Endovascular treatment options	29
7.4	Long-term follow-up.....	30
8	Outlook.....	30
8.1	Database enhancement	30
8.2	Endovascular approaches	31
8.3	Establishment of universal algorithms	31
8.4	Tissue engineered vascular grafts.....	31
9	Acknowledgement.....	33
10	References.....	34

11 Biography..... 39

Summary

Title: Problems in Surgical Treatment of Pediatric Vessel Injuries

Author: Lea Catharina Flockenhaus

Pediatric vessel injuries are rare and associated with high mortality and morbidity. This is owed to the distinct anatomical and physiological features in children, which are significantly different from those in adults. Their smaller, spastic and more fragile vessels predispose to vascular occlusion and cause a lower injury threshold. Due to the tendency of children's vessels to go into vasospasm upon trauma, the severity of injury might get concealed and lead to non-recognition. Furthermore, despite possessing a larger neoangiogenic potential, which accounts for the good tissue viability seen in pediatric patients following reconstructions, children are more sensitive to chronic ischemia, since it can give rise to limb-length discrepancies as the child grows. There are several complications that could arise from vessel injuries in children, ranging from arteriovenous fistulas, pseudoaneurysms, vessel occlusions, to compartment syndrome and limb loss. The diagnosis and treatment of each of these complications, depend on the mechanism, location and severity of injury, as well as other factors, i.e. the age of the patient. The fast and efficient management of pediatric vessel injuries is further complicated by the lack of training and experience of surgeons regarding these specific cases. One of the main areas of interest for research in the field of pediatric vascular surgery, is the development of tissue-engineered vascular grafts that are able to grow with the child and circumvent the downsides connected to autologous and synthetic grafts.

Key words: pediatric vessel injuries, iatrogenic, endovascular procedures, vascular grafts.

Sažetak

Naslov: Problemi u kirurškom liječenju ozljeda krvnih žila u djece

Autor: Lea Catharina Flockenhaus

Ozljede krvnih žila su rijetke u djece i imaju veliki mortalitet i morbiditet. Tome doprinose anatomska i fiziološka obilježja djece, koja su značajno različita od onih u odraslih osoba. Manje, spastične i krhke žile u djece povećavaju sklonost okluziji krvnih žila i snizuju prag tolerancije na ozljede. Zbog sklonosti dječjih krvnih žila vazospazmu nakon traume, težina krvožilne ozljede može biti prikrivena, što dovodi do izostanka njenog prepoznavanja. Nadalje, unatoč tome što djeca posjeduju veći neoangiogeni potencijal, što objašnjava dobru održivost tkiva viđenu u dječjih bolesnika nakon rekonstrukcije, ona su osjetljivija na kroničnu ishemiju, koja može dovesti do odstupanja u dužini udova tokom rasta djeteta. Postoji nekoliko komplikacija koje nastaju kao posljedica ozljeda krvnih žila u djece, od arteriovenskih fistula, pseudoaneurizama i okluzija žila, do sindroma mišićnih odjeljaka i gubitka ekstremiteta. Dijagnoza i liječenje svake od ovih komplikacija ovise o mehanizmu, mjestu i težini ozljede, kao i o ostalim čimbenicima, te o dobi pacijenta. Brzo i učinkovito zbrinjavanje ozljeda dječjih žila dodatno je otežano nedostatkom obuke i iskustva kirurga u tim specifičnim slučajevima. Jedno od glavnih područja istraživačkog interesa u području dječje vaskularne kirurgije je razvoj vaskularnih graftova dobivenih tkivnim inženjerstvom (engl. "tissue engineered vascular grafts") koji su sposobni za rast i zaobilaze nedostatke povezane s autolognim i sintetičkim graftovima.

Ključne riječi: ozljede krvnih žila u djece, jatrogene, endovaskularni postupci, vaskularni graftovi.

1 Introduction

In a peacetime environment, the occurrence of pediatric vessel injuries is very rare (Villamaria et al. 2014). Compared to the incidence of 3.5% in warzones (Villamaria et al. 2014), the incidence of vascular injuries in pediatric trauma patients in the rest of the world is below 0.6% (Sidawy & Perler 2018). Most vessel injuries described in the pediatric age group are of iatrogenic etiology, caused by peripheral diagnostic and therapeutic vascular interventions (Sidawy & Perler 2018). Those interventions commonly are related to heart catheterizations, but can also occur during central venous catheter placement, cannulation for extracorporeal membrane oxygenation (ECMO) or cardiopulmonary bypass (CPB), venous or arterial punctures, imaging (Besir et al. 2017), umbilical artery catheterizations or during surgery (Sidawy & Perler 2018). As the survival rate of preterm infants has been increasing (Dzepina et al. 2004), and the use of peripheral interventions becomes more and more frequent (Costa et al. 2016), the incidence of iatrogenic vascular injuries is expected to rise in the future. Non-iatrogenic injuries are the predominant cause of vascular injuries in children older than six years of age (Sidawy & Perler 2018), from which the majority is caused by penetrating mechanisms (Shah et al. 2009) and most commonly affects the upper extremities (Sidawy & Perler 2018).

Despite pediatric vessel injuries being such a rare instance, they carry a high risk of morbidity and mortality (Costa et al. 2016). In the United States, around 13% of vascular injuries in children are fatal, with injuries to certain body regions, such as the chest, having a mortality risk as high as 41% (Sidawy & Perler 2018). Contributing to the high mortality rates are the characteristic features of pediatric vessels, which include their smaller size (Sidawy & Perler 2018), thin and fragile structure, weak surrounding supportive tissue (Besir et al. 2017) and tendency to develop severe

vasospasms with surgical handling (Sidawy & Perler 2018). The aforementioned characteristics do not only pose a technical challenge to management of vascular injuries, but may also obscure their severity (Costa et al. 2016), leading to non-recognition. Another great challenge is the long-term patency of repair in a growing child, which must allow for future axial and radial growth of the vessels (St. Peter & Ostlie 2006; Sidawy & Perler 2018).

2 Differences to adult patients

2.1 Anatomical differences

Complicating the surgical treatment of pediatric vessel injuries, are the much smaller and more fragile vessels than those seen in adults. Due to the smaller size of their vessels, children have a lower injury threshold (Sidawy & Perler 2018). In addition to that, children do not have a preexisting collateral circulation which is commonly present in adult patients, that could bridge the ischemic time until repair of the vascular lesion (Costa et al. 2016). Therefore, diagnosis needs to be established as soon as possible in order to allow appropriate management to take place.

2.2 Physiological differences

There are several physiological differences between children and adults, which play an important role in the presence of vascular injuries. In comparison to adults, children possess good compensatory mechanisms: due to their high neoangiogenic potential (Landau et al. 2003), which includes the ability to rapidly establish an adequate collateral circulation (Besir et al. 2017), children are at a lesser risk of limb loss following vascular insults than adults (Landau et al. 2003). On the other hand, their blood vessels are hyperreactive to manipulation, which presents in the form of

vasospasm (Costa et al. 2016) and could result in prolonged ischemia due to partial or complete vascular occlusion (Sidawy & Perler 2018). Occlusion may as well result from the small intravascular volume (Mommsen et al. 2010; Sidawy & Perler 2018), which increases the risk of developing arterial thrombosis (Sidawy & Perler 2018). Caution must also be exercised in regards to the significant growth rate of children, which may be adversely affected by long ischemic periods (Amaro et al. 2017), potentially causing limb-length discrepancies (Sidawy & Perler 2018).

3 Etiology

3.1 Iatrogenic

One of the most common mechanisms leading to pediatric vessel injuries are iatrogenic interventional procedures, in particular those used for diagnosing congenital heart diseases (Besir et al. 2017). In pediatric patients, cardiac catheterizations carry a risk of up to 16.2% of developing complications, from which vascular lesions form the majority (Amaro et al. 2017). Other iatrogenic causes of vascular injuries in children are invasive imaging, trauma related to surgical procedures, as well as various interventional procedures (Besir et al. 2017), such as ECMO cannulation, which is connected to a high rate of vascular injuries occurring in 20-52% of patients (Sidawy & Perler 2018). In children of five years of age or younger, iatrogenic injuries are the most prevalent cause of vascular trauma (Costa et al. 2016) and according to Mommsen et al., one third of vessel injuries result from iatrogenic causes (Mommsen et al. 2010).

3.2 Non-iatrogenic

Non-iatrogenic injuries, which occur mainly in children over the age of six years (Sidawy & Perler 2018), can further be classified into penetrating, blunt and mixed injuries. According to Shah et al., the age group affected most by penetrating vascular injuries are the 11 to 17-year-olds (Shah et al. 2009). This type of injury is predominantly inflicted by lacerations from glass (Shah et al. 2009), but can also be caused by high-energy penetrating blast mechanisms (Shah et al. 2009), in which the dimension of injury is commonly far more severe than that provoked by other events, i.e. stabbing, gunshot wounds, falls or miscellaneous mechanisms (Villamaria et al. 2014). Tissue destruction in high-energy blast injuries may be so severe as to necessitate extensive soft tissue debridement, bone and joint repair together with vascular reconstructions, sometimes with temporary vascular shunt, and fasciotomies (Sidawy & Perler 2018). Apart from that, in all types of penetrating injuries, it should be a priority to counteract exsanguination first to keep the patient alive and then salvage the limb through repair of the vascular injuries (Sidawy & Perler 2018). Small injuries may be repaired by a primary suture as in adults, whereas patch angioplasty is used in injuries that cannot be managed successfully by simple suturing, such as larger or lateral wall injuries (Sidawy & Perler 2018). Patch angioplasty prevents stenosis, and thereby reduces the likelihood of flow restriction due to a reduced luminal diameter (Lin et al. 2001; Sidawy & Perler 2018). The required patch is typically harvested from the uninjured greater saphenous vein (GSV), which is also the preferred vessel to use as an autologous interposition graft (Lin et al. 2001).

Apart from warfare regions, blunt trauma is the most common mechanism overall of non-iatrogenic vessel injuries in pediatric patients (Sidawy & Perler 2018). Opposite to penetrating trauma, which is more common in the age group of 11 to 17-year-olds, blunt trauma predominantly affects those of 10 years of age and younger

(Shah et al. 2009). Compared to the more localized injuries caused by penetrating trauma, blunt injuries present with more complex wounds caused by shearing and traction forces, which commonly require reconstruction with grafts (Corneille et al. 2011). The graft of choice is usually the reversed saphenous vein, although there are reports on successful use of synthetic grafts as well (Corneille et al. 2011). Nevertheless, synthetic grafts such as polytetrafluoroethylene (PTFE) are connected to a worse outcome overall (Corneille et al. 2011).

Mixed vascular injuries, can be caused by dog bites which in children may present as a combination of penetrating and blunt injuries to the vessels (Sidawy & Perler 2018). These usually necessitate extensive debridement with subsequent reconstruction using interposition grafts (Sidawy & Perler 2018).

3.2.1 Warzone

Much of the knowledge on treatment of pediatric vascular injuries was gained from military experience (Costa et al. 2016). Vascular injuries with an incidence of 12% in wounded adult combatants have been well described, contrary to pediatric civilian casualties (Villamaria et al. 2014). As was mentioned before, the incidence of vascular injuries in pediatric patients in non-combat zones is around 0.3% (Villamaria et al. 2014) to 0.6% (Sidawy & Perler 2018). In their study, Villamaria et al. found the incidence in warzone to be 3.5% (Villamaria et al. 2014). Majority of those vessel injuries were found to be blast-related (58%), followed by gunshot wounds on second place (37.4%), while falls (1.9%) and miscellaneous (2.6%) mechanisms made up the minority (Villamaria et al. 2014). Most commonly the lower extremities (37.8%) were affected, followed by upper extremities (28.1%) and torso (25.4%). Head and neck injuries were the least common, making up 8.6% of all vascular injuries (Villamaria et al. 2014). The most lethal injuries were those sustained to the torso (Villamaria et al.

2014), which carried a mortality rate of up to 41% (Sidawy & Perler 2018). Interestingly in warzones, the incidence of vascular injuries related to the torso-region is twice as high as in the adult population, which is likely owed to the protective armor of the combatants (Villamaria et al. 2014).

In the head and neck region, carotid artery injuries are the ones that were most commonly reported and treated with either primary repair, patch angioplasty, reversed venous interposition graft or PTFE grafts (Villamaria et al. 2014). Vessel injuries of the torso have the highest mortality rates of vascular injuries in children (Villamaria et al. 2014). Due to major vessels located in that region, the risk of death caused by exsanguination is high (Villamaria et al. 2014). There are reports of deaths secondary to uncontrolled hemorrhage from the aorta, inferior vena cava and iliac vessels (Villamaria et al. 2014). Other causes of mortality due to injury to that region, are postoperative complications such as mesenteric ischemia and necrosis following primary aortic and inferior vena cava repair (Villamaria et al. 2014). Furthermore, lethal consequences may as well be brought about by concomitant trauma, such as significant brain injury (Villamaria et al. 2014). For hemorrhage control in torso-related injuries, laparotomies or thoracotomies are used (Villamaria et al. 2014). Lesions of the innominate and pulmonary vessels have been successfully treated with primary repair, whereas transection of the thoracic aorta at the level of the ligamentum arteriosum can be repaired using a prosthetic tube graft (Villamaria et al. 2014). Injuries to the iliac vessels can be treated either primarily or by the means of reversed venous interposition grafts (Villamaria et al. 2014). Limb-threatening vascular injuries to the extremities are commonly controlled initially by tourniquets, temporary intravascular shunts or fasciotomies (Villamaria et al. 2014). Most of these injuries are managed by reconstruction (56.1%) and ligation (42.9%), but might as well be subject to amputation (Villamaria et al. 2014). Primary amputation is used, if a limb cannot be saved due to

severe associated bone and soft tissue injuries or in the case of irreversible limb ischemia (Villamaria et al. 2014). If prior attempts of revascularization were without success and there are no options for further revascularizations, a secondary amputation is indicated in cases of irreversible limb ischemia (Villamaria et al. 2014). Total rate of limb salvage in pediatric patients, that has been reported in warzone setting, is 95% (Villamaria et al. 2014). As in adults, the contralateral GSV is the preferred vessel to harvest for use as an interposition graft (Sidawy & Perler 2018). Particularly in the case of high-blast injuries, which require extensive debridement, GSV should be the graft of choice (Sidawy & Perler 2018).

3.2.2 Violence

Common causes of vascular injuries in children older than five years of age in developing countries are gunshots and stabbings as a cause of penetrating trauma, and falls in the case of blunt trauma, frequently associated with bone and joint injuries (Costa et al. 2016). The predominant mechanism of injury is stabbing, especially to the upper limbs, frequently wounding the ulnar (15.66%), radial (12.04%) and brachial (12.04%) arteries (Costa et al. 2016). Based on bleeding being the main clinical sign, physical examination is usually sufficient for diagnosis (Costa et al. 2016). Arteriography and ultrasound (US) may be used as additional diagnostic methods in case of uncertainty (Costa et al. 2016). These injuries are most commonly managed by vascular exploration, followed by vessel ligation or an end-to-end anastomosis, but an interposition graft is sometimes also used (Costa et al. 2016).

3.2.3 Falls

Non-iatrogenic blunt vascular injuries in children are most commonly caused by supracondylar fractures, resultant from falls onto the outstretched hand (Sidawy &

Perler 2018). Ten percent of all supracondylar fractures present with blunt brachial artery injury, which may be caused by stretching of the artery with resultant intimal disruption or impingement of the artery by hematoma or surrounding tissue (Sidawy & Perler 2018). This might result in acute arterial ischemia or pink pulseless hand (Grant et al. 2018), which may be reversed solely by orthopedic repair, namely fraction reduction and percutaneous pinning (Grant et al. 2018; Sidawy & Perler 2018). If vascular compromise is persistent following orthopedic repair, it is advisable to explore the injury surgically, since delayed repair can potentially lead to compartment syndrome, Volkmann's ischemic contracture, nerve palsy (Grant et al. 2018) or possibly even irreversible ischemia, necessitating amputation (Sidawy & Perler 2018). Depending on the presentation, it can be managed by thrombectomy (Grant et al. 2018) with subsequent arterial repair or venous interposition graft (Grant et al. 2018; Sidawy & Perler 2018).

4 Complications

4.1 Hemorrhage

Depending on its time of presentation, hemorrhage can either be a hard or soft sign of vascular injury (Table 1). A positive bleeding history prior to arrival to the hospital, is a so-called soft sign, whereas persistent bleeding is a hard sign. Other hard signs of vascular injury include active arterial hemorrhage, pulsatile or expanding hematoma, lack of pulse distal to the injury, or other signs of acute distal limb ischemia, palpable thrill or the presence of bruits on auscultation (Hogan et al. 2009; Costa et al. 2016; Sidawy & Perler 2018).

Table 1. Hard and soft signs of vascular injury

Hard signs	Soft signs
Observable active hemorrhage	Bleeding or shock in history at the time of injury (prior to arriving to hospital)
Expanding or pulsating hematoma	Small, non-pulsatile and non-expanding hematoma
Palpable thrill or audible bruit	Penetrating trauma or bone injury in vicinity of major blood vessel
Signs of acute distal ischemia	Ipsilateral sensory or motor function loss

Presence of one of these is sufficient for clinical diagnosis (Hogan et al. 2009) and indicates immediate surgical treatment or an angiography (Figure 1), if there is enough time for diagnostics in a hemodynamically stable patient whose limb is not immediately threatened (Costa et al. 2016). Soft signs include hemorrhage at the time of injury, low blood pressure, hematoma which does not expand nor is pulsatile, ipsilateral sensory or motor function loss, or penetrating trauma or bone injury in proximity to a major blood vessel (Hogan et al. 2009). In the presence of soft signs of vascular injury, it is recommended to assess the ankle brachial index (ABI) (Hogan et al. 2009). In case of an abnormal ABI, further imaging, such as Duplex US, conventional angiography (CA), or a computed tomography angiography (CTA) is indicated (Hogan et al. 2009).

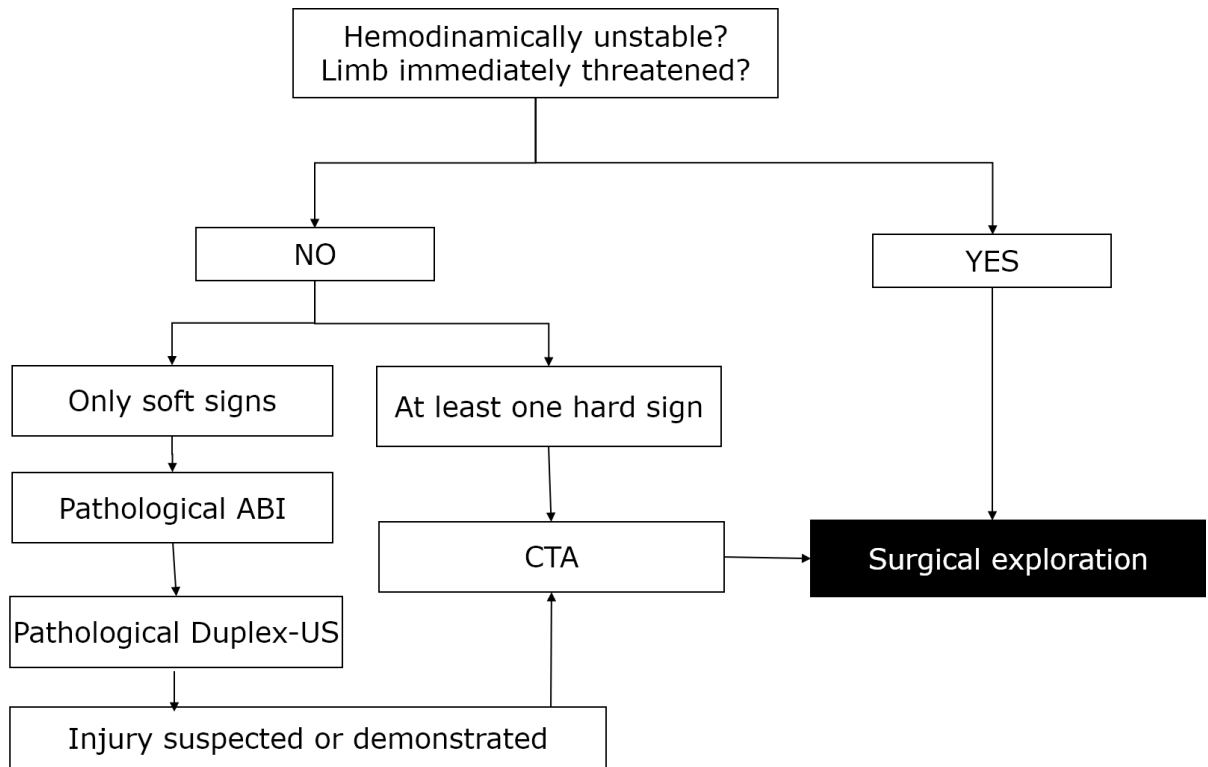


Figure 1. Algorithm for diagnostics and treatment of vascular injuries (ABI – Ankle brachial index, US – ultrasound, CTA – computed tomography angiography).

One extremely rare but dangerous type of massive bleeding is retroperitoneal hemorrhage, with only very few cases reported in the literature (Amaro et al. 2017). Fatalities related to it, are due to the remarkable amount of blood the retroperitoneal space can accommodate, obscuring the urgency of the situation (Amaro et al. 2017). The causative factor to this type of hemorrhage may be injury to the common iliac arteries, which needs to be addressed urgently (Amaro et al. 2017). Angiography can demonstrate bleeding from the common iliac arteries that can sometimes be treated endovascularly, but a surgical exploration is frequently needed (Amaro et al. 2017). On the physical examination, insufficient blood flow to the ipsilateral extremity might present as cyanosis (Amaro et al. 2017). Management includes hematoma evacuation, bleeding control with clamps and vascular reconstruction with reversed autologous vein graft (Amaro et al. 2017). If collateral blood flow is sufficient, the superficial femoral vein may also be harvested (Amaro et al. 2017).

In cases of massive bleeding, it is important to prevent hemorrhagic shock (Grizelj et al. 2006). Multiple intravenous (IV) boluses of recombinant activated factor VII (rFVIIa), with concentrations ranging from 130-222 µg/kg, in conjunction with aminocaproic acid of 100 mg/kg/dose, may be administered (Grizelj et al. 2006). Blood coagulation parameters should be reassessed frequently (Grizelj et al. 2006). In addition to the administration of fluids, platelets, packed red blood cells, fresh frozen plasma (FFP) and cryoprecipitate, it has been shown that rFVIIa is a valuable adjunct to therapy of massive bleeding (Grizelj et al. 2006). Problematic in life-threatening emergencies is the urgent need for available blood products, such as FFP. Without it, the levels of coagulation factors will continue to fall, and hemorrhage will persist (Grizelj et al. 2006). Furthermore, Grizelj et al. stated that substitution of FFP often imposes a volume overload, while not sufficiently replacing coagulation factors (Grizelj et al. 2006). The rFVIIa has been proven helpful in suppressing excessive fibrinolysis, as well as in improving clot structure and stability (Grizelj et al. 2006). By binding to activated platelets, high concentrations of rFVIIa also allow the generation of thrombin in the absence of tissue factor, with the resultant benefit of optimal local coagulation instead of activation of the systemic coagulation system (Grizelj et al. 2006).

4.2 Arteriovenous fistula

Arteriovenous fistula (AVF) with acute limb ischemia occurs in 0.3-2.6% of pediatric patients, following repeated vascular access attempts, such as for venipuncture or cannulation (Dzepina et al. 2004). AVFs may present with dilated superficial veins, limb edema, palpable thrill, audible bruit, nerve compression causing pain or aneurysm formation (Papes et al. 2019). Frequently, patients are without symptoms initially, and become symptomatic only later on (Sidawy & Perler 2018). The presenting symptoms and signs include tachycardia, hyperkinetic precordium,

elevated pulse pressure and distension of the jugular veins (Stern & Klemmer 2011). A few more severe consequences of long-standing AVFs are heart failure (Stern & Klemmer 2011), limb-length discrepancies and ischemic ulcers (Sidawy & Perler 2018). Heart failure may develop as a result of the left-to-right shunt, which increases preload and ultimately leads to hypertrophic cardiomyopathy (Stern & Klemmer 2011), whereas high pressure venous ulcers, ischemic arterial ulcers and limb overgrowth of the affected extremity are based on the high flow associated with AVFs (Sidawy & Perler 2018).

When a diagnosis of AVF is suspected, Doppler may be used to check the arteriovenous patency, dilation or communication and flow rate of the vessel (Costa et al. 2016). If the patient has another coexisting vascular pathology or the location cannot be assessed with Doppler, a computed tomography (CT) or magnetic resonance imaging (MRI) scan may provide more information (Papes et al. 2019). According to Papeš et al., the most precise method of evaluation is subtraction angiography, specifically in the case of multiple, deep intramuscular, residual or recurrent AVFs (Papes et al. 2019). In order to examine for cardiac complications of AVFs, echocardiography, right heart catheterization, electrocardiography (ECG) and shunt-volume calculation may be utilized (Papes et al. 2019). The definite diagnosis of high-pressure venous ulcers is made with a CTA scan or by observing the intraoperative Nicoladoni sign (Stern & Klemmer 2011), which is acute bradycardia caused by compression of the artery proximal to the AVF (Velez-Roa et al. 2004).

The AVF closes spontaneously within six months (Lin et al. 2001) to a year in one third of patients (Papes et al. 2019). If the AVF does not close spontaneously within that time, it needs to be repaired surgically (Lin et al. 2001). In the operating room, the lesion will first be exposed and controlled proximally and distally (Lin et al. 2001). Surgical banding with a circumferential PTFE band (Suding & Wilson 2007),

ligation (Stern & Klemmer 2011; Sidawy & Perler 2018) or coiling (Sidawy & Perler 2018) may then be used to reduce inflow into the fistula. Despite the successful use of coil embolization in a residual intramuscular AVF reported by Young et al. (Young et al. 2015), other authors have advised against coiling, as well as the use of glue for embolization of AVFs, as the small vessels and short fistulas may precipitate coil displacement or glue leakage which could potentially cause larger vessel thrombosis (Papes et al. 2019). Papeš et al. managed AVFs of the upper extremities with resection, followed by an end-to-end anastomosis of the artery and stripping of comitant veins; and femoral AVFs with ligation, lateral arteriorrhaphy and venorrhaphy (Papes et al. 2019). The presence of a residual AVF should then be excluded by palpation, intraoperative Doppler, and postoperative angiography (Papes et al. 2019). In the case of a high-pressure venous ulcer, Young et al. divided the AVF following vessel control, achieved femoral artery repair with patch angioplasty and performed primary repair of the femoral vein (Young et al. 2015).

4.3 Pseudoaneurysm

Pseudoaneurysm (PSA) is a containment of circulating arterial blood within a sac-like cavity, which results from a lesion to the vessel wall with subsequent evolving hematoma, that is supported by the surrounding soft tissues and its fibrous capsule, which formed over time due to scarring of the external surface of the hematoma (Landau et al. 2003; Barkho et al. 2018). The PSAs are most commonly caused by catheterization complications or penetrating injuries (Wollstein et al. 2000), for example as complications of venipuncture (Dzepina et al. 2004), diagnostic or therapeutic catheterization, arterial access punctures or trauma (Landau et al. 2003). Their occurrence is connected to multiple puncture attempts in infants, specifically in the case of low and extremely low birth weight neonates (Dzepina et al. 2004). Less

commonly, they may be congenital, due to infection or inflammation (Guzzetta 1994). Pseudoaneurysms are very rare (Landau et al. 2003; Dzepina et al. 2004), arising in around 0.05% of catheterizations (Landau et al. 2003), making up only 0.03% of neonatal intensive care unit (ICU) admissions (Barkho et al. 2018). In regard to all procedures requiring vascular access, the incidence of pseudoaneurysms varies from 0.88% to 8% (Fraser et al. 2009), which makes them even less common than arteriovenous fistulas and acute limb ischemia following injuries at vascular puncture sites (Dzepina et al. 2004).

They are commonly asymptomatic and discovered only accidentally (Dzepina et al. 2004). When they do cause symptoms, they can present as compressible soft tissue swelling, with or without pain and erythema (Dzepina et al. 2004) or as a pulsatile mass, i.e. in close proximity to the vascular access site (Dzepina et al. 2004). An audible bruit may be present or not (Barkho et al. 2018). Symptoms are usually caused by complications such as vessel rupture, bleeding, thrombosis (Landau et al. 2003), nerve compression or distal embolization, that might result in ischemia, tissue necrosis or growth discrepancies (Landau et al. 2003; Dzepina et al. 2004). Following auscultation for bruit and physical examination for pulsation (Barkho et al. 2018), diagnosis is done with Duplex US (Barkho et al. 2018). In case of a planned reconstruction, it is advisable to do a helical CTA (Hogan et al. 2009) for preoperative evaluation and establishment of a surgical treatment plan. In uncertain cases, a digital subtraction angiography can be useful (Barkho et al. 2018). On Duplex, a PSA typically presents as either an hypoechogenic or anechogenic zone with turbulent flow, in addition to typical “to-and-fro” flow (Dzepina et al. 2004). Diagnosis should be made timely in order to experience best outcome with lesser risk of reintervention (Dzepina et al. 2004).

The treatment of pseudoaneurysms nowadays is more expeditious, compared to the expectant approach pursued in the past (Dzepina et al. 2004). This surgical approach has been proven beneficial, because it reduces complications caused by expectant management, such as thrombosis, ischemia, rupture and massive hemorrhage (Barkho et al. 2018). Surgical management usually includes primary suture repair, excision and end-to-end anastomosis, excision with vein patch, or excision with venous interposition graft (Barkho et al. 2018). In femoral pseudoaneurysm, definite repair of the lesion can be achieved with either interrupted polydioxanone (PDS) or polypropylene suture (Lin et al. 2001).

Less invasive treatment options successful in adults aren't as suitable for children due to the size of the pseudoaneurysms being very large compared to the small size of the vessel, its short neck, as well as possible complications which have been reported in the past (Landau et al. 2003; Dzepina et al. 2004). Nevertheless, according to Barkho et al., there is a trend away from surgical treatment, towards minimally invasive management of these lesions (Barkho et al. 2018).

An example of this is the use of US-guided compression obliteration, which has been reported to be successful in 78-95% of adults (Fraser et al. 2009). The mechanism behind this technique is clotting at the opening through which the native artery and pseudoaneurysm communicate, leading to healing of the defect of the vessel wall (Fraser et al. 2009). Wollstein et al. reported successful duplex compression of a pseudoaneurysm in a six-year-old boy with traumatic 2x3 cm PSA of the posterior tibial artery (Wollstein et al. 2000). For a successful outcome, the site of previous trauma should be fully healed without signs of infection (Wollstein et al. 2000). In this patient, following compression with the probe, the pseudoaneurysm showed no signs of flow and flow in the native artery was maintained (Wollstein et al. 2000). Moreover, Barkho et al. were also able to demonstrate spontaneous resolution in 79%

of their pediatric patients treated with conservative management (Barkho et al. 2018). 18% of those developed complications later on, i.e. skin necrosis due to compression bandage and painless priapism, which resolved without surgical intervention, solely with dressing changes (Barkho et al. 2018). However, there are reports on complications of US-guided compression obliteration: according to a case published by Landau et al., the pseudoaneurysm in a newborn boy began to grow in size following two obliteration attempts (Landau et al. 2003). Later on, the lesion was resected and an end-to-end anastomosis was used to restore arterial patency (Landau et al. 2003). Anastomosis in these cases can be complicated by the poor quality of the vessel edges left, which need to be resected or trimmed to enable a flawless anastomosis (Fraser et al. 2009).

Another example of conservative treatment is percutaneous intracavitary thrombin injection, a method commonly used in adults that causes obliteration of the pseudoaneurysm (Cho et al. 2014). Successful use of this technique has been reported, among others, in a six-months-old infant with a right iliac artery pseudoaneurysm by Cho and colleagues: with the tip of a biopsy needle in position within the lumen, away from the neck of the pseudoaneurysm, diluted heparin (1,000 IU/mL of normal saline) was injected slowly while monitoring the process with a color Doppler (Cho et al. 2014). Using this technique, they achieved complete thrombosis of the lesion, with no signs of residual perfusion (Cho et al. 2014). Nonetheless, complications in infants have been reported as well (Lennox et al. 1998). The most severe complication associated with this procedure is embolization of the feeding artery (Lennox et al. 1998). Using the described technique, while precisely monitoring the needle and ensuring that at all times the tip of the needle is kept away from the neck of the pseudoaneurysm, should make it safe to use (Cho et al. 2014). Lennox et al. and Kang both reported their experience of acute limb ischemia as a consequence

of this type of procedure: following thrombin injection into the center of the pseudoaneurysm of a 10-month-old boy, the hand and forearm became acutely ischemic with loss of distal pulses, caused by thrombosis of the native artery (Lennox et al. 1998). Despite return of pulse but due to persistence of the thrombus, they surgically evacuated the thrombus and hematoma and repaired the artery with direct suturing (Lennox et al. 1998). In another patient, who developed hand ischemia due to a thrombus in the distal brachial artery, heparin anticoagulation resulted in complete disappearance of the clot within three days (Kang 1998). Causes for thrombus formation in the native artery could be either too large volume of injected thrombin or too rapid injection (Kang 1998). This can lead to spillage of the solution. A small diameter of the native vessel in combination with the short neck or the thrombogenic surface of the thrombosed pseudoaneurysm can cause an extension of the thrombus, occluding the small vessel lumen (Kang 1998). Accordingly, it is suggested to begin with a small volume of thrombin solution, to use slow injection, to anticoagulate the patient during and after the procedure and possibly to avoid this type of treatment in very small vessels in order to prevent it, while anticoagulation or selective intraarterial fibrinolysis are management options should this complication occur (Kang 1998).

Whether to treat a pseudoaneurysm in a patient with coagulopathy conservatively or surgically, has to be decided on an individual basis. Surgical management leaves a significant risk of bleeding, whereas conservative treatment has lower success rates and has to be closely followed, possibly for a long period of time (Barkho et al. 2018). Successful conservative treatment has been reported in the study of Barkho et al., in which the pseudoaneurysms resolved successfully under conservative treatment in all patients suffering from hemophilia A (Barkho et al. 2018). Thus, despite coagulopathy actually being a risk factor and predictor of a poorer outcome, conservative management can be successful, provided that anatomic

location needs to be at low risk for trauma and subsequent rupture of the pseudoaneurysm (Barkho et al. 2018).

4.4 Vascular occlusion

Vascular occlusion in vessel trauma can be the result of intimal flaps blocking blood flow, arterial spasm, thrombosis or distal embolism, while catheter-related occlusions can also be caused by large size of the catheter related to the vessel diameter, or fibrin sleeves which can be stripped off angiographic catheters during their removal (Lin et al. 2001).

4.4.1 Thrombosis

Specific settings, that pose an increased risk of arterial thrombotic occlusion following catheterization are polycythemia, poor cardiac function, volume depletion (Lin et al. 2001) or small vessel size (Sidawy & Perler 2018). Treatment of vessel obstruction should be initiated as soon as possible, as the occlusion can lead to downstream ischemic symptoms (Sidawy & Perler 2018). First line treatment is thrombectomy, which can be done with a Fogarty embolectomy catheter (Lin et al. 2001), followed by repair of the underlying vascular lesion. The correct catheter size to choose depends on the diameter of the artery (Lin et al. 2001). For a femoral artery in children, the Fogarty catheter size used is 2-3F (Lin et al. 2001). Following thrombectomy, the artery can be closed primarily using interrupted polypropylene sutures, or by patch angioplasty using a vein graft (Lin et al. 2001). Intimal flaps caused by thrombectomy have been reported, which can be treated by resection of the respective arterial segment, with subsequent anastomosis using interrupted sutures (Lin et al. 2001). In the case of acute thrombosis of the femoral artery, the patient may be treated with unfractionated heparin or low molecular weight heparin for five to seven

days (D'Oria et al. 2020). If the patient presents with a postsurgical bypass thrombosis, bypass can be repeated (Corneille et al. 2011).

A very rare yet dangerous complication is thrombosis of the abdominal aorta (Bogović et al. 2016). In neonates, thrombotic occlusions of the abdominal aorta may be caused by cardiac or umbilical artery catheterization, peripartal asphyxia or trauma, arteritides, dehydration, sepsis, or embolism from congenital heart defects (Bogović et al. 2016). While management options in symptomatic patients range from selective thrombolysis to surgical thrombectomy, observation with anticoagulation may be adequate in case of asymptomatic patients (Bogović et al. 2016). The anticoagulants used are unfractionated or low molecular weight heparin (Bogović et al. 2016). Thrombolysis can be achieved by the use of tissue plasminogen activator (Bogović et al. 2016). Surgical removal of the thrombus is possible through a transperitoneal or retroperitoneal approach (Bogović et al. 2016). An alternative to open surgical thrombectomy, which has become more available, is percutaneous transcatheter thrombectomy (Bogović et al. 2016). Should the abdominal aortic thrombosis occlude the ostia of the renal arteries, as was reported by Bogović et al., the patient may develop renal failure (Bogović et al. 2016). In these cases, surgical thrombectomy through a retroperitoneal approach is the preferred management option, as it bypasses the abdomen and thus allows for peritoneal dialysis to take place (Bogović et al. 2016).

4.4.2 Vasospasm

Vasospasms are particularly common in extremity vascular injuries (Costa et al. 2016). The occurrence of vasospasm during or following arterial manipulation is more common in children than in adults (Costa et al. 2016), especially within the age group of 10 years and younger (Shah et al. 2009). According to one study, in around a quarter of all pediatric patients presenting with vascular insufficiency, it was brought about by

vasospasm (Shah et al. 2009). Vasospasm often develops as a consequence of catheterizations, which frequently cause pediatric arteries to go into spasm around the catheter, resulting in partial or total arterial occlusion (Sidawy & Perler 2018). The degree of occlusion correlates to the catheter size used in children (Lin et al. 2001): a catheter diameter of more than half of the arterial diameter, or less than 1.9 mm smaller than the arterial diameter, has been connected with an increased risk of serious vasospasms (Sidawy & Perler 2018) and should thus be avoided. In order to differentiate between vasospasm and arterial lesion, angiography may be used (Sidawy & Perler 2018).

Conservative treatment of spastic arteries, such as the sole removal of the catheter, may be sufficient for a complete restoration of vessel patency (Shah et al. 2009; Sidawy & Perler 2018). Nevertheless, it is advised to give systemic heparin in vasospasm, to reduce the chances of thrombosis development or to slow it down if already happening (Sidawy & Perler 2018). If a bone fracture or a dislocation is associated with acute vascular insufficiency, it is very likely that it will subside following or even during surgical repair of the fracture, assuming that it was due to vasospasm (Shah et al. 2009). It is therefore of utmost importance to reevaluate the vascular status after bone fracture reduction or fixation (Shah et al. 2009). Specifically during orthopedic procedures, the time and safe environment of the operating room should be taken advantage of, in order to avoid missing vascular complications or unnecessary interventions for problems that resolve on their own (Shah et al. 2009). Warming of the affected limb or the use of intra-arterial vasodilators, such as papaverine, may be enough to reverse spasm (Sidawy & Perler 2018). In cases of vascular reconstructions, the harvested vessel should be immersed into saline and papaverine beforehand, in order to attenuate vasospasm following graft interposition (D'Oria et al. 2020).

4.4.3 Acute arterial ischemia

An occlusion may present as acute or chronic arterial ischemia (Lin et al. 2001). Acute arterial ischemia is one of the most common complications following iatrogenic procedures, that will require surgical intervention (Lin et al. 2001). To establish the diagnosis prior to intervention, it is usually sufficient to use US scanning (Lin et al. 2001). If patients present with absence of pulse on Doppler examination, they may immediately undergo surgical repair without any further diagnostics (Lin et al. 2001). In more complex cases, an angiogram can be used as well (Lin et al. 2001). Prompt regeneration of blood flow in the affected limb represents a “gold standard” of care in these situations (Sidawy & Perler 2018). If occlusion is incomplete, it may be managed conservatively on systemic heparin, given that perfusion remains steady and ongoing monitoring is assured (Sidawy & Perler 2018). In warzones, the early use of four-compartment fasciotomy has been proven beneficial and its application is generally advisable in cases of ischemia of the lower extremities in order to improve limb-related outcomes (Sidawy & Perler 2018). According to Lin et al., complications of surgical treatment and mortality were only found in children aged two years and younger (Lin et al. 2001). Complications that might develop after surgical interventions include infection or re-occlusion, with the latter reportedly being successfully treated with another thrombectomy and subsequent patch angioplasty using a vein graft (Lin et al. 2001). The fatalities reported by Lin et al., consist of a two-year-old boy who ended up with multisystem organ failure and a six-month-old infant with pulmonary hypertension (Lin et al. 2001). Both of them, due to their hemodynamic instability, weren't able to undergo surgical intervention to manage their acute limb ischemia immediately (Lin et al. 2001). Instead, they were operated on around a week after their catheterization procedure (Lin et al. 2001), which emphasizes the importance of immediate surgical intervention in the case of acute arterial ischemia.

4.4.4 Chronic arterial ischemia

Concerning chronic arterial ischemia, the presenting symptoms depend on the location (Lin et al. 2001). In chronic femoral ischemia, presenting symptoms can be severe claudication or unequal limb lengths leading to gait disturbances (Lin et al. 2001). With the help of skeletal roentgenography, Lin et al. were able to present significant treatment success after iliofemoral artery bypass grafting in a nine-year-old boy, whose limb-length-discrepancy shrank two centimeters over five years (Lin et al. 2001). When making a treatment plan in chronic occlusion, the use of a preoperative arteriography is crucial, in order to accurately assess the size of the occlusion (Lin et al. 2001). Asymptomatic patients with arterial occlusion should be followed up regularly, whereas symptomatic patients should be operated on as soon as possible (Lin et al. 2001). In case of chronic arterial ischemia, preferred treatment is bypass grafting with a reversed vein graft (Lin et al. 2001). If the ischemia is a consequence of femoral approach catheterization, the most common location for bypass grafting would be iliofemoral (Lin et al. 2001).

4.5 Compartment syndrome

Compartment syndrome is sometimes managed prophylactically in adults with fasciotomy, since delayed treatment has been shown to result in a higher number of amputations at 30 days (D'Oria et al. 2020). There is a lack of literature regarding this topic in the pediatric population. However, successful use of prophylactic fasciotomy has been reported by D'Oria et al., which in their case was justified by long ischemic times, as well as concurrent peripheral nervous injury (D'Oria et al. 2020). This correlates to the proposition made by Costa et al., according to which fasciotomy can be used prophylactically in the event of prolonged ischemic times or acutely, when compartment syndrome is suspected (Costa et al. 2016).

4.6 Amputation

Amputation may be “acute” or delayed (Corneille et al. 2011). “Acute” amputation is applied promptly in the case of severely comminuted limbs, whereas delayed amputation of the extremities may be necessary following failed revascularization attempts, long ischemic periods or extensive injuries (Corneille et al. 2011; Costa et al. 2016). A scoring system, which can help surgeons decide whether a limb is salvageable or not, has been developed by Helfet and colleagues (Mommsen et al. 2010). The so-called Mangled Extremity Severity Score (MESS), which is mainly applied to the adult population and ranges from one to 14, is reportedly 100% accurate in predicting amputation in adults, in case the score is seven or higher (Mommsen et al. 2010). This tool takes the mechanism of injury, stages of shock the patients present with, ischemia of the limb, as well as age of the patient, into account (Mommsen et al. 2010). Mommsen et al. concluded, that MESS may be a good basis for prediction, yet needs to be adjusted in children, as they were able to successfully salvage limbs in children with $MESS \geq 7$ (Mommsen et al. 2010). Lin et al. raised the threshold in their study to $MESS \geq 10$ and were able to salvage the limbs of 75% of patients (Mommsen et al. 2010).

Common complications of leg replantation following crush-amputations in adults are shortening of the affected limb and inadequate motor and sensory reinnervation. Thus, the use of prosthesis commonly offers a more beneficial outcome in adults. In children, specifically those who did not learn how to walk yet, replantation of the legs is the preferred treatment option (30). However, reports of successful leg replantation are very limited. An example of a successful replantation of amputated legs in a three-month-old infant has been reported by Bulić et al. following crush amputation of lower limbs with the loss of both knee joints (Bulic et al. 2017), including the femoral and tibial growth plates. The authors succeeded to reestablish motor and sensory

reinnervation in both legs, enabled significant limb growth of only 7% - 8% less than normal growth at that age, and also provided the option of possible future knee reconstruction (Bulic et al. 2017).

4.7 Pink pulseless hand

A supracondylar fracture of the humerus can be accompanied by a lack of pulse distally to the brachial artery. The mechanism leading to this phenomenon is thought to be either blunt injury to the brachial artery, transection or entrapment of the artery, or arterial compression due to expanding hematoma (Grant et al. 2018). If the lack of pulse, accompanied by signs of hypoperfusion, persists following fracture reduction (Figure 2), an immediate surgical exploration is indicated (Grant et al. 2018).

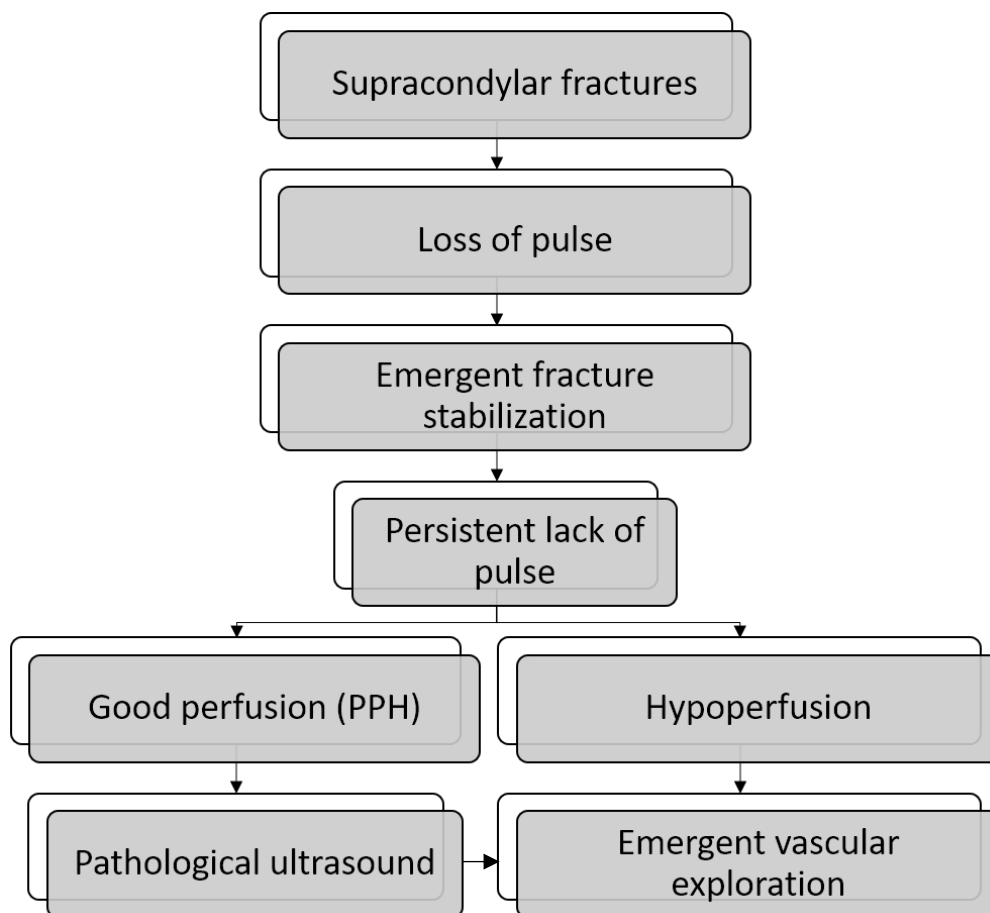


Figure 2. Algorithm for the treatment of supracondylar fractures (PPH – “pink pulseless hand”).

In the case of a “pink pulseless hand (PPH)”, when there is no detectable pulse despite the hand being well perfused following fracture reduction, a Duplex-US can be performed to evaluate the vascularization (Grant et al. 2018).

Should there be a restoration of pulse following orthopedic surgery, it may be sufficient to monitor the patient closely for a minimum of 24 hours (Grant et al. 2018). Duplex US is highly recommended to guide management decisions, as it allows rapid detection of compromised flow and location of lesions (Grant et al. 2018). Should the PPH be caused by arterial transection, this may be treated with thrombectomy and subsequent reconstruction with a terminoterminal anastomosis or a venous interposition graft (Grant et al. 2018).

5 Follow-up

All patients, provided there aren't any contraindications, should receive antiplatelet therapy for 30 days after vessel injury, as it is thought to assist in avoiding platelet adherence to the injured vessel and site of repair (Sidawy & Perler 2018). Anticoagulants on the other hand are usually avoided due to their tendency to cause bleeding (Sidawy & Perler 2018). Following revascularization, antithrombotic therapy is most commonly managed with acetylsalicylic acid, 15 mg/kg/day (D'Oria et al. 2020). Complications of acetylsalicylic acid administration, such as the Reye's syndrome, are not to be expected, since they usually only occur with higher dosages above 40 mg/kg/day (D'Oria et al. 2020). If there is no evidence of bleeding or other complications following revascularization, i.e. thromboembolism or failed patency, antithrombotic therapy may be withdrawn after a month (D'Oria et al. 2020).

Immediate postoperative surveillance should generally include hourly vascular examinations, including routine pulse exam and clinical assessment (Sidawy & Perler

2018). Outpatient follow-up should include regular pulse examinations, blood pressure monitoring, assessment of limb-length discrepancies and evaluation of any signs and symptoms of arterial insufficiency (Costa et al. 2016). Doppler US is an excellent method to assess for arteriovenous communications, expanding hematomas, thrombosis, pseudoaneurysms and to evaluate flow, following intravascular procedures (Costa et al. 2016). A few of the revascularization procedures demand a more specific surveillance: following stenting of the thoracic aorta, the patient will need to undergo a CTA scan annually until adulthood (Sidawy & Perler 2018). In the early postoperative period following lower extremity revascularization, routine physical exam is the surveillance method of choice, whereas Duplex scanning should be the preferred surveillance method at one month postoperatively, as well as afterwards at regular intervals, since it can reliably visualize complications such as stenosis or other changes (Sidawy & Perler 2018).

6 Prevention

Prior to vascular procedures, a risk scoring system for serious adverse events (SAE) can be undertaken (Sidawy & Perler 2018). According to this, catheterizations in children that are less than 30 days old and 2.5 kg of weight, as well as the use of larger sheaths for endovascular intervention, are highly likely to result in SAE (Sidawy & Perler 2018).

Guiding catheters of 6F or larger, have been positively correlated with significant iatrogenic vascular injuries in pediatric patients (Lin et al. 2001; Sidawy & Perler 2018) and should thus be avoided. For carotid interventions, a pediatric feeding tube or Argyle shunt should be used, due to the smaller size of children's vessels (Sidawy & Perler 2018).

Repeated arterial punctures should be avoided and their use reserved to major arteries (Costa et al. 2016), since ≥ 3 catheterizations are positively associated with severe iatrogenic injuries in children (Lin et al. 2001). Use of US is recommended to guide arterial punctures, considering the overlap of femoral artery and vein in up to a third of all pediatric patients (Sidawy & Perler 2018). Following the procedure, firm pressure needs to be applied (Costa et al. 2016) with the aim to prevent the development of complications, such as hematoma or pseudoaneurysm formation.

The risk of vascular injury can be reduced by handling the vessel carefully, such as by grasping its surrounding adventitia instead of the vessel itself, in order to avoid direct injury to the endothelium (D'Oria et al. 2020). Yet one needs to be careful during reconstruction of a vessel, to avoid adventitial tissue to be incorporated into the luminal aspect of the anastomosis, since this could lead to thrombotic complications (D'Oria et al. 2020). Further complications causing narrowing of the conduit may also be reduced by locally flushing the vessel prior to reconstruction with heparin (D'Oria et al. 2020).

Grafts for vascular repair must allow growth of the patients' vessels (Sidawy & Perler 2018). To enable this axial and radial growth and prevent narrowing at the site of the anastomosis, running sutures should be avoided (Sidawy & Perler 2018). Interrupted sutures allow prevention of narrowing at the site of anastomosis as the child grows (D'Oria et al. 2020), which is thought to happen with the use of running sutures, as was shown in animal models (Calles-Vázquez et al. 2005).

The use of nonabsorbable sutures, i.e. polypropylene or nylon sutures, is preferable, as it has been shown that they have a lesser thrombogenic potential than absorbable sutures (Calles-Vázquez et al. 2005). Nevertheless, other authors have been using absorbable sutures, like PDS, without reporting a particularly high incidence of thrombotic complications (Lin et al. 2001; Costa et al. 2016). Research by Wang et al. demonstrated that PDS sutures maintained adequate tensile strength until

healing of the anastomoses, while the absorbability might improve long-term patency by reducing foreign body reactions (Wang et al. 1994). Moreover, Costa and colleagues were able to demonstrate the successful use of atraumatic vascular clips (Uclips) for challenging anastomoses, under application of microsurgical instrumentation (Costa et al. 2016).

The usage of systemic heparin sodium in the setting of vascular trauma is controversial, due to the risk of bleeding, but some authors maintain that it may be beneficial in cases of extremity vascular trauma and for thrombosis prevention during intravascular procedures (Costa et al. 2016). Systemic anticoagulation is, however, contraindicated in cases of active (uncontrolled) bleeding and aortic dissection (Khan et al. 2020). Thrombotic complications are also less frequent when trauma at the anastomosis site during reconstruction is kept minimal by utilization of microsurgical technique and instruments (D’Oria et al. 2020).

7 Limitations

7.1 Multidisciplinary approach

There’s not one single specialty responsible for taking care of pediatric vascular injuries, thus individual decisions on a case-by-case basis need to be made regarding which specialists will take over a case (Shah et al. 2009). Pediatric surgeons, vascular surgeons, plastic surgeons and orthopedic surgeons can all be involved in these situations (Shah et al. 2009). Theoretically, this multidisciplinary approach is a benefit, yet in praxis it won’t be available at all times, specifically in smaller hospitals with fewer departments, and it can also slow down the delivery of surgical care, unless there is a strictly defined protocol at the institutional level.

7.2 Graft types

Vessel reconstructions with grafts are substantially more challenging in pediatric patients than in adults. Children's vessels do not only have a much smaller diameter, but also a vast growth potential and most importantly, require durable reconstructions that will last a lifetime. Synthetic grafts have been applied successfully in reconstructions of large diameter vessels, yet in blood vessels with a diameter of ≤ 6 mm, these grafts carry an increased risk of thrombosis, calcification, stenosis and infection (Matsuzaki et al. 2019; Mallis et al. 2020). For this reason, autologous vessels such as the internal thoracic artery, radial arteries and the saphenous vein have been favored in cases of surgery for peripheral obstructive arteriosclerosis (Matsuzaki et al. 2019). However, autologous vessel grafts carry some disadvantages, as the amount of harvestable autologous vessels in children is limited and vessels, such as the saphenous vein, may dilate under long-standing arterial pressure (Shalkow & Vazquez-Braverman 2020). If there is no adequate autologous vessel available, non-biodegradable grafts made from PTFE or polyethylene terephthalate (PET) are the preferred synthetic materials used (Pascual et al. 2005). PTFE grafts show a similar compliance as native arteries, withstand pulsatile blood flow, allow tissue ingrowth on the abluminal surface due to its porosity and are protected from leakage through the low porosity of the luminal surface (Pascual et al. 2005). The downside of synthetic grafts is that they don't grow with the child's vessels and require lifelong pharmacotherapy with anticoagulant or antiplatelet drugs (Matsuzaki et al. 2019).

7.3 Endovascular treatment options

Endovascular techniques have many benefits, such as the ability to manage vascular lesions difficult for open surgical access, shorter intervention times, and possibility for accomplishing temporary vascular control in seriously injured patients

before definitive repair (Costa et al. 2016). They are also less invasive (Costa et al. 2016), but cannot be used as widely in pediatric patients as in the adult population, owing to distinct anatomy and future growth in children (Sidawy & Perler 2018). Nonetheless, endovascular techniques have recently been more frequently employed for embolization and bleeding control in general, for temporary stenting in multiply injured patients, or for placement of covered stents for carotid injuries (Sidawy & Perler 2018).

7.4 Long-term follow-up

Long-term follow-up is difficult due to the rarity of pediatric vascular injuries, but also due to the multitude of specialists working on each case, having a negative impact on compliance (Sidawy & Perler 2018).

8 Outlook

8.1 Database enhancement

The rarity of pediatric vascular injuries as well as the hesitation to report one's own complications, lead to a consequential lack of information necessary for quality improvement and board certification (Barkho et al. 2018). In order to accumulate more valuable information and enable improved management, all available data on cases of pediatric vessel injuries should be recorded in a registry particular for this type of patients (Sidawy & Perler 2018). For this purpose, Fisher et al. developed a novel case-log web application, which aids pediatric surgeons in reporting complications real-time and by doing so, exceeding the accuracy of administrative datasets (Fisher et al. 2017). Nevertheless, when gathering information on these patients, data should also be added from existing vascular and trauma registries, the military's experience, as well

as in-hospital cases (Sidawy & Perler 2018). By doing so, there will be an enhanced and extended database in the future, that will provide quality information about diagnoses, treatment options, outcomes and long-term follow-up (Sidawy & Perler 2018).

8.2 Endovascular approaches

Endovascular procedures in children should be improved and their use made safer, in order to decrease the incidence and morbidity of iatrogenic pediatric vessel injuries. Surgeons should receive a deeper education on the necessary precautions when facing vascular injuries in children, and the awareness of possible complications should be raised accordingly.

8.3 Establishment of universal algorithms

To date, pediatric vascular injuries have been treated on a case-by-case approach (Sidawy & Perler 2018). Since fast diagnosis and treatment are crucial for a successful outcome, it has been recommended for each institution facing these cases, to establish an algorithm, so that all participating specialists will be able to follow the same guidelines (Sidawy & Perler 2018). In addition to that, utilizing an algorithm will have the advantage of addressing the common problem of inexperience with this rare type of injuries.

8.4 Tissue-engineered vascular grafts

Since small-diameter vascular grafts are required and the disadvantages of both autologous and synthetic grafts are substantial, the development of tissue-engineered vascular grafts (TEVGs) is underway. A TEVG is made of a scaffold, seeded cells and factors to stimulate tissue formation (Matsuzaki et al. 2019). Ideally, the optimal TEVG

would be universally applicable, resistant to calcification, stenosis, thrombosis and infection, while being affordable and offering growth potential (Matsuzaki et al. 2019). Theoretically, the newly formed tissue will be antithrombogenic and capable of growth, while being less susceptible to infection, as it is derived from autologous tissue (Matsuzaki et al. 2019). In addition to that, the TEVG should have sufficient suture retention strength and be able to withstand pulsatile arterial pressures, to allow optimal potency and adequate long-term results (Mallis et al. 2020).

9 Acknowledgement

I would like to thank my mentor, doc.dr.sc. Tomislav Meštrović, MD, PhD, for his support and knowledge that he kindly shared with me. I would also like to thank other members of the Surgery Department at the Clinical Hospital Center Rebro, as well as other members of my graduation committee: doc.dr.sc. Predrag Pavić, MD, PhD, and prof.dr.sc. Boško Skorić, MD, PhD.

10 References

- Amaro E, Pophal S, Zoldos J (2017) Vascular Reconstruction in a Neonate after Iatrogenic Injury during Cardiac Catheterization. *Plast Reconstr Surg Glob Open* 5:e1600. doi: 10.1097/GOX.0000000000001600
- Barkho JO, Chan AKC, Choi M (2018) Successful conservative management of a superficial pediatric pseudoaneurysm. *J Pediatr Surg Case Rep* 31:64–68. doi: 10.1016/j.epsc.2018.01.009
- Besir Y, Gökalp O, Eygi B, Lafcı BB, Gökalp G, Yılık L, İner H, Gürbüz A (2017) Surgical approach to vascular iatrogenic injuries in pediatric cases. *Ulus Travma Acil Cerrahi Derg* 23:217–222. doi: 10.5505/tjtes.2016.61282
- Bogović M, Papeš D, Mitar D, Smiljanić R, Sršen-Medančić S, Čavar S, Antabak A, Luetić T (2016) Abdominal Aortic Thrombosis in a Healthy Neonate. *Ann Vasc Surg* 32:131.e7-131.e9. doi: 10.1016/j.avsg.2015.10.014
- Bulic K, Antabak A, Dujmovic A, Kistic H, Lorencin M (2017) Bilateral Leg Replantation in a 3-Month-Old Baby After a Knee Level Crush Amputation—A 2-Year Follow-up. *Ann Plast Surg* 78:304–306. doi: 10.1097/SAP.0000000000000965
- Calles-Vázquez MC, Viguera FJ, Sun F, Usón JM, Usón J (2005) Vein and artery growth after anastomosis with vascular closure staple clips vs interrupted polypropylene suture: application in pediatric vascular surgery. *J Pediatr Surg* 40:1428–1435. doi: 10.1016/j.jpedsurg.2005.05.062
- Cho MJ, Jeon UB, Choo KS, Lee HD (2014) Percutaneous ultrasound-guided thrombin injection is effective even in infants with external iliac artery pseudoaneurysms. *Korean J Pediatr* 57:199–201. doi: 10.3345/kjp.2014.57.4.199

- Corneille MG, Gallup TM, Villa C, Richa JM, Wolf SE, Myers JG, Dent DL, Stewart RM (2011) Pediatric Vascular Injuries: Acute Management and Early Outcomes. *J Trauma Inj Infect Crit Care* 70:823–828. doi: 10.1097/TA.0b013e31820d0db6
- Costa CDA, Souza JEDS, Araújo AOD, Melo FAO, Costa IN, Klein PH (2016) Pediatric vascular trauma in Manaus, Amazon - Brazil. *Rev Col Bras Cir* 43:320–326. doi: 10.1590/0100-69912016005004
- D’Oria M, Mani K, Rodriguez Lorenzo A (2020) Microsurgical Salvage of Acute Lower Limb Ischemia after Iatrogenic Femoral Injury during Orthopedic Surgery in a Pediatric Patient. *Ann Vasc Surg* 69:452.e5-452.e11.
- Dzepina I, Unusic J, Mijatovic D, Bulic K (2004) Pseudoaneurysms of the brachial artery following venipuncture in infants. *Pediatr Surg Int* 20:594–597. doi: 10.1007/s00383-004-1238-z
- Fisher JC, Kuenzler KA, Tomita SS, Sinha P, Shah P, Ginsburg HB (2017) Increased capture of pediatric surgical complications utilizing a novel case-log web application to enhance quality improvement. *J Pediatr Surg* 52:166–171. doi: 10.1016/j.jpedsurg.2016.10.036
- Fraser JD, Cully BE, Rivard DC, Leys CM, Holcomb GW, St. Peter SD (2009) Traumatic pseudoaneurysm of the anterior tibial artery treated with ultrasound-guided thrombin injection in a pediatric patient. *J Pediatr Surg* 44:444–447. doi: 10.1016/j.jpedsurg.2008.08.027
- Grant C, Theiss M, Mukherjee D (2018) PC196. Pediatric Brachial Artery Injury Due to Supracondylar Humerus Fractures. *J Vasc Surg* 67:e227. doi: 10.1016/j.jvs.2018.03.342
- Grizelj R, Vuković J, Filipović-Grčić B, Šarić D, Luetić T (2006) Successful use of recombinant activated FVII and aminocaproic acid in four neonates with life-

- threatening hemorrhage. *Blood Coagul Fibrinolysis* 17:413–415. doi: 10.1097/01.mbc.0000233373.71970.6f
- Hogan AR, Lineen EB, Perez EA, Neville HL, Thompson WR, Sola JE (2009) Value of computed tomographic angiography in neck and extremity pediatric vascular trauma. *J Pediatr Surg* 44:1236–1241. doi: 10.1016/j.jpedsurg.2009.02.039
- Kang SS (1998) Reply to the letter to the editor. *J Vasc Surg* 28:1121.
- Khan S, Elghazaly H, Mian A, Khan M (2020) A meta-analysis on anticoagulation after vascular trauma. *Eur J Trauma Emerg Surg* 46:1291–1299. doi: 10.1007/s00068-020-01321-4
- Landau D, Schreiber R, Szendro G, Golcman L (2003) Brachial artery pseudoaneurysm in a premature infant. *Arch Dis Child Fetal Neonatal Ed* 88:152F – 153. doi: 10.1136/fn.88.2.F152
- Lennox A, Griffin M, Nicolaidis A, Mansfield A (1998) Letter to the editor. *J Vasc Surg* 28:1120–1121.
- Lin PH, Dodson TF, Bush RL, Weiss VJ, Conklin BS, Chen C, Chaikof EL, Lumsden AB (2001) Surgical intervention for complications caused by femoral artery catheterization in pediatric patients. *J Vasc Surg* 34:1071–1078. doi: 10.1067/mva.2001.119043
- Mallis P, Kostakis A, Stavropoulos-Giokas C, Michalopoulos E (2020) Future Perspectives in Small-Diameter Vascular Graft Engineering. *Bioengineering* 7:160. doi: 10.3390/bioengineering7040160
- Matsuzaki Y, John K, Shoji T, Shinoka T (2019) The Evolution of Tissue Engineered Vascular Graft Technologies: From Preclinical Trials to Advancing Patient Care. *Appl Sci* 9:1274. doi: 10.3390/app9071274

- Mommsen P, Zeckey C, Hildebrand F, Frink M, Khaladj N, Lange N, Krettek C, Probst C (2010) Traumatic extremity arterial injury in children: Epidemiology, diagnostics, treatment and prognostic value of Mangled Extremity Severity Score. *J Orthop Surg Res* 5:8.
- Guzzetta PC (1994) Congenital and acquired aneurysmal disease. *Semin Pediatr Surg* 3:97–102.
- Papes D, Šnajdar I, Čavar S, Antabak A, Bulić K, Bartoniček D, Dobrota S, Luetić T (2019) Pediatric Iatrogenic Arteriovenous Fistulas. *Am Surg* 85:262–265. doi: 10.1177/000313481908500512
- Pascual G, Martínez S, Rodríguez M, Serrano N, Bellón JM, Buján J (2005) Patency and structural changes in cryopreserved arterial grafts used as vessel substitutes in the rat. *J Surg Res* 124:297–304. doi: 10.1016/j.jss.2004.10.016
- St. Peter SD, Ostlie DJ (2006) A review of vascular surgery in the pediatric population. *Pediatr Surg Int* 23:1–10. doi: 10.1007/s00383-006-1778-5
- Shah SR, Wearden PD, Gaines BA (2009) Pediatric Peripheral Vascular Injuries: A Review of Our Experience. *J Surg Res* 153:162–166. doi: 10.1016/j.jss.2008.03.006
- Shalkow J, Vazquez-Braverman J (2020) Conduits for Vascular Reconstruction in the Pediatric Patient. In: Medscape, <https://emedicine.medscape.com/article/1018266-overview>. Accessed 9 April 2021
- Sidawy AN, Perler BA (2018) Rutherford's Vascular Surgery and Endovascular Therapy, 9th ed. Philadelphia: Elsevier.
- Stern AB, Klemmer PJ (2011) High-output heart failure secondary to arteriovenous fistula: High-output heart failure. *Hemodial Int* 15:104–107. doi: 10.1111/j.1542-4758.2010.00518.x

- Suding PN, Wilson SE (2007) Strategies for Management of Ischemic Steal Syndrome. *Semin Vasc Surg* 20:184–188. doi: 10.1053/j.semvascsurg.2007.07.009
- Velez-Roa S, Neubauer J, Wissing M, Porta A, Somers VK, Unger P, van de Borne P (2004) Acute arterio-venous fistula occlusion decreases sympathetic activity and improves baroreflex control in kidney transplanted patients. *Nephrol Dial Transplant* 19:1606–1612. doi: 10.1093/ndt/gfh124
- Villamaria CY, Morrison JJ, Fitzpatrick CM, Cannon JW, Rasmussen TE (2014) Wartime vascular injuries in the pediatric population of Iraq and Afghanistan: 2002–2011. *J Pediatr Surg* 49:428–432. doi: 10.1016/j.jpedsurg.2013.10.002
- Wang ZG, Pu LQ, Li GD, Du W, Symes JF (1994) Polydioxanone absorbable sutures in vascular anastomoses: experimental and preliminary clinical studies. *Cardiovasc Surg* 2:508–13.
- Wollstein R, Wolf Y, Sklair-Levy M, Matan Y, London E, Nyska M (2000) Obliteration of a Late Traumatic Posterior Tibial Artery Pseudoaneurysm by Duplex Compression. *J Trauma Inj Infect Crit Care* 48:1156–1158. doi: 10.1097/00005373-200006000-00025
- Young CJ, Dardik A, Sumpio B, Indes J, Muhs B, Ochoa Char CI (2015) Venous Ulcer: Late Complication of a Traumatic Arteriovenous Fistula. *Ann Vasc Surg* 29:836.e1-836.e3. doi: 10.1016/j.avsg.2014.11.020

11 Biography

Lea Catharina Flockenhaus was born on September 20th, 1995 in Hamburg, Germany where she grew up. During high school, she completed several internships in the fields of art, theater, television, law and social work, and participated in exchange programs to Kituntu, Tanzania, and Dublin, Ireland. After finishing high school, she went on to solo travel to South America, where she learned Spanish, volunteered in work with children and completed three months of practical nursing training for medical students in Córdoba, Argentina. All her life she has been a competitive athlete in tennis and golf, and has won numerous championships. She moved to Zagreb, Croatia in 2014 and enrolled in the University of Zagreb, School of Medicine, Medical Studies in English program. Throughout medical school, she has completed several months of voluntary clinical rotations in the departments of Cardiology and Trauma surgery. During her free time, she enjoys playing tennis and practicing various other sports, travelling, and spending time with her family and friends.