

Aortic root surgery

Koritnik, Polona

Master's thesis / Diplomski rad

2016

Degree Grantor / Ustanova koja je dodijelila akademski / stručni stupanj: **University of Zagreb, School of Medicine / Sveučilište u Zagrebu, Medicinski fakultet**

Permanent link / Trajna poveznica: <https://um.nsk.hr/um:nbn:hr:105:055036>

Rights / Prava: [In copyright](#) / [Zaštićeno autorskim pravom.](#)

Download date / Datum preuzimanja: **2024-04-17**



Repository / Repozitorij:

[Dr Med - University of Zagreb School of Medicine Digital Repository](#)



**UNIVERSITY OF ZAGREB
SCHOOL OF MEDICINE**

Polona Koritnik

**Aortic Root Surgery: ECHO Analysis
Repair versus Replacement**

GRADUATE THESIS



Zagreb 2016

**UNIVERSITY OF ZAGREB
SCHOOL OF MEDICINE**

Polona Koritnik

**Aortic Root Surgery: ECHO Analysis
Repair versus Replacement**

GRADUATE THESIS

Zagreb 2016

This graduate thesis was made at the Department of Cardiac and Transplant Surgery, University Hospital Dubrava in Zagreb under the supervision of prof. dr. sc. Željko Sutlić and it was submitted for evaluation in the academic year of 2015/2016.

ABBREVIATIONS

AR = aortic regurgitation

AV = aortic valve

AVR = aortic valve replacement

AVRep = aortic valve repair

LV = left ventricle

LVOT = left ventricle outflow tract

STJ = sinotubular junction

VAJ = ventriculo-aortic junction

RA = right atrium

FAA = functional aortic annulus

BAV = bicuspid aortic valve

LVEF = left ventricular ejection fraction

LVEDD = left ventricular end-diastolic diameter

LVESD = left ventricular end-systolic diameter

TTE = transthoracic echocardiography

TEE = transesophageal echocardiography

VSRR = valve-sparing aortic root replacement

VSD = ventricular septal defect

NYHA = New York Heart Association

EuroSCORE = European System for Cardiac Operative Risk Evaluation

IQR = interquartile range

MV = mitral valve

MVRep = mitral valve repair

CABG = coronary artery by-pass grafting

TABLE OF CONTENTS

INTRODUCTION	1
AIM OF THE STUDY	11
PATIENTS AND METHODS	12
<i>Study population</i>	12
<i>Echocardiography</i>	14
<i>Surgery</i>	15
<i>Follow-up</i>	15
<i>Statistical Analysis</i>	15
RESULTS	17
<i>Preoperative and operative data</i>	17
<i>Echocardiography</i>	19
DISCUSSION	23
CONCLUSSION	26
ACKNOWLEDGEMENTS	27
REFERENCES	28
BIOGRAPHY	32

SUMMARY

Title: Aortic Root Surgery: ECHO Analysis Repair versus Replacement

Author: Polona Koritnik

Keywords: aortic regurgitation, aortic valve repair, ventricular function

Chronic aortic regurgitation (AR) sets in motion numerous compensatory mechanisms for left ventricle (LV) to be able to maintain normal ejection fraction (EF), regardless of chronic volume and pressure overload. With long standing AR compensatory mechanism eventually fail and EF decreases. The survival prognosis is poor once symptoms develop. That is why current guidelines recommend surgical intervention in case of symptoms, $EF \leq 50\%$ or left ventricular end-diastolic diameter (LVEDD) $> 70\text{mm}$ or left ventricular end-systolic diameter (LVESD) $> 50\text{mm}$.

Aortic valve replacement (AVR) is an established treatment for patients with AR. In the past 20 years numerous repair techniques for diseased aortic valves (AV) have been developed with the aim to be able to treat AR without subjecting patient to possible complications connected with mechanical or bioprosthetic valve implantation. Promising results of aortic valve repair (AVRep) surgeries in terms of overall survival, freedom from re-operation and valve related complications have been documented.

LV reverse remodeling has been reported both after AVR and AVRep. This retrospective study investigated and compared changes in LV dimension (LVEDD) and function (LVEF) between 32 patients who underwent AVR and 25 who underwent AVRep for treatment of AR. Statistically significant ($p < 0,05$) decrease of LVEDD has been documented in both groups when comparing dimensions immediately post-operatively and at early follow-up with dimensions measured pre-operatively. LVEF has decreased immediately post-operatively but normalized at early follow-up in both groups. This proves that both AVR and AVRep lead to LV reverse remodeling with comparable LVEDD and LVEF immediately post-operatively and at early follow-up.

INTRODUCTION

Aortic regurgitation (AR) is a consequence of either aortic valve (AV) disease or dilation of aortic root. It has been traditionally treated with aortic valve replacement (AVR) surgery. Attempts at aortic valve repair (AVRep) began already in the 1950s but due to poor success and later wide availability of mechanical and biological valve prostheses the AVRep was nearly abandoned[1]. The interest in developing and improving AVRep techniques decreased for a while until the 1980s when Carpentier's success [2] on mitral valve repair renewed the interest in AVRep operations. AVRep is an attractive treatment alternative to AVR because it avoids long-term risks associated with prosthetic valve implantation. A major drawback of biological valves is limited durability of the prostheses. Mechanical valves are connected to cumulative incidence of valve-related complications, including thromboembolism and hemorrhage, ranging from 4-5% per year[3]. Both are connected with increased overall risk of endocarditis.

The quality of life of young patients after surgery seems to be affected by the type of operation and it was shown that AVRep is connected with lower degree of worrying about possible valve failure as opposed to AVR[4].

The AV separates the left ventricle (LV) from systemic circulation. It lies at the terminal portion of left ventricular outflow tract (LVOT). The normal working of this tricuspid semilunar apparatus is critical for maintenance of efficient cardiac function.

The leaflets of the AV are supported and surrounded by the structures that together form the functional and anatomic unit the so-called aortic root (Figure 1). The components of the aortic root are: annulus, leaflets, leaflet attachments, aortic sinuses (Sinuses of Valsava), interleaflet triangles and sinotubular junction (STJ)[5]. The aortic root extends from the basal attachments of the leaflets within the LV to the STJ.

Normally, an AV is composed of three leaflets. They are attached in a semilunar fashion within the valvar sinuses. Together, these attachments form a thick fibrous crown-shaped structure, often termed "annulus". This description is unfortunate because annulus implies a circular structure, which

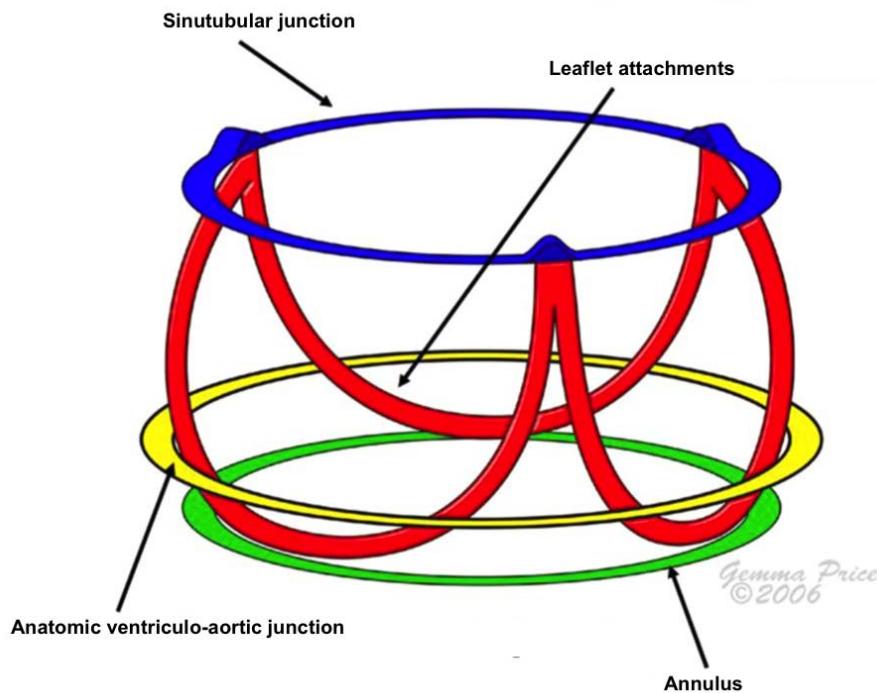


Figure 1: Aortic root anatomy (schematic representation); adapted from Anderson RH [6]

leaflet attachments do not form. This crown-shaped structure formed by leaflet attachments is also frequently called ventriculo-aortic junction (VAJ). This term is rather unclear since the anatomical ventriculo-aortic junction, found at the point where the ventricular structures change into fibroelastic wall of the arterial trunk, is a distinct circular locus within the aortic root and is not coincident with the leaflet attachments[6]. For the purpose of this study, both terms VAJ and annulus will be used to describe the crown-shaped structure formed by leaflet attachments at the base of aortic root.

The leaflets form a hemodynamic junction between LV and aorta. Everything distal to them is subjected to arterial pressures and all the structures proximal to their attachments are subjected to ventricular pressures. Physiologic trileaflet structure of the AV is the optimal solution for a low resistance valve opening[5]. The AV must open and close with minimal pressure differences between the ventricle and aorta. During closure, it must prevent the backflow of the blood. In order for that to happen, the leaflets must be perfectly aligned and should have a homogeneous coaptation line.

During the ventricular systole, the semilunar leaflets open into aortic sinuses called sinuses of Valsava. Two of those sinuses give rise to coronary arteries

consequently naming sinuses as the right and left coronary sinus and non-coronary or posterior sinus. Most of the sinuses' walls are made of thinned aortic wall but at their bases, the ventricular musculature is partly incorporated. This is not true for the base of the non-coronary sinus, which is made of fibrous tissue due to the continuity of leaflets of aortic and mitral valves.

The areas where the attachments of two adjacent AV cusps meet compromise commissures. Under each commissure lies one of the three interleaflet triangles. These represent the extension of LVOT but rather than being bound by ventricular musculature, histologically they are made of thinned aortic wall[7]. These triangles are the crucial part of proper valvar function since through them, the systolic expansion of aortic root maximizes ejection of LV and reduces shear stress on the cusps[8]. The triangle between non-coronary and right coronary sinuses faces the right atrium (RA). It is incorporated within the membranous part of the septum. During surgery this area is of special importance because of the proximity of His bundle and any injury of this bundle can lead to temporary or permanent conduction abnormalities. The triangle between the non-coronary and left coronary sinuses is positioned along the aortic valve-mitral valve continuity. The fibrous aortomitral curtain lies beneath this triangle[5]. The triangle between the right and left coronary sinuses faces the commissure of the pulmonary valve.

STJ separates the aortic root from the ascending aorta. It supports the peripheral attachments of the leaflets. Together with the ventriculo-aortic junction (VAJ), it forms functional aortic annulus (FAA)[9].

Failure of coaptation of valve leaflets during diastole leads to AR. This can be the consequence of distorted valve leaflets, dilated aortic annulus or combination of both. Most common pathologies leading to distorted leaflets are rheumatic disease, infective endocarditis, bicuspid aortic valve (BAV), calcific aortic disease, idiopathic degenerative disease and myxomatous proliferation of aortic tissue. Pathologies that lead to aortic annular dilatation and consequently to improper valvular closure are aortic dissection, trauma, connective tissue disorders such as Marfan syndrome, degenerative disease, aortitis (syphilitic, noninfectious giant cell).

Pathophysiological consequences of AR depend on the duration of the process. Acute AR is defined as hemodynamically significant aortic incompetence of sudden onset across previously competent AV in LV previously not subjected to volume overload. Common etiologies leading to acute AR are endocarditis, aortic dissection and trauma. Due to acute onset, the LV is unable to adapt to increased end-diastolic pressure. Hence, effective cardiac output is smaller as in chronic AR. In order to compensate for low cardiac output, the heart rate increases.

On the other hand, chronic AR causes gradual LV volume overload. This leads to numerous compensatory changes, including LV eccentric hypertrophy and enlargement. Due to this ventricular remodeling, patients may remain asymptomatic for a significant amount of time[10]. Nevertheless, with the progression of AR, the compensatory mechanisms fail and the patient becomes symptomatic. After the development of symptoms, the long-term prognosis is poor. In order to prevent further deterioration and possible development of heart failure, current guidelines recommend surgical intervention of all symptomatic patients with AR. Surgical intervention is also recommended for all asymptomatic patients with AR with impaired LV function ($LVEF \leq 50\%$) or $LVEDD > 70\text{mm}$ or $LVESD > 50\text{mm}$ since there is increased risk of developing irreversible myocardial dysfunction[11].

Echocardiography is the diagnostic method of choice when evaluating patients with AR. Either transthoracic echocardiography (TTE) or more invasive transesophageal echocardiography (TEE) can be used for the evaluation of AR severity and hemodynamic consequences, delineation of underlying mechanism(s) and to predict its reparability. The image quality produced by TTE is frequently insufficient for reliable assessment of underlying AR mechanism(s). TEE is therefore the preferred method for evaluating the mechanism of AR[12]. During preoperative assessment of AR by either TTE or TEE it is important to measure the size of aortic annulus, sinuses of Valsava, STJ and the first centimeters of ascending aorta (Figure 2). These measurements are best done in end-diastole. At the same time, one can also measure the length of cusp apposition and the cusp effective height. Effective height (Figure 3) is the height difference between central free margins of the leaflets and the aortic insertion lines. In adults, it normally

measures 9-10mm and everything less than 6-7mm indicates a degree of prolapse[13]. Any structural deformity of the leaflets as well as number of leaflets should be noted. Intraoperative TEE is mandatory during AVRep procedures as it represents a great tool for the assessment of repair adequacy and prediction of recurrent AR[12]. Whether or not the patient is a candidate for surgery depends on symptoms and LV dimension and function measurements done during echocardiography[11].

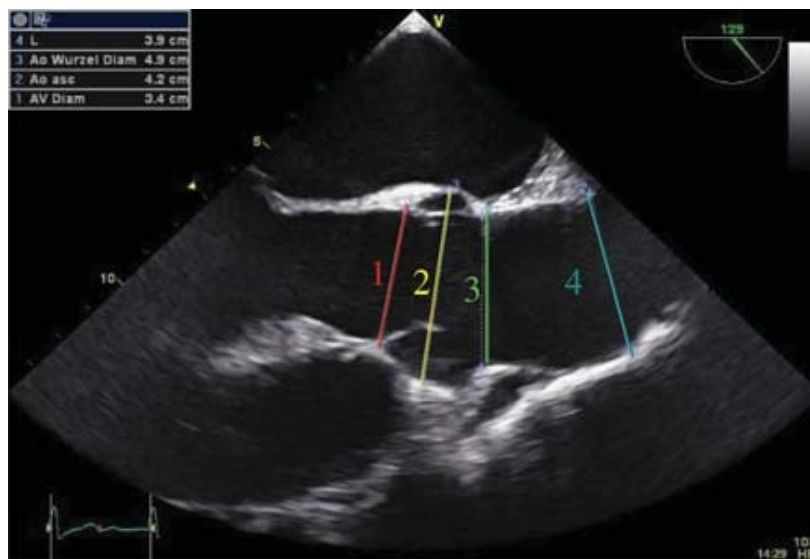

Figure 2: Measurements of the aortic diameters. 1: annulus; 2: sinuses of Valsava; 3: sinotubular junction; 4: proximal ascending aorta[14].

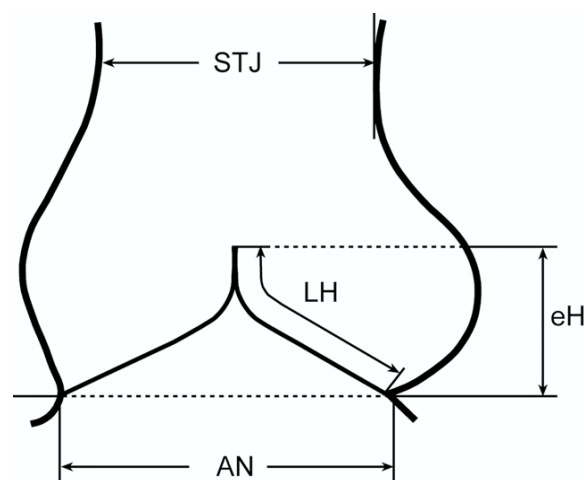


Figure 3: Effective height (eH). Schematic drawing of aortic valve and root. AN: annulus; LH: leaflet height; STJ: sinotubular junction[13].

Back in 1983, Carpentier wrote that surgeons are not basically concerned with the lesion but rather care more about the function. He defined the aim of the valve reconstruction as restoration of normal valve function and developed a functional approach to dealing with valve lesions with the goal of simplification of valve analysis before operation. He classified the valve lesions into type I (normal leaflet motion), type II (prolapsed leaflet) and type III (restricted leaflet motion)[2].

This guided development of repair oriented functional classification of AR (Figure 4) with the aim to provide a common framework for AV assessment and to guide approach to valve repair. Before describing functional classification, one must remember that the annulus of aortic valve is not a single anatomic structure as is annulus of the mitral valve, but rather consists of two separate components, VAJ and STJ, which together form the so called FAA.

Any lesion of FAA with normal leaflet motion is considered as type I AR. This group is further subdivided into type Ia-d AR. Type Ia AR results from STJ enlargement and dilatation of ascending aorta, type Ib AR results from dilatation of the sinuses of the Valsava and the STJ, type Ic results from the dilatation of VAJ and type Id results from cusp perforation without primary

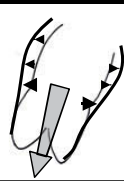
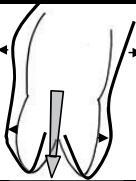
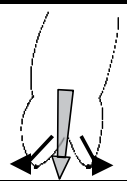
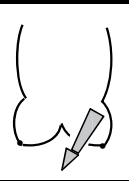
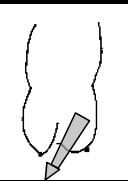
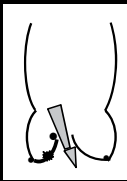
AI Class	Type I Normal cusp motion with FAA dilatation or cusp perforation				Type II Cusp Prolapse	Type III Cusp Restriction
	Ia	Ib	Ic	Id		
Mechanism						
Repair Techniques (Primary)	STJ remodeling <i>Ascending aortic graft</i>	Aortic Valve sparing: <i>Reimplantation or Remodeling with SCA</i>	SCA	Patch Repair <i>Autologous or bovine pericardium</i>	Prolapse Repair <i>Plication Triangular resection Free margin Resuspension Patch</i>	Leaflet Repair <i>Shaving Decalcificatio Patch</i>
(Secondary)	SCA		STJ Annuloplasty	SCA	SCA	SCA

Figure 4: Repair-oriented functional classification of aortic regurgitation[15]

FAA lesion. As type II AR are considered all those lesions resulting in leaflet prolapse either due to excessive leaflet tissue or commissural disruption. Type III AR is characterized by restrictive leaflet motion, which can be the consequence of bicuspid, degenerative or rheumatic valvular disease. One must have in mind that patients may have single or multiple lesions contributing to AR, for example patients with type Ib lesions may present with concomitant cusp prolapse (type II) which must be carefully evaluated during surgery[15].

After thorough pre-operative echocardiographic evaluation and determination of underlying mechanism of AR, the surgeon is able to choose the most appropriate surgical technique that would restore normal valve physiology. Even though the AVR has been standard surgical procedure for treatment of AR for many years, a great improvement has been done in understanding the normal anatomy of AV as well as interrelation between AV and aortic root and appreciation of different mechanisms leading to AR. These important improvements have lead to AVRep operations becoming a more and more attractive alternative to AVR surgeries. The term AVRep does not only imply the repair of the cusps but also includes valve-sparing root replacement or any kind of FAA stabilization.

As mentioned above, the possible underlying mechanisms leading to AR are classified into type I, II or III AR. This classification helps the surgeon to choose an appropriate repair technique. The goal of cusp prolapse correction is the elimination of redundant tissue at the level of free margin and re-establishment of homogenous coaptation line for all leaflets. This is most commonly done by plicating sutures (5-0 or 6-0 polypropylene) in the central part of the free cusp margin. Any presence of cusp fenestration together with cusp prolapse should be properly addressed and closure of these fenestrations with an autologous pericardial patch has lead to good long-term results[16]. Effective height of the cusps should be measured after correction of the prolapse in order to objectively assess the repair and avoid potential failure of procedure.

In restrictive leaflet disease, shaving or decalcification is required with or without patching. The outcome of these procedures has been poor and type III lesions represent risk factor for recurrent AR[15].

When performing isolated AV repair, one should keep in mind the fact that any dilatation of the annulus is a risk factor for failure of the procedure. Different techniques have been proposed over the years to address this problem. The biggest experience has been obtained by expansible external device placed at the level of VAJ[17].

Valve-sparing aortic root replacement (VSRR) techniques are widely accepted treatment methods when AR is a consequence of dilated FAA and leaflet motion is otherwise normal. Two types of VSRR operations were originally performed to treat dilated FAA: aortic root remodeling[18] and aortic valve reimplantation[19].

For both techniques, the best exposure is median sternotomy. After cross-clamping and longitudinal opening of the ascending aorta the aortic root is transected above the commissures. The aneurysmal aortic sinuses are excised, leaving 5mm of aortic wall adjacent to cusp insertion lines and around coronary artery orifices.

When performing aortic root remodeling, the next step should include gentle stretching of the three commissures in the vertical direction by means of three horizontal mattress sutures placed just above the top of each commissure and approximation until the cusps coapt. The appropriate size of the graft is chosen and tailored to create three neo-aortic sinuses. The commissures are suspended in the graft that is sutured to the cusp insertion lines and remnants of aortic wall tissue.

If valve reimplantation is planned the excision of aortic sinuses (as in remodeling technique) is followed by placing multiple horizontal mattress sutures just below the nadir of aortic annulus. They are passed from the inside to the outside of LVOT. The appropriate size of the graft is chosen and a small triangle may be cut out in order to accommodate the septal muscle below the commissure between left and right cups. The prepared sutures are passed through the graft and tied on the outside. The three commissures are suspended inside the graft and before the remnants of the aortic wall can be sutured to the graft one must carefully inspect the commissures and cusps to make sure they are all correctly aligned[20].

A crucial component of either aortic root remodeling or aortic valve reimplantation technique is assessment and repair-if necessary-of the AV.

Any residual cusp prolapse has been linked to increased risk of early failure of the aortic valve sparing procedure and the need for re-operation[21]. The best approach to intra-operative evaluation of any residual prolapse has been shown to be the objective measurement of effective height using a cusp caliper (Figure 5) [22].

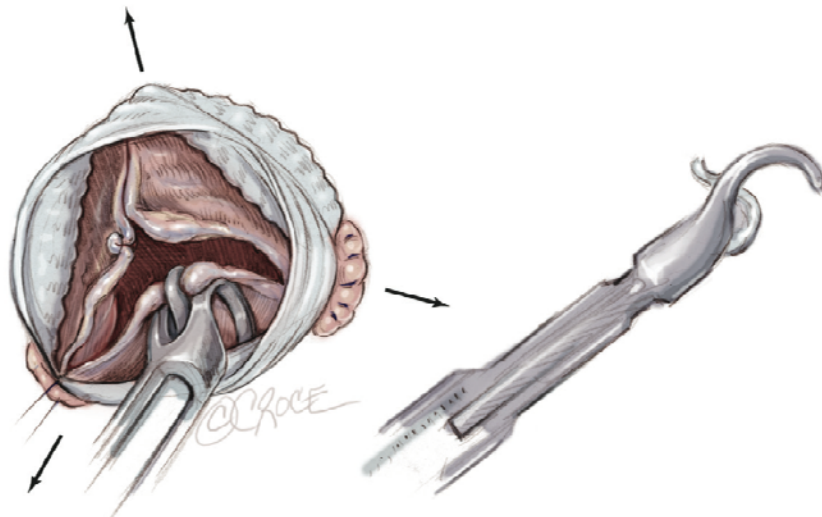


Figure 5: Resuspension of cusp effective height using a caliper as described by Schäfers et al.[23]

Both original VSRR procedures, which are described above, have undergone many modifications and improvements throughout the years. It was recognized that both have certain advantages and disadvantages. Studies have shown that the remodeling procedure provides more physiologic cusp motion and flow patterns but at the same time fails to address the annular dilation. The reimplantation technique, on the other hand, addresses the annular dilation but impairs the aortic root dynamics because it withdraws the sinuses of Valsava and includes the interleaflet triangles within the graft tube[24]. Numerous variations of both techniques have been proposed with the aim of preserving normal aortic root dynamics and simultaneously treating dilated annulus[25]. The widespread use of these modifications has been limited. Taking this into consideration, Lansac proposed a standardized approach to aortic valve repair associating physiologic remodeling of the root with resuspension of cusp effective height and subvalvular aortic annuloplasty with an external expansible ring (Figure 6). This ring was designed in order to

increase cusps coaptation height, reduce stress on the cusps and protect the repair[23].

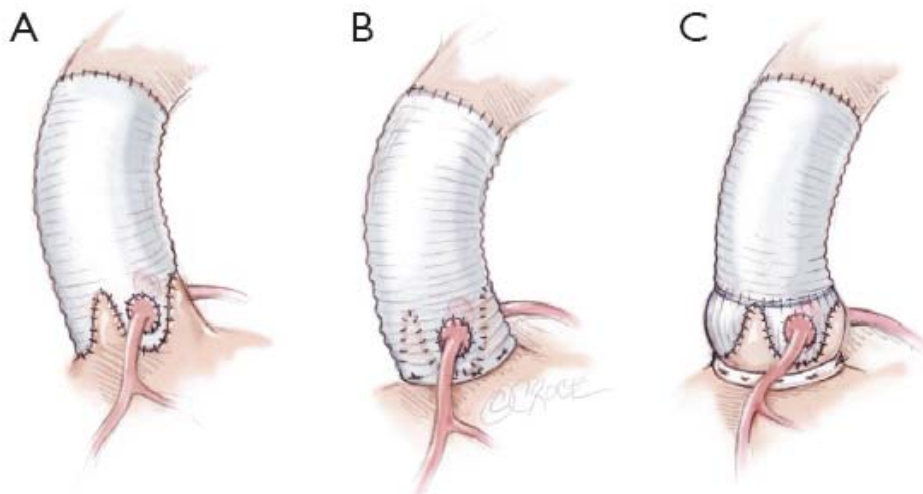


Figure 6: Standardized approach to aortic valve repair as proposed by Lansac (C), combining advantages of aortic root remodeling (A) and aortic valve reimplantation (B) [23].

AIM OF THE STUDY

Chronic AR sets numerous compensatory mechanisms in motion to accommodate for volume and pressure overload caused by regurgitating valve. LV eccentric hypertrophy with consecutive increase in LV dimensions happens in order for LV to be able to maintain normal left ventricular ejection fraction (LVEF). These adaptive mechanisms allow for relatively asymptomatic course of the disease. Over time the adaptive mechanisms fail and symptoms occur. Patients with severe LV dilatation and symptoms have poor survival if not treated appropriately.

Surgical intervention is recommended for all symptomatic patients or for asymptomatic patients with severely impaired LV function ($LVEF \leq 50\%$, $LVEDD > 70\text{mm}$ or $LVESD > 50\text{mm}$)[11].

The aim of this study was to evaluate changes in LV dimensions and function after AVR and AVRep and to prove that AVRep is just as suitable therapeutic option for AR with satisfactory postoperative outcomes in terms of left ventricular end-diastolic diameter (LVEDD) and LVEF when compared to AVR.

PATIENTS AND METHODS

This is a retrospective review of patients who underwent AVR or AVRep due to AR with or without aortic root aneurysm at the University Hospital Dubrava in Zagreb.

Study population

Between January 2013 and February 2016, 57 patients underwent surgery for treatment of AR that was either isolated or associated with aortic root dilation. Baseline demographic and clinical characteristics were collected before surgery and are summarized in Table 1.

The mean patient age was $53 \pm 13,7$ years. There were 47 (82%) male patients and 10 (18%) female patients.

There were 22 (39%) patients altogether with bicuspid aortic valve (BAV), 1 was suffering from Marfan syndrome and 4 (7%) patients developed AR as a consequence of endocarditis. 1 patient had AR associated with ventricular septal defect (VSD).

All patients were classified pre-operatively according to New York Heart association (NYHA) functional classification for heart failure. There were 10 (18%) patients in NYHA class I, 43 (75%) patients in NYHA class II, 4 (7%) patients in NYHA class III and none of the patients had NYHA class IV score. Predictive operative mortality was calculated according to European System for Cardiac Operative Risk Evaluation scoring system (EuroSCORE and EuroSCORE II). Mean logistic EuroSCORE was $5,84 \pm 0,03\%$ and mean EuroSCORE II was $2,95 \pm 0,02\%$.

Table 1: Baseline clinical characteristics

	AVR (n=32)	AVRep (n=25)	P value
Age	55±13,02	50±14,3	0,19
Female	6 (19)	4 (16)	0,79
Male	26 (81)	21 (84)	0,79
NYHA functional class			
I	4 (13)	6 (24)	0,4
II	25 (78)	18 (72)	0,4
III	3 (9)	1 (4)	0,4
IV	0	0	
EuroSCORE	5,75±0,03%	5,94±0,02%	0,81
EuroSCORE II	2,82±0,02%	3,13±0,02%	0,5
Bicuspid aortic valve	11 (34)	11 (44)	0,5
Marfan syndrome	0	1 (6)	
VSD	1 (3)	0	
Endocarditis	3 (9)	1 (4)	0,4

All data are presented as mean ± standard deviation or as number (percentage).

AVR: aortic valve replacement; AVRep: Aortic valve repair; NYHA: New York Heart Association; EuroSCORE: European System for Cardiac Operative Risk Evaluation; VSD: ventricular septal defect

Echocardiography

All patients underwent pre-operative transthoracic echocardiography (TTE) for assessment of AV anatomy and aortic root diameters (annulus, sinuses of Valsava, STJ and proximal ascending aorta) as well as dimensions and function of LV. M-mode and 2-dimensional echocardiography, as well as conventional and color Doppler data were acquired. Enlarged LVEDD was defined for values above 57mm. Impaired LVEF was defined for all values below 50%.

Mean pre-operative LVEF was $58,7 \pm 9,9$ % and mean pre-operative LVEDD was $62,2 \pm 8,9$ mm.

AR severity was assessed using a multiparametric approach that includes measurement of the jet width relative to the LV outflow tract width, vena contracta width and magnitude of the diastolic flow reversal in descending aorta when assessable according to current recommendations[14]. AR was classified as zero (grade 0), trivial (grade 1+), mild (grade 2+), moderate (grade 3+) and severe (grade 4+). Table 2 summarizes pre-operative AR grades.

Transesophageal echocardiography (TEE) was performed intraoperatively both before and after AVRep or AVR.

Table 2: Pre-operative aortic regurgitation grades

Aortic regurgitation grade	AVR	AVRep	P value
Trivial	1 (3)	1 (4)	0,3
Mild	2 (6)	6 (24)	0,3
Moderate	13 (41)	9 (36)	0,3
Severe	16 (50)	9 (36)	0,3

All data are presented as number (percentage).

AVR: aortic valve replacement; AVRep: aortic valve repair

Surgery

Attending surgeon together with cardiologist who evaluated the patient pre-operatively made the choice of most appropriate surgical technique.

AVR was performed in 32 (56%) patients. 10 (31%) patients underwent isolated replacement of AV and 22 patients (69%) had both AV and ascending aorta replaced. 21 (66%) mechanical valves and 11 (34%) bioprosthetic valves were implanted.

25 (44%) patients underwent AVRep. Most commonly performed AVRep technique was the one as described by Lansac (23 patients) [23]. There was 1 patient who underwent isolated valve repair with subvalvular aortic annuloplasty with external expandable ring and in 1 patient annular stabilization was done by subcommissural annuloplasty[26] rather than by subvalvular annuloplasty with external expandable ring. Effective height of each cusp was measured using a caliper in order to evaluate any residual or induced cusp prolapse during AVRep procedure.

Follow-up

Echocardiography was performed during the immediate post-operative period (within 7 days from operation) by the cardiologists working at the University Hospital Dubrava and at early follow up (within 6 months from operation) appointments by the cardiologists that were individually chosen by the patient. LVEDD and LVEF were measured and measures were compared to those obtained at the pre-operative echocardiographic evaluation.

Median echocardiographic follow up time was 6 months (IQR= 4 to 9 months). All patients were still alive at the time when this paper was written.

Statistical Analysis

Continuous variables are presented as mean \pm standard deviation or median with interquartile ranges (IQR). Categorical variables are reported as counts and percentages. Independent and paired student's t-tests were used for comparison of continuous variables when appropriate. Categorical variables were analyzed using χ^2 test.

All statistical analyses were performed using SPSS version 24.0 software.
Values of $p < 0,05$ were considered statistically significant.

RESULTS

Preoperative and operative data

Preoperative clinical characteristics of patients undergoing either AVR or AVRep were comparable (Table 1). The mean age at operation was similar between the two groups (AVR=55±13,02 vs AVRep=50±14,3, p=0,19) as well as proportion of male and female patients (6 females and 26 males in AVR group and 4 females and 21 males in AVRep group, p=0,79). There was also a comparable proportion of BAV among patients treated by AVR or AVRep (34% vs 44%, p=0,5).

No significant difference comparing predictive operative mortality calculated by EuroSCORE and EuroSCORE II (EuroSCORE: AVR=5,75±0,03% vs AVRep=5,94±0,02%, p=0,81. EuroSCORE II: AVR=2,82±0,02% vs AVRep=3,13±0,02%, p=0,5) scoring systems was noticed.

More patients with AR as a consequence of endocarditis were in AVR group (3 patients) compared to AVRep group (1 patient). 1 patient in AVRep group had AR as a consequence of Marfan syndrome.

Table 3 summarizes operative data. No patients died in the operative room. There were 2 patients who first underwent AVRep procedure but were re-operated due to poor echocardiographic results during immediate post-operative period and replacement of aortic valve together with aortic arch replacement was done.

The difference between cross clamp and pump times among groups was significant (Cross clamp time: AVR=80±31 vs AVRep=120,2±27,1, p<0,05. Pump time: AVR=117,8±42,1 vs AVRep=154,1±27,1, p<0,05).

2 (8%) patients in AVRep group had concomitant coronary artery by-pass grafting done and 1 (4%) patient had mitral valve (MV) repaired in addition to AVRep. There was 1 patient who underwent VSD closure together with AVR. Altogether 45 patients had concomitant aortic arch replacement, 22 (69%) in AVR group and 23 (92%) in AVRep group (p=0,01). 1 patient in AVRep group had aortic hemi-arch replacement done.

There were 17 (68%) patients in AVRep group who required additional cusp repair (plication of the free edge of the leaflet, fenestration closure).

Table 3: Operative data

	AVR (n=32)	AVRep (n=25)	P value
Cross clamp time, min	80±31	120,2±27,1	<0,05
Pump time, min	117,8±42,1	154,1±27,1	<0,05
Type of valve			
Mechanical	21 (66)		
Bioprosthetic	11 (34)		
Associated surgical procedures			
CABG		2 (8)	
Ascending aorta replacement	22 (69)	23 (92)	0,01
Hemiarch		1 (4)	
MVRep		1 (4)	
VSD closure	1 (3)		
Additional aortic cusp repair		17 (68)	

All data are presented as mean ± standard deviation or as number (percentage).

AVR: aortic valve replacement; AVRep: Aortic valve repair; CABG: coronary artery by-pass grafting; MVRep: Mitral Valve repair; VSD: Ventricular Septal Defect

Echocardiography

Complete echocardiographic follow up data could be obtained in all but 15 patients (7 in AVR group and 8 in AVRep group).

Figure 7 shows how AR severity grade changed over time. AR severity grades were comparable among groups both pre-operatively and post-operatively ($p=0,3$ for both). There was 1 patient in AVRep group who had mild AR during immediate post-operative period, all other patients left the hospital with zero to trivial AR. During follow up period AR grade in AVR group remained zero to trivial for all patients, whereas in AVRep group 5 additional patients had mild AR.

Table 4 summarizes echocardiographic parameters as measured pre-operatively, immediately post-operatively and at follow up appointments. Both pre-operative LVEDD and LVEF were comparable between groups. Mean pre-operative LVEDD in AVR was $62,6 \pm 8,7$ mm and in AVRep group $61,6 \pm 9,3$ mm ($p=0,7$). In both groups we can notice a significant decrease in post-operative LVEDD in comparison to pre-operative LVEDD (AVR= $58,2 \pm 7,4$ mm vs AVRep= $56,5 \pm 9,2$ mm, $p=0,4$). LVEDD further decreased at early follow-up (AVR= $53,5 \pm 5,4$ mm vs AVRep= $52,9 \pm 4,8$ mm, $p=0,7$).

LVEF decreased in both groups immediately post-operatively, which can be explained by acute correction of volume overload. However, at early follow-up LVEF normalized (AVR= $59,4 \pm 7,8\%$ vs AVRep= $63,1 \pm 7,5\%$, $p=0,1$) in both groups.

Figure 8 illustrates how LVEDD and LVEF changed over time in both groups.

Table 4: Echocardiographic data

	AVR (n=32)	AVRep (n=25)	P value
LVEDD (mm)			
Pre-operative	62,6±8,7	61,6±9,3	0,7
Post-operative	58,2±7,4 [*]	56,5±9,2 [*]	0,4
Follow up	53,5±5,4 ^{*,†}	52,9±4,8 [*]	0,7
LVEF (%)			
Pre-operative	56,9±9,3	61±10,4	0,1
Post-operative	53,6±10,8 [*]	57,2±10,1 [*]	0,2
Follow up	59,4±7,8 ^{*,†}	63,1±7,5	0,1

All data are presented as mean ± standard deviation.

AVR: aortic valve replacement; AVRep: aortic valve repair; LVEDD: left ventricular end-diastolic diameter; LVEF: Left ventricular ejection fraction

Within groups:

*p<0,05 versus pre-operative

†p<0,05 versus post-operative

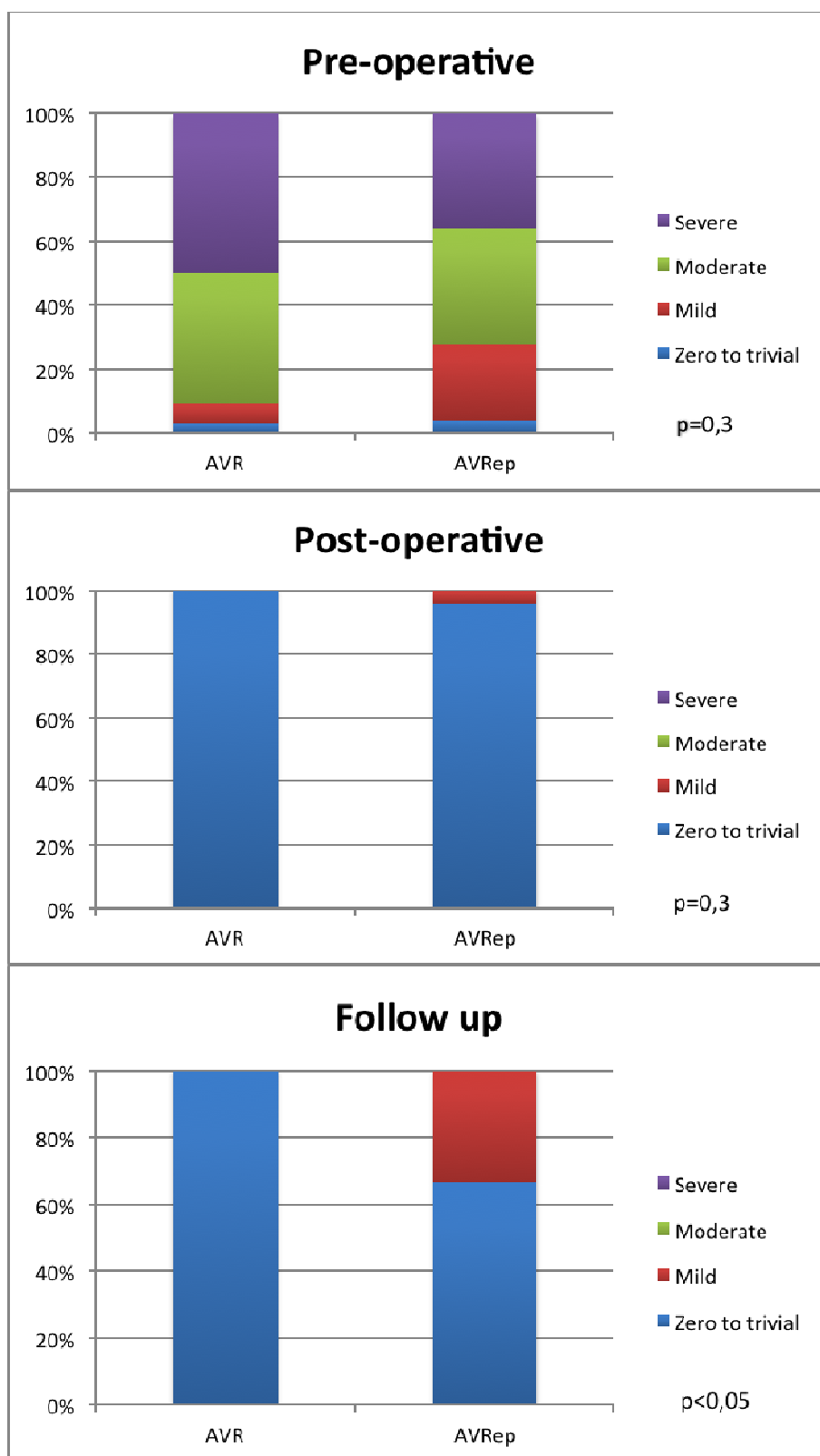


Figure 7: Aortic regurgitation severity grades over time. Data are displayed as percentages per group. AVR: aortic valve replacement; AVRep: aortic valve repair

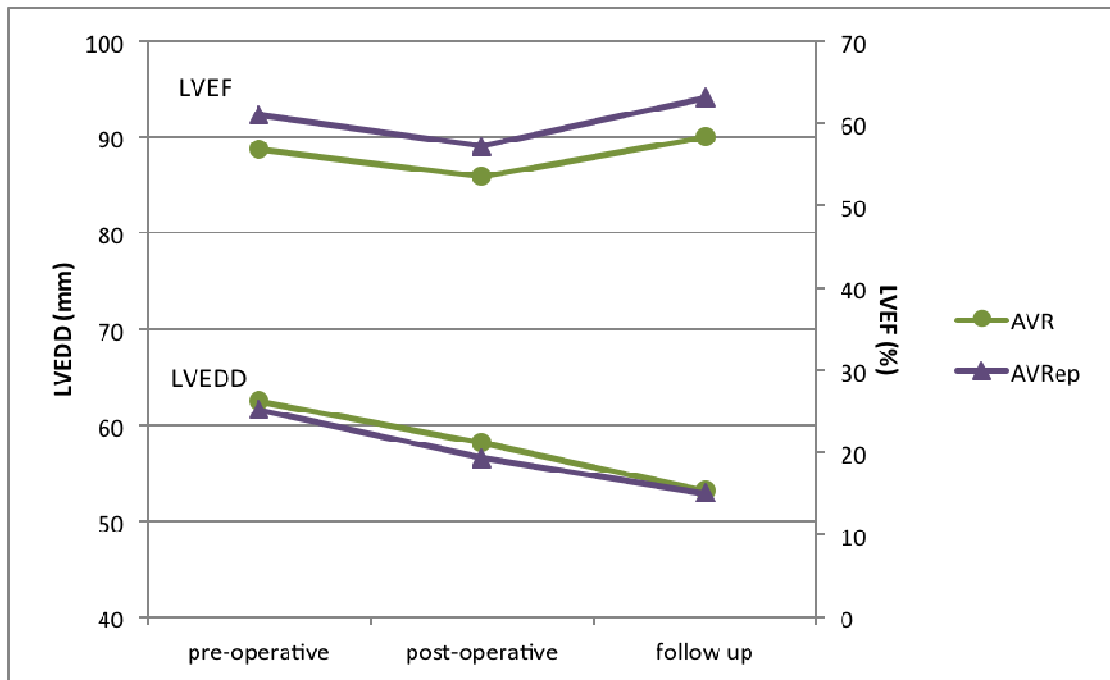


Figure 8: Left ventricular end-dastolic diameter and left ventricular ejection fraction over time in aortic valve replacement compared to aortic valve repair. Data are displayed as estimated means. LVEDD: left ventricular end-diastolic volume; LVEF: left ventricular ejection fraction; AVR: aortic valve replacement; AVRep: aortic valve repair.

DISCUSSION

This study was performed to compare the effects of AVRep versus AVR operations on LV dimensions and function immediately post-operatively and at early follow up. Immediately post-operatively a significant decrease in LVEDD has been noted in AVRep group as well as in AVR group with further decrease at early follow-up. LVEF was lower in both groups immediately post-operatively in comparison to pre-operatively but normalized at early follow up. There is no doubt that AVRep techniques are an attractive alternative to AVR surgery in order to avoid risks of prosthetic valve such as thromboembolism, structural deterioration, endocarditis and hemorrhagic events connected to long-term anticoagulation therapy.

One could argue the decision of sparing the AV leaflets that have suffered from years of chronic AR instead of replacing the valve with either mechanical or biologic prosthesis, since there is a possibility of failing to restore the normal competence of AV and thus failing to remove the volume overload on LV.

Recent improvements in understanding functional anatomy of aortic root and physiology of aortic valve with appreciation of importance of adjacent structures have lead to favorable outcomes of valve sparing aortic root replacement techniques with or without AV repair in terms of overall survival, freedom from reoperation and freedom from AR grade>2 at follow up[27][28]. Risk factors leading to potential failure of valve preserving procedures have been identified and techniques to correct those possible factors leading to failure of valve sparing operations have been proposed and applied with favorable outcomes[21][29]. With further experience the repair techniques have been successfully applied even in patients with BAV[30].

Comparison of AVR and AVRep techniques has led to the conclusion that both lead to similar survival rates but AVRep is connected to lower rates of valve-related complications, such as thromboembolism, bleeding and endocarditis[31][32].

Even though the above-mentioned studies show satisfying results after AVRep operations, the lack of technical standardization of the AVRep

techniques limits their widespread use and reproducibility. Taking this into consideration, Lansac et al. proposed the before-mentioned standardized approach to AV repair with the aim of defining the actual best surgical strategy when it comes to treatment of aortic root aneurysm with or without AV disease.

AR imposes a volume overload on heart, which responds to it by LV remodeling. Chronic long standing AR is relatively well compensated by LV remodeling and can be well tolerated for a significant amount of time. However, if left untreated, the compensating mechanism eventually fails and LVEF decreases. Patients become symptomatic and have poor survival if remaining under medical treatment only. Several studies have shown changes in LV dimensions and function after AVR operations for treatment of AR. Already back in 1978, a study made by Gaasch et al.[33] reported of postoperative LVEDD decrease after AVR. Tanoue et al.[34] showed that LV contractility increased in 93 patients who underwent AVR as treatment for AR. They have also noticed change in LVEDD and LVEF. LVEDD changed from 64.3 ± 9.2 mm pre-operatively to 52.3 ± 9.9 mm directly post-operatively and to 48.4 ± 9.0 mm at 1-year follow up. LVEF showed decrease from pre-operatively 60.2 ± 11.0 % to post-operatively 51.9 ± 14.6 % but later stabilization at 1-year follow up to 57.9 ± 15.2 %. Cho SH et al.[35] also observed similar changes in terms of LVEF and LVEDD.

A few studies have described changes in LV function and volumes after AVRep procedures[36][37]. A. Mangini et al. [37] have observed a decrease of LVEDD from 55.54 ± 7.95 mm pre-operatively to 50.90 ± 7.8 mm post-operatively and to 51.29 ± 6.26 mm. There was slight increase of LVEDD at follow up but it was still statistically different when compared to pre-operative measures. When observing the EF they have noticed a decrease from 57.83 ± 9.8 % pre-operatively to 55.09 ± 10.43 % post-operatively and later complete restoration to 59.73 ± 8.2 % at follow up.

In this study I have made a further insight into LV function and volume changes after both AVR and AVRep by comparing outcomes of patients undergoing AVR or AVRep for treatment of AR. Both groups have shown significant decrease in LV dimensions post-operatively with further decrease at early follow up appointments. The LV function in terms of LVEF has

decreased post-operatively, which was probably the consequence of acute correction of volume overload, but has normalized at early follow up in both groups. These results show us that durable AV repair in patients with AR with or without aortic root aneurysm is connected with beneficial outcome in terms of LV reverse remodeling and preserved LVEF immediately post-operatively and at early follow up.

There are several limitations to this study that should be acknowledged. First, this is a retrospective and non-randomized study. There has also been quite a big loss due to follow up. Follow up data were difficult to collect due to lack of patients' participation during follow up process and despite multiple attempts to reach patients through telephone some did not answer.

In addition, the AVRep is a demanding procedure and the learning process is long. The surgeons in University Hospital Dubrava have only recently started performing the technique as described by Lansac et al. and despite good results until now, there is no doubt that there is room for improvement.

CONCLUSION

One could argue the idea of conservative approach to repairing the regurgitant valve rather than replacing it, as there is a significant risk of unsuccessful restoration of normal coaptation of leaflets and potential need for reoperation. The results of mitral valve repair have lead to mitral valve repair becoming superior to mitral valve replacement when dealing with mitral valve regurgitation. Even though AVR are known for technically easier, widely reproducible and applicable operations in comparison to AVRep techniques, the positive results of mitral valve repair have greatly influenced progress of AVRep techniques over the past 20 years.

Theoretical benefits of native aortic valve repair rather than replacement with prosthesis and thus subjecting the patient to prosthesis related complications, such as thromboembolism, endocarditis and hemorrhage, have also been the reason for continuous improvements made in the field of AVRep techniques. Significant amount of knowledge has been gained over the past 20 years about the precise anatomy and physiology of AV and the importance of supporting structures for normal leaflet movements. Risk factors for potential failure of repair have been identified and various techniques have been proposed to approach them. This has led to good results in terms of freedom of reoperation and overall survival.

It has been shown by this study that successful repair of AV leads to reverse remodeling of LV and improved LV function, which is comparable to LV remodeling seen after AVR.

ACKNOWLEDGEMENTS

I would like to thank prof. dr. sc. Željko Sutlić for agreeing to be my mentor on this thesis and his assistance in this regard. My sincere gratitude goes to doc.dr.sc. Igor Rudež for his encouragement and selfless guidance throughout the whole process of writing this thesis. Many thanks to mr.sc. Davor Barić and dr. Josip Varvodić for their help.

Last, but not least, thanks to my parents for their support throughout my studies and for believing in me even when I stopped believing in myself.

REFERENCES

1. Ross D. Surgical reconstruction of the aortic valve. *Lancet*. 1963;1(7281):571–4.
2. Carpentier A. Cardiac valve surgery--the "French correction." *J Thorac Cardiovasc Surg*. 1983;86(3):323–37.
3. Ikonomidis JS, Kratz JM, Crumbley AJ, Stroud MR, Bradley SM, Sade RM, et al. Twenty-year experience with the St Jude Medical mechanical valve prosthesis. *J Thorac Cardiovasc Surg*. 2003;126(6):2022–31.
4. Aicher D, Holz A, Feldner S, Köllner V, Schäfers HJ. Quality of life after aortic valve surgery: Replacement versus reconstruction. *J Thorac Cardiovasc Surg*. 2011;142(2):19–24.
5. Charitos EI, Sievers H-H. Anatomy of the aortic root: implications for valve-sparing surgery. *Ann Cardiothorac Surg*. 2013;2(1):53–6.
6. Anderson RH. The surgical anatomy of the aortic root. *Multimed Man Cardiothorac Surg MMCTS / Eur Assoc Cardio-Thoracic Surg*. 2007;2007(102):mmcts.2006.002527.
7. Anderson R. Clinical anatomy of the aortic root. *Heart*. 2000;84:670–3.
8. Lansac E, Di Cerna I, Raoux F, Bulman-Fleming N, Ranga A, Abed A, et al. An expansible aortic ring for a physiological approach to conservative aortic valve surgery. *J Thorac Cardiovasc Surg*. 2009;138(3):718–24.
9. Kerchoue L De, Khoury G EI. Anatomy and pathophysiology of the ventriculo-aortic junction□: implication in aortic valve repair surgery. 2013;2(5):57–64.
10. Mihaljevic T, Sayeed MR, Stamou SC, Paul S. Pathophysiology of Aortic Valve Disease. In: Cohn L, editor. *Cardiac Surgery in the Adult*. 3rd ed. New York: McGraw-Hill Medical Publishing Division; 2008. p. 825–40.
11. Vahanian A, Alfieri O, Andreotti F, Antunes MJ, Barón-Esquivias G, Baumgartner H, et al. Guidelines on the management of valvular heart disease (version 2012). *Eur Heart J*. 2012;33(19):2451–96.

12. Le Polain De Waroux JB, Pouleur AC, Goffinet C, Vancraeynest D, Van Dyck M, Robert A, et al. Functional anatomy of aortic regurgitation: Accuracy, prediction of surgical repairability, and outcome implications of transesophageal echocardiography. *Circulation*. 2007;116(11 SUPPL. 1).
13. Schäfers HJ, Bierbach B, Aicher D. A new approach to the assessment of aortic cusp geometry. *J Thorac Cardiovasc Surg*. 2006;132(2):436–8.
14. Lancellotti P, Moura L, Pierard LA, Agricola E, Popescu BA, Tribouilloy C, et al. European association of echocardiography recommendations for the assessment of valvular regurgitation. Part 1: aortic and pulmonary regurgitation (native valve disease). *Eur J Echocardiogr*. 2010;11(4):307–32.
15. Boodhwani M, de Kerchove L, Glineur D, Poncelet A, Rubay J, Astarci P, et al. Repair-oriented classification of aortic insufficiency: impact on surgical techniques and clinical outcomes. *J Thorac Cardiovasc Surg*. 2009;137(2):286–94.
16. Schäfers HJ, Langer F, Glombitza P, Kuniyara T, Fries R, Aicher D. Aortic valve reconstruction in myxomatous degeneration of aortic valves: Are fenestrations a risk factor for repair failure? *J Thorac Cardiovasc Surg*. 2010;139(3):660–4.
17. Schäfers HJ. Aortic annuloplasty: A new aspect of aortic valve repair. *Eur J Cardio-thoracic Surg*. 2012;41(5):1124–5.
18. Yacoub MH, Gehle P, Chandrasekaran V, Birks EJ, Child A, Radley-Smith R, et al. Late results of a valve-preserving operation in patients with aneurysms of the ascending aorta and root. *J Thorac Cardiovasc Surg*. 1998;115(5):1080–90.
19. David TE. How i do aortic valve sparing operations to treat aortic root aneurysm. *J Card Surg*. 2011;26(1):92–9.
20. David TE. Aortic Valve Repair and Aortic Valve-Sparing Operations. In: Cohn LH, editor. *Cardiac Surgery in the Adult*. 3rd ed. New York: McGraw-Hill Medical Publishing Division; 2008. p. 935–47.
21. Pethig K, Milz A, Hagl C, Harringer W, Haverich A. Aortic valve reimplantation in ascending aortic aneurysm: Risk factors for early valve failure. *Ann Thorac Surg*. 2002;73(1):29–33.

22. Lansac E, Di Cerna I, Sleilaty G, Crozat EA, Bouchot O, Hacini R, et al. An aortic ring: From physiologic reconstruction of the root to a standardized approach for aortic valve repair. *J Thorac Cardiovasc Surg.* 2010;140(6 SUPPL.).
23. Lansac E, Di Cerna I, Vojacek J, Nijs J, Hlubocky J, Mecozzi G, et al. Valve sparing root replacement: the remodeling technique with external ring annuloplasty. *Ann Cardiothorac Surg.* 2013;2(19):117–23.
24. Leyh RG, Schmidtke C, Sievers HH, Yacoub MH. Opening and closing characteristics of the aortic valve after different types of valve-preserving surgery. *Circulation.* 1999;100(21):2153–60.
25. Hopkins RA. Aortic valve leaflet sparing and salvage surgery: Evolution of techniques for aortic root reconstruction. *Eur J Cardio-thoracic Surg.* 2003;24(6):886–97.
26. Boodhwani M, de Kerchove L, Glineur D, Noirhomme P, El Khoury G. Repair of aortic valve cusp prolapse. *Multimed Man Cardiothorac Surg MMCTS / Eur Assoc Cardio-Thoracic Surg.* 2009;2009(702):mmcts.2008.003806.
27. Saczkowski R, Malas T, de Kerchove L, El Khoury G, Boodhwani M. Systematic review of aortic valve preservation and repair. *Ann Cardiothorac Surg.* 2013;2(1):3–9.
28. Aicher D, Langer F, Lausberg H, Bierbach B, Schäfers HJ. Aortic root remodeling: Ten-year experience with 274 patients. *J Thorac Cardiovasc Surg.* 2007;134(4):909–15.
29. le Polain de Waroux J-BP. Mechanisms of Recurrent Aortic Regurgitation After Aortic Valve Repair. Predictive Value of Intraoperative Transesophageal Echocardiography. *Jacc Cardiovasc Imaging.* American College of Cardiology Foundation; 2009;2(8):931–9.
30. Aicher D, Kuniyara T, Abou Issa O, Brittner B, Gräber S, Schäfers HJ. Valve configuration determines long-term results after repair of the bicuspid aortic valve. *Circulation.* 2011;123(2):178–85.
31. Aicher D, Fries R, Rodionychewa S, Schmidt K, Langer F, Scha H. Aortic valve repair leads to a low incidence of valve-related complications. 2010;37(February 2007):127–32.

32. Price J, De Kerchove L, Glineur D, Vanoverschelde JL, Noirhomme P, El Khoury G. Risk of valve-related events after aortic valve repair. *Ann Thorac Surg*. Elsevier Inc.; 2013;95(2):606–13.
33. Gaasch WH, Andrias CW, Levine HJ. Chronic aortic regurgitation: the effect of aortic valve replacement on left ventricular volume, mass and function. *Circulation*. 1978;58(5):825–36.
34. Tanoue Y, Maeda T, Oda S, Baba H, Oishi Y, Tokunaga S, et al. Left ventricular performance in aortic valve replacement. *Interact Cardiovasc Thorac Surg*. 2009;9(2):255–9.
35. Cho S-H, Byun C-S, Kim K-W, Chang B-C, Yoo K-J, Lee S. Preoperative indexed left ventricular dimensions to predict early recovery of left ventricular function after aortic valve replacement for chronic aortic regurgitation. *Circ J*. 2010;74(11):2340–5.
36. Regeer M V., Versteegh MIM, Klautz RJM, Stijnen T, Schali J MJ, Bax JJ, et al. Aortic valve repair versus replacement for aortic regurgitation: Effects on left ventricular remodeling. *J Card Surg*. 2015;30(1):13–9.
37. Mangini A, Contino M, Romagnoni C, Lemma M, Gelpi G, Vanelli P, et al. Aortic valve repair: A ten-year single-centre experience. *Interact Cardiovasc Thorac Surg*. 2014;19(1):28–35.

BIOGRAPHY

Polona Koritnik was born on March 8th 1992 in Ljubljana, Slovenia. She finished her high school education at Gimnazija Vič, Ljubljana in 2010. In academic year 2010/2011 she started studying medicine at the University of Zagreb where she is currently enrolled in her final year of study.

Before enrolling into Medical school sport has been a big part of her life. She has been a professional figure skater for 13 years and in 2003 she won Slovenian National Championship. Even after finishing her figure skating career, sport remains important part of her life.

During her studies she was a student demonstrator at the Department of Cardiology in academic years 2014/2015 and 2015/2016.