

Recent advances in understanding the pathogenesis of rosacea

Faruqui, Ibad Ahmad

Master's thesis / Diplomski rad

2017

Degree Grantor / Ustanova koja je dodijelila akademski / stručni stupanj: **University of Zagreb, School of Medicine / Sveučilište u Zagrebu, Medicinski fakultet**

Permanent link / Trajna poveznica: <https://um.nsk.hr/um:nbn:hr:105:779969>

Rights / Prava: [In copyright](#)/[Zaštićeno autorskim pravom.](#)

Download date / Datum preuzimanja: **2024-09-21**



Repository / Repozitorij:

[Dr Med - University of Zagreb School of Medicine Digital Repository](#)



**UNIVERSITY OF ZAGREB
SCHOOL OF MEDICINE**

Ibad Ahmad Faruqi

**Recent advances in understanding the
pathogenesis of rosacea**

GRADUATE THESIS



Zagreb, 2017.

This graduate thesis was made at the Department of Dermatology and Venereology mentored by Professor Zrinka Bukvić Mokos, MD, PhD and was submitted for evaluation in academic year 2016/2017.

Mentor: Professor Zrinka Bukvić Mokos, MD, PhD

ABBREVIATIONS

AMP: antimicrobial peptide

Cag A: cytotoxin-associated gene A

CAMP: cathelicidin AMP

ETR: erythematotelangiectatic rosacea

IL: interleukin

KLK-5: kallikrein 5

MMP: matrix-metalloproteinase

PPR: papulopustular rosacea

SCTE: stratum corneum tryptic enzyme

TLR-2: Toll-like receptor-2

TNF α : tumor-necrosis factor α

UV: ultraviolet radiation

VEGF: vascular endothelial growth factor

CONTENTS

1. SUMMARY	
2. SAŽETAK	
3. INTRODUCTION	1
4. EPIDEMIOLOGY	2
5. CLINICAL PRESENTATION	2
5.1. Erythematotelangeictatic rosacea	4
5.2. Papulopustular rosacea	4
5.3. Phymatous rosacea	4
5.4. Ocular rosacea	5
6. PATHOGENETIC FACTORS	5
6.1. The role of innate immune system	6
6.1.1. Antimicrobial peptides	6
6.1.2. TLR-2 and KLK-5	8
6.1.3. Epidermal barrier disruption	10
6.2. Neuroimmune and neurovascular pathways	11
6.3. Microbial pathways	14
6.3.1. Helicobacter pylori	14
6.3.2. Demodex folliculorum	16
6.3.3. Bacillus oleronius	17
6.3.4. Staphylococcus epidermidis	17
6.4. UV radiation	18
7. RISK FACTORS	19
8. CONCLUSION	20
9. REFERENCES	21
10. ACKNOWLEDGEMENTS	26
11. BIOGRAPHY	27

1. SUMMARY

Rosacea is a common, chronic inflammatory skin disease that affects the central portions of the face, such as forehead, the chin and the lower half of the nose. This graduate thesis will delve into the existing scientific literature that attempts to recognize the pathophysiologic pathways leading to rosacea manifestation. Even though rosacea is one of the most common conditions encountered by dermatologists worldwide, the etiopathogenesis of this inflammatory disease remains somewhat of a mystery. Researches dedicated to epidemiological investigations undeniably point towards a genetic factor; however, no “rosacea gene” has been recognised to date. Although rosacea has a high prevalence among fair-skinned individuals, recent reports show that it can occur in other skin phenotypes as well. While four clinical subtypes have been designated, it is still unknown if the subtypes are a representation of the different developmental stages of the disease or simply manifestations of a syndrome that clinically overlap.

This paper classified pathophysiological mechanisms of rosacea as either being the outcome of innate immune dysfunctions, neuroimmune and neurovascular interactions, ultraviolet radiation, and lastly, microbial causation. Many investigative and observational studies have been undertaken in the past few decades to pinpoint the precise pathophysiological pathway, especially clarifying the pivotal role of innate immunity dysfunction in the development of rosacea.

Keywords: rosacea, pathophysiology, innate immunity, vascular system, ultraviolet radiation

2. SAŽETAK

Rozaceja je česta kronična bolest koja zahvaća središnji dio lica, uključujući čelo, bradu i donji dio nosa. Ovaj diplomski rad obuhvatit će pregled znanstvene literature kojom su se pokušali prepoznati patofiziološki putovi koji dovode do manifestacije rozaceje. Iako je rozaceja jedna od najčešćih bolesti s kojima se susreću dermatolozi širom svijeta, etiopatogeneza ove upalne bolesti ostaje svojevrsna zagonetka.

Istraživači koji su provodili epidemiološka istraživanja nedvojbeno ukazuju na genetski čimbenik; međutim, do danas nije otkriven "gen za rozaceju". Iako rozaceja ima visoku prevalenciju među osobama sa svijetlim tenom, nedavna izvješća pokazuju da se može pojaviti i kod drugih kožnih fenotipova. Iako se razlikuju se četiri klinička podtipa bolesti, još uvijek nije jasno radi li se o različitim razvojnim fazama bolesti ili jednostavno manifestacijama jednog sindroma koje se klinički preklapaju.

U ovom radu klasificirani su patofiziološki mehanizmi rozaceje, uključujući poremećaj funkcije urođene imunosti, neuroimune i neurovaskularne interakcije, ultraljubičasto zračenje, i konačno, mikroorganizme kao etiološke čimbenike. U posljednjih nekoliko desetljeća provedena su brojna istraživanja i opservacijske studije kako bi se utvrdio precizan patofiziološki mehanizam bolesti, osobito pojašnjavajući ključnu ulogu poremećaja urođene imunosti u razvoju rozaceje.

Ključne riječi: rozaceja, patofiziologija, urođena imunost, krvožilni sustav, ultraljubičasto zračenje

3. INTRODUCTION

Rosacea is a common, chronic inflammatory skin disease that primarily affects the central face convexities, typically characterized by remissions and exacerbations. The synonym “acne rosacea” has been traditionally used for this condition, reflecting the occurrence of facial papules and pustule in both conditions. However, today it is recommended that the term “acne rosacea” should be avoided, because both etiology and pathology of rosacea are distinct from acne vulgaris.

As rosacea encompasses a constellation of different signs and symptoms, a completely satisfactory definition of rosacea is still lacking. The attempt to define diagnostic criteria was made by National Rosacea Society Expert Committee, who proposed that rosacea may be diagnosed when on or more primary signs are present on the central face. Primary features include transient or persistent erythema, papules and pustules, and telangiectasia. (Wilkin, 2002). Additional, secondary features, include burning or stinging, rough and scaly appearance, edema, red plaques, peripheral localization, ocular symptoms, and phymatous lesions. Opposite to this opinion, some authors found that these criteria are specific enough. They have thus proposed that the most characteristic feature of rosacea is a persistent centrofacial erythema lasting at least 3 months with a tendency to exempt periocular area (Crawford, 2004).

While rosacea was identified hundreds of years ago, its pathophysiology remains to be completely understood till today. Currently projected etiological mechanisms include but are not limited to the aberrant innate immune system, ultraviolet (UV) radiation, vascular changes, epidermal barrier dysfunction, neurogenic

inflammation and microbes. Nevertheless, a fundamentally incomprehensible contradiction continues to be unsolved; how can the diverse clinical presentation of rosacea be explained by a solitary systematic theory? Several pathophysiological theories will be discussed later in this paper.

Since it affects the face, rosacea negatively impacts the quality of life of the affected patients to a great extent.

4. EPIDEMIOLOGY

Rosacea is a very common skin disease. Although diagnosed in all skin types, rosacea is considered more common in fair-skinned than in darker individuals. The prevalence in Northern and Eastern European descent has been estimated at 2%–10% (Goldberg, 2013). It has been reported that rosacea accounts for 1.2% of dermatological consultations in Greece. However, large epidemiological studies have sometimes suffered from the lack of precise definition of this disease.

Rosacea affects women nearly three times more commonly than men. On the other hand, rhinophyma occurs predominantly in male patients.

Rosacea is most frequently diagnosed within the age range 36-50 years, but it can affect the individuals of all ages, including occasionally children.

5. CLINICAL PRESENTATION

Rosacea is a polymorphic disease that characteristically affects the central portions of the central convex areas of the face (nose, cheeks, forehead and chin). The

National Rosacea Society Expert Committee provided the standard organisation system for clinical variants of rosacea in 2002 (Wilkin, 2002). Since then, rosacea has characteristically been categorised into four major subtypes: erythematotelangiectatic rosacea, papulopustular rosacea, phymatous (fibrotic) type, and ocular rosacea (Table 1).

SUBTYPE OF ROSACEA	CLINICAL FEATURES
ERYTHEMATOTELANGIECTATIC	<ul style="list-style-type: none"> • Persistent centrofacial erythema • History of flushing • Telangiectasias
PAPULOPUSTULAR	<ul style="list-style-type: none"> • Persistent centrofacial erythema • Papules • Pustules
PHYMATOUS	<ul style="list-style-type: none"> • Thickened skin • Irregular surface nodularities • Glandular hyperplasia • Fibrosis
OCULAR	<ul style="list-style-type: none"> • Blepharitis • Conjunctivitis • Foreign body sensation • Light sensitivity • Dryness, itching, burning or stinging • Chalazia

Table 1. Subtypes of rosacea.

5.1. ERYTHEMATOTELANGEICTATIC ROSACEA

Erythematotelangiectatic rosacea (ETR) is characterized by persistent centrofacial erythema and a long history of episodes of flushing in response to different stimuli (the extremes of environmental temperatures, spicy foods, hot drinks, alcohol, exercise, emotional stress etc.). In most patients telangiectasias are present, but these are not required for diagnosis. Besides the central convexities of the face, the other areas may be affected by redness, including ears, neck, and chest. Typically, periocular area is spared (Powell, 2012).

5.2. PAPULOPUSTULAR ROSACEA

Patient with papulopustular rosacea (PPR) typically present with persistent central facial erythema with multiple, dome-shaped, small erythematous papules and pustules, sparing the periocular regions. The patients may complain of burning and stinging. Telangiectasias are usually not prominent as they are commonly obscured by the erythema in the background.

This type of rosacea should not be confused with acne vulgaris, which is characterized by the presence of comedones, which are not the feature of rosacea (Berth-Jones, 2010).

5.3. PHYMATOUS ROSACEA

This subtype is defined by thickened, nodular skin with irregular surface and enlargement. Phymatous rosacea occurs most commonly on the nose (rhinophyma),

but less commonly may affect the chin (gnatophyma), forehead (metophyma), ears (otophyma), and eyelids (blepharophyma). Rhinophyma is predominantly observed in male patients. It does not represent the ultimate stage of rosacea as many patients have a history of mild rosacea or no preceding rosacea. The appearance of prominent pores on the nose is the earliest sign of rhinophyma. Based on the clinical and histological differences, four variants of rinophyma have been recognized, including glandular, fibrous, fibroangiomaticous, and actinic type (Berth-Jones, 2010).

5.4. OCULAR ROSACEA

Ocular rosacea may occur in patients with any of the other three subtypes of rosacea, but also may be present without accompanying cutaneous findings. In the cases of isolated ocular symptoms, the diagnosis of ocular rosacea is difficult to make. There is a wide spectar of ocular symptoms that can be observed in ocular rosacea. The most common presentation of this subtype are blepharitis and conjunctivitis. Additional findings may include foreign body sensation, dryness, itching, burning or stinging, light sensitivity, and conjunctival telangiectasias. Eyelid and periocular erythema also may occur. Meibomian gland dysfunction and recurrent chalazia are common. Most patients require an ophthalmologic consultation regarding to treatment (Powell, 2012).

6. PATHOGENETIC FACTORS

Concepts of rosacea's etiology have been inferred from a scientific observation of suspected elements, giving new understandings to the pathogenesis of rosacea. A

fresh upsurge in research in this area has considerably progressed the understandings of this disease's pathways. The authors of most studies discussed the following factors of pathogenesis associated with rosacea: innate immunity dysfunction, vascular aberrations, neuropeptides, various microorganisms, reactive oxygen species due to ultraviolet radiation, environmental factors, modifications in temperature, chemical irritability, emotional upsurges, alcoholic consumption, and ingestion of spicy food (Mc Aleer, Lacey and Powell, 2009).

Rosacea represents, in fact, a fascinating clinical and histopathological disease model for research regarding the associations that exist between the immune, vascular, and nervous systems. Innate immune processes and neurovascular system dysfunctions contribute to the occurrence of rosacea and its progression, even though the multifaceted grid of primary initiation and secondary response of neuroimmune communication needs to be better understood.

6.1. THE ROLE OF THE INNATE IMMUNE SYSTEM

6.1.1. Antimicrobial peptides

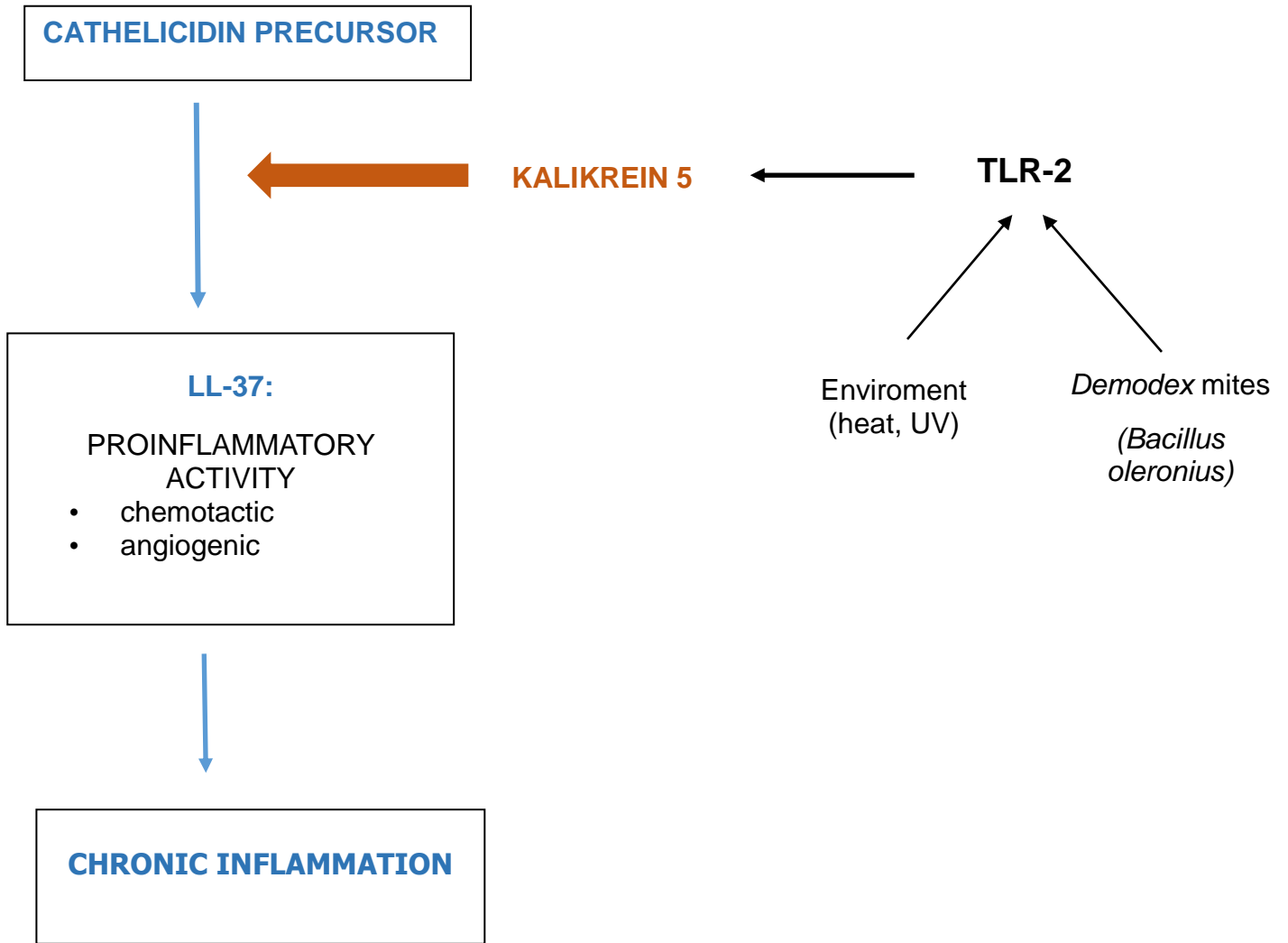
The innate immune system plays a vital role in skin defense through the keratinocytes which are capable to interact with each other upon microbial danger. This interaction in between the keratinocytes can lead to immune-activating cascades, providing a coordinated immune response and thereby secretion of antimicrobial peptides (AMPs), the soluble defense factors in the skin (Schauber, Gallo, 2007). AMPs

were initially recognized as endogenous antibiotics because of their potential to kill various pathogens. The production of AMPs in the skin is significantly amplified in dangerous situations such as skin injury or infections. Furthermore, since most AMPs are synthesized as propeptides and activated after proteolytic cleavage from their precursor molecules, signifies the extensive regulation of AMPs at the translational and posttranscriptional levels required for the skin to produce these peptides (Yamasaki et al., 2006). In well-studied groups of AMPs in human skin are the family of defensins and cathelicidins, latter of which only a single gene has been identified in humans, the cathelicidin AMP or (CAMP). The first active cathelicidin is derived from a propeptide termed LL-37, which is mainly composed of N- and C-terminal peptides that grant it antimicrobial properties (Gudmundsson et al., 1996). Along with its antimicrobial role, LL-37 can enhance various innate immune processes such as an increased liberation of cytokine and chemokine from local cells and leukocytes. Additionally, LL-37 affects angiogenesis by augmenting the proliferation of endothelial cells. Yamasaki et al. (2007) revealed that symptoms of rosacea are aggravated by the discharge of cathelicidin. Individuals with rosacea demonstrably present with unusually great quantities of cathelicidin in their facial dermis. Furthermore, cathelicidin peptides that have undergone proteolytic routes are specifically found in rosacea and never in its absence. These cathelicidin protein units are a product of a processing anomaly concomitant with an expression of the stratum corneum tryptic enzyme (SCTE) within the skin. Intensified serine protease action and cathelicidin stimulate inflammatory reactions in patients of rosacea. The extensive laboratory procedures conducted to verify this correlation led the authors to conclude that cathelicidin plays a prominent role in inflammation of the surface of the skin, thereby suggesting a possible explanation for the manifestation of

rosacea by proving that an aggravated intrinsic immune response can lead to the development of several symptoms of the disease.

6.1.2. TLR-2 and KLK-5

Vicissitudes in the skin's proteolytic equilibrium lead to lowered potential of the epidermis to act as an immunological barrier. Toll like receptors (TLR) are a major subset of pattern recognition receptors (PRR) that recognize damage-associated molecular patterns in the skin (Ozlu et. al, 2015). The expression of TLR-2 intensifies in inflammatory skin disorders such as acne and rosacea but cannot be observed in same levels with other chronic inflammatory cutaneous diseases therefore granting a certain specificity to rosacea. An external source, for instance, dust mites or UV radiation can also be held accountable for these proteolytic inconsistencies hence putting forward the premise that these proteins should be implicated in rosacea etiopathogenesis. An increased activation of TLR-2 is followed by the release of proinflammatory cytokines and chemokines such as IL-8, IL-1 β , and TNF- α (Meyer-Hoffert and Schroder, 2011). IL-8 attracts neutrophils in the skin which then release proteases such as cathepsin G, elastase, and protease-3. Furthermore, the IL-1 β and TNF- α may cause the vascular hyperreactivity shown by Gerber et al (2011) in rosacea through their roles as angiogenic vascular endothelial growth factor (VEGF). In addition, TLR-2 is known to increase the expression of the serine protease kallikrein-5 (KLK-5), which is an enzyme responsible for processing a cathelicidin precursor into its active form, LL-37 (Figure1).



TLR-2: Toll-like receptor-2

Figure 1. The role of antimicrobial peptides (AMP) in the pathogenesis of rosacea.

It must be noted that the lesioned skin of patients with rosacea exhibits an increased expression of KLK-5 when compared with the skin of healthy individuals. Yamasaki et al (2011) showed that the release of KLK-5 is calcium dependent and is linked to the calcium triggering properties of TLR-2, which in turn further augments the release of KLK-5. Matrix-metalloproteinases (MMPs) are also responsible for the activation of KLK-5 after the cleavage of its proenzyme form, MMP-9, which are observed in high numbers among patients with rosacea. Thereafter, this increased activation of KLK-5 mediated via MMP leads to further activation of LL-37, the processed form of cathelicidin (Two et. al. 2015).

6.1.3. Epidermal barrier disruption

The skin plays a vital part in the immune system as a physical barrier. The disturbance of this barrier is thought to be behind the pathogenesis of various chronic inflammatory diseases, such as rosacea, psoriasis and atopic dermatitis (Kim and Leung, 2012). One of the contributing factors behind this disruption is an increased loss of water in the skin of patients with rosacea. These reduced epidermal hydration levels are the feature of rosacea but the alkalinity is also more profound in the centofacial epidermis when compared to healthy individuals (Ni Raghallaigh and Powell, 2014). Since an alkaline pH is responsible for enhanced protease activity, the activation of a particular epidermal protease known as kallikrein (KLK-5) may be associated with this epidermal barrier disruption in rosacea.

6.2. NEUROIMMUNE AND NEUROVASCULAR PATHWAYS

The contribution of neuroimmune and neurovascular aberrations to the pathogenesis of rosacea is presently implicated vastly by merely clinical scrutiny. Several types of research have inspected the molecular connections of different cellular pathways involved in the development of rosacea and their unique configurations in the differing variants of rosacea.

Clinical observations demonstrated intimate connotations of the vasculature, sensory nerves, and cells of the immune system, signifying that neurovascular and neuroimmune physiognomies are responsible for dilated blood vessels and distended lymphatic vessels. Studies conducted by Schwab et al. (2011) strongly implicate extensive neurovascular and neuroimmune communication in rosacea development.

With the outcomes of the study consistently portending substantial vasodilation in each rosacea variant, its correlation to the characteristic erythema and flushed appearance of rosacea was not a stretch by any means whatsoever. Several authors decreed that angiogenesis also plays a part in rosacea pathophysiology, thereby proposing that the upsurge in the multiplication of vascular tissue specifically is a result of this causation (Del Rosso et al., 2012). Other studies were unable to isolate the presence of angiogenesis in rosacea patients, regardless, a considerable amount of vasodilation was prominent in all cases.

The mechanisms that bring about the prompt reddening and erythema representative of rosacea are still unidentified (Sobottka and Lehmann, 2009).

Notwithstanding the conspicuous amount of telangiectasia in these patients, the ability of the vasculature to react to vasoactive stimuli remains unharmed, signifying that such modifications are not fundamental or owing to irreparable impairment. On the other hand, molecular analysis has pointed out a discernible upregulation of genes archetypally implicated in vasodilation. Consequently, it is largely concluded that sensory nerves could be prompting vasodilation via the stimulation of high-affinity receptors that are receptive of vasoregulatory neuropeptides on the cells of the endothelium, as well as the cells forming the smooth musculature of the walls of the vessels.

In current years, the lymphatic system has been the object of mounting intrigue and fascination as a previously overlooked significant contributor to chronic inflammatory diseases (Huggenberger et al., 2010). In this particular area of development, it was largely discovered that lymphatic vessels are evidently shown to be involved in the instigating routes of rosacea pathogenesis but not in the stages that follow, even though clinically detectable edema is almost always present in advanced subtypes.

Very little documentation was found regarding the potential impact of the nervous system on the tissues comprising the lymph vasculature. Some existing researches support that mechanisms involving neuropeptides affect the lymphatic vessels' function and morphology. For instance, Amerini et al. (2004) established through laboratory findings that substance P prompts the decline in systolic as well as diastolic vessel width, stroke volume, and heightening of the rate of recurrence of contraction.

Another concept that attained prominence in the field of rosacea proposes the possible participation of processes that result in neurogenic inflammation, which could explain the initial and later clinically dominant aspects of rosacea such as erythema, reddening of the skin and an influx of leukocytes to the site of dermal inflammation (Steinhoff et al., 2003)

Mast cells are inarguably established components responsible for neurogenic inflammation, the process of fibrosis, and defensive immune function. Aroni et al. (2008) conducted a study not too long ago that deliberated upon the noteworthy role played by mast cells in the progression of rosacea to chronic stages.

The results of the tests undertaken by Schwab et al. (2011) plainly point toward a striking proliferation of mast cells in all variant forms of rosacea, although the most prominent increase was demonstrated in the papulopustular subtype. When these results were compared to the findings from tests conducted on patients with lupus erythematosus, mast cells were not present in distinctly higher quantities. This comparison prompted the hypothesis that the great concentration of mast cells seen in rosacea indicates a deeper pathophysiology than merely general skin inflammation.

The truncated affirmative outcomes of direct and indirect immunofluorescence demonstrate a poor supporting theory suggesting any prospective autoimmune function involvement in the pathophysiological development of rosacea (Lazaridou et al., 2010)

To sum it up, the considerable literature reviewed to discover the role of neuroimmune and neurovascular mechanisms in the pathogenesis of rosacea definitely leads to the suggestion that these networks are strong contenders for its causation. It has been demonstrated by researchers that within both molecular and anatomic-

physiological frameworks, neurogenic inflammation is an undeniable contributor to the development of this chronic inflammatory disease, causing vasodilation as opposed to angiogenesis, and supporting the propagation of the numerous fibrotic pathways perceived in rosacea.

6.3. MICROBIAL PATHWAYS

The part played by microorganisms (predominantly bacteria) in the causation of rosacea has been explored in a multitude of studies; in fact, several authors acclaim it to be amongst the most highly suspected factors. A number of microorganisms have thus far been identified that either causes an immune-reactive response in rosacea patients or are found in abnormally large colony numbers in this population. A comprehension of the microbiological aspects of rosacea pathology could provide an explanation for modifications in and reactivity to certain microbial species. Recognition of disease pathways is crucial to making patient care more target-specific and developing more effective therapeutic interventions.

Regardless of the extensive literature available for scrutiny, a scientifically distinct confirmation of their direct etiological contribution to rosacea has not been validated. It was, however, established that microorganisms were largely associated with the PPR variant of the disease.

6.3.1. *Helicobacter pylori*

There has been a lot of conflicting data found regarding the likelihood of *Helicobacter pylori* playing a causative part in rosacea. The precise pathways through which *Helicobacter pylori* initiates rosacea have yet to be established. Studies have

suggested that it acts through the release of certain cytotoxins that impact production of cytokines, histamines and similar mediators, thus affecting the vascular system and triggering rosacea. No explicit histological mechanisms have been recognised in rosacea patients who harbored *Helicobacter pylori*.

Szlachcic (2002) observed the incidence of a *Helicobacter pylori* infection in the gastric regions of people suffering from rosacea. The study found that 67% of such individuals were identified with a concurrent infection with *H. pylori* and the presence of a virulence agent known as “cytotoxin-associated gene A” (CagA). A number of studies that concluded with similar results put forward that rosacea demonstrates obvious linkages to gastrointestinal symptomatology, and is interrelated to the mechanism of expression of CagA by *H. pylori*, which resultantly elevates blood levels of (interleukin 8) IL-8 and tumour necrosis factor α (TNF α). Such studies propose that rosacea may be an extra-gastric expression of *H. pylori* colonisation, interceded through the production of cytotoxins.

Schneider et al. (1992), on the other hand, did not observe a significant incidence of *H. pylori* infection in the rosacea population they studied. This was also the result of a more recent research undertaken by Herr and You (2000) where once more the levels of antibodies against *H. pylori* were not found to be in significant numbers. It was thereby suggested by these studies that *H. pylori* does not play a role in the pathogenesis of rosacea.

This report concludes from the research performed up to the present time regarding this particular factor that the antibodies are proficient in minimalizing both *H. pylori* gastric infections as well as the symptomatology of rosacea make it a very

challenging task to stratify the implicated group against all influences that stimulate both diseases in question. Therefore, the findings continue to be unconvincing regarding the connection of *Helicobacter pylori* with rosacea development.

6.3.2. *Demodex folliculorum*

Demodex folliculorum has also been implicated in a significant quantity of published literature to be a pathological cause of rosacea. *Demodex* is present in the vast majority of the population.

Lazaridou et al. (2009) opted to distinguish the occurrence of *Demodex folliculorum* on skin afflicted with rosacea and to there by explicate the immunological contribution of the mite, amongst other suspected causes. The results of this study were enlightening. Women were found to be more frequently prone to rosacea. Half the population afflicted was 51-70 years of age. 73% of patients reported exacerbation of rosacea upon contact with sunlight, while solar elastosis was a virtually perpetual histopathological manifestation isolated. This particular study demonstrated that the incidence and mean concentration of *Demodex folliculorum* was considerably amplified in the people with rosacea. It was thus established that *Demodex* could be a noteworthy cofactor particularly in the changeover of the disease stages from the vessel- centred to inflammatory (Forton et al., 2005).

It is noteworthy to mention here that the immune response observed surrounding the pilosebaceous glands in papulopustular rosacea could potentially be a result of *Demodex* mites' accumulation. It is conjectured that the build-up of the mites

within the follicles is the source of their impairment. The impaired follicles are a gateway for bacterial invasion through the follicular walls, allowing inflammation around the pilosebaceous units and leading to their aberrant activity. However, additional studies are necessitated to further institute this finding.

6.3.3. *Bacillus oleronius*

Bacillus oleronius is a nonmotile, Gram-negative, endospore-forming bacteria whose role in rosacea became known after its isolation from *Demodex folliculorum* mites, which had been inhabiting the face of a patient with PPR (Lacey et al., 2007). Further investigation showed that this bacterium has the potential to stimulate a proliferative response in rosacea patients from a significantly higher number of monocytes than that in healthy individuals. The antigenic proteins related to *Bacillus oleronius* have been shown to increase production of MMP-9, tumor necrosis factor (TNF), and IL-8 from exposed neutrophils of healthy subjects, quite like the inflammatory mediators of PPR (Yamasaki et al., 2007).

6.3.4. *Staphylococcus epidermidis*

Staphylococcus epidermidis was pronounced a prospective causal microbe in a study executed by Dahl, Ross and Schlievert (2004). However, bacterial cultures performed from extracts of rosacea-related pustules fail to consistently demonstrate the presence of *Staphylococcus epidermidis*, and since the bacteria contributes to the resident flora of the skin, it is largely considered a contaminant.

6.4. UV RADIATION

Energy radiated from sunrays is widely acknowledged to be involved in the destruction of the cutaneous vasculature and the connective tissue of the dermis, particularly considering that rosacea emanates on surfaces exposed to the sun. Lazaridou et al (2011) also advocates the focal role of chronic sun exposure in the pathogenesis of rosacea. This points toward a relationship between prolonged exposure to sunlight, resultant degenerative elastosis and the origination of rosacea (Aroni et al., 2004). In this same line of thought, it is important to review the dermal matrix degeneration theory, which signifies that the development of rosacea is likely a result of the lack of connective tissue reinforcement for the blood vessels present in the facial region.

Chronic ultraviolet A (UVA) irradiation can lead to an overexpression in the interstitial collagenase such as MMP-1, which are associated with dermal collagen degeneration observed in rosacea (Wlaschek et. al, 1993). Moreover, solar elastosis has been observed after chronic UV radiation, a typical histopathological feature of rosacea. Furthermore, ultraviolet B (UVB) exposure to culture keratinocytes causes upregulation of the mRNA and protein expression of (VEGF) which in turn contributes to hypervascularity seen in the skin of individuals with rosacea (Bielenberg et. al, 1998). Whether it is UVA or UVB, the primary wavelength influential in the pathogenesis of rosacea has yet to be fully researched. Ultraviolet radiation upsurges the production of reactive oxygen species (ROS) within the dermal layers of the skin (Jones, 2004). ROS are responsible for activating inflammasomes, pro-inflammatory cytokines, and

inflammatory mediators produced by keratinocytes and fibroblasts. These molecules are signalled via Toll-like receptor 2 to proliferate the seditious inflow of kallikrein 5-cathelicidin (Wu et al., 2015). Not only do ROS propagate the inflammatory responses common in rosacea, but further decline the tissue superoxide dismutase and cause an observable accumulation of serum peroxide, thus representing an imbalance between antioxidant and oxidant pathways in patients (Oztas et. al, 2003). These previously mentioned findings suggest that restructuring of the dermal matrix and vasculature by VEGF, FGF2, and MMP-1 and the production of the ROS due to chronic photo damage validate the theory of UV radiation as an influential contributor for rosacea.

7. RISK FACTORS

Dietary agents have traditionally been accepted as potential influencers of the symptoms of rosacea. Even though spicy edibles, alcohols and hot drinks are established to generate flushing in patients with confirmed rosacea, the prevalent confirmations from scientific publications do not maintain that dietary factors play a principal role in rosacea pathophysiology. Qualitative and quantitative epidemiological researches that have been engrossed in determining the interrelationship existing between alcohol consumption and rosacea manifestation have been faced with too many limitations such as hurdles to medical access, poor compliance from subjects with rosacea, by imprecisions in history of alcohol consumption as related by alcoholics personally, and by insufficient control populations to conduct the studies on. Alcoholism has demonstrably manifested its effects on the skin in a diverse range of diseases and skin conditions, although it should be acknowledged that majority of these

manifestations encompass the consequence of liver cirrhosis and therefore only indirectly caused by alcohol itself (Crawford, Pelle and James, 2004).

8. CONCLUSION

The specific cause of development of this chronically inflamed condition of rosacea remains largely unknown. Founded on the numerous contradictory researches and clinical opinions articulated in the comprehensively compiled literature, it appears that the identification of the fundamental pathophysiology that contributes to the establishment of the disease is far from accomplished.

While it cannot be denied that the recent studies have considerably enriched the understanding of rosacea pathophysiology, the author concludes that the precise etiopathological pathways of rosacea are not clear at this point of time and necessitates significant further elucidation based on its variants and age at which it is developed.

A query that repetitively came up during the undertaking of the present study was whether or not rosacea is, in fact, a multifactorial illness in terms of pathophysiological origin. It is deliberated that it could not be possible for a solitary pathological hypothesis to successfully justify the concurrent existence of the many diverse manifestations of rosacea. Further progress in understanding of the numerous intricate factors of consideration and communicating pathways could enable the development of broad new, far more specific and effective therapeutic options for rosacea.

9. REFERENCES

Amerini S, Ziche M, Greiner ST, Zawieja DC (2004) Effects of substance P on mesenteric lymphatic contractility in the rat. *Lymph Res Biol* 2(1):2-10.

Aroni K, Tsagrioni E, Kavantzias N, Patsouris E and Ioannidis E(2008) A study of the pathogenesis of rosacea: how angiogenesis and mast cells may participate in a complex multifactorial process. *Arch Derm Res* 300(3):25-131.

Aroni K, Tsagrioni E, Lazaris AC, Patsouris E, and Agapitos E(2004) Rosacea: a clinicopathological approach. *Dermatol* 209(3):177-182.

Berth-Jones J. (2010) Rosacea, perioral dermatitis and similar dermatoses, flushing and flushing syndromes. In: Burns T, Breathnach S, Cox N, Griffiths C. 8. Ed. *Rook's Textbook of Dermatology*. Oxford: Blackwell Publishing Ltd, p.43.1-43-20.

Bielenberg DR, Bucana CD, Sanchez R, Donawho CK, Kripke ML, Fidler IJ (1998) Molecular regulation of UVB-induced cutaneous angiogenesis. *J Invest Dermatol* 111:864-872.

Crawford GH, Pelle MT and James WD(2004) Rosacea: I. Etiology, pathogenesis, and subtype classification. *J Am Acad Dermatol* 51(3):327-341.

Dahl MV, Ross AJ and Schlievert PM(2004) Temperature regulates bacterial protein production: possible role in rosacea. *J Am Acad Dermatol* 50(2):266-272.

Del Rosso JQ (2012) Advances in Understanding and Managing Rosacea: Part 1 Connecting the Dots between Pathophysiological Mechanisms and Common Clinical Features of Rosacea with Emphasis on Vascular Changes and Facial Erythema. *J Clin Aest Dermatol* 5(3):26-36.

Forton F, Germaux MA, Brasseur T, De Liever A, Laporte M, Mathys C, Sass U, Stene JJ, Thibaut S, Tytgat M and Seys B(2005) Demodicosis and rosacea: epidemiology and significance in daily dermatologic practice. *J Am Acad Dermatol* 52(1):74-87.

Gerber PA, Buhren BA, Steinhoff M, Homey B (2011) Rosacea: The cytokine and chemokine network. *J Investig Dermatol Symp Proc*15:40-47.

Goldberg DJ and Berlin AL (2013) Rosacea – epidemiology and pathophysiology. In: Goldberg DJ, Berlin AL. *Acne and rosacea. Epidemiology, diagnosis and treatment*. London: Manson Publishing, p. 51-58.

Gudmundsson GH, Agerberth B, Oberberg J, Bergman T, Olsson B, Salcedo R (1996) The human gene FALL39 and processing of the cathelin precursor to the antibacterial peptide LL-37 in granulocytes. *Eur. J. Biochem.* 238:325-332.

Herr H and You CH (2000) Relationship between *Helicobacter pylori* and Rosacea. *J Korean Med Sci* 15:551-4.

Holmes AD (2013) Potential role of microorganisms in the pathogenesis of rosacea. *J Am Acad Dermatol* 69(6):1025-1032.

Huggenberger R and Detmar M (2011) Dec. The cutaneous vascular system in chronic skin inflammation. *J Investig Dermatol Symp Proc*. vol 15, No. 1, p 24-32. Elsevier.

Kim BE, Leung DY (2012) Epidermal barrier in atopic dermatitis. *Allergy Asthma Immunol Res* 4:12-16.

Lacey N, Delaney S, Kavanagh K, Powell FC (2007) Mite-related bacterial antigens stimulate inflammatory cells in rosacea. *Br J Dermatol* 157:474-481

Lazaridou E, Apalla Z, Sotiraki S, Ziakas NG, Fotiadou C and Ioannides D (2010) Clinical and laboratory study of rosacea in northern Greece. *J Eur Acad Dermatol Venerol* 24(4):410-414.

Lazaridou E, Giannopoulou C, Fotiadou C, Vakirlis E, Trigoni A and Ioannides D (2011) The potential role of microorganisms in the development of rosacea. *JDDG: J Dtsch Dermatol Ges* 9(1):21-25.

Mc Aleer MA, Lacey N and Powell FC(2009)The pathophysiology of rosacea. *Giornale italiano di dermatologia e venereologia: organo ufficiale, Soc Ital Dermatol Sifilog* 144(6):663-671.

Meyer-Hoffert U, Schroder JM (2011) Epidermal proteases in the pathogenesis of rosacea. *J Investig Dermatol Symp Proc* 15:16-23

Ni Raghallaigh S and Powell FC (2014) Epidermal hydration levels in patients with rosacea improve after minocycline therapy. *Br J Dermatol*171:259-266

Ozlu E, Karadag AS, Ozkanli S, Oguztuzun S, Kilic M, Zemheri E, Akbulak O, Akdeniz N (2015) Comparison of TLR-2, TLR-4, and antimicrobial peptide levels in different lesions of acne vulgaris. *Cutan Ocul Toxicol* 35(4):300-309.

Oztas M, Balk M, Ogus E, Bozkurt M, Ogus I, Ozer N (2003) The role of free oxygen radicals in the aetiopathogenesis of rosacea. *Clin Exp Dermatol*28:188-192.

Powell FC and Raghallaigh SN (2012) Rosacea and related disorders. In:Bologna JL, Jorizzo JL, Schaffer JV. 3.ed. *Dermatology*. London: Elsevier Saunders,p. 561-569.

Schneider MA, Skinner RB, Rosenberg EEA, Noah PW, Smith L and Zwarum A, (1992) December. Serologic determination of helicobacter-pylori in rosacea patients and controls. *Clin Res* 40(4):A831-A831.

Schwab VD, Sulk M, Seeliger S, Nowak P, Aubert J, Mess C, Rivier M, Carlavan I, Rossio P, Metze D and Buddenkotte J(2011) Dec. Neurovascular and neuroimmune aspects in the pathophysiology of rosacea. *J Investig Dermatol Symp Proc*15(1):53-62. Elsevier.

Schauber J, Gallo RL(2007) Expanding the roles of antimicrobial peptides in skin: alarming and arming keratinocytes. *J Investig Dermatol* 127:510-512.

Sibenge S and Gawkrodger DJ (1992) Rosacea: a study of clinical patterns, blood flow, and the role of *Demodex folliculorum*. *J Am Acad Dermatol* 26(4):590-593.

Sobottka A and Lehmann P(2009) Rosacea 2009: new advances in pathophysiology, clinical staging and therapeutic strategies. *Hautarzt* 60(12):999-1009.

Steinhoff M, Buddenkotte J, Aubert J, Sulk M, Novak P, Schwab VD, Mess C, Cevikbas F, Rivier M, Carlavan I and Déret S(2011) Dec. Clinical, cellular, and molecular aspects in the pathophysiology of rosacea. *J Investig Dermatol Symp Proc* 15(1):2-11.

Szlachcic A (2002) The link between *Helicobacter pylori* infection and rosacea. *J Euro Acad Dermatol Venereol*16(4):328-333.

Two AM, Wu W, Gallo RL, Hata TR (2015) Rosacea: Part I. Introduction, categorization, histology, pathogenesis, and risk factors. *J Am Acad Dermatol*72:749-758.

Wlaschek M, Bolsen K, Hermann G, Schwarz A, Wilmroth F, Heinrich PC, Goerz G, Scharffetter-Kochanek K (1993) UVA-induced autocrine stimulation of fibroblast-derived-collagenase by IL-6: A possible mechanism in dermal photodamage? *J Investig Dermatol*101:164-168.

Whitfeld M, Gunasingam N, Leow LJ, Shirato K and Preda V (2011) *Staphylococcus epidermidis*: a possible role in the pustules of rosacea. *J Am Acad Dermatol* 64(1):49-52.

Wilkin J, Dahl M, Detmar M, Drake L, Feinstein A and Odom R(2002) Standard classification of rosacea: Report of the National Rosacea Society Expert Committee on the Classification and Staging of Rosacea. *J Am Acad Dermatol* 46:584–7.

Wu W, Gallo RL and Hata TR(2015) Rosacea: part I. Introduction, categorisation, histology, pathogenesis, and risk factors. *J Am Acad Dermatol* 72(5):749-758.

Yamasaki K, Schaubert J, Coda A, Lin H, Dorschner RA, Schechter NM, et al. (2006) Kallikrein-mediated proteolysis regulates the antimicrobial effects of cathelicidins in skin. *FASEB J* 20:2068-80

Yamasaki K, Di Nardo A, Bardan A, Murakami M, Ohtake T, Coda A, Dorschner RA, Bonnart C, Descargues P, Hovnanian A and Morhenn VB(2007) Increased serine protease activity and cathelicidin promotes skin inflammation in rosacea. *Natur Med* 13(8):975-980.

Yamasaki K, Kanada K, Macleod DT, Borkowski AW, Morizane S, Nakatsuji T, et al. (2011) TLR2 expression is increased in rosacea and stimulates enhanced serine protease production by keratinocytes. *J Invest Dermatol* 131:688-97

10. ACKNOWLEDGEMENTS

I would like to whole-heartedly thank Professor Zrinka Bukvić Mokos, MD, PhD, for her unwavering guidance that enabled me to precisely undertake the documentative analyses methodology. Her knowledge and expertise in the field of dermatology is truly inspiring. Secondly, I would like to convey my gratitude to Professor Branka Marinović, MD, PhD, and Assist. Prof. Krešimir Kostović, MD, PhD, for reviewing the paper and providing valuable feedback that enhanced the quality of the document. I am also grateful to my family for their endless support, without whom none of this would be possible. Lastly, I would like to thank the University of Zagreb, School of Medicine for providing me this privileged opportunity to study medicine.

11. BIBLIOGRAPHY

Ibad A Faruqi was born in Karachi, Pakistan and subsequently moved to Seattle, Washington in the mid-90s where he completed his primary and high school education. After graduating from high school, he enrolled at the Bellevue College where he completed his Associates Degree of Arts and Science with an emphasis on pre-medicine. He heard about the University of Zagreb, School of Medicine through his father who had been visiting the region for business. Thereafter, he decided to apply and pursue a career in medicine, as it had always been one of his goals in life. Ibad is currently finishing his time as a student and yearns to become a productive and influential medical doctor that our society needs. Apart from the medical studies, he has worked and volunteered with first aid response team made of students and young residents at the faculty of Zagreb. His hobbies include playing team sports such as soccer, cricket and flag football and occasionally indulging in a few rounds of racquetball or squash. Ibad holds great interest in the field of trauma and emergency care, and general medicine but is also impressed by the field of dermatology. His other academic interests go beyond the scope of medicine, particularly in astronomy, history and video production.