

# Epilepsy in children caused by hypoxic-ischemic encephalopathy

---

Salman, Rima

Master's thesis / Diplomski rad

2018

Degree Grantor / Ustanova koja je dodijelila akademski / stručni stupanj: **University of Zagreb, School of Medicine / Sveučilište u Zagrebu, Medicinski fakultet**

Permanent link / Trajna poveznica: <https://um.nsk.hr/um:nbn:hr:105:091689>

Rights / Prava: [In copyright](#) / [Zaštićeno autorskim pravom.](#)

Download date / Datum preuzimanja: **2024-12-23**



Repository / Repozitorij:

[Dr Med - University of Zagreb School of Medicine Digital Repository](#)



**UNIVERSITY OF ZAGREB**

**SCHOOL OF MEDICIN**

**Rima Salman**

**Epilepsy in children caused by hypoxic ischemic  
encephalopathy**

**GRADUATE THESIS**



**Zagreb, 2018.**

This graduate thesis paper was made at the Department of Pediatrics, Clinical Hospital Center Zagreb, under the mentoring role of prof.dr.sc. Nina Barišić, M.D. Thesis paper "Epilepsy in children caused by hypoxic-ischemic encephalopathy" was submitted for evaluation in the academic year 2017./2018.

Mentor: prof.dr.sc. Nina Barišić, M.D.

## **ABBREVIATIONS**

ACTH- adrenocorticotropic hormone

ATP- adenosine triphosphate

AMPA -  $\alpha$ -amino-3-hydroxy-5-methylisoxazole-4-propionate

EEG – electroencephalography

cEEG - continuous electroencephalography

aEEG – amplitude-integrated electroencephalography

FDA – food and drug agency

GABA - gamma-aminobutyric acid

HIE- hypoxic-ischemic encephalopathy

LGS- Lennox-Gastaut syndrome

mRNA- messenger ribonucleic acid

MRI – magnetic resonance imaging

NMDA - N-methyl-D-aspartate

PDS - paroxysmal depolarizing shift

TORCH- toxoplasmosis, rubella, CMV, herpes virus

VNS- vagal nerve stimulation

## CONTENT

Summary

Sažetak

1. Introduction	1
1.1. Definitions	1
1.2. Epidemiology	4
2. Pathophysiology	5
2.1. Pathophysiology of hypoxic-ischemic encephalopathy	5
2.2. Pathophysiology of epilepsy	7
3. Etiology	10
4. Neonatal seizures and epilepsies	12
4.1. Focal seizures	12
4.2. Generalized seizures	13
4.3. Seizures of unknown type	14
4.4. Neonatal seizures	14
4.5. Epileptic syndromes beginning in the newborn age	15
4.6. Epilepsy arising in infants	16
4.7. Epilepsy beginning after the first year of life	18
4.8. Epilepsy in adolescents	20
5. Diagnosis of epilepsy and diagnostic procedure	20
6. Treatment of seizure and epilepsy	24
6.1. Antiepileptics	24
6.2. Adrenocorticotrophic hormone	27
6.3. Corticosteroids	28

6.4. Ketogenic diet	28
6.5. Vagal nerve stimulation	28
6.6. Corpus callosotomy	28
6.7. Therapeutic hypothermia	29
7. Prognosis	30
8. Conclusion	31
9. Acknowledgment	32
10. References	33
11. Biography	37

## **SUMMARY**

Title: Epilepsy in children caused by hypoxic-ischemic encephalopathy

Author: Rima Salman

*Hypoxic-ischemic encephalopathy* is a condition associated with low uteroplacental blood flow that results in perinatal asphyxia. As a consequence of neonatal oxygen deprivation, perinatal asphyxia at the time of delivery is more common than in utero. Hypoxic-ischemic encephalopathy leads to several unfavorable neurodevelopmental outcomes. Epilepsy, cerebral palsy, mental retardation, visual and hearing problems are some of them.

Epilepsy in children with perinatal asphyxia and hypoxic-ischemic encephalopathy is at the primary focus in this graduate thesis paper. Neonatal seizures are seizures that occur during neonatal period – first 28 days of the life of a full-term infant. Fifty percent of neonatal seizures are subtle and characterized by orolingual movements, automatisms, progression and purposeless movements. Most of the newborn seizures usually last 10 seconds to 1-2 minutes. Seizures are mostly repetitive with a median of a few minutes between each seizure.

Many different epilepsy types are seen in children some of which being Ohtahara syndrome, West syndrome, and Lennox-Gastaut syndrome.

Electroencephalography is the gold standard for diagnosis of neonatal epileptic seizures. 85% of electrographic seizures are usually silent.

First line antiepileptic drugs of choice are phenobarbital and phenytoin.

Keywords: hypoxic-ischemic encephalopathy, epilepsy

## SAŽETAK

Naslov: Epilepsije u dječjoj dobi uzrokovane hipoksično-ishemičnom encefalopatijom

Autor: Rima Salman

*Hipoksično-ishemična encefalopatija* je stanje koje nastaje kao posljedica slabog uteroplacentalnog krvotoka koji rezultira perinatalnom asfiksijom. Pojavljuje se kao posljedica niske saturacije kisikom u novorođenčeta u vrijeme poroda. Hipoksično-ishemična encefalopatija dovodi do nekoliko nepovoljnih neurorazvojnih ishoda kao što su epilepsija, cerebralna paraliza, mentalna retardacija, problemi s vidom i sluhom.

Epilepsija i epileptički napadaji uzrokovani perinatalnom asfiksijom i hipoksično-ishemičnom encefalopatijom su glavna tema ovoga diplomskoga rada. Epileptički napadaji koji se javljaju tijekom neonatalnog razdoblja, prvih 28 dana života prematurnog i terminskog djeteta. Pedeset posto neonatalnih napadaja su suptilni napadaji za koje su karakteristični orolingvalni pokreti sisanja, gutanja, slinjenja; pokreti poput veslanja i plivanja, multifokalni klonički grčevi. Većina cerebralnih napadaja obično traje 10 sekundi do 1-2 minute.

Različite vrste epilepsija mogu se prezentirati u dječjoj dobi kao na primjer Ohtahara sindrom, Westov sindrom i Lennox-Gastautov sindrom.

Elektroencefalografija je zlatni standard za dijagnozu cerebralnih epileptičkih napadaja. 85% elektrografskih napadaja obično je tiho to jest nisu klinički prepoznati.

Prva linija antiepileptičkih lijekova po izboru su fenobarbital i fenitoin.

Ključne riječi: hipoksično-ishemična encefalopatija, epilepsija



## 1.INTRODUCTION

### 1.1.DEFINITIONS

*Hypoxic-ischemic encephalopathy (HIE)* is a condition caused by reduced uteroplacental blood flow; it is also known as perinatal asphyxia. Hypoxic-ischemic encephalopathy occurs in neonates around the time of delivery, that is why we can classify it as prenatal or perinatal. More often injury to the CNS occurs as a result of oxygen deprivation during difficult delivery than in utero. Birth asphyxia, associated with HIE, is manifested with hypotension, lactic acidosis and organ failure (2).

Encephalopathic lesions differ between preterm and term infant (18). While, in term infant cerebral edema, cortical necrosis and involvement of basal ganglia are commonly observed. In preterm infant periventricular leukomalacia, white matter injury that results in the formation of cavitations and cysts is a characteristic finding.

An outcome of HIE can be fatal, or it can result in neurodevelopmental consequences for the child and its family. Most common neurodevelopmental outcomes of encephalopathy are cerebral palsy, seizures, epilepsy, mental retardation, vision and hearing problems. Twenty-five percent of neonates with HIE will develop severe and permanent neuropsychological sequelae (34).

Risk factors for HIE can be maternal and fetal (7). Maternal risk factors are arterial hypertension, preeclampsia/ eclampsia, diabetes mellitus, heart condition, anemia, thyroid gland abnormalities, placenta previa, placental abruption and breech delivery. Fetal causes are congenital anomalies, intrauterine infections and erythroblastosis fetalis.

*Seizures* are one of the most commonly seen neurological problems in practice. Seizures are classified as epileptic and non-epileptic seizures (non-epileptic paroxysmal events). By definition, *epileptic seizures* can be defined as hypersynchronous electrical discharges of cortical and subcortical neurons that are hyperexcitable (4). "In hypoxic-

ischemic encephalopathy, seizures signal a secondary injury phase and may further aggravate brain damage" (14).

Epileptic seizures are classified according to International League Against Epilepsy into generalized seizures, focal seizures, and seizures of unknown type. *Generalized epileptic seizures* arise from both hemispheres at once, whereas *focal seizures* are derived from only one brain hemisphere. Epileptic seizures arising from one hemisphere can spread and involve a whole brain turning into *bilateral seizures*(19). *Generalized seizures* are further subdivided into convulsive ( tonic-clonic, tonic, clonic, myoclonic and atonic) and non-convulsive seizures ( typical and atypical absence seizures). *Focal seizures* can be subdivided into complex partial seizures, in which awareness is impaired, and focal seizures in which consciousness is preserved (4). Focal seizures are differentiated by signs and symptoms as well as by their localization.

Non-epileptic seizures occur together with different physiological states (sleeping, fear, excitement) and diseases (CNS infections, hypoxia and hypoperfusion of the brain, metabolic disturbances and poisoning) (19).

Seizures caused by HIE, also called post-asphyxial seizures, occur in full-term infants 12-24 hours after the event of birth asphyxia. Other possible causes of post-asphyxial non-epileptic seizures are metabolic disturbances such as hypocalcemia, hypoglycemia, and hypomagnesemia. In preterm infants, seizures can be caused by intraventricular hemorrhage. Such seizures often occur between 1-3 days after birth(18).

Differential diagnosis of epileptic and non-epileptic seizures in infants is crucial. Tremors and jitteriness are sensory dependent and can be elicited by stimuli. Other characteristics of tremor are that they can be stopped by holding tremorous extremity and that they are not associated with any of the ocular movements specific to seizures. Seizures are manifested as coarse, fast and slow clonic activity, associated with abnormal

eye movements. Identifying seizures in newborns is difficult, especially in preterm infants who have low birth weight, because they do not show tonic-clonic activity typically seen in older children. Subtle seizures are more commonly seen in newborns. This kind of seizure activity is manifested with apnea, tongue thrusting, eye deviation, blinking, staring and fluctuation of vital signs. To identify subtle seizures bedside electroencephalographic monitoring is necessary.

*Epileptic seizures in a newborn* are most often manifested in the form of fragmentary attacks; characterized as one or a combination of listed events (19):

1. sudden short-term changes in the state of alertness and behavior accompanied with motoric failure (atonia, apnea)
2. the short-term tonic deviation with a series of eyeball twitches
3. stereotypical automatisms such as sucking, swallowing, drooling, snoring
4. the tonic position of one extremity (cramp like)
5. stereotypical upper extremity movements (paddling or swimming)
6. multifocal (migrating, erratic) clonic cramps at the upper or lower extremities
7. focal clonic cramps without loss of consciousness (lack of localization)
8. generalized tonic cramps (similar to decerebration)
9. single generalized myoclonisms at the upper and lower extremities.

Epilepsy is a chronic brain disorder characterized by recurrent repetitive seizures. Classification of seizures according to ILAE include focal and generalized seizures as well as seizures of unknown onset. Multilevel classification of epilepsy is present:

1. seizure type- motor and nonmotor
2. epilepsy type – generalized epilepsy, focal epilepsy, combined generalized and focal
3. epilepsy syndrome refers to a cluster of features including seizure type, EEG, often has age-dependent features ( age at onset and remission), seizure triggers, diurnal variation

and prognosis (29).

According to ILAE, diagnosis of epilepsy can be established if at least one of the criteria is present:

1. at least 2 unprovoked or reflexive seizures in a time frame longer than 24 hours
2. one unprovoked or reflexive seizure with high recurrence risk (at least 60%)
3. presence of epileptic syndrome without a doubt (19)

## **1.2.EPIDEMIOLOGY**

The hypoxic-ischemic encephalopathy, also called neonatal encephalopathy, occurs in about 1 to 2.5 per 1000 live term births, the majority being caused by perinatal asphyxia. The incidence rate of HIE in premature infants is 60% of all live births. As mentioned previously, epilepsy may develop in patients with neonatal HIE. The reported rate of epilepsy in such children ranges from 9-33% (9). Five times higher risk of developing epilepsy is present in children with a history of hypoxic-ischemic encephalopathy compared to children without HIE.

The difference in the incidence of neonatal seizures in term and preterm infants is also noticed. In infants born at term, the frequency of seizures is 0.5 – 3 per 1000 live births. Higher incidence of epilepsy is observed in preterm infants, ranging from 1-13% of very low birth weight infants. (26) In the world, 10 million children younger than 15 years of age have epilepsy, while in the Republic of Croatia 7000 children up to age 14 have epilepsy.(19)

The injury pattern is dependant on the level of brain development and the severity of the insult, both affecting selective regional vulnerability and subsequent clinical manifestations. In infants born prematurely (<32 weeks of gestation) periventricular white matter is particularly vulnerable to hypoxia-ischemia resulting in injury characterized by motor, cognitive and sensory deficits. Whereas severe hypoxia-ischemia in term infants

causes selective damage to the sensorimotor cortex, basal ganglia, thalamus and brainstem (28).

## **2.PATHOPHYSIOLOGY**

### **2.1. PATHOPHYSIOLOGY OF HYPOXIC-ISCHEMIC ENCEPHALOPATHY**

"Hypoxic-ischemic brain injury is a syndrome that evolves over days, even weeks"(28). The pathogenetic mechanism associated with the intrapartum hypoxic-ischemic event is impaired cerebral blood flow. Mainly, reduced cerebral blood flow occurs as a consequence of impaired placental flow and gas exchange. The initial compensatory mechanism in asphyxia, which is defined by hypoxia and hypercapnia, is increase in cerebral blood flow (39). After the failure of cerebral autoregulation phenomenon, brain injury secondary to the diminished blood supply and lack of oxygen occurs; resulting in intracellular energy failure. During the early phases of brain injury, a cascade of events occurs, brain temperature drop with the increased release of neurotransmitters locally, such as GABA. (39)

At the cellular level, the reduction of cerebral blood flow and subsequent depletion of oxygen results in a switch from oxidative phosphorylation to anaerobic metabolism. The anaerobic metabolism triggers several events: rapid consumption of high energy reserves (as well as ATP), lactic acid accumulation and the inability to maintain cellular functions. This leads to the development of cytotoxic edema resulting from transcellular ion pump failure (25).

The membrane depolarization results in a release of excitatory neurotransmitters, especially glutamate which activates specific cell surface receptors, NMDA and AMPA, resulting in an influx of  $\text{Na}^+$  and  $\text{Ca}^{2+}$  into postsynaptic neurons (25). High synaptic levels of glutamate and excitatory amino acid receptor overactivation, NMDA, AMPA and kainate receptors which are permeable to different ions.

Failure of the energy-dependent enzyme,  $\text{Na}^+/\text{K}^+$  ATPase, together with the accumulation of  $\text{Na}^+$  leads to cytotoxic edema and cell death. NMDA receptor activation leads to intracellular  $\text{Ca}^{2+}$  accumulation and further cascade activation (39). Intracellular calcium accumulation induces activation of nitric oxide synthase and production of nitric oxide, which diffuses into adjacent cells making them susceptible to nitric oxide toxicity. High intracellular  $\text{Ca}^{2+}$  concentration also causes activation of phospholipases, endonucleases, and proteases. The combination of all of those events led to the disruption of cell components and eventually cell death. (25;39)

During reperfusion phase free radical production increases leading to further exacerbation of free radical damage in the neonate, because of immature antioxidant defenses (39). Free fatty acids, accumulated within the cytoplasm, undergo peroxidation by free oxygen radicals that arise from reductive processes in the mitochondria, and as a byproduct in the synthesis of prostaglandins, xanthines and uric acid (25). Cascade of pathophysiological events occurring in hypoxic-ischemia is summarized in Figure 2.1.

The recovery phase is when cerebral oxygenation and perfusion is restored after one successful resuscitation. It is characterized by phosphorous metabolite concentration returning to baseline as well as intercellular pH. In the second phase of injury, 6-48 hours later, cerebral energy failure recurs. The decrease in the ratio of phosphocreatine/ inorganic phosphate, with a constant pH and stable cardiorespiratory status, contributes to additional brain injury (25).

Neuronal injury occurring after the hypoxic-ischemic event can be observed as two different processes, neuronal necrosis, and apoptosis. Perlman in his article states that intensity of the initial hypoxic-ischemic insult determines the mode of death. Severe neuronal injuries result in necrosis, whereas milder injury results in apoptosis (25).

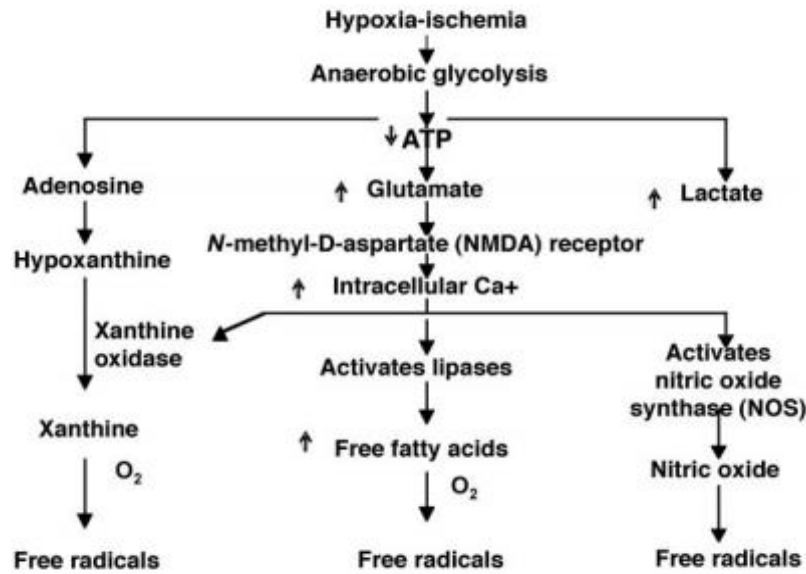


Figure 2.1. Brain injury pathways after the hypoxic-ischemic event.

Modified from: Perlman (2006.)

## 2.2.PATHOPHYSIOLOGY OF EPILEPSY

Epilepsy is clinically manifested in the form of a seizure. Two pathophysiological processes that can be noticed in the development of seizures are hyperexcitability of neurons and hyper-synchronization. A neuron that is hyperexcitable causes excessive excitability of a large group of surrounding neurons (17).

Every neuron within a seizure focus has electrical response called the paroxysmal depolarizing shift(PDS). The paroxysmal depolarizing shift consists of sudden, significant, long-lasting depolarization (20-40mV, 50-200ms) which triggers many of action potentials at the peak of PDS followed by after-hyperpolarization. Both PDS and after-hyperpolarization are under the influence of intrinsic membrane properties of the neuron (  $\text{Na}^+$ ,  $\text{K}^+$ ,  $\text{Ca}^{2+}$  voltage-gated channels) and synaptic inputs from excitatory (glutamatergic) and inhibitory (GABAergic) neurons. Depolarization phase results from activation of

excitatory glutamate-mediated channels such as AMPA and NMDA receptor channels, as well as the voltage-gated  $\text{Ca}^{2+}$  channel. Duration of PDS is limited by after-hyperpolarization. The most crucial factor in seizure development is gradual disappearance of PDS. As far as the abnormal electrical activity is restricted to 1000 or so neurons that create seizure focus no clinical manifestations will be observed. (12).

Up to 50 % of all neonatal seizures are caused by HIE. Miller et al. did a research using a pig model, of hypoxic ischemia with spontaneous neonatal seizures. Miller investigated changes in protein expression of the three predominant alpha-subunits of the  $\text{GABA}_A$  receptor,  $\alpha_1$ ,  $\alpha_2$ ,  $\alpha_3$ . " The alpha receptor protein is fundamental to receptors structure and function. The  $\alpha_3$  protein predominates in the immature brain while  $\alpha_1$  is most abundant in mature brain" (20).

Gamma-aminobutyric acid (GABA) is the first active neurotransmitter in the human brain that has an essential role in regulating cortical development; cortical neural stem cells express functional  $\text{GABA}_A$  receptors (20).

In adults with focal epilepsy, specific changes have been observed, such as reductions in  $\text{GABA}_A$  receptor  $\alpha_1$  and  $\alpha_3$  protein expression. Alternatively, in the neonatal rat models with status epilepticus, who are on chemoconvulsants, they have noticed reduced mRNA expression  $\alpha_1$  and  $\alpha_2$ . The  $\text{GABA}_A$  system alterations have been suggested as a mechanism of inhibitory loss. This loss of inhibition may cause seizures and resistance to antiepileptic drugs in the neonatal brain (20).

To prove changes in  $\text{GABA}_A$   $\alpha$ -subunit protein expression Miller et al. have subjected newborn pigs to the global hypoxic-ischemic event after which they analyzed expression  $\text{GABA}_A$   $\alpha$ -subunit proteins using immunohistochemical techniques and Western blot. Research results showed that 55% of all hypoxic-ischemic animals developed seizures. In post hoc analysis, Miller et al. concluded that end-insult physiological data did



not show any difference between animals that did develop seizures and animals that did not get seizures, in relation to hypoxic-ischemic insult severity (20). There was no significant difference between arterial pH of hypoxic-ischemic animals with seizures and those without seizures, nor was there a difference in the period of systemic hypotension. All the animals that did develop seizures during this study presented with seizure activity within first 24 hours, post-hypoxia. Seizure activity was either clinical and/or electrographic. Not one of the animals exhibited status epilepticus. Common clinical manifestations observed during simultaneous electrographic seizure activity included lip-smacking, vocalization, forelimb cycling, neck hyperextension. Background amplitude integrated EEG pattern in hypoxic-ischemic animals with seizures was depressed compared to hypoxic-ischemic animals without seizures (20).

Miller et al., have reported that neonatal seizures, arising 24 hours after hypoxic-ischemic insult, are associated with previously observed changes in GABA<sub>A</sub> receptor subunits seen in chronic epilepsy and status epilepticus (20).

### 3.ETIOLOGY

Epilepsy is a chronic neurological condition defined by recurrent, unprovoked, but also provoked seizures. Etiology of seizures is very diverse including structural abnormalities of the brain, genetic causes, infectious diseases, metabolic conditions, and brain-immune diseases. They can be caused by many different acquired and inherited factors and diseases(18).

The most common cause of neonatal seizures and afterward of epilepsy development is HIE. "It is responsible for 80% of all neonatal seizures in the first two days of life" (15; 24). Other common causes are intracranial hemorrhage and infarction, stroke, prenatal and neonatal infections. Metabolic disturbances such as electrolyte and glucose abnormalities have been common previously while inborn errors of metabolism are rare. Pyridoxine dependency with seizures within first days of life is exceptional. Exogenous causes of neonatal seizures may be iatrogenic, or they can occur due to drug withdrawal in babies born to mothers on drugs (24;18). Table 3.1. lists leading causes of neonatal seizures. Mostly, neonate presents with a combination of many different neurological disturbances, each of which can cause seizures, proving of diverse etiology(24).

Risk factors for epilepsy development in children with neonatal HIE are multiple. In the research done by Glass et al. at the Intensive care unit at the University of California San Francisco they concluded that degree of encephalopathy had an essential role in the development of epilepsy. The results of their research showed that frequency of epilepsy among the 52 children with a history of neonatal seizures was 25% and that those children who had status epilepticus were most likely to develop it. "Children with severe or near total brain injury were more likely to develop epilepsy." The pattern of injury is also essential, basal ganglia and thalamus were predominantly affected. The highest risk for epilepsy development is within the first year of life, as is the high rate of the associated

neurodevelopmental disabilities (9).

TABLE 3.1. Primary causes of neonatal seizures ( Modified from Panayiotopoulos, 2005.)

Hypoxic-ischemic encephalopathy	<i>Prenatal</i> (toxemia, fetal distress, placental abruption)
	<i>Perinatal</i> (iatrogenic, maternal hemorrhage, fetal distress)
	<i>Postnatal</i> (hyaline membrane disease, pulmonary hypertension, congenital heart disease)
Hemorrhage and intracerebral infarction	Intraventricular and periventricular ( mainly preterm neonates)
	Intracerebral (spontaneous, traumatic)
	Subarachnoid hemorrhage
	Subdural hemorrhage
	Cerebral artery and vein infarction
Trauma	Intracranial hemorrhage
	Cortical vein thrombosis
Infections	Encephalitis, meningitis, brain abscess
	Intrauterine (rubella, toxoplasmosis, syphilis, cytomegalovirus, herpes simplex virus, human immunodeficiency virus, coxsackievirus B)
	Postnatal (beta-hemolytic streptococci, Escherichia coli infection, herpes simplex virus, Mycoplasma)
Metabolic	Hypoglycemia
	Neonates of diabetic and toxemic mothers
	Glycogen storage disease
	Pancreatic disease
	Hypocalcemia
	Hypomagnesemia
	Hypo/Hypernatremia
	Inborn errors of metabolism
Pyridoxine dependency	
Malformations of cerebral development	All disorders of neuronal induction, segmentation, migration, myelination and synaptogenesis
Neurocutaneous syndromes	Tuberous sclerosis
	Incontinentia pigmentii
Drug withdrawal	Withdrawal from narcotic-analgesics, sedative-hypnotics, and alcohol; heroin- and methadone-addicted mothers; barbiturates

## 4. NEONATAL SEIZURES AND EPILEPSY

### 4.1. FOCAL SEIZURES

Focal seizures are characterized by motor and autonomic signs as well as with sensory symptoms. A child can experience aura which is a brief initial period of a seizure during which consciousness is still preserved. It can be manifested with somatosensory (pins and needles sensation, burning) and psychological (discomfort, nausea, fear) symptoms and visual, olfactory, taste hallucinations.

Jacksonian march is an example of focal motoric seizure which starts with twitches on one side of the face that spread afterward to the ipsilateral extremities. The mouth may froth with saliva on the side of the mouth where twitches are present together with twitches of the eyeballs toward that side. After the motoric seizure, temporary Todd paralysis might occur. Paralysis could last from several hours to up to 7 days with the twisting of the eyeballs in the opposite direction of the side affected by hemiparesis. Focal seizures can originate from temporal, frontal or occipital lobe. (19)

*Focal seizures from the temporal lobe* are common in infants and are manifested with turning of the head and eyes to the one side with the gaze fixation (staring) and movement reduction (hypomotor seizures). Sometimes automatisms, motor dysphasia and phenomenon such as *déjà vu* (subjective experience as though we were already in an environment or as if we experienced it) and *jamais vu* (a feeling of ignorance and disenchantment in the current environment) are present.

*Epileptic seizures from the frontal lobe* are most commonly focal seizures but can also be absence seizures. Seizures are hypermotoric, asymmetric and frequently occurring in series of 10 or more attacks. Head turning to the side followed by the lifting of the arms can be accompanied by bizarre signs (screaming, running around the bed). Structural abnormalities, primarily focal cortical dysplasia and neuronal migration

disorders, are the most common causes of seizures.

Epileptic seizures from the occipital lobe are manifested by the appearance of visual hallucinations, nystagmus, diplopia and temporary blindness.

#### **4.2. GENERALIZED SEIZURES**

An essential clinical feature of generalized seizures is a loss of consciousness.

*Generalized tonic-clonic seizures* are attacks manifested with complete loss of consciousness and rhythmic contractions of the extremities and back musculature. Tonic contraction of the respiratory muscles may cause an expiration induced vocalization and cyanosis. The mouth may froth with saliva. With time jerking stops and muscles are flaccid. The patient may wet him/herself. As the patient regains consciousness, there is post-ictal confusion and often headache.

*Myoclonic seizures* are sudden, brief ( 2 seconds), shock-like contractions. They can be tonic and atonic.

*Atonic seizures* are marked by a sudden loss of postural muscle tone leading to a fall or drop attack.

Non-convulsive seizures can be typical and atypical absence seizures. A *typical absence* seizure is manifested with brief loss of consciousness (2-20seconds). The child stops its activity and stares, sometimes turns eyeballs up or blinks. A seizure can be interrupted by calling the patient. The atypical absence is clinically associated with automatisms, tonic-clonic twitches, autonomic symptoms and affective disorders.

An absence seizure can be provoked with hyperventilation and photostimulation. The EEG shows characteristic 3 Hz spike and wave complexes. (19)

### **4.3. SEIZURES OF UNKNOWN TYPE**

*Epileptic spasms* are unique types of seizure which are similar to tonic seizures but shorter in duration. Infantile spasms are a special type of epileptic spasms that occur as a part of West syndrome. They are depicted by the phase of abduction followed by adduction phase of the extremities. Spasms last 2-10 seconds and are similar to Moro reflex in appearance. Epileptic spasms are usually seen in series, mainly when a child is waking up or going to sleep. Mostly they are symmetric with flexion of the body and head, but can also be one-sided if the cause of epilepsy is structural damage of the brain.

### **4.4. NEONATAL SEIZURES**

Neonatal seizures mostly occur on the first day, but they can happen from birth to the end of the neonatal period which is defined as the first 28 days of the life of the full term infant (24). Due to the immature brain, they are weakly propagated, fragmentary seizures that are focal and often short lasting. The cerebral cortical organization of the brain is not fully achieved in the neonate resulting in higher frequency of symptoms such as mouthing, eye deviation, and apnea then is seen in adults. Another difference between adult and neonatal brain is that generalized tonic-clonic seizures are rarely seen in the first month of life of a full-term infant and not at all seen in the preterm infants (26). The neonatal seizures occur repetitively with a median of a few minutes (8 minutes according to Panayiotopoulos) between each seizure. One neonatal seizure usually lasts from 10 seconds to 1-2 minutes(15;24).

Neonatal seizures are commonly clinically subtle and difficult to recognize from the normal inter-ictal behaviors and physiological phenomena. They have no recognizable post-ictal state (24). Pressler states that additional problems in differentiation arise when a relationship between clinical and electroencephalographic seizures is considered. Sometimes there is an overlap between the two, so-called electroclinical seizures.

"However up to 85% of electrographic seizures are clinically silent" (26). Neonatal seizures can also be tonic seizures, clonic seizures, and myoclonic seizures.

Subtle seizures are the most common presentation of neonatal seizures (50% of cases) occurring in both preterm and term infants. They are frequently overlooked because they imitate normal behavior and reactions.

Signs include: ocular movements, oral-lingual movements, progression movements, autonomic phenomena, complex purposeless movements. (24;15;37)

A clonic seizure is seen in 25% of children with neonatal seizures. They primarily occur in term infants and can be focal or multifocal. Clonic seizures are manifested as rhythmic jerks that may localize in the small part of the face or limbs, axial muscles or diaphragm.

Myoclonic seizure type occurs in 20% of infants, more frequent in preterm than full-term infants. Seizures are characterized by rapid jerks of extremities (upper extremities are affected more than lower extremities). The myoclonic seizures are frequently part of the early myoclonic encephalopathy syndrome which has a poor prognosis(15;24;37).

Tonic seizures (5%) occur predominantly in premature infants. Seizures occur as tonic extensions of the limbs, mimicking decerebrate or decorticate posturing. They have a poor prognosis because they frequently accompany intraventricular hemorrhage(15;24;37).

#### **4.5. EPILEPTIC SYNDROMES BEGINNING IN THE NEWBORN AGE**

*Benign familial neonatal convulsions* are rare disorders with autosomal dominant inheritance manifested with apnea, tonic-clonic seizures, myoclonisms and often epileptic status. A child can have 20-30 seizures per day starting in the first week of life, mostly 2<sup>nd</sup> or 3<sup>rd</sup> day. The prognosis is excellent with normal psychomotor development. (19;26)

*Benign nonfamilial (idiopathic) neonatal convulsions* occur around the fifth day of life (90% between day 4 and 6). Characterized by focal clonic seizures with apnea. They have a good prognosis. (19;26)

*Early myoclonic encephalopathy* starts in the newborn or early infancy period. Can sometimes occur in the first few hours of life with myoclonisms followed by tonic, infantile spasms and focal seizures. It is commonly caused by hereditary metabolic disorders and less often with brain development disorders. On the EEG burst suppression activity is noticed which later evolves into atypical hypsarrhythmia. Prognosis is very poor- seizures are pharmaco-resistant with the development of psychomotor retardation. Mortality is high (>50%), and at age 3-5 months it can evolve into West syndrome. (19;26)

*Ohtahara syndrome or early infantile epileptic encephalopathy* starts in the first 3 months of life and usually within first 10 days (being the earliest age-dependent neonatal epileptic encephalopathy). Characterized with frequent tonic and myoclonic seizures (100-300 per day) and progressive psychomotor regression. Various brain development disorders and rarely inherited metabolic diseases and gene mutations can cause Ohtahara syndrome. If the child survives early infancy period, it will most probably develop West syndrome. (19;26;13) Seizure control can be established with vigabatrin, phenobarbital or through steroid therapies using ACTH and prednisone. Treatment with ketogenic diet and vagus nerve stimulation can also be beneficial to the patient.

#### **4.6. EPILEPSY ARISING IN THE INFANT**

*West syndrome* is a relatively common severe form of epilepsy occurring in the first year of life (3-12 months). "Infantile spasms occur in roughly 2-3 per 10,000 live births, with a peak incidence at 6 months of age and less than 10% of cases presenting after 12 months of age." (20) Triad of infantile spasms, developmental deterioration and hypsarrhythmia pattern on EEG are characteristic for it. In 60 % of cases it occurs in



infants that have an underlying brain pathology-*symptomatic West syndrome*. West syndrome is also possible in completely healthy infants – cryptogenic West syndrome.

Symptomatic West syndrome can be caused by congenital anomalies of brain development (cortical dysplasia), intrauterine and perinatally acquired infections, perinatal brain damage caused by ischemic stroke or intracranial hemorrhage, neurocutaneous and hereditary metabolic diseases. (19)

Infantile spasms are concurrent, symmetric contractions of the extremities, body, and neck that last 2-10 seconds and are followed by relaxation. Spasms may be isolated at the onset but typically form clusters later in the course. Each spasm begins with a rapid abduction of shoulders and extension of elbows and fists followed by adduction and flexion which is similar to Moro reflex. Seizures most commonly occur when a child is waking up or falling asleep.(19;13)

Interictal hypersarrhythmia on EEG consists of disorganized pattern with asynchronous, very high amplitude slowing and frequent multifocal spike and sharp wave discharges. Ictal EEG typically shows generalized slow wave followed by diffuse voltage attenuation. (13) MRI is always necessary to exclude morphological anomalies.

Treatment of West syndrome is usually started with vigabatrin and ACTH. Vigabatrin is particularly effective in suppressing infantile spasms in children with tuberous sclerosis. Otherwise, treatment with ACTH seems more effective. No matter which drug is chosen for treatment, it is essential to start with it as soon as possible. Goal of therapy is not just to stop infantile spasms but to preserve brain function. Other antiepileptics that can be used are topiramate, levetiracetam, lamotrigine. Corticosteroids may also be useful but not as ACTH.

The ketogenic diet is helpful in the majority of cases. In about ¼ of patients long-term outcome is good ( termination of seizures and IQ >85). Focal cortical resection or

hemispherectomy may be considered in cases that are medically intractable. (13;19)

Developmental prognosis is highly dependable on etiology – normal development is observed in 51% of cryptogenic cases and only 6% of symptomatic cases. "Approximately 17% of cases evolve into Lennox-Gastaut syndrome. (13) This is usually seen in 2<sup>nd</sup> or 3<sup>rd</sup> year of life. West syndrome ends with death in 1/3 of patients. (19)

#### **4.7. EPILEPSY BEGINNING AFTER THE FIRST YEAR OF LIFE**

*Benign childhood epilepsy with centrotemporal spikes (Rolandic epilepsy)* is most common electroclinical epilepsy syndrome in children. The first seizure usually occurs between 4 and 12 years of age. It is manifested with focal seizures occurring most often during night time but can also occur during the day after sleepless night. Seizures are usually focal motoric(simple) or complex, sensory and motoric seizures with neurovegetative symptoms but without consciousness disturbances. They start with somatosensory aura which is followed by hand and face twitches, increased salivation, tongue parasthesias, dysphagia and motor aphasia. On the EEG centrotemporal spikes are seen. Very often inter-ictal EEG is within the normal limits; it is indicated to do EEG after the sleepless night. Treatment is started after the second seizure with carbamazepine. Prognosis is excellent because seizures stop spontaneously, even without treatment, at the age of 14 to 16.

*Myoclonic-astatic epilepsy (Doose syndrome)* starts in the second year of life with myoclonisms, tonic-clonic seizures, epileptic status and atonic seizures. It is differentially very similar to Lennox-Gastaut syndrome, but the prognosis is, unlike in Lennox-Gastaut, 50% more favorable.

*Lennox-Gastaut syndrome* is a devastating pediatric epilepsy syndrome that occurs from the second year of life on with focal and generalized seizures, especially grand mal and atonic seizures with drop attacks during which child sustains injuries. "Overall, LGS

accounts for 1-4% of patients with childhood epilepsy but 10% of patients with onset of epilepsy when younger than 5 years." (13) In children suffering from West syndrome, after the first year of life, Lennox-Gastaut syndrome is frequently developed. Regularly, it is manifested with multiple seizure types, psychomotor retardation and diffuse appearance of slow spike and wave discharges of 2Hz or less on EEG. Treatment involves, apart from pharmacotherapy with valproate and topiramate, vagal nerve stimulation and corpus callosotomy. (13;19) Long-term prognosis overall is unfavorable.

*Autosomal dominant nocturnal frontal lobe epilepsy* is characterized by nocturnal motoric seizures (parasomnia like) and unarticulate vocalizations. It is a lifelong type of epilepsy that usually starts at age 10. In adulthood, attacks become milder and occur less often. Normal neurological and intellectual development are preserved. (19)

*Early-onset benign partial epilepsy with occipital paroxysms (Panayiotopoulos type)* presents with autonomic signs and symptoms and ictal syncope at age 3-5. Seizures are more often during night time and are accompanied by a headache, hemiconvulsions and forcible deviation of eyes or head to the side. Seizures can be brief or long lasting (several hours). (19)

*Benign late-onset childhood occipital seizures (Gastaut type)* appear at the age of 7-10 years and is manifested during daytime with visual symptoms (visual hallucinations, scotomas, temporary blindness). Seizures are easily controlled, and remission occurs 2-4 years after the onset. (19)

*Childhood absence epilepsy* includes epilepsy with generalized absence attacks, juvenile absence epilepsy and epilepsy with myoclonic absences. Most frequently occurs at the age of 6 but can occur earlier (at the age of 3). Absence seizures are followed by a brief termination of activity and loss of consciousness. Sometimes generalized tonic-clonic seizures can occur. Typical EEG report shows 3Hz spike and wave complexes. (19)

#### **4.8. EPILEPSY IN ADOLESCENTS**

*Juvenile absence epilepsy* has an onset at age 8 to 20 years of age (peak at 9-13 years). May present with generalized tonic-clonic seizures before the onset of absence. Learning difficulties and attention deficit hyperactivity disorder can occur. Less responsive to valproate and ethosuximide unlike childhood absence epilepsy.

*Juvenile myoclonic epilepsy (Janz syndrome)* is a relatively common idiopathic generalized epilepsy, representing 10-30% of all myoclonic epilepsies with generalized tonic-clonic seizures. Demonstrated with brief episodes of involuntary muscle twitches in teenagers 12-16 years of age. Seizures can be induced by exhaustion, excitement, stress and menstrual period. Janz epilepsy has an excellent prognosis, and it is treated with valproate and topiramate.

#### **5. DIAGNOSIS OF EPILEPSY AND EPILEPTIC PROCEDURES**

To diagnose the epilepsy etiology with certainty, we use many different diagnostic procedures. It is important to stress out that diagnosis of epilepsy could not always be (and especially in newborn period) established according to ILAE definition. Since infants suffered from hypoxic-ischemic encephalopathy, the brain is damaged resulting in hyperexcitability and a higher probability of seizure recurrence. That is why one event of seizure is enough to classify it as epilepsy (5).

*Clinical assessment* of seizure type may be inaccurate without EEG recording but describing the observed seizure is most important for the establishing of seizure type and epilepsy afterward. It is important to describe:

- a) types of movements, limb and body involvement
- b) duration and frequency of movements
- c) when did the movements occur – during sleep or awake state

d) if the movement stopped with limb restraint

e) can the movement be provoked with tactile stimulation (23).

And ultimately and imperatively to differentiate nonepileptic from epileptic seizures which is often very difficult even for subspecialists in developmental neurology.

Through family and prenatal history are essential. Evidence of intrapartum asphyxia has to be considered. Intrapartum asphyxia is defined by at least 3 of the following: late decelerations on fetal monitoring or meconium staining, arterial cord blood pH <7.1, delayed onset of respiration, Apgar score <7 at 5 minutes, and multiorgan damage (10).

Laboratory tests are needed to ascertain the etiology of seizures. The crucial ones are serum glucose and electrolytes levels, TORCH (toxoplasmosis, rubella, CMV, herpes virus), urine organic acid, serum amino acid assay, renal function test. The cerebrospinal fluid analysis should be done to check for: pleocytosis, xanthochromia, lactic acid and pyruvate, herpesvirus type 1 and 2PCR, and glucose concentration (31).

*Brain imaging* is used for detection of structural abnormalities such as malformations of cortical development, hydrocephalus, infections and intracranial hemorrhage. Diagnostic method considered to be part of the brain imaging methods are cranial ultrasonography, computed tomography and magnetic resonance imaging (24).

Cranial ultrasonography is useful as a first line diagnostic method for exclusion of gross CNS pathology (26). It is the primary modality used in premature neonates. Additional advantages of cranial ultrasonography are that it can be used at the bedside, provides a proper assessment of ventricular size as well as a good view of ischemic and hemorrhagic lesions (24).

*Computed tomography scan* is used when additional testing is needed in children that continue to have seizures or have abnormal inter-ictal neurological signs (26). High-resolution scans generated within seconds can detect hemorrhage, infarction, gross

malformations, etc. It has low sensitivity when it comes to abnormalities of cortical development; in such cases, MRI is more superior and presents imperative for the evaluation of epilepsy etiology(24).

*Electroencephalography* (EEG), especially ictal EEG has the vital role in differentiating between neonatal seizures and non-epileptic events. If the outbreaks last more than 10 seconds, they are considered to be seizures. The typical duration of seizures on EEG is 2-3 minutes. "Neonatal seizures have focal onset whereas generalized spike and wave seizures are infrequent" (26).

*Continuous video electroencephalography* (cEEG) in 10-20 electrode systems is the gold standard for monitoring of neonatal seizures. Continuous EEG should be maintained until 3-4 clinical events have been caught and determined not to be seizures or until electrographic seizures have disappeared for at least 24 hours (8).

*Amplitude-integrated electroencephalography* (aEEG) is a neurophysiological tool that is user-friendly and can be used at the bedside. Amplitude-integrated EEG started to replace cEEG in many medical centers (8).

Only 10% of neonates have EEG confirmation of seizures. Out of that 44 % of clonic seizures can be identified by EEG and only 17% of subtle seizures (24). Tonic spasm is associated with delta wave activity whereas clonic seizures are represented by a repetitive spike and wave discharges. Myoclonic seizures are often associated with other seizure types and with a burst suppression pattern with or without ictal correlation (27).

Burst suppression pattern is an age-dependent EEG pattern characterized by high voltage discharges interchanging with periods of low amplitude activity typical in early-onset epileptic encephalopathies. A burst suppression pattern can be induced with high doses of barbiturates and other neuroactive medications (as anesthetics) as well. In the absence of high concentrations of neuroactive drugs, burst suppression pattern is

associated with poor prognosis. Infants who have a changeable pattern with stimulation have somewhat better prognosis (1).

Ictal EEG paroxysms consist of repetitive waves with a beta, theta, alpha, and delta range or a mixture of all. Represented as spikes sharp, sawtooth or sinusoidal surges ranging in amplitude from very low to very high. In the course of the same or subsequent seizures, ictal discharges may change, abruptly or gradually, in amplitude, frequency, and morphology(24). Characteristic ictal EEG patterns seen in epilepsy caused by hypoxic-ischemic encephalopathy are:

- a) focal spikes or sharp wave discharges of progressively increasing amplitude – corresponding to contralateral jerking
- b) multifocal spike and sharp wave discharge with independent frequencies in multiple foci – associated with variable seizure types; prognosis depends on the background EEG abnormalities
- c) prehypsarrhythmic and hypsarrhythmic patterns which are usually interictal (33). Post-ictal usually promptly returns to the preictal state.

*Video polysomnography* is indicated in preterm infants to exclude sleep-related respiratory disorders that may endanger it after release from the neonatal unit (33).

## 6.TREATMENT OF SEIZURES AND EPILEPSIES

### 6.1.ANTIEPILEPTIC DRUGS

When the etiology of neonatal seizures is known neonate may be treated with specific therapy. When the cause is not identifiable anticonvulsant treatment is started (19).

A neonatal seizure is an emergency that has to be treated immediately to prevent brain injury. Glucose levels and oxygen saturation should be assessed because they are one of the easily treatable causes. The first step in management is proper ventilation and perfusion as well as treatment of hypoglycemia - 10% glucose solution should be given intravenously (0,5 g/kg = 5ml/kg).

Electrolyte disturbances that can trigger seizures are hypocalcemia and hypomagnesemia. Hypocalcemia is treated with 10% calcium gluconate solution, 5 ml is given intravenously very slowly over at least 5 minutes. Hypomagnesemia is treated with 5 ml 2% magnesium sulfate solution applied intravenously. 50 mg of pyridoxine hydrochloride is given intravenously in neonates with vitamin B<sub>6</sub> dependency (19).

If seizure duration is longer than 5 minutes the neonates should be treated first with phenobarbital i.v. If seizure continues after application of phenobarbitone, midazolam or levetiracetam i.v. should be administered.

*Benzodiazepines* work by enhancing GABA<sub>A</sub> receptor responses and are used in seizures refractory to phenobarbital and/or phenytoin (22; 36). Lorazepam is more commonly prescribed benzodiazepine due to its longer half-life in comparison with diazepam and midazolam. Midazolam is short acting and has a more rapid onset of action (22). Monitoring respiration is crucial; respiratory depression is a possible side effect.

*Lidocaine* is an excellent drug for refractory seizures. Studies showed that it has moderate efficacy as second-line treatment (22). It is given in intravenous infusion (3-4



mg/kg/hour over 12-24 hours) (19).

Epilepsy should be treated with different AED according to seizure types and EEG, regarding the type of epileptic syndromes or epileptic encephalopathy. Although short-acting benzodiazepines such as diazepam are widely used (24;31).

Antiepileptic drugs in infants are often tapered and discontinued after 3-6 months of age if new seizures have not occurred. EEG is helpful in deciding when to stop them (31). If the seizures recur than an infant should be put back on anticonvulsants. Since phenobarbital and phenytoin have disadvantages, long-term side effects and difficulty maintaining levels respectively, other medications may be considered. Levetiracetam, oxcarbazepine, and topiramate are some of the options(31).

*Phenobarbital* is a drug of choice in generalized tonic-clonic seizures in infants. It acts by enhancing GABA<sub>A</sub> receptor responses; has a long half-life (36). Except for anticonvulsive properties, it decreases metabolism of a brain by decreasing sensory and motor cortex activity (19). One-third of neonatal seizures are controlled with a loading dose of 15-20 mg/kg and maintenance dose of 3-4 mg/kg daily (24). Phenobarbital was named orphan drug for the treatment of neonatal seizures by FDA.

*Phenytoin* acts by blocking voltage-gated Na<sup>+</sup> channels. It works in the motor cortex where it inhibits spread of seizure activity. It has many side effects such as ataxia, diplopia, nystagmus and it is cardiotoxic (36). Phenytoin is equally effective as phenobarbitone at a loading dose of 15-20 mg/kg. Fosphenytoin is a good potential alternative to phenytoin because of less adverse side effects and the possibility for intramuscular administration (24). Although phenobarbital and phenytoin are effective in only one-third of affected infants, they are still used as a first line antiepileptic in infants (32).

*Carbamazepine* is an antiepileptic that blocks voltage-gated Na<sup>+</sup> channels and decreases glutamate release. It is used in the treatment of generalized tonic-clonic and partial seizure(36). Use of carbamazepine in neonates is still under investigation.

*Levetiracetam's* mechanism of action includes binding to the synaptic protein. It is used in generalized tonic-clonic and partial seizures as well as a backup drug in myoclonic syndrome(36). It is increasingly used for the treatment of neonatal seizures (11). Han et al. did a research analysis on 37 preterm infants of which 57% were seizure free while given levetiracetam at the end of the first week of life. Loading doses ranged from 40-60 mg/kg (mean dose 56 mg/kg) and maintenance dose ranged from 20-30 mg/kg ( mean dose 23 mg/kg) (14).

*Topiramate* has multiple mechanisms of action including glutamate receptor inhibition and Na<sup>+</sup> voltage channel block (22; 36). Used for generalized tonic-clonic and partial seizures, absence seizure. Topiramate appears to have neuroprotective effects in animals with seizures and brain injury (8).

*Valproate* is an effective AED used for the treatment of recurrent, usually generalized, seizures and status epilepticus. It should be used with great caution because it has a high risk of fetal hepatotoxicity in neonates, in girls and women of child-bearing age, it should be used with caution because it can cause hormonal disturbances such as polycystic ovarian syndrome, obesity and it is also teratogenic (22).

*Vigabatrin* acts by inhibiting GABA transaminase. It is used as an adjunctive drug in the treatment of refractory epilepsies, focal seizures, bilateral seizures and as a monotherapy for infantile spasms in West syndrome.

*Ethosuximide's* mechanism of action is decreasing Ca<sup>2+</sup> current. Used in the treatment of absence seizures. Side effects are usually minimal (loss of appetite, abdominal pain, diarrhea) but awareness about less frequent serious adverse effects(

suicidal thoughts, low blood cell levels, lupus erythematosus) is essential.

TABLE 6.1.1. Antiepileptic drugs used in seizure treatment ( According to Neubauer et al.,2013.)

ANTIEPILEPTICS	
1 <sup>st</sup> line antiepileptics	Phenobarbital Benzodiazepine Phenytoin
2 <sup>nd</sup> line antiepileptics	Levetiracetam Valproate Topiramate Lamotrigine
Rarely used antiepileptics	Carbamazepine

If the seizures occur despite regular antiepileptic administration change of therapy is indicated. If epilepsy is unresponsive to polytherapy, pharmaco-resistant epilepsy (seen in 20-30% of patients), different treatment options have to be considered.

## 6.2. ADRENOCORTICOTROPIC HORMONE (ACTH)

ACTH is a hormone that is released from the pituitary gland. It stimulates the release of adrenal glucocorticoids and activates glucocorticoid receptors in the CNS.

It is administered intramuscularly for the treatment of infantile spasms. Successful treatment is observed in 86-88% of cases. (3) Additional research is needed to establish the best dosage regimen. Several studies suggest that it may be appropriate to start with 20 units/day or 150 units/m<sup>2</sup>. After 14 days of treatment, ACTH dosage is tapered.

Possible side effects are weight gain, irritability, infection at the site of administration,

glycosuria, high blood pressure, edema, weakness of the immune system. (3, 21)

### **6.3. CORTICOSTEROIDS**

Prednisolone is one of the treatment options for West syndrome. Studies suggest that corticosteroids are less effective than ACTH and vigabatrin. Anyhow, prednisolone is often used because it is readily available, cheap, easy to administer and has side effects that are more tolerable than that of ACTH.(21)

### **6.4. KETOGENIC DIET**

A ketogenic diet is a high-fat, low-carbohydrate diet that is used in children with intractable seizures that are unresponsive to polytherapy administered. It is prescribed in 4:1 or 3:1 ratio (3 to 4 grams of fat for every 1 gram of carbohydrates or protein). The 4:1 ratio diet is used in most children.

It is useful in infantile spasms, Dravet syndrome, tuberous sclerosis complex and Doose syndrome. Beneficial effects were also seen in children with focal seizures. Nelson in his paper states that studies have reported that 14-65% of children became seizure-free within 1-3 months. (21)

### **6.5. VAGAL NERVE STIMULATION**

Vagal nerve stimulation is an adjunctive therapy for intractable epilepsy. Mostly used for focal seizures in children older than 12 years.

A generator that delivers regular intermittent stimuli is implanted in the chest and connected to the left cervical vagus nerve. Surgery is completed within 2 hours and patient is discharged home on the same day. Possible side effects are tingling sensation in the throat, voice alterations, coughing. (38)

### **6.6. CORPUS CALLOSOTOMY**

Corpus callosotomy is used in patients with refractory epilepsy in which treatment with VNS was unsuccessful and who are not candidates for excisional surgery.

Most commonly performed is anterior callosotomy. It involves cutting of the anterior midbody of the corpus callosum that carries intrahemispheric motor connections.

Main side effects are speech difficulties afterward. (35)

## **6.7. THERAPEUTIC HYPOTHERMIA**

Therapeutic hypothermia is a relatively new method used in neonates with hypoxic-ischemic encephalopathy to prevent further brain damage. It involves head cooling and/ or total body cooling. The therapeutic window for implementing hypothermia is rather short and last only 3-6 hours after birth (10). Infants are placed under hypothermic conditions ( temperature of 33 °C) for 72 hours after that time temperature is increased slowly (0.5 °C/ hour). Possible adverse effects that can occur during hypothermia are cardiac arrhythmia, acidosis, major vessel thrombosis or bleeding, skin changes and death (30).

Shankaran et al. in their research showed that: "whole body hypothermia reduces the risk of death and disability in infants with moderate or severe hypoxic-ischemic encephalopathy" (30).

Liu et al. in their cohort study concluded that infants that were cooled for perinatal asphyxia needed lower dosages of AED later in life, 6 % of infants with epilepsy at 2 years (2% on AED) and 13% of school-aged children ( 7% on AED). (16)

## 7. PROGNOSIS

Neonatal seizure prognosis is highly dependable on the etiology of the seizure. More than half of newborns with hypoxic-ischaemic encephalopathy will develop neonatal seizures. Despite high mortality and morbidity 50% of neonates with seizures will reach normal or near-normal development. 30% of children with neonatal seizures develop epilepsy later in life, most of which develop epilepsy by 3 and half years of age. (15;27).

Neonatal seizures caused by HIE might affect neurodevelopment and predispose a child to development of epilepsy, cognitive and behavioral disorders in post-neonatal life. Prolonged seizures cause progressive cerebral hypoxia, changes in cerebral blood flow, edema and lactic acidosis causing additional brain damage. Worse prognosis is expected in preterm infants, infants with hypoxic-ischemic encephalopathy, meningitis, and cerebral malformations.

Very poor prognosis is seen with several epileptic encephalopathies such as early myoclonic epilepsy and Ohtahara syndrome as well as Lennox-Gastaut syndrome. Prognosis of West syndrome depends on the etiology. Symptomatic West syndrome has a poorer prognosis. Unlike so far mentioned epilepsies Rolandic epilepsy has an excellent prognosis because it stops spontaneously in teenagers.

Most patients with focal epilepsy are treated with AEDs for 2 years. If the patient remains seizure-free during that time AEDs are tapered down. Tapering should be done gradually because otherwise, it can cause withdrawal seizures. About one-third of patients continue to have seizures despite polytherapy. Others have good seizure control but suffer from severe side effects of AEDs.

## **8.CONCLUSION**

Majority of neonatal seizures, 80% to be exact, are caused by the hypoxic-ischaemic encephalopathy. Hypoxic-ischaemic encephalopathy can occur prenatally or perinatally, and it is associated with disturbed cerebral blood flow. Neonatal seizures and different epilepsy types are one of the possible consequences of hypoxic-ischemic encephalopathy.

The most important factor in the management of seizures is their clinical diagnosis that has to be confirmed by EEG. The first step in treatment is to start symptomatic therapy to treat the underlying cause. Commonly used antiepileptic drugs are phenobarbital and phenytoin for epileptic seizures and epilepsies in neonates. Benzodiazepines, and anesthetics are used for the treatment of refractory seizures.

Prognosis of seizures depends on early diagnosis and treatment. Most of the children are taken off the antiepileptics during their childhood, and they live a seizure-free life. Children who developed epilepsy after HIE should be treated according to accepted protocol at least two years after seizures resolve, also depending on EEG findings and psychomotor development of a child. Epilepsy is resolved when a child is without seizures for 10 years, and 5 years without AED medications.

## **9.ACKNOWLEDGMENT**

I would like to thank my mentor prof.dr.sc. Nina Barišić for her support, guidance, and knowledge that she kindly shared with me. I hope that this review paper will show how honored and grateful I am for the opportunity to have been working with her.

I would also like to thank other members of the Pediatric Ward at the Clinical Hospital Center Rebro, as well as other members of my graduation thesis committee: doc.dr.sc Irena Senečić-Čala and prof.dr.sc Marija Jelušić.

At last, I would like to thank my family and friends for their support throughout the years.



## 10. REFERENCES

1. Aminoff M. (2012.) Aminoff's electrodiagnosis in clinical neurology. Edinburgh]: Elsevier/Saunders
2. Barry, P., Morris, K., Ali, T. (2010.), Paediatric intensive care, New York, Oxford University Press Inc.
3. Brunson K., Avishai-Eliner S., Baram T.Z.; ACTH treatment of infantile spasms: mechanism of its effects in the modulation of neuronal excitability (2002.) *Interventional Review of Neurobiology*. 2002;(49):185–197.
4. Drislane, F. (2018). *Blueprints Neurology*. [S.I.]: WOLTERS KLUWER.
5. Epilepsy Diagnosis.org [Internet]. 2018 Available from <https://www.epilepsydiagnosis.org/index.html>
6. Fisher R, Boas W, Blume W, Elger C, Genton P, Lee P et al. Epileptic Seizures, and Epilepsy: Definitions Proposed by the International League Against Epilepsy (ILAE) and the International Bureau for Epilepsy (IBE). *Epilepsia*. 2005;46(4):470-472.
7. Futrakul, S., Praisuwanna, P., Thaitumyanon (2006.). Risk factors for hypoxic-ischaemic encephalopathy in asphyxiated newborn infants. *Journal of the Medical Association of Thailand*, Vol.89. No.3 pp.322-328
8. Glass, H. (2014.). Neonatal seizures: Advances in mechanisms and management. *Clinical Perinatology*, 41(1), pp.177-190
9. Glass, H., Hong, K., Rogers, E., Jeremy, R., Bonifacio, S., Sullivan, J., Barkovich, A. and Ferriero, D. (2011). Risk Factors for Epilepsy in Children With Neonatal Encephalopathy. *Pediatric Research*, 70(5), pp.535-540.
10. Graham, E., Ruis, K., Hartman, A., Northington, F. and Fox, H. (2008). A systematic review of the role of intrapartum hypoxia-ischemia in the causation of neonatal

- encephalopathy. *American Journal of Obstetrics and Gynecology*, 199(6), pp.587-595.
11. Han J, Moon C, Youn Y, Sung I, Lee I. Efficacy of levetiracetam for neonatal seizures in preterm infants. *BMC Pediatrics*. 2018;18(1).
  12. Kandel, E., Schwartz, J. and Jessell, T. (2000). *Principles of neural science*. New York: McGraw-Hill, Health Professions Division.
  13. Khan S, Al Baradie R. Epileptic Encephalopathies: An Overview. *Epilepsy Research and Treatment*. 2012;2012:1-8.
  14. Kharoshankaya, L., Stevenson, N., Livingstone, V., Murray, D., Murphy, B., Ahearne, C. and Boylan, G. (2016). Seizure burden and neurodevelopmental outcome in neonates with hypoxic-ischemic encephalopathy. *Developmental Medicine & Child Neurology*, 58(12), pp.1242-1248
  15. Knežević-Pogančev M. (2016.). Neonatal Seizures Characteristics and Prognosis. *Epilepsy Journal*. 2016;2(3).
  16. Liu X, Jary S, Cowan F, Thoresen M. Reduced infancy and childhood epilepsy following hypothermia-treated neonatal encephalopathy. *Epilepsia*. 2017;58(11):1902-1911.
  17. Mandal, A., Epilepsy-pathophysiology, News Medical Reference, <https://www.news-medical.net/health/Epilepsy-Pathophysiology.aspx> Last updated: 27 February 2018.
  18. Marcdante, K.J., Kliegman, R.M. (2015.). *Nelson essentials of pediatrics*. Philadelphia, Elsevier Saunders
  19. Mardešić, D. (2016). *Pedijatrija*. Zagreb: Školska knjiga.
  20. Miller, S., Sullivan, S., Ireland, Z., Chand, K., Colditz, P. and Bjorkman, S. (2016). Neonatal seizures are associated with redistribution and loss of GABA<sub>A</sub>  $\alpha$ -subunits in the hypoxic-ischaemic pig. *Journal of Neurochemistry*, 139(3), pp.471-484.

21. Nelson G. Management of infantile spasm *Translational Pediatrics*. 2015;4(4):260–270.
22. Neubauer D, Soltirovska-Salamon A, Osredkar D, Paro-Panjan D. Management of refractory neonatal seizures. *Research and Reports in Neonatology*. 2014;:17.
23. Osborn, D.(2013.). Newborn care guidelines: Seizures. Royal Prince Alfred Hospital, available at:  
<https://www.slhd.nsw.gov.au/rpa/neonatal%5Ccontent/pdf/guidelines/seizures.pdf>
24. Panayiotopoulos C. *The epilepsies*. Oxfordshire, UK: Bladon Medical Publishing; 2005.
25. Perlman, J. (2006). Summary Proceedings From the Neurology Group on Hypoxic-Ischemic Encephalopathy. *Pediatrics*, 117(Supplement 1), pp.S28-S33.
26. Pressler, R., M., Neonatal seizures, Department of Clinical Neurophysiology, Great Ormond Street Hospital, London, 2015.  
<https://www.epilepsysociety.org.uk/.../Chapter06Pressler2015.pdf>
27. Robertson, C., Perlman, M., (2006.). Follow-up of the term infant after hypoxic-ischaemic encephalopathy. *Pediatrics and Child Health*,2006;11(5): pp. 278-282
28. Rocha-Ferreira, E. and Hristova, M. (2016). Plasticity in the Neonatal Brain following Hypoxic-Ischaemic Injury. *Neural Plasticity*, 2016, pp.1-16.
29. Scheffer I. Et al. ILAE classification of the epilepsies: Position paper of the ILAE Commission for Classification and Terminology. *Epilepsia*. 2017;58(4):512–521.
30. Shankaran,S., Laptok,A.,R., Ehrenkranz,A.,R., Tyson,J.,E., McDonald,S.,A., Donovan,E.,F., Fanaroff,A.,A., Poole,W.,K., Wright, L.,L., Higgins,R.,D., National Institute of Child Health and Human Development , Neonatal Research Network (2005.). Whole body hypothermia for neonates with hypoxic-ischaemic encephalopathy. *The New England Journal of Medicine*, 353, pp.1574-84

31. Sheth, R. (2017.) Neonatal Seizures Workup: Approach Considerations, Imaging Studies, Medscape reference. Updated 6 September 2017  
<https://emedicine.medscape.com/article/1177069-workup>
32. Shetty, J. (2015). Neonatal seizures in hypoxic-ischaemic encephalopathy - risks and benefits of anticonvulsant therapy. *Developmental Medicine & Child Neurology*, 57, pp.40-43.
33. Silvestri-Hobson et al. (2016.) Abnormal Neonatal EEG: Neonatal EEG, The Normal Neonatal EEG, The Abnormal Neonatal EEG Medscape reference Available from:  
<https://emedicine.medscape.com/article/1139692-overview#a7>
34. Taniguchi, H. and Andreasson, K. (2008). The Hypoxic Ischemic Encephalopathy Model of Perinatal Ischemia. *Journal of Visualized Experiments*, (-1).
35. Taraschenko O, Pedavally S, Samson K, Puccioni M, Madhavan D. Anterior corpus callosotomy in patients with drug-resistant epilepsy: Invasive EEG findings and seizure outcomes. *Epilepsy & Behavior Case Reports*. 2018;9:12-18.
36. Trevor. Katzung & Trevor's Pharmacology Examination and Board Review, 10th Edition. McGraw-Hill; 2013.
37. University of California San Francisco, Benioff Children Hospital, 2004., Intensive care nursery house staff manual: Neonatal seizures, Available at:  
[https://www.ucsfbenioffchildrens.org/pdf/manuals/48\\_Seizures.pdf](https://www.ucsfbenioffchildrens.org/pdf/manuals/48_Seizures.pdf)
38. Uthman B. Vagus Nerve Stimulation for Seizures. *Archives of Medical Research*. 2000;31(3):300-303.
39. Zanelli S.A. et al. (2018) Hypoxic-Ischemic Encephalopathy, Medscape Reference <https://emedicine.medscape.com/article/973501-overview#a5,5> , Updated 11 January 2018

## **11.BIOGRAPHY**

This graduate, this in the form of a review paper, is written by Rima Salman. Rima was born on July 4<sup>th</sup>, 1990 in Zagreb where she lived since. After finishing elementary school Rudeš, she enrolled into nursing school "Škola za medicinske sestre Vinogradska. During this time I was reassured that medicine is what I want to pursue in life, my passion for medicine has increased even more. I hope that in my future career I will be able to practice in the field of Neuropediatrics, not only because I love working with children but also because this topic is very dear to my heart.