

Neonatal liver failure

Ćaćić, Ivana Marija

Master's thesis / Diplomski rad

2014

Degree Grantor / Ustanova koja je dodijelila akademski / stručni stupanj: **University of Zagreb, School of Medicine / Sveučilište u Zagrebu, Medicinski fakultet**

Permanent link / Trajna poveznica: <https://um.nsk.hr/um:nbn:hr:105:790831>

Rights / Prava: [In copyright](#) / [Zaštićeno autorskim pravom.](#)

Download date / Datum preuzimanja: **2024-04-19**



Repository / Repozitorij:

[Dr Med - University of Zagreb School of Medicine Digital Repository](#)



**UNIVERSITY OF ZAGREB
SCHOOL OF MEDICINE**

Ivana Marija Ćaćić

**Neonatal Liver Failure: Gestational
Alloimmune Liver Disease**

GRADUATION THESIS



Zagreb, 2014

This graduate thesis was made at the Department of Paediatrics, University Hospital Center Rebro, Zagreb, mentored by Professor Jurica Vuković, Dr. Med. and was submitted for evaluation during the academic year 2013/2014.

ABBREVIATIONS

ALT:	Alanine aminotransferase
aPTT:	Activated partial thromboplastin time
AST:	Aspartate aminotransferase
CBC:	Complete blood count
CRP:	C-reactive protein
GALD:	Gestational alloimmune liver disease
GGT:	Gamma-glutamyl transferase
HE:	Hepatic encephalopathy
HH:	Hereditary Haemochromatosis
INR:	International normalised ratio
IVIG:	Intravenous immunoglobulin
NH:	Neonatal haemochromatosis
NLF:	Neonatal liver failure
PHD:	Pathohistological diagnosis
PT:	Prothrombin time

TABLE OF CONTENTS

Abstract.....	1
Introduction.....	2
Case Reports.....	5
Discussion.....	16
Conclusion.....	19
Acknowledgements.....	20
References.....	21
Biography.....	23

ABSTRACT

Neonatal liver failure, the failure of the synthetic function of the liver within 28 days of birth, is relatively rare, but unfortunately carries a high mortality rate. There are many different aetiologies of neonatal liver failure, ranging from haematological malignancies to viral infections, from inborn errors of metabolism to drug toxicity. This case review will explore neonatal liver failure due to gestational alloimmune liver disease as seen in three patient families. In addition, prevention of gestational alloimmune liver disease in subsequent pregnancies and the successful birth of healthy or gestational alloimmune liver disease-unaffected siblings to the parents of the aforementioned gestational alloimmune liver disease-affected patients will be discussed. Family 1's first born, soon after birth, showed signs of acute liver failure. He received a partial liver transplant from his father, but despite all efforts, died at five months of age from neonatal liver failure as a result of neonatal haemochromatosis. The mother fell pregnant again and, in order to prevent gestational alloimmune liver disease in the second pregnancy, received intravenous immunoglobulin therapy. As a result, a female infant was born with minor complications, but was deemed healthy soon afterwards. Family 2 had two previous children that had died, soon after birth, from neonatal liver failure caused by neonatal haemochromatosis, in addition to two early spontaneous abortions. While in her fifth pregnancy, the mother received intravenous immunoglobulin treatment, and despite some initial mild hepatic dysfunction at birth, following treatment with intravenous immunoglobulin and phototherapy, a healthy baby boy was discharged soon after admission. Family 3's first child was born prematurely and, at birth, was in haemorrhagic shock due to jejunal perforation and apparent disseminated intravascular coagulation. Despite all therapeutic and surgical interventions, the patient died one month after birth. A year later, the mother fell pregnant and received preventative intravenous immunoglobulin. Although the pregnancy was laden with complications, a healthy male infant was born without any organ dysfunction.

INTRODUCTION

Neonatal liver failure (NLF), the failure of hepatic function within 28 days of birth, has a high mortality, but is fortunately rare. The criteria defining NLF, as established by the Paediatric Acute Liver Failure study group, are as follows: 1) hepatic-based coagulopathy (PT \geq 15s or INR \geq 1.5 not corrected by vitamin K with clinical hepatic encephalopathy (HE) or PT \geq 20s or INR \geq 2.0 with or without clinical HE), 2) biochemical evidence of acute liver injury, and 3) no known evidence of chronic liver disease (1,2). Unlike in the case of adults, the diagnosis of ALF does not require evidence of hepatic encephalopathy since it is difficult to recognize in this age group and it generally presents late in the course of liver failure (1).

There are many causes of NLF, with the most common being neonatal haemochromatosis (NH) (1). NH is defined as severe neonatal disease with extrahepatic siderosis of various tissues, as similarly seen in hereditary haemochromatosis (HH) (3). Although NH has some overlapping features with HH, NH is not autosomal recessively inherited, and, until fairly recently, its underlying cause/mechanism was not fully understood (1,4). After many years of research, Whittington and his research group (4) discovered that nearly all cases of NH are, in fact, due to gestational alloimmune disease (GALD).

The alloimmune basis of NH, and hence of GALD, was initially hypothesised based on several facts: the very high probability of recurrence of NH in subsequent babies born to a mother with a child that previously suffered from NH (up to 90%), the absence of records of women with a NH-affected child having siblings with affected offspring, and the ability for maternal IgG to cross the placenta and attack foetal hepatocytes (as seen in other maternofoetal alloimmune diseases like ABO incompatibility hemolysis, etc.) (2,4). With this discovery, NH has been deemed a symptom and GALD the disease (4). The target of the maternal IgG is currently unknown, but since hepatocytes are the only cells attacked by maternal IgG, it is hypothesised that a hepatocyte-specific antigen is the target of IgG-mediated cell injury (3,4,9). The IgG complement-mediated mechanism of hepatocyte destruction in NH has been confirmed by immunohistochemical staining for C5b-9, a neoantigen formed in the assembly of the membrane attack complex, during terminal complement cascade activation (4,6). Immunohistochemical staining of liver samples, from nearly all neonates or infants with GALD-NH, shows strongly positive staining for C5b-9 complexes in hepatocytes (4,6).

Maternal IgG begins to cross the placenta after the 12th week of gestation, when FcRn begins to be expressed by the placenta, and steeply increases in concentration in foetal blood in the second trimester (3-5). In concordance with the finding that nearly all cases of NH have been attributed to maternal IgG-mediated injury of the liver, most cases of

NH present in late second and third trimester (4). These cases may present with second or third trimester fetal loss or, if the babies are live-born, the pregnancy may be plagued with complications like intrauterine growth retardation, oligohydramnios, and/or premature labour (3,4,7).

The clinical picture may vary greatly for affected live-born babies – rarely, they may have little to no clinical disease or, most commonly, they may present at birth with fulminant NLF (4,7,8). Most of the affected neonates usually present with severe sepsis, hypoglycaemia, severe coagulopathy, hypoalbuminaemia, and oedema (“nonimmune hydrops”), all of which indicate a failure of the liver’s synthesizing function (4,7,9). Jaundice is not characteristically seen right at birth, but develops over the next few days of the neonate’s life (3,4,7). Bilirubin levels are typically increased, both total and direct, with total bilirubin serum levels usually exceeding 513 $\mu\text{mol/L}$ (3,4,7). As opposed to NLF caused by infectious aetiologies, transaminases are normal, or even low, and do not reflect the degree of hepatic dysfunction and damage (3,4,7,9). Characteristic for NH, but not necessarily specific, is a greatly elevated alpha-fetoprotein serum level ($>100,000$ ng/mL) and ferritin levels (>800 ng/mL), but with oversaturation of typically low serum transferrin levels (3,4,7-9). Additionally, NH-affected neonates tend to have a patent ductus venosus, as seen on abdominal ultrasound (4).

As previously mentioned, NH is usually not recognised and is therefore underdiagnosed (4). It should be suspected in neonates who are born with hepatic dysfunction or failure or present with signs soon after birth, and in families with histories of unexplained second trimester spontaneous abortion and stillbirths (3,4). In general, the diagnosis of NH is further explored after other aetiologies of NLF (infectious, metabolic, storage disease, and other) have been excluded (7). As stated above, bilirubin levels will be increased, transaminases will usually be normal or decreased, AFP and ferritin will be greatly increased above reference values, and transferrin levels will be decreased, but transferrin saturation will be high (3,4,7-9).

To diagnose NH, one must be able to establish extrahepatic siderosis (1,3,4,7,9). NH is frequently diagnosed at autopsy and histologic preparation and staining of the affected extrahepatic tissues with Prussian blue or Perl’s stain should be made (1,3,4,6,7,9). In living neonates, extrahepatic siderosis can be seen on MRI where any areas of extrahepatic siderosis will have a lower than expected signal intensity on T2-weighted images (3,4,7). Liver pathohistological examination shows global hepatic necrosis or, sometimes, no viable hepatocytes can be seen and usually no significant fibrosis can be observed (4,7). Oral mucosal or lower lip biopsy for minor salivary glands can also be used to identify

extrahepatic siderosis in NH-affected liveborn neonates or from pathological samples taken at autopsy of stillborn NH-affected babies (4,7-10). However, it is important to note that not all cases of GALD demonstrate extrahepatic siderosis. This may occur when liver injury and/or failure occur so acutely so that extrahepatic siderosis may not have enough time to develop (6). In these cases, GALD may be confirmed with immunohistochemical staining of a liver biopsy with anti-human antibodies for C5b-9 complex, as previously mentioned (4,6).

CASE REPORTS

Family 1

M.I.

M.I. was born on July 29th, 2011. He was the first born to a primigravida mother and the pregnancy was well controlled. The mother was treated with Azithromycin after pathological cervical swab findings and in the seventeenth week of gestation, the mother noticed vaginal bleeding. For the rest of the pregnancy, the mother was on bed rest and was prescribed Utrogestan. In the 36th week of gestation, one day after amniotic fluid began to leak, M.I. was born via emergency caesarean section, after pathological readings had been found on the cardiotocograph. At birth, he weighed 2560 grams, was 48 cm long, and had an Apgar score (1 minute) of 8. His status at birth indicated that he was somatically underdeveloped. He was eucardic and eupnoic. Auscultation of his heart and lungs were unremarkable and his abdomen was slightly meteoric and soft. Extremities and sex organs were also unremarkable and his neurological examination revealed mild hypotonus.

M.I.'s lab values, at admission to the neonatology department, showed a normal leukocyte count but low erythrocyte, haemoglobin, haematocrit, and thrombocyte values. This laboratory picture remained constant throughout the patient's hospital stay, up until his transfer out of the hospital. At birth, M.I. glucose and electrolyte levels were normal, as were liver function tests taken on M.I.'s fifth day of life. The patient's coagulation parameters, however, were abnormal. At 1 day old, M.I.'s PT was 0.42, his INR was 1.58, aPTT was >120s, and his fibrinogen was 0.4 g/L. M.I.'s coagulation parameters remained abnormal and the last tests before hospital transfer revealed a PT of 0.43, INR of 1.5, aPTT of >120s, and fibrinogen 1.0 g/L. The patient's first bilirubin blood levels were evaluated on his third day of life. His total bilirubin was 236.3 $\mu\text{mol/L}$ and direct bilirubin was 50.6 $\mu\text{mol/L}$. At discharge, the patient's total bilirubin was 230.3 $\mu\text{mol/L}$ and direct bilirubin was 128.6 $\mu\text{mol/L}$. As expected with NH patients, M.I.'s AFP was elevated at 29000.8 ng/mL, ferritin was also elevated at 2676.1 ng/mL, and transferrin was low at 0.85 g/L.

Ultrasound of the heart revealed a type II atrial septal defect and a patent foramen ovale, with a minimal stenosis of the right branch of the pulmonary artery. Due to these findings, bacterial endocarditis prophylaxis was prescribed. Ultrasound of the abdomen revealed normal abdominal organs, but throughout the entire abdominal cavity, there was free fluid. Ultrasound of the brain was also within normal limits.

Due to his abnormal coagulation parameters, anaemia, and thrombocytopenia, M.I. received blood transfusions, fresh frozen plasma, activated factor VII, and concentrated platelets. Additionally, to correct his hypoproteinemia, M.I. received intravenous albumin. On his seventh day of life, it was suspected that M.I. had an infection and, thus, broad-spectrum antibiotic therapy was initiated.

At 25 days of age, M.I. was transferred to the paediatric referral centre for Croatia. Further radiological and pathohistological diagnostic workup was carried out and M.I. was diagnosed with NH. Based on his worsening status and diagnosis, it was indicated that M.I. should receive a liver transplant from a family member, and on November 9th, 2011, he received a partial liver transplant from his father. After his surgery and upon admission to the paediatric intensive care unit (PICU), M.I. was hypotensive and was therefore given albumin and vasopressors to help stabilise his blood pressure. Additionally, M.I. had abnormal coagulation parameters (PT 0.40, aPTT 67.7s, fibrinogen 1.0g/L) and ammonia levels of 686.2 $\mu\text{mol/L}$. Liver function tests were also mostly abnormal: total bilirubin 216 $\mu\text{mol/L}$, direct bilirubin 66 $\mu\text{mol/L}$, ALP 344U/L, AST 9701 U/L, ALT 16706 U/L, and GGT 27 U/L.

The first exploratory laparotomy was performed one day after the transplantation when, after the postoperative control ultrasound, thrombosis of the portal vein was suspected. A revision of the portal vein was executed and the control ultrasound showed some portal vein flow, albeit in mixed directions, and free fluid around the liver. On the 10th post-transplant day, another exploratory laparotomy was performed and re-revision of the portal vein was carried out. Six days later, a pathohistological examination of a sample of the transplanted liver was taken. The general picture showed rejection of the grafted liver - ischemic damage of the liver parenchyma with areas of necrosis and changes that may be related to extrahepatic biliary obstruction and hepatic steatosis. Additionally Kupffer cells, when stained with Berlin blue, showed haemosiderin-laden macrophages.

A third explorative laparotomy was undertaken on the 24th post-transplant day. Necrotic sections of the liver were resected and pathological samples and microbiological swabs were taken. PHD showed narrow portal spaces infiltrated with mixed inflammatory cells, including lymphocytes. Furthermore, there was moderate ductular cholestasis, hepatocytes were polymorphic with 60% of them showing macrovesicular and microvesicular steatosis, and more areas of coagulative necrosis and calcification were observed.

On the 43rd post-transplant day, M.I. began showing signs of haemorrhagic shock. A gastroscopy was ordered and haemorrhagic erosive gastritis and a duodenal bulb ulcer were found. At the time, the ulcer showed no signs of active bleeding and therefore conservative treatment and close observation of M.I.'s haemodynamic status was recommended. An

emergency gastroscopy and colonoscopy was performed on the 62nd post-transplant day. In the distal third of the esophagus, two varices of the first degree were found. However, colonoscopy yielded an unremarkable finding.

The rest of M.I.'s stay at the hospital was laden with worsening liver function and multiorgan failure. Pneumonia and cytomegalovirus infection lead to respiratory insufficiency and on 74th post-transplant day, M.I. went into cardiopulmonary arrest and could not be revived.

Ž.I.

M.I.'s mother, T.I., fell pregnant again in July 2012 and it was decided to administer antenatal IVIG to prevent severe GALD in this second pregnancy. The treatment plan followed the suggested guidelines as proposed by Peter Whittington (PF Whittington, personal communication, June 2012). T.I. received 60 mg IVIG in her 14th and 16th weeks of pregnancy and, from the 18th week of pregnancy on, received 60 mg IVIG weekly until the pregnancy reached full-term. The pregnancy was generally unremarkable, except that the mother had thrombocytopenia for which she was admitted on April 18th, 2013 to the Women's Clinic for observation and treatment. T.I. also received prednisone (20 mg per day) and iron supplementation (350mg per day). On April 19th, 2013, in her 38th week of pregnancy, T.I. gave birth vaginally to a female infant, Ž.I., with a birth weight of 3700 g, length of 53 cm, and with an Apgar score of 10/10.

Ž.I. was transferred to the NICU for further work up and observation. She did not receive vitamin K or a hepatitis B vaccine dose at the women's clinic and she did not undergo regular neonatal screening tests. Her examination, upon arrival at the NICU, revealed a fully developed female neonate of 38 weeks gestational age that adapted well to her surroundings. Ž.I. had small petechiae on her cheeks and lips, but the rest of her skin was pink, clean, and without any rashes. She was eucardic, eupnoic, with a heart rate of 117 per minute, oxygen saturation of 97%, and a mean arterial pressure of 57 mmHg. All other examinations were unremarkable except for a basal systolic cardiac murmur of II/VI.

Laboratory tests taken at the NICU revealed a normal CBC, CRP, blood glucose, and electrolyte values. AST and ALT were within normal ranges, however, GGT was elevated (657 U/L). Coagulation parameters were abnormal – PT 0.54, INR 1.35, aPTT 29.9s, fibrinogen 1.3 g/L. After vitamin K administration, PT increased slightly to 0.60, but other parameters did not change significantly. Alpha-fetoprotein levels were elevated (244580 g/L),

as were ferritin levels (484.8 g/L). However, all these values are expected in a GALD patient and, by consensus, no GALD therapeutic intervention was deemed necessary.

On her third day of life, Ž.I.'s total bilirubin was 201 $\mu\text{mol/L}$ (direct bilirubin 12 $\mu\text{mol/L}$) and the day after, her total bilirubin increased to 303 $\mu\text{mol/L}$ (direct 30 $\mu\text{mol/L}$). Due to this increase in serum bilirubin, phototherapy was started. On her seventh day of life, because of suspected perinatal infection, persistent hyperbilirubinemia, and leukocytosis of 20,000 cells/ mm^3 , meropenem therapy was initiated. Two days later, Ž.I. was transferred to the department of paediatric gastroenterology after completion of successful phototherapy. Meropenem therapy was completed after a total of seven days. At discharge, 19 days after birth, Ž.I.'s CBC, electrolytes, liver function tests, platelets, and alpha-fetoprotein levels all fell to normal levels for her age. Only her total and direct bilirubin levels were still elevated (188 $\mu\text{mol/L}$ and 33 $\mu\text{mol/L}$, respectively), but physicians believed that those levels would continue to fall to normal levels soon. Ž.I. was discharged and her parents were ordered to obtain control blood tests and return for a check-up a month later. Ž.I. is currently healthy, with no sequelae.

Family 2

J.K.

J.K. was born to a mother who had previously given birth to two children with confirmed NH, who both died within a week of birth. The first born, a male infant born in 2004, and the second born, a female born in 2008, both died of *E. coli* sepsis and multiorgan failure. Additionally, the mother had two early spontaneous abortions between the second child and J.K.

While pregnant with J.K., the mother went regularly for control check-ups. From the 18th to the 38th week of pregnancy, the mother received 60g IVIG weekly, as recommended by Peter Whittington (11). The mother only had the occasional headache and pressure in her chest after IVIG therapy; however, it is unknown if this was a side effect of the IVIG administration or due to another pre-existing condition.

Labour was induced on December 14th, 2011, in the 40th week of pregnancy. J.K. was delivered vaginally, head first, with a birth weight of 3550 grams, length of 51 cm, and an Apgar score of 10/10. In the delivery room, J.K. received vitamin K and a dose of hepatitis B vaccine. Two hours after birth, he was transported to the neonatology department at the referral centre for Croatia.

At admission to the neonatology department, J.K. was examined. He was well developed for his gestational age, conscious, breathing spontaneously, had a heart rate of 141 beats per minute, a respiratory rate of 50 breaths per minute, blood pressure of 66/42 mmHg, and rectal temperature of 36.8°C. His skin showed no rashes. Auscultation of the heart and lungs revealed normal heart and lung sounds and abdominal examination was unremarkable. Furthermore, extremity, genital, and neurological examinations were all normal.

Laboratory testing, upon admission to the neonatology ward, was performed. CBC was normal except that J.K.'s erythrocyte count was slightly elevated (5.8×10^6 cells/mm³) and haemoglobin levels were also elevated at 208 g/L. Coagulation parameters were as follows: INR 1.76, PV 0.45, aPTT 68s, and fibrinogen 1.1 g/L. Total and direct bilirubin levels were also elevated (49 µmol/L and 13 µmol/L, respectively), as were AST (290 U/L) and GGT (415 U/L), but ALT was within reference range (42 U/L). Electrolytes and glucose were normal, as were his iron and total iron binding capacity values.

Since J.K.'s laboratory results, taken 8 hours after birth, indicated some degree of liver damage (INR 1.75, ferritin 8882 ng/mL, and alpha-fetoprotein 856 950 ng/mL), vitamin E and N-acetylcysteine was given on J.K.'s second day of life, but were stopped the next day due to side effects. To prevent potential worsening of his liver's function, IVIG therapy, 1g/kg body weight (3.5 grams total), was also initiated on his second day of life. The therapy proved successful, as J.K.'s laboratory values improved soon after. By 3 days of age, his INR began to decrease (1.33) and his ferritin levels dropped to 1367 ng/mL. Throughout his hospital stay, J.K.'s coagulation parameters normalised, as seen in figure 2, and on the day before his discharge, his INR was 1.02, PT was 0.93, aPTT was 38.5s, and fibrinogen was 2.3g/L. Due to an increase in leukocytes from 18000 cells/mm³, at admission, to 30000 cells/mm³, on J.K.'s second day of life, empirical antibiotic therapy was given, for a total of 7 days, and at discharge, leukocyte levels were 11000 cells/mm³.

At admission, J.K.'s total and direct bilirubin levels were 49 µmol/L and 13 µmol/L, respectively, and both increased to a maximum on his fifth day of life (total bilirubin 267 µmol/L and direct bilirubin 15 µmol/L). At this point, phototherapy was initiated. Soon after phototherapy was started, J.K.'s bilirubin levels began to decrease and, at discharge, his total and direct bilirubin serum levels were 230 µmol/L and 21 µmol/L, respectively (figure 1).

J.K. was discharged after an eight-day hospital stay. Despite having signs of mildly compromised liver function (mildly deranged lab parameters of liver function, increased AFP, and increased ferritin), IVIG therapy quickly improved the patient's liver function. Since discharge, the patient has been to regular control visits and has no signs of hepatic dysfunction, nor any other medical sequelae.

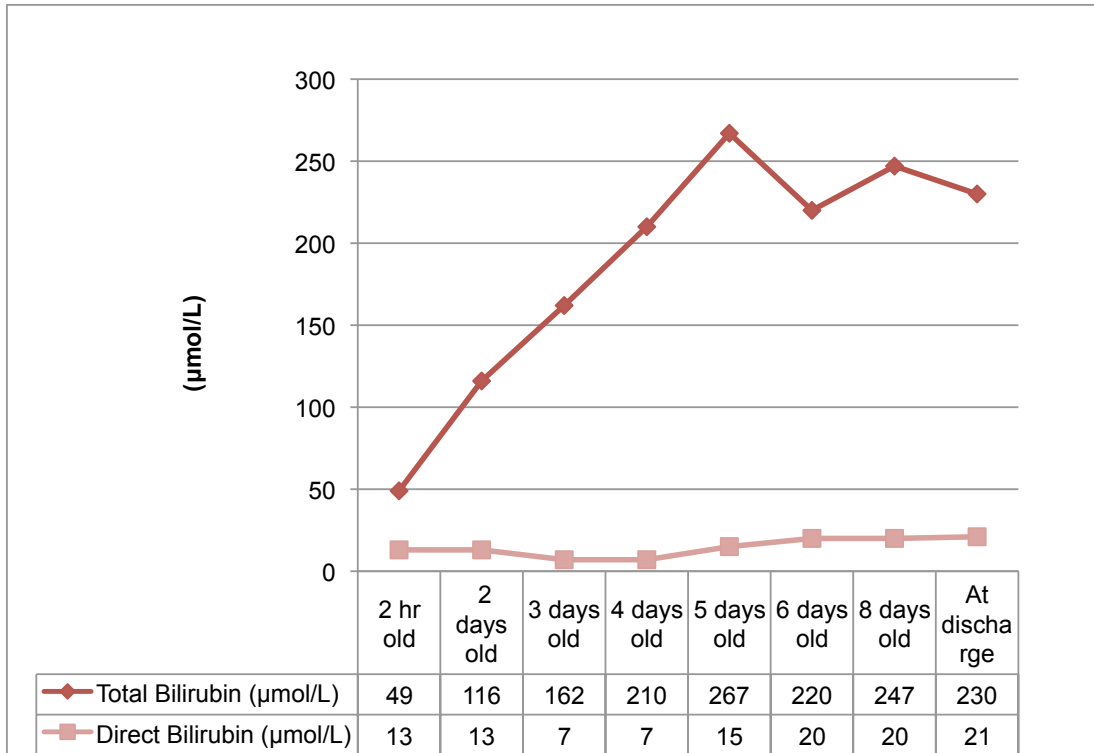


Figure 1. Total and direct bilirubin for patient J.K.

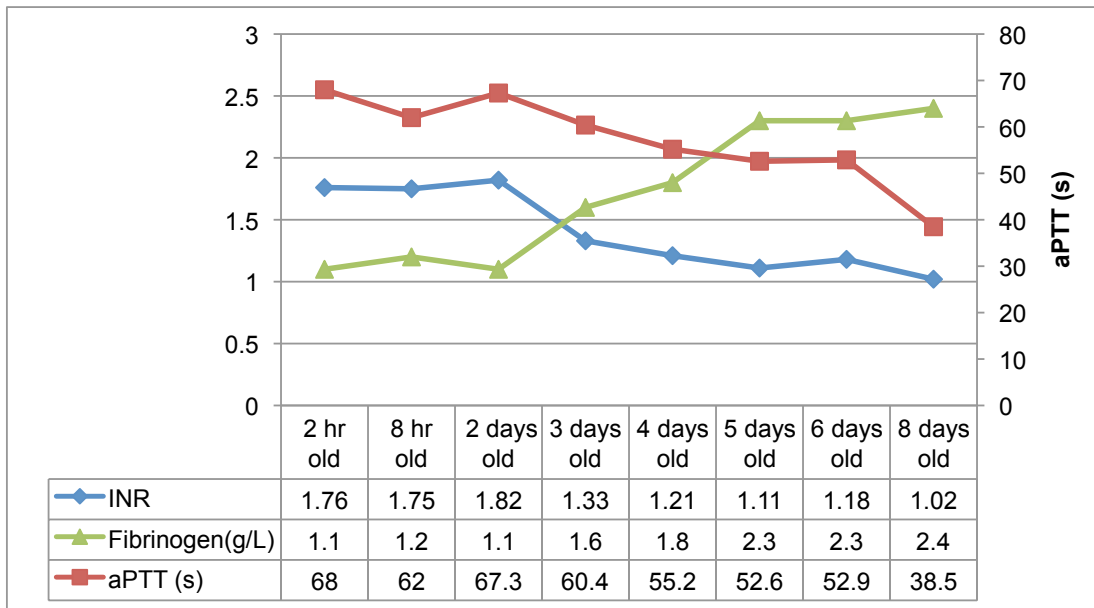


Figure 2. Coagulation parameters for patient J.K.

Family 3

T.A.

T.A. was the first child born to a primagravida mother, on 08.07.2011, at a gestational age of 32 weeks. The pregnancy was well controlled. However, in the 32nd week of pregnancy, because of oligohydramnios and signs of premature labour, the mother was hospitalised at the Woman's Clinic. While hospitalised, the mother received intravenous tocolysis, therapy to induce foetal lung maturation, and empirical antibiotic therapy. Despite these efforts and due to signs of foetal distress on the cardiotocograph, a female baby, T.A., was born via elective caesarean section. T.A.'s birth weight was 1430 grams, birth length was 40 cm, and Apgar score was 7/8. T.A., for a short period of time after birth, was ventilated with a bag-valve-mask, with additional oxygen, after which she had an oxygen saturation greater than 95% and was slightly tachypneic (up to 80 breaths per minute). T.A. was started on empirical antibiotic therapy of ampicillin and gentamicin and received vitamin K. Due to prolonged bleeding at the injection site and gastric bleeding, as seen in the nasogastric tube, T.A. was transferred to the NICU at the paediatric referral centre.

At arrival to the NICU, T.A.'s status and physical examination revealed normal reaction to position, pale skin and visible mucosa, moderate tachypnea and dyspnea (respiratory rate of 50 breaths per minute) on oxygen supplementation and a SpO₂ of 90%. She was eucardic and had a heart rate of 152 beats per minute, hypotensive with a blood pressure of 23/8 mmHg, and peripheral pulses were barely palpable. Auscultatory examination of the heart and lungs were normal, the abdomen was distended, and genital examination was normal. Additionally, from the nasogastric tube, profuse fresh blood was continuously evacuated.

Laboratory values at NICU admission revealed a low erythrocyte count (3.14×10^6 cells/ μ L), haemoglobin (107 g/L), low haematocrit (32%), and thrombocytopenia (47×10^9 cells/L). T.A.'s coagulation parameters were greatly deranged: PT <0.1, aPTT >120s, and fibrinogen <0.3 g/L. Thus, based on her thrombocytopenia and coagulation status, it was evident that T.A. was in disseminated intravascular coagulation (DIC). Liver enzymes, arterial blood gases, serum electrolytes, renal function tests, and markers of inflammatory parameters were, however, all unremarkable. T.A.'s first total bilirubin level, at admission, was 80 μ mol/L and direct bilirubin was 16 μ mol/L. During her stay at the NICU, T.A.'s total and direct bilirubin levels rose steadily until her 14th day of life. These values began to decrease until her last blood tests, at 24 days old, revealed a total bilirubin level of 262 μ mol/L and direct bilirubin level of 110 μ mol/L (figure 3). Furthermore, the patient's total

serum protein level was below reference range at 31 g/L. Ultrasound of T.A.'s brain revealed abnormal findings of a hypoplastic cerebellum, dilated lateral ventricles, a possible left frontal hematoma or infarction, and possible signs of leukomalacia.

T.A.'s initial upper gastrointestinal bleeding was stopped with recombinant factor VIIa with additional fresh frozen plasma and thrombocyte concentrate. To correct the patient's anaemia, packed red blood cells were given in addition to cardiocirculatory inotropic support and empirical antibiotic therapy.

Multi-slice computed tomography of the abdomen, performed on the patient's second day of life, revealed excessive pneumoperitoneum and therefore indicated an gastrointestinal perforation. Based on this radiological finding, T.A. was sent for an explorative laparotomy. During surgery, upon entrance to the abdominal cavity, an abundance of blood and air was visible. Exploration of the intestines revealed a jejunal perforation, 10 cm distal to the ligament of Treitz, spanning 50% of the jejunum's circumference. Exploration of the rest of the gastrointestinal tract revealed no other perforations. All other abdominal organs appeared normal. The jejunal perforation was closed primarily and an intraabdominal drain was put in place. Despite receiving blood transfusions, recombinant factor VIIa and, later on, cryoprecipitate, the patient continued to bleed from her urinary tract, gastrointestinal tract, and lungs.

Nine days after birth, T.A.'s general status worsened and intestinal contents were found in her intraabdominal drain. T.A. was sent for a second explorative laparotomy where an aperistaltic intestine was found in addition to three jejunal perforations and a 4 cm long section of necrotic bowel. Distally, along the jejunum and ileum, multiple livid protrusions of around 3-5 mm were found. 25 cm of the jejunum was resected and a T-T duodenojejunal anastomosis was performed. Pathohistological examination of the resected jejunum revealed multiple small perforations with extravasation of erythrocytes in the wall of the jejunum, clots in the jejunal lumen, and edema and hyperemia of the submucosa.

Soon after, the patient's renal function began worsen as the patient became oliguric and then anuric. Due to renal failure, T.A. was placed on continuous veno-venous hemodialysis. Despite all therapeutic and surgical interventions, T.A.'s coagulopathy could not be corrected and she passed away on August 7th, 2011, thirty days after her birth.

To determine the cause of T.A.'s pathologies, further tests were performed. Analysis for a possible hereditary coagulopathy yielded no results. Post-mortem histological analysis of T.A.'s liver tissue revealed collapsed parenchyma and fibrosis around residual hepatocytes. Immunohistochemical staining of the liver tissue for C5b-9 membrane attack

complexes, performed by Professor Whittington in Chicago, yielded pathological results and confirmed an immune-mediated destruction of hepatocytes leading to NH. Due to the high risk of recurrence of GALD in subsequent pregnancies, T.A.'s mother was advised to consult with a paediatric hepatologist before planning a second pregnancy.

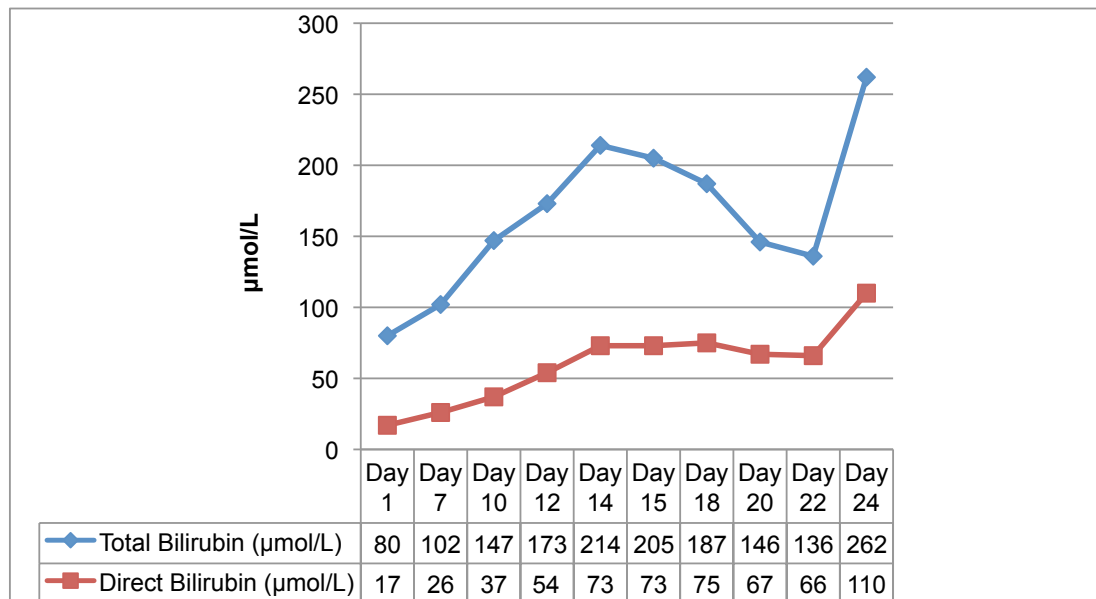


Figure 3. Total and direct bilirubin for patient T.A.

M.A.

The mother of T.A. fell pregnant again in April of 2012. She was admitted, in her 11th+1 week of pregnancy, to the women's clinic due to vaginal bleeding for further workup, observation, and treatment. On ultrasound, a 13 mm retrochorial haematoma was found. While hospitalised, the mother was given dydrogesterone 3x20 mg, benzodiazepine 3x2 mg, and ketoprofen as needed. Throughout her stay, the mother had several bouts of vaginal bleeding. Thrombophilia tests were performed and the mother was found to have hereditary thrombophilia (methylenetetrahydrofolate reductase heterozygote). As a result, low molecular weight heparin therapy was initiated. Furthermore, in order to prevent GALD in this pregnancy, from her 14th week of pregnancy and on, the mother received IVIG therapy. After a psychiatric consult, sertraline and benzodiazepine therapy was prescribed. The mother stayed in hospital for a month and was discharged on 08.08.2012.

On October 20th, 2012, in her 27th week of pregnancy, the mother was re-admitted to the women's clinic because of cervical dilation and an occasional feeling of mild cramping. At admission, cardiotocograph monitoring was normal and the tocodynamometer showed no signs of contractions. The mother remained in hospital for treatment, observation, and bed rest until the birth of a male child, M.A., in her 38+1 week of pregnancy on January 8th, 2013. M.A. was born vaginally, without complications, with a birth weight of 3290 grams, birth length of 50 cm, and an Apgar score of 10/10. M.A. was transferred to the paediatric referral centre for liver function workup.

Examination of M.A., at admission to the NICU, revealed a male, fully developed neonate, with normal vital functions and completely normal physical findings. All laboratory tests were unremarkable and within normal limits, except for a slightly low blood glucose level (2.2 µmol/L) and an increased GGT (404 U/L), AFP (164100 µg/L), and ferritin (1744µg/L). Ultrasound of the abdomen was also normal. To resolve the mild hypoglycaemia, M.A. was given a glucose infusion until he was able to take baby formula per os and he received a dose of hepatitis B vaccine.

At discharge, six days after admission, M.A.'s AFP, ferritin, GGT were falling and all other laboratory tests remained normal. M.A.'s parents were told to take control blood tests and refer to a paediatric hepatologist for regular control check-ups. Currently, M.A. is doing well with completely normal liver function and without signs of any sequelae.

DISCUSSION

For the first NH-affected child within a family, the treatment and management remains disappointing and the prognosis is usually poor. This can be attributed to the fact that the diagnosis of NH is usually delayed and the neonate is plagued with other health issues in addition to their liver failure (e.g., hypoglycaemia, hypoalbuminaemia, marked coagulopathy, and sepsis) (14). Additionally, NH, and thus GALD, is sometimes only considered as a possible aetiology of NLF after other metabolic, infectious, malignant, and drug toxicity aetiologies have been excluded (7). Since, NH is the most common cause of NLF, awareness for this disease needs to be heightened and should be considered as the first differential diagnosis when presented with a neonate with NLF (1,4).

There are no particularly pathognomonic laboratory findings for possible NH patients; however, some clinical presentations and findings should alert physicians to the possibility of NH. NH should be considered in neonates that present at birth with liver failure that is suspected to have begun in utero or in neonates that present with signs of liver failure soon after birth (1,3,4,7,12). As outlined by the Paediatric Acute Liver Failure study group, for the diagnosis of NLF, the neonate must have a hepatic-based coagulopathy (PT ≥ 15 s or INR ≥ 1.5 not corrected by vitamin K with clinical hepatic encephalopathy (HE) or PT ≥ 20 s or INR ≥ 2.0 with or without clinical HE), biochemical evidence of acute liver injury, and no known evidence of chronic liver disease (1,2). As previously mentioned, at birth, NH-affected newborns will usually be born prematurely, in addition to being small for gestational age, oedematous, and usually hypoglycaemic. These neonates will have hypoalbuminaemia, marked coagulopathy, hypotransferrinaemia, AFP >100000 ng/mL, and ferritin >800 ng/mL, with jaundice and hyperbilirubinaemia developing several days after birth. Moreover, liver transaminases will be low or normal (3,4,7-9). To make a diagnosis of NH, extrahepatic siderosis must be proven; however, not all cases of GALD have evident extrahepatic siderosis (4,6-10).

As seen in figure 4, if the neonate's clinical and laboratory findings indicate liver failure and NH is suspected, then a lip biopsy, for evidence of extrahepatic siderosis in minor salivary glands, or a T2-weighted MRI, to look for extrahepatic siderosis in abdominal organs, must be performed for NH confirmation (4,10,12). If the lip biopsy and T2-weighted MRI are positive, then NH has been confirmed and appropriate treatment with exchange transfusion and IVIG should follow (4,12). However, if lip biopsy and MRI are negative, then a liver biopsy with C5b-9 immunohistochemical staining should be performed (4,12). If there

is positive staining for C5b-9, then GALD-NH can be confirmed and if staining is negative, then other aetiologies should be explored (4,12).

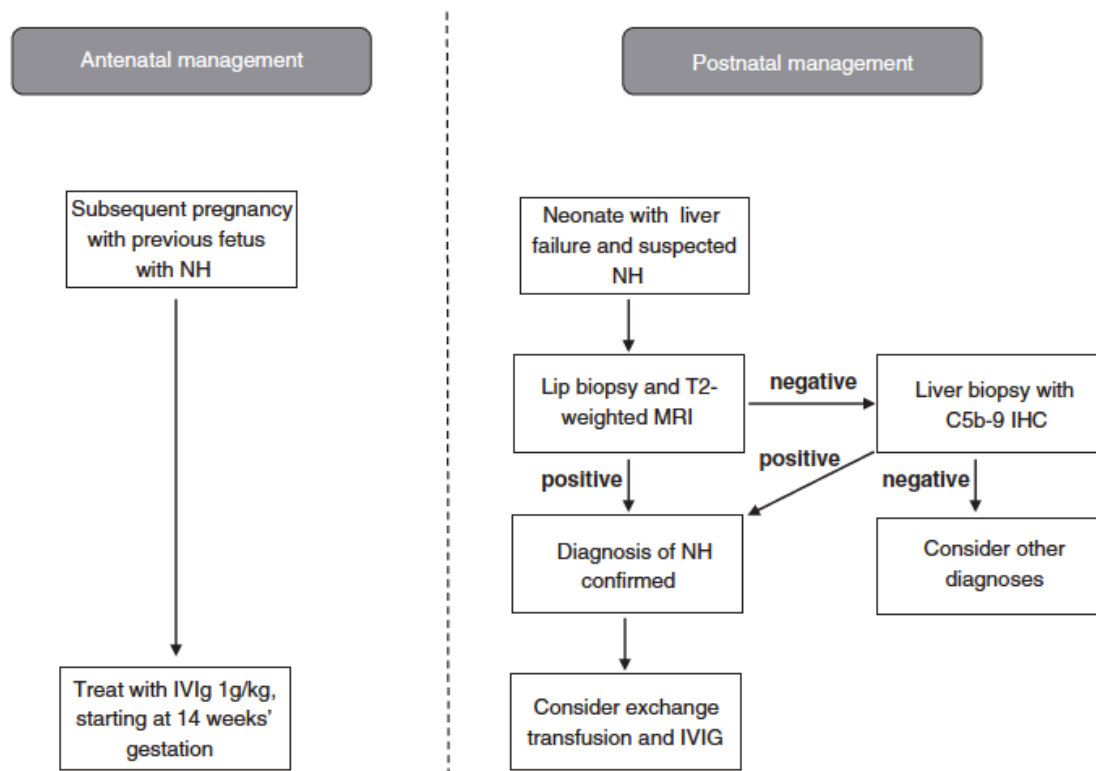


Figure 4. Schematic flow chart illustrating the antenatal and postnatal management options in a subsequent pregnancy with gestational alloimmune liver disease or in a newborn with suspected neonatal hemochromatosis (12).

The method of treatment and management of NH depends on the severity of the damage to the neonate's liver. Neonates with suspected NH were previously treated with anti-oxidants (e.g.: vitamin E, N-acetylcysteine) and chelation therapy (e.g.: deferoxime), as seen in patient J.K., in order to reduce injury caused by iron overload (1,3,4,7,9,12). However, this therapy has proven to not be very efficacious in the management of liver failure in NH patients – survival rates of NH affected neonates with anti-oxidant and chelation therapies range from as low as 10% up to only 20% (1,3,4,7,8,12). The most recent guidelines, for postnatal treatment of NH-affected first-borns or babies born to mothers undergoing prenatal preventative IVIG treatment, suggest exchange transfusion and IVIG as a better medical treatment than previously used anti-oxidants and chelation therapies (4,12). Exchange transfusion aims to remove maternal antibodies from the neonate's circulation, while IVIG (high doses of 1g/kg body weight) aims to impede antibody action in the neonate (4,12,15). Postnatal IVIG proved effective in the management of mild hepatic dysfunction in

patient J.K. Thus, these two therapies work symbiotically to block further maternal IgG damage in the NH-affected neonate (4,12,15). With this new treatment plan, Whittington reported cumulative survival rates of 79% in comparison with 10-20% as obtained with the previously used anti-oxidant and chelation therapies (4).

If medical management is unsuccessful, then liver transplant should be considered (4,8). Many authors state that the only definitive therapy for severe NH is orthotopic liver transplantation (1,3,4,14). In fact, NH is the most common reason for liver transplantation in the neonatal period and is one of the most common indications for liver transplant in the first three months of life (8,13). There has been some success with early liver transplant in NH-affected newborns, but typically there are difficulties in obtaining an appropriate liver to transplant, in addition to the generally poor condition of severely ill NH-affected neonates (3,4). With advances in the development of more efficacious postnatal medical treatment guidelines for NH-affected newborns, one must also look to make improvements in antenatal management, to prevent the reoccurrence of GALD.

Since Peter Whittington and his research group have further confirmed the alloimmune basis of more than 95% of NH cases, and since studies have shown that IVIG prevents and treats GALD, IVIG has become a staple in antenatal and postnatal management of GALD-NH (3,4,11,12,15,16). The effectiveness of IVIG in GALD prevention was first made known in a 2004 study, where all women (n=15) received high-dose IVIG from the second trimester (18th week of pregnancy) until birth (15). All babies born to mothers receiving IVIG were live-born and did not require liver transplantation (15). Further conducted studies produced the same or similar results and, currently, the success of antenatal preventative IVIG therapy reaches almost 100% (11,12). Current guidelines from 2013 recommend the use of 1g/kg IVIG at gestational weeks 14, 16, and 18, with the administration of 1g/kg IVIG weekly from the 18th week of gestation until the end of the pregnancy (12). This antenatal treatment plan was similar to the treatment plan that all mothers in the three patient families received. All three families, after IVIG antenatal treatment, had live-born babies; one baby had very easily treated mild hepatic dysfunction and the other two had little-to-no clinical illness. To this day, all three babies have no health problems or residual hepatic dysfunction. Thus, it is necessary to diagnose NH as quickly after birth as possible. With swift diagnosis, medical therapy with exchange transfusion and IVIG can increase survival outcomes to up to 79%, and even more importantly, GALD-NH can be prevented in subsequent pregnancies with antenatal IVIG resulting in an almost 100% success rate (4,11,12).

CONCLUSION

Neonatal hemochromatosis, the most common aetiology of neonatal liver failure, is overwhelmingly caused by gestational alloimmune liver disease. Due to a variety of presentations – late second and third trimester fetal loss, stillbirth, or a neonate born with little liver dysfunction ranging to fulminant liver failure – and no true pathognomonic laboratory findings, the diagnosis of NH is often overlooked or discovered late in the course of illness. With early diagnosis of live-born babies, medical management can be initiated early and produce a rather favourable outcome without the need for orthotopic liver transplantation. Furthermore, recognition of NH in previous pregnancies, whether they resulted in late second and third trimester fetal loss, stillbirth, or a live-born child, is imperative. With current antenatal management guidelines, high-dose IVIG therapy can prevent GALD in up to 100% of subsequent pregnancies.

ACKNOWLEDGMENTS

I would like to thank Professor Jurica Vuković, Department of Paediatrics, University Hospital Center Rebro, Zagreb, for his mentorship and guidance throughout this endeavour. Additionally, I would like to thank my family, friends, and älskling for all of their love and support throughout my medical studies and in the writing of this thesis.

REFERENCES

1. Shanmugam NP, Bansal S, Greenough A, Verma A, Dhawan A. Neonatal liver failure: aetiologies and management--state of the art. *Eur J Pediatr*. 2011 May;170(5):573–81.
2. Elzouki AY, Stapleton FB, Harfi HA, Oh W, Whitley RJ, Nazer H. *Textbook of Clinical Pediatrics*. Springer; 2011. 1 p. 2098–99
3. Whittington PF. Neonatal hemochromatosis: a congenital alloimmune hepatitis. *Semin Liver Dis*. 2007 Aug;27(3):243–50.
4. Whittington PF. Gestational alloimmune liver disease and neonatal hemochromatosis. *Semin Liver Dis*. 2012 Nov;32(4):325–32.
5. Simister N. Placental transport of immunoglobulin G. *Vaccine*. 2003 Jul 28;21(24):3365–9.
6. Whittington PF, Pan X, Kelly S, Melin-Aldana H, Malladi P. Gestational alloimmune liver disease in cases of fetal death. *The Journal of Pediatrics*. 2011 Oct;159(4):612–6.
7. Murray KF, Kowdley KV. Neonatal Hemachromatosis. *PEDIATRICS*. 2001 Oct;108(4): 960-3.
8. Grabhorn E, Richter A, Burdelski M, Rogiers X, Ganschow R. Neonatal hemochromatosis: long-term experience with favorable outcome. *PEDIATRICS*. 2006 Nov;118(5):2060–5.
9. Derusso PA. Hemochromatosis. In: Liacouras CA, Piccoli DA (eds.) *Pediatric Gastroenterology: Requisites*. 1st ed. USA: Mosby Elsevier; 2008. p261-5
10. Smith SR, Shneider BL, Magid M, Martin G, Rothschild M. Minor salivary gland biopsy in neonatal hemochromatosis. *Arch Otolaryngol Head Neck Surg*. 2004 Jun;130(6):760–3.
11. Whittington PF, Kelly S. Outcome of pregnancies at risk for neonatal hemochromatosis is improved by treatment with high-dose intravenous immunoglobulin. *PEDIATRICS*. 2008 Jun;121(6):e1615–21.
12. Lopriore E, Mearin ML, Oepkes D, Devlieger R, Whittington PF. Neonatal hemochromatosis: management, outcome, and prevention. *Prenat Diagn*. 2013 Dec;33(13):1221–5.
13. Sundaram SS, Alonso EM, Whittington PF. Liver transplantation in neonates. *Liver Transpl*. 2003 Aug;9(8):783–8.
14. Rodrigues F, Kallas M, Nash R, Cheeseman P, D'Antiga L, Rela M, et al. Neonatal hemochromatosis--medical treatment vs. transplantation: the king's experience. *Liver Transpl*. 2005 Nov;11(11):1417–24.
15. Rand EB, Karpen SJ, Kelly S, Mack CL, Malatack JJ, Sokol RJ, et al. Treatment of neonatal hemochromatosis with exchange transfusion and intravenous immunoglobulin. *The Journal of Pediatrics*. 2009 Oct;155(4):566–71.

16. Whittington PF, Hibbard JU. High-dose immunoglobulin during pregnancy for recurrent neonatal haemochromatosis. *Lancet*. 2004 Nov;364(9446):1690–8.

BIOGRAPHY

Ivana Marija Ćaćić was born and raised in Toronto, Canada, where she graduated from Cawthra Park Secondary School in 2006 with an honours Ontario Secondary School diploma and a Regional Arts Diploma in Dance. She then attended the University of Toronto, where she completed two years of an Honours Bachelor of Science degree in biology, physiology, and classics before transferring to the University of Zagreb School of Medicine in 2008. While at the University of Zagreb, Ivana received the Dean's Award for her academic achievements in her second year of studies. Moreover, Ivana has been a member of the Medical Studies in English's student council, eMed, since 2010, was a member of the European Medical Student's Association for the academic year of 2012/2013, and is currently a part of the executive council for StEPP, an organisation involved in the education and promotion of first aid and cardiopulmonary resuscitation. She plans to complete her specialty training in Europe and hopes to specialise in paediatrics (neonatology), radiology, or otorhinolaryngology.