

# Cryptorchidism

---

**Maixant, Anne-Lise Marie Julie**

**Master's thesis / Diplomski rad**

**2014**

*Degree Grantor / Ustanova koja je dodijelila akademski / stručni stupanj:* **University of Zagreb, School of Medicine / Sveučilište u Zagrebu, Medicinski fakultet**

*Permanent link / Trajna poveznica:* <https://um.nsk.hr/um:nbn:hr:105:000125>

*Rights / Prava:* [In copyright](#) / [Zaštićeno autorskim pravom.](#)

*Download date / Datum preuzimanja:* **2024-04-18**



*Repository / Repozitorij:*

[Dr Med - University of Zagreb School of Medicine  
Digital Repository](#)



**UNIVERSITY OF ZAGREB**

**SCHOOL OF MEDICINE**

**Anne-Lise Maixant**

# **Cryptorchidism**

**GRADUATE THESIS**



**Zagreb, 2014**

**UNIVERSITY OF ZAGREB**

**SCHOOL OF MEDICINE**

**Anne-Lise Maixant**

# **Cryptorchidism**

**GRADUATE THESIS**



**Zagreb, 2014**

This graduate thesis was made at the medical faculty of zagreb mentored by Prof. Davor Jezek, and was submitted for evaluation during the academic year 2013/2014.

# LIST OF FIGURES

**Figure 1:** Different gonadal position during the 2 stage descent of the testis.

**Figure 2:** Classification of undescended testis.

**Figure 3:** Prevalence of cryptorchidism in relation to age of the boys.

**Figure 4:** Physical examination.

**Figure 5:** Treatment.

# LIST OF ABBREVIATIONS

AIS :	androgen insensitivity syndrome
AR :	androgen receptor
AUA :	american urology association
CGRP :	calcitonin gene related peptide
DEC:	endocrine disrupting chemical
DES:	diethylstilbestrol
DIT :	Dihydrotestosterone
DSD :	disorder of sex development
ER :	estrogen receptor
FSH :	folliculating stimulating hormone
LHRH :	Luteinizing hormone releasing hormone
MIH :	Müllerian inhibiting substance
MRI :	magnetic resonance imaging
PBS :	Prune-Belly syndrome
SHBG:	sex hormone binding globulin
SNP :	single nucleotide polymorphism
UDT :	undescended testis

# TABLE OF CONTENTS

## 0.0 SUMMARY

### 1.0 INTRODUCTION.....p1

### 2.0 EMBRYOLOGY OF TESTICULAR DEVELOPMENT AND DESCENT.....p1

#### 2.1 The intra abdominal phase.....p1

#### 2.2 The inguinoscrotal phase.....p2

#### 2.3 Testis development.....p2

#### 2.4 Regulation of testicular descent.....p3

### 3.0 CLASSIFICATION OF UNDESCENDED TESTIS.....p5

#### 3.1 incidence and associated anomalies.....p6

#### 3.2 Effect of age on prevalence of cryptorchidism.....p7

### 4.0 PATHOPHYSIOLOGICAL HYPOTHESIS.....p8

#### 4.1 Genetic susceptibilities.....p8

#### 4.2 Other genetic anomalies.....p10

#### 4.3 Syndromic chryptorchidism.....p11

#### 4.4 Mini puberty and testicular descent.....p12

#### 4.5 Dysgenesis syndrome hypothesis.....p13

### 5.0 DIAGNOSIS .....p14

#### 5.1 Physical examination.....p14

#### 5.2 Palpable testis.....p15

#### 5.3 Non palpable testis.....p16

5.4 Radiological tests.....	p17
6.0 TREATMENT.....	p18
6.1 Hormonal therapy.....	p18
6.2 Studies on HCG and/or its analogue to induce testis descent.....	p19
6.3 Studies of LHRH and/or analogs to induce testis descent.....	p19
6.4 Use of hormones to improve fertility.....	p19
6.5 Surgical treatment.....	p20
6.5.1 Palpable UDT.....	p21
6.5.2 Non palpable UDT.....	p21
7.0 FERTILITY ASPECT.....	p22
8.0 LONG TERM OUTCOME, TESTICULAR CANCER.....	p25
9.0 CONCLUSION.....	p26
10.0 BIBLIOGRAPHY.....	p27
11.0 BIOGRAPHY.....	p35



## 0.0 SUMMARY

### **Title :** Cryptorchidism

Cryptorchidism is the most common congenital urogenital anomaly seen in male children. The incidence of cryptorchidism varies from 2-4 % in the male infant population and is more common in premature infants. Mechanisms involved in the etiology of this pathology require an understanding of the underlying embryology of testicular descent. The process of testicular descent has been clearly established to occur in two phases: the intra-abdominal phase and the inguino-scrotal phase. Both are regulated by complex hormonal and genetic factors, among which a balance between androgens and estrogens seems to play an important role.

Environmental factors like estrogen disrupters have been incriminated in etiology of cryptorchidism, but their precise role has not yet been clearly established.

Most cryptorchid testis diagnosed at birth will eventually achieve descent by the first three months after birth. Diagnosis of cryptorchidism relies on patient genital examination. A functional classification of palpable or impalpable testis provides the first step in the diagnostic and therapeutic algorithm. While radiological investigation such as ultrasound and computed tomography are of no use in the diagnosis of impalpable testis, laparoscopic exploration provides the most accurate diagnostic method in assessment and localization of impalpable testis.

Laparoscopy is ultimately also used in the treatment of cryptorchidism. The current standard therapeutic option relies on surgical repositioning of the gonad within the scrotum. Hormonal treatment is of little value but can be used as an adjuvant therapy to improve fertility rather than stimulating testicular descent. Orchidopexy should be performed by 18 months of age in order to preserve testicular function and decrease risk for malignancy.

**Key words :** undescended testis , gubernaculum , infertility , testicular cancer

## 1.0 INTRODUCTION

Cryptorchidism comes from the greek word cryptos which means hidden and orchis which means testis, and occurs when one or both testis fail to achieve complete descent into the scrotum. This developmental abnormality is the most common urogenital malformation seen in male children. The defect can occur as a single entity or can also be associated with multi systemic syndromes. Underlying mechanisms involved in the etiology of cryptorchidism intertwine hormonal, genetic and environmental factors. The ability of a clinician to detect the defect in early childhood provides the future male patient with a better long term reproductive outcome.

## 2.0 EMBRYOLOGY OF TESTICULAR DEVELOPMENT AND DESCENT

The development of the gonads and genital duct system begins approximately around the fifth week of gestation.(1) At this time, the human undifferentiated gonads develop adjacent to the ventro-medial side of the mesonephros. Below, we discuss the two major phases in which testicular descent is sequentially divided into.(2)

### 2.1 The intra abdominal phase

The intra-abdominal phase starts with inguinal canal development . This canal forms the pathway for the testis to descend through the abdominal wall into the scrotum. As the mesonephron degenerates, the gubernaculum descends on each side from the lower pole of the gonads and attaches to the future scrotum. (3)

Later on , by the 12 th week of gestation , the processus vaginalis (peritoneal sac) develops along the ventral side of the lower gubernaculum and herniates through the lower abdominal wall along the pouch form by the gubernaculum.

Each processus vaginalis carries extensions of layers of the abdominal wall before it and together they form the covering wall of the inguinal canal and future covering of the testis and spermatic cords.

## 2.2 The inguino-scrotal phase

Once the canal is created, the testis will start their migration through the inguinal canal, this occurs at around week 28, and the process then takes approximately two to three days. The testis moves beneath the peritoneum and behind the processus vaginalis.

The testes then reach the orifice of the inguinal canal around the sixth month of gestation, then cross the canal during the seventh month and finally reach their definitive intrascrotal position at the end of the eighth month of gestation.

## 2.3 Testis development

The human gonad cell formation within the testis relies on the expression of the SRY (sex determining region Y) and other genes like SOX9, expressed between days 41 and 44. Their expression trigger sertoli and testicular cord formation by the ninth week of gestation: (3)

Sertoli cells functions include:

- regulation of spermatogenesis through endocrine follicular stimulating hormone (FSH) and testosterone
- regulation of the intra-tubular and intercellular environment

- sequestration of meiotic and post-meiotic germ cells
- production of anti-mullerian hormone (AMH) causing regression of mullerian ducts between weeks 9 and 10.

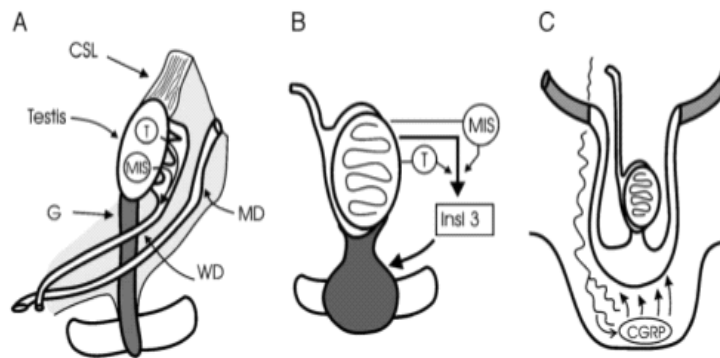
Leydig cell development is divided into three phases: a proliferation and differentiation phase between 7 and 14 weeks of gestation, a maturation phase until 18 week of gestation and finally an involution phase that continues until term. Leydig cells start secreting testosterone as early as 6 to 7 weeks but appear to be at first independent to gonadotrophin stimulation. Insulin-like 3 (INS-3) of leydig cells is measurable in human amniotic fluid by the 13 week. Evidence from animal models suggests that INS-3 and testosterone are keys hormones required for testicular descent.

#### 2.4 Regulation of testicular descent

Testicular descent is a complex embryological process. Many reviews of testicular descent by researchers emphasize the importance of both hormonal and genetic involvement in testicular decent.(5) For example, take INS-3, it is secreted by the leydig cells and causes the gubernaculum to swell. This swelling reaction does not only dilate the inguinal canal but also holds the testis near the groin as the fetal abdomen enlarges between 8 and 15 weeks of development.

Hormonal regulation of the second phase of descent is clearly dependent on androgenic influence but a precise mechanism remains controvertial.The second phase starts at 15 weeks of gestation. Many studies in mice and marsupials have shown a role for the genito-femoral nerve in guiding and/ or promoting passage of the gubernaculums(6). It releases the neuro-transmitter

calcitonin gene-related peptide (CGRP) which acts on the gubernaculum receptor which subsequently results in mitoses and suppression of apoptosis, thus guiding the elongation of the gubernaculum toward the scrotum by chemotaxis.(7) In summary, testicular descent is a complex mechanism involving enlargement of the gubernaculum and distal detachment and migration to the distal detachment and migration to initiate caudal migration of the testes.



**Fig. 1** Schema showing the different gonadal positions during the 2-stage descent of the testis. A, Initial gonadal position showing testis in urogenital ridge with wolffian ducts (WD), müllerian ducts (MD), and the supporting ligaments, CSL and genitoinguinal ligament or gubernaculum. Testosterone (T) and MIS are secreted down the WD. B, During the transabdominal phase, the testis is held by the gubernaculum near the inguinal region as the fetus enlarges. Insulin 3 stimulates gubernacular enlargement, augmented by MIS and T, which also causes regression of CSL. C, In the inguinoscrotal phase, the gubernaculum migrates and elongates toward the scrotum under androgenic action, which is indirect, via the GFN and release of CGRP.

### 3.0 CLASSIFICATION OF UNDESCENDED TESTIS

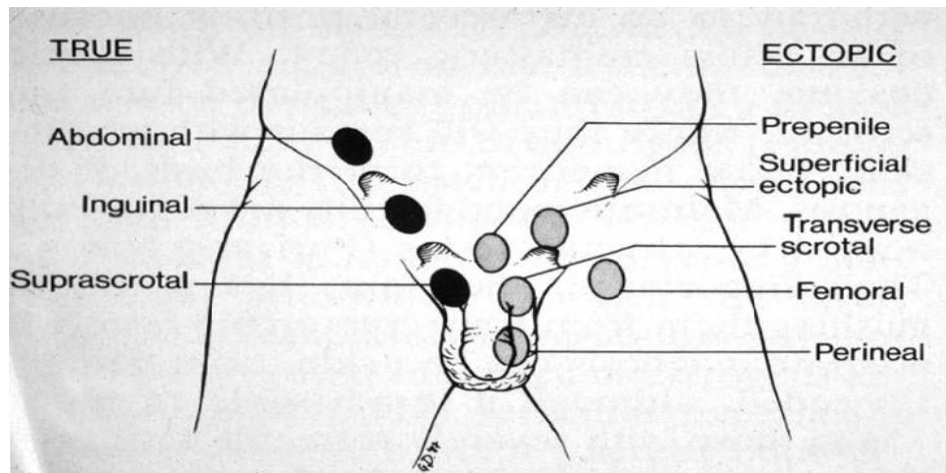
Undescended testes are defined as a disruption in migration of the testes along its normal pathway between the lumbar region and the scrotum. Normal scrotal position has been defined as the midpoint of the testis or below the mid-scrotum. Testis may be classified clinically as palpable or non palpable, in which non palpable testes can either be cryptorchid or absent.

Precise classification of undecended testes:

- Congenital cryptorchidism: testes that are extra-scrotal at birth
- Recurrent cryptorchidism: occurs when testes are initially present in the scrotum at birth and subsequently return to a non-scrotal position
- Secondary cryptorchidism: applies to testes which become supra-scrotally located after hernial repair or as a complication of orchidopexy.

It is important not to confuse undecended testes with ectopic testes. Ectopic testes descend normally though the external inguinal ring but are misdirected in the subsequent descent to an extra-scrotal position. The most common site of ectopic testes is the superficial inguinal pouch between the external oblique aponeurosis and the subcutaneous tissue. Perineal, prepenile, transverse scrotal, femoral and abdominal positions are other less common sites of ectopia. Retractable testes is defined as a possibly manipulated supra-scrotal testes that can be easily tract down into the scrotum.

Incomplete testicular descent can be described as unilateral or bilateral and the position of the testes may occupy an intra-abdominal, intracanalicular or supra-scrotal position.



### 3.1 Incidence and associated anomalies

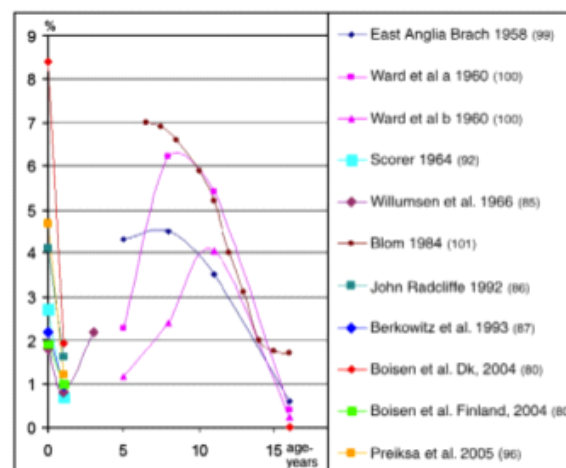
Generally, it is difficult to compare the frequency of cryptorchidism in different publications as the definition of cryptorchidism varies from one country to another.(8) However it is generally accepted that 2 to 3 % of full term and 17 to 30% of premature male neonates have one or more testis that have not completely descended to the scrotum. In 25 % of patients with cryptorchidism the condition is bilateral. The frequency of undescended testes in a population has been shown to be dependent on birth weight. Premature boys have a significantly increased risk of having the defect. Incidence of the undescended testes at birth for premature and/or low birth weight (< 2500 g) infants varies from 1,1 to 45 %. Low birth weight is a well known association with cryptorchidism and may be related to placental malformation. Other perinatal risk factors associated with cryptorchidism include breech presentation, maternal diabetes. In most affected infants the testes descend during the first three months after birth or by

the end of the first year of life. However, after one year of age the incidence of cryptorchidism remains between 0,7 % and 1 % suggesting that spontaneous descent is unusual after one year of age.

### 3.2 Effect of age on prevalence of cryptorchidism

The observation that testes, thought to be completely descended at birth, may re-ascend to a supra-scrotal position with time was noted by Villumsen and Zachau- Christiansen in 1966. In their investigations, 1,6 % of boys had unilateral or bilateral ascended testes which moved from a normal scrotal position at birth to a higher position by the age of 3. Other researchers have noted the same phenomenon and have provided case reports with well-documented data.

Later in childhood, the ascended testis can be extremely difficult to discriminate from a retractile testes, and in addition the previous scrotal position may be hard to verify.



**Fig. 1** Prevalence of cryptorchidism (in percent; y-axis) in relation to age of the boys (in years; x-axis). Modified after Thorup and Cortes [99].



## 4.0 PATHOPHYSIOLOGICAL HYPOTESIS

### 4.1 Genetic susceptibility

#### **Insulin like -3 (INL-3) and its receptor leucine-rich reoeat-contaning G protein-coupled receptor LGR-8**

Inl 3 is expressed in Leydig cells of the testis and theca cells of the ovary. This peptide affects testicular descent by acting on the gubernaculum via its specific receptor leucine-rich reoeat-contaning G protein-coupled receptor 8 ( LGT-8) , also known as G-protein-coupled receptor affecting testes descent (Great ). Therefore Insl-3 and its receptor were considered the most likely candidates for contributing to human non syndromic cryptorchidism, since their role in testicular descent has been clearly established.(11,12) However, case specific DNA coding variants of Insl 3 and its receptors found mutations in only 1,8 % of cryptorchid patients. On the other hand, it was demonstrated that estrogens and some endocrine disrupters like diethylstilbestrol (DES) are able to suppress transcription of Ins-3 gene of leydig cells.(14-15-16) In this way, maternal exposure of these type of molecules during the trans-abdominal phase prevents gubernaculum development and would potentially lead to cryptorchidism.

#### **Androgen receptor (AR)**

Two androgens, namely testosterone and dihydrotestosterone (DHT) are crucial for the development, function, and pathologic status of male testes and male internal and external genitalia.(17,) Partial androgen insensitivity syndrome (AIS) is almost nearly always associated with cryptorchidism. This syndrome is linked to a gene mutation in the androgen receptor which modifies the receptors affinity for testosterone and DHT(18). Knowledge of the role of androgens during the two phases of testicular migration would allow us to fully understand the

pathophysiology of cryptorchidism. Moreover, it was surmised that the greater the number of mutations involving androgen receptor function, the higher the testicle was located in the abdomen. Some studies have focused on a single polymorphism of the androgen receptor gene that may lead to cryptorchidism. The gene exhibits two polymorphic sites in exon 1, characterized by different numbers of CAG and GGN repeats. Recent reports have shown no association between triplets and overall risk of cryptorchidism. However, association of certain polymorphism of these two triplet repetitions would be involve in some bilateral cryptorchidism.

### **Estrogen receptor (ER)**

Estrogens are not classically known to have a direct role in testicular migration. Nevertheless, prenatal exposure to non steroidal synthetic estrogen diethylstilbestrol disturbs the endocrine balance and subsequently causes cryptorchidism.(19) This exposure down regulates Insl-3 expression in embryonic leydig cells. In humans, there are 2 genes, each coding for one type of estrogen receptor, either ESR1 (alpha receptor) and ESR-2 (beta receptor). Codemonth and al reported that ESR alpha was a major contributor to estrogen-mediated fetal testis dysgenesis and cryptorchidism in their E2 exposure study of E-alpha knockout mice. These animal studies imply that estrogens and ER may play a role in testicular descent. Several researchers have examined the association between the SNPs or specific estrogen receptor alpha (ESR1) haplotype and the risk of cryptorchidism in humans. The first results, showed that some polymorphisms of these genes (for exaple: AGATA in the 3' region of ESR1 gene) were associated with severity of cryptorchidism. (20)

### **Cytogenetics anomalies**

Prevalence of anomalies in germ cells in patients who have a history of cryptorchidism is about 3 to 4%. In these cases, bilateral forms are more frequent. The principal karyotypic

anomalies are: klinefelter syndrome (47 , XXY), Men 46 XX, inversion of chromosome Y (46 XY / 47 , XXY , 46 XX/46 XY etc). Other chromosomal anomalies often implying (but not exclusively) chromosome Y were supposed to be associated with an increase risk of cryptorchidism. Among them, klinefelter syndrome is the most common, with a prevalence of 2% in the general male population (21). Additionally, 27% of Klinefelter patients present with bilateral cryptorchidism. The underlying mechanism would imply a gonadic dysgenesis leading to leydig cell dysfunction associated with a major disturbance in sertoli cell function and a disruption of the meiotic process. Felix and al search for association between anomalies in testicular migration and micro-deletion of Y chromosome but early results show no pathophysiological link between these two events.(22)

#### 4.2 Other genetic anomalies

Anatomic studies of the genito-femoral nerve in neonate rodents identified the calcitonin gene related peptide (CGRP) . Specific binding sites for CGRP have been found on developing cremaster muscle fibers within the gubernaculum. CGRP may stimulate gubernaculum migration during testicular descent by release from the genito-femoral nerve. Mutation screening of the coding regions and intro-exon boundaries of CGRP revealed polymorphic variants but no pathogenic sequence changes in the 90 selected cases of idiopathic unilateral or bilateral cryptorchidism. Besides, the hypothesis that androgen/estrogen ratio may be more important than only one hormone per se in both sexes. This ratio is controlled by aromatase enzyme. Over expression or hyperactivity of aromatase could lead to relative hyperestrogenic and hypoandrogenic state that would disrupt testicular migration. This hypothesis was confirmed in an animal model. In humans, studies are in the process of demonstrating an association between

hyperactivity of aromatase and cryptorchidism. Paradoxically, some sporadic bilateral cryptorchid cases have been described with an associated aromatase deficiency. These observations support the idea that minimal estrogen secretion is necessary for the correct process of testicular migration.

HOX genes play a key role in the morphogenesis of the segmented structure along the primary body axis such as brachial arches, vertebrae, cranial nerves and ganglia. Satokata and al reported that HOX10 knockout mice showed intra-abdominal bilateral cryptorchidism.(23) The testes of HOX10 knockout mice showed incomplete descent into the scrotal sac, but the degree of mal-descent was variable. Although HOX10 knockout mice exhibit cryptorchidism, there is no evidence of a relationship between HOXA 10 variants and cryptorchidism in humans, since the polymorphism of HOXA10 exists either in control subject or in cryptorchid patient.(24)

#### 4.3 Syndromic chryptorchidism

Di-George syndrome (microdeletion 22p11.2), Wiedemann Beckwith, Cornelia de lange (gene mutation NIPB2), Prader Willy and Down Syndromes are the poly-malformative syndromes in which cryptorchidism may be one of the involved symptoms. Specific mechanisms and etiology of cryptorchidism in these different syndromes are not always understood. Bilateral, undescended testes can be found in Prune-Belly syndrome (PBS).(25) This syndrome consists of a constellation of three major findings which include the absence of abdominal musculature, undescended testes and abnormal urinary tract (characterised by a tortuous and dilated urethra and renal dysmorphism). In PBS, the undescended testicles are usually found at the level of iliac vessels in the peritoneum on a long mesorchium. Kaplan et al (1986) suggested a role for intra-abdominal pressure in the process of testicular descent additionally Hutson et al believed that

high intra-abdominal pressure and bladder distention block descent. The fact that the PBS patient can have normally descended testicles despite severe abdominal wall laxity sheds some doubts that simply mechanical forces are responsible for cryptorchidism. Moreover, most PBS patients are sporadic cases and there is no elucidated mechanism of genetic involvement in the development of PBS. Other abdominal wall defects have been associated with an increased risk of cryptorchidism. (26) These include omphalocele and gastroschisis (15 to 30 % of cases) and also suggest a syndromic etiology. Also, T10 to S5 spinal anomalies are also associated with an increased risk of cryptorchidism. For example, in spina bifida the incidence varies from 19 to 36 % depending at which level the cord is affected.

#### 4.4 Mini puberty and testicular descent

The process of spontaneous post-natal descent after congenital cryptorchidism in the first year of life may be due to post-natal increases in the levels of sex-hormone called, aptly named mini puberty. (27) This endocrine phenomenon corresponds to a gonadotrophin surge which leads to an elevated level of circulating testicular androgens and Insl-3. It would secondarily promote physiological testicular descent. This supports the hypothesis that anomalies occurring during the mini puberty period could be associated with some form of cryptorchidism. However results in mini pubertal hormone level in cryptorchidism have been contradictory. Some studies have suggested that luteinising hormone (LH) and testosterone levels are decreased in boys with cryptorchidism as compared to controls or to boys with spontaneous testicular descent while other studies have found no difference in hormonal level. (28) Furthermore, in some studies where special attention was paid to the time point of sampling, cryptorchidism was associated with increased mini-pubertal gonadotrophin levels and reduced inhibin B levels as compared to

controls (Suomi and al; 2006). However, many researchers argue that the correct run of this mini puberty influences fertility in patient with cryptorchidism.

#### 4.5 Dysgenesis syndrome hypothesis: Environmental exposure

Over few decades, it was observed that a constellation of reproductive abnormalities including testicular cancer, hypospadias and reduced sperm count are all part of a syndrome called testicular dysgenesis syndrome.(29) Different arguments made the hypothesis of a pathophysiological link between these anomalies: compared studies made in different European countries showed higher incidence of hypospadias, cryptorchidism, and testicular cancer compared to others. Cryptorchidism is a well-known risk factor for testicular cancer. Hypospadias and oligospermia are also risk factor for testicular cancer. Infertile males are at increased risk for developing testicular cancer

In 1993, Sharpe and Skakkeback suggested that this syndrome could be caused by some perturbation in the development and differentiation of the testicle during fetal life. The concern for a link between EDC and cryptorchidism arose due to a reported increased risk of cryptorchidism after maternal exposure to DES. In humans, there is data supporting a correlation between exposure to antiandrogenic and/or estrogenic EDC (such as pesticides, flame retardants, and phthalates) and the occurrence of cryptorchidism. However, these data are mostly indirect or suggestive. Three mechanisms have been describe to explain their deleterious actions on testicular functions: estrogenic activity and /or anti-androgenic modification of bio-dispondibility of estrogen / androgen by competitive action on sex hormone binding globulin ( SHBG) causing a rupture in physiological balance of steroid hormone in profit of estrogen. (30)

## 5.0 DIAGNOSIS

Before proceeding to the physical examination, the physician must take a general history, specifically inquiring about prematurity and birth weight. Clinicians should also ask about other potential risk factors for cryptorchidism, such as gestational diabetes of the mother and smoking during gestation.

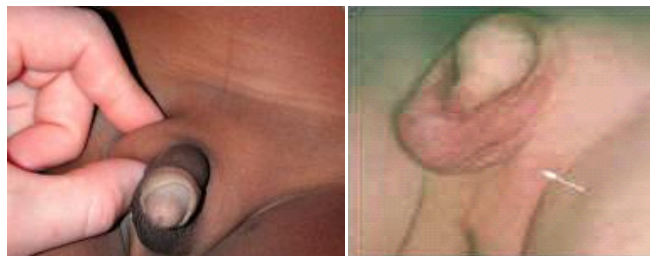
### 5.1 Physical examination

Examination should start with a careful examination of the boy, looking for general dysmorphic features which may point to any of the closely associated syndromes. A full urogenital examination should be performed, including documentation of testicular palpability, position, hydrocele, penile size, and urethral position. Undescended testes may be located along the line of normal descent between the abdomen and the scrotum or in an ectopic position that is commonly the superficial inguinal pouch (anterior to the rectus abdominis muscle) or more rarely, in the peritoneal, prepubic, femoral, peripenile perineal or contra-lateral scrotal position. Careful examination of these areas is needed to correctly classify a testis as palpable or non palpable and is a critical step that determinate further diagnosis investigation.

The method of testicular examination varies depending on age and developmental status of child. Infants should be examined in the supine position with legs gently frog-legged, or sitting on the lap of the parent. Gentle downward pressure along the inguinal canal from the anterior iliac spine to the scrotum and concomitant counter palpation with the opposite hand helps to identify the lowest position of a palpable testes. Older children may be examined in the up-right position cross-legged or in a supine position. Careful examination of the groin, femoral

region, perineum, contralateral hemiscrotum (to detect the rare case of transverse testicular ectopia) and pubic areas are needed in order to correctly classify a testis as palpable or non-palpable. The palpability of the undescended testis will determinate future surgical approach.

Once the testis is palpated, gently grasp it with the dominant hand and continue to sweep the testis toward the scrotum with the other hand. In palpable testes that can be manipulated into the scrotum, maintain the position for 30 seconds to a couple of minutes to fatigue the cremaster muscle. This will allow differentiation of retractile testes from undescended testes. Release the testes, and if it remains in place it is a retractile testes. If it immediately retracts to a prescrotal position, it is an undescended testes. Repeated examination, patient distraction techniques, a warm environment and use of lubricant on the examiners hands facilitate the physical examination. The size and location of the normally located contralateral gonad should also be noted as it may increase the ability to predict the status of the undescended testes. A hypoplastic hemiscrotum may imply that the testis is not present. The presence of compensatory hypertrophy (length greater than 2 cm in pre pubertal young boys) is highly associated with monorchia. However, hypertrophy of the contralateral testes, if present, is either perfectly sensitive or specific for the presence of vanishing testes. Therefore, because surgical exploration is indicated in all children with a history of nonpalpable testes, these children should be referred to a surgical specialist regardless of the size of the contralateral testes.



5.2 Palpable testis



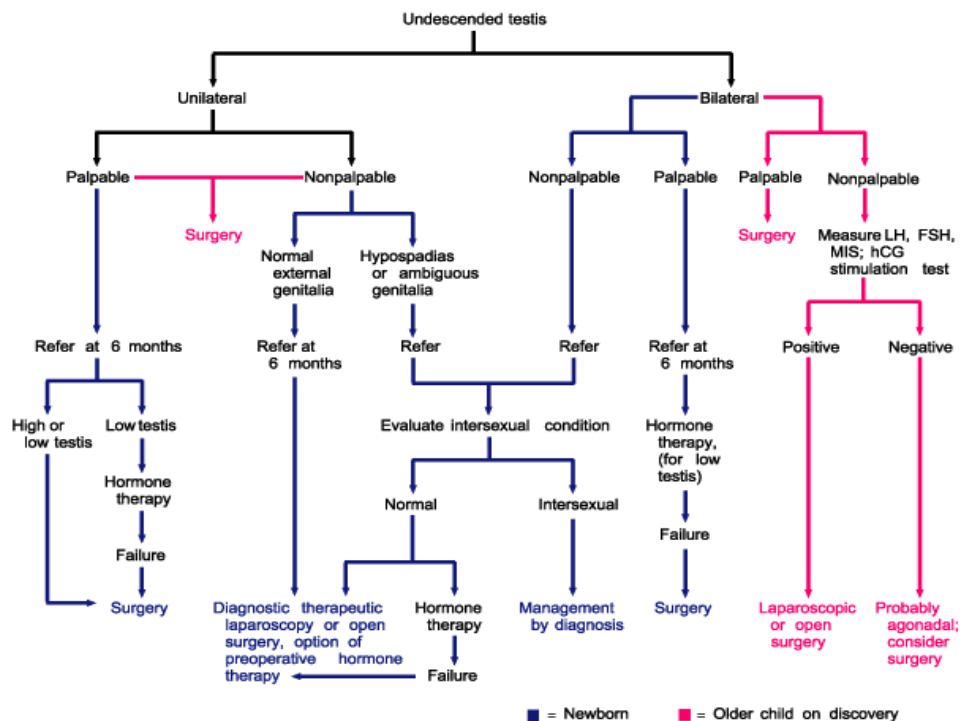
Infants who do not have spontaneous testicular descent by six months of corrected gestational age should be referred to a surgical specialist for a timeline evaluation. Testes that remain undescended by six months are unlikely to descend spontaneously and leave the child at a increased risk of infertility in adulthood. Acquired cryptorchidism is defined by a diagnosis after six months and must be referred for a surgical evaluation. Prevalence of acquired cryptorchidism is 1 to 7%, and the peak occurs around 8 years of age. Acquired cryptorchidism is more common in boys with a history of proximal hypospadias which suggests a common mechanism, such as aberrant androgen signaling. Although spontaneous descent of acquired cryptorchidism was reported, the same adverse histological changes are also found in primary undescended testis. Given the probability for post-natal descended testes to re-ascend, pediatricians should perform a scrotal examination at every check up.

### 5.3 Non palpable testis

All newborns with bilateral, non palpable testes must be evaluated for possible disorders of sex development (DSD). A newborn with a male phallus and bilateral non-palpable gonad is potentially a genetic female (46 XX) with congenital adrenal hyperplasia until proven otherwise. Thus, serum electrolytes, karyotype and hormonal levels of LH, FSH, testosterone and androstenedione must be obtained with simultaneous consultation with a pediatric endocrinologist. If the infant with bilateral non palpable testes has normal penile development or micropenis and a 46 YX karyotype an evaluation to distinguish between vanishing testes syndrome from bilateral abdominal testes should be done. To avoid surgical exploration of males with anorchia tests are used to assess the presence of any viable testicular tissue and include; MIS, inhibin B, FSH, LH and testosterone.

## 5.4 Radiological tests

Given the low cost and wide availability of ultrasound it has the potential to contribute to diagnosis through ease of routine use, however with a low sensitivity and specificity to localize non-palpable testis it is generally not considered reliable. MRI has been more widely used in the USA, but given that it is expensive and not always available, is not recommended in the diagnosis of cryptorchidism.(31) At this time, there are no radiological tests that could conclude with 100% reliability that a testis is absent. Therefore, surgical laparoscopy remains the gold standard diagnostic test for non palpable testis.



## 6.0 TREATMENT

Correction of cryptorchidism is indicated to optimize testicular function , potentially reduce or facilitate diagnosis of testicular malignancy , provide cosmetic benefits and prevents complications such as clinical hernia or torsion. Except in certain cases of associated complex medical illness or in the post-natal period , treatment should proceed after confirmation of diagnosis.

### 6.1 Hormonal therapy

Hormonal therapy has been used for many years for a variety of indications in patients with cryptorchidism, including differentiation of retractile testis from true undescended testis, stimulation of testicular descent or germ cell maturation and as an adjuvant to abdominal orchidopexy. The latest guideline from the American urology association states that hormonal therapy should not be used to induce testicular descent.

HCG or LHRH administration stimulates production of androgens by the Leydig cells. The exact mechanism of action of increased androgen in stimulating testicular descent is not known but may involve an effect on testicular cords or cremaster muscle. HCG is administered by intra-muscular injection (IM), while GnRH can be administered intra-nasally. Despite multiple studies being published in regards to hormonal therapy in cryptorchidism, there are too many differences in the including criteria (patient age, treatment time line, and follow up times). This means that these studies have failed to show uniform results, but tend to demonstrate a significant risk in recurrence. (32,33)

## 6.2 Studies on HCG and/or its analogue to induce testis descent

Few studies have examined the optimal dosing regimens of hormonal treatment to induce testicular descent.(35) Results show no difference in successful descent to the scrotum with different doses. Side effects of HCG treatment were seen in up to 75% of boys, including increase scrotal rugae, pigmentation, growth of pubic hair and penis, which may regress after treatment cessation. A total dose of more than 15000 IU of HCG must be avoided since it may induce epiphyseal plate fusion and retard future somatic growth. HCG has also been reported to cause a temporary increase in intra-testicular pressure and to render the testes hyperemic and enlarged.

## 6.3 Studies of LHRH and/or analogs to induce testis descent

Agonist analogs of LHRH, such as Nafarelin or Buserelin, stimulate the release of the pituitary gonadotrophins LH and FSH and subsequently result in a temporary increase of gonadal steroidogenesis. Trials comparing LHRH treatment to placebo showed that LHRH had a slightly higher rate of testicular descent compared to the placebo sample, but the statistical significance of these results was not proven (36). Once again care must be taken when using this hormonal therapy as the recognized side effects of GnRH include increase penile and testicular size, scrotal erythema or erection. However, side effects were less common than in the HCG trial.

## 6.4 Use of hormones to improve fertility ( rather than to induce testicular descent):

A patient born with undescended testis shows a decreased number of spermatogonia in their testes compared to normal boys. In some cases, histological biopsy after surgical treatment

does not show any germ cell presence. LHRH or HCG treatment prior to surgery was shown to improve fertility index in some trials, but could not be of any help in a patient lacking germ cells at time of biopsy.(37) In a separate prospective study, 42 boys with 63 undescended testis, were prospectively randomized to receive either orchidopexy alone (21patients) or with neo-adjuvant GnRH therapy. Result show that neo-adjuvant administration of GnRH improved the fertility index above 0,6 and subsequently improved future individual fertility potential. Recently, a prospective study followed boys who underwent orchidopexy and were subsequently treated with a six month course of agonist analogs of LHRH .This group was compared to a control group who included only boys treated by orchidopexy alone. Results focus on semen analysis (number of sperm per ejaculate), measured in early adulthood. Patients receiving both hormonal and orchidopexy had a significantly higher sperm count compared with boys treated with surgery alone. This first result could be of future interest to improve fertility potential in cryptorchid patients.

#### 6.5 Surgical treatment :

Surgical treatment of UDT should be performed after sixth months of age if the testes have not yet descended by that time. Inguinal or scrotal orchidopexy remains the goldstandard procedure to preserve both testicular function and future fertility in male patients. However the type of procedure will depend on the precise location of the testes and will differ if the testes are palpable or non-palpable.

##### 6.5.1Palpable UDT:

Standard inguinal and scrotal incisions are the well-known approach for treatment of palpable UDT.(38) Adequate spermatic length should be acquired in order to reposition it back into the scrotum. The testis and the cord are dissected up to the inguinal ring that is subsequently opened to give adequate exposure if more length is required. This dissection is essentially the mobilization of the spermatic vessel and the vas deferens out of the endo-abdominal fascia.

A pathway is made into the scrotum to ensure that there are no obstructive bands of tissue remaining. Scrotal fixation is done by a subcutaneous pouch method with fixation of the testis beneath the skin and above the dartos muscle.(39) A path is made between the skin and the dartos, the testis are positioned back in the pouch and sutured directly to the dartos muscle.

A recent series or a single incision approach orchidopexy for low lying UDT showed to be as effective as the two wide spread orchidopexy incisions. (40)It can safely be used to additionally repair hernias if adequate ligation cannot be achieved, it can be converted to the conventional inguinal and scrotal procedure. This new approach presents with enhanced time recovery and better cosmetic outcome.

#### 6.5.2 Non palpable UDT

In case of non-palpable testis, laparoscopic exploration of the peritoneum and abdominal cavity and subsequent repair should be performed. Laparoscopic techniques have become widely used among young surgeons and allow minimally invasive methods for orchidopexy.(41)

When direct visualization of intra-abdominal testis is encountered, careful attention should be paid to the anatomic vascular structures: spermatic vessels signals surgical end of exploration and determinates the next step of surgical repair. If the testicular vasculature is long

enough then a primary orchidopexy is performed. In cases where the vasculature is too short for adequate testicular mobilization, one-stage or two stage Fowler Stephen (FS) orchidopexy can be performed.(42) In one stage FS, direct ligation of the spermatic vessel and repositioning of the testis in the scrotum is made in a single fashion, whereas in the two-stage FS, a primary ligation is done to allow collateral circulation to develop and a second surgery will be performed sixth months later to position the testis in the scrotum.

The decision for proceeding with one or the other procedure mainly depends on testicular position, anatomical structures and the surgeon's technical skills.

In any case, testicular biopsy should be performed at the time of orchidopexy for later histopathological analysis. Biopsy analysis provides an important tool in assessing future male fertility potential and determines the additional benefit for additional hormonal treatment.

Moreover, in cases where dimorphic testis are found at the time of the orchidopexy, a biopsy will help determine the need for orchidectomy instead of orchidopexy, if the patient presents with a normal contra-lateral testis.

## 7.0 FERTILITY ASPECT

Men with a history of cryptorchidism have an increased risk of infertility. The risk is even higher when a patient presents with bilateral cryptorchidism. Outcomes related to infertility include paternity rates, semen analysis, serum LH levels, FSH and Inhibin B and testicular size. (43). Testicular size and sperm density are positively correlated to germ cell status in cryptorchid testis in children. At birth, cryptorchid patients harbour germ cells in the testis but in reduced

numbers compared to normal boys. Early surgical repair may preserve the neonatal gonocyte pool to increase future fertility.

The mean number of spermatogonia and gonocyte per tubule cross-section (mean S/T) correlates positively with sperm count in adulthood. If decreased S/T values are found after biopsy, the risk of infertility is high and correlates with the S/T value. In cases where no germ cells are found at biopsy, the risk of infertility increases from 78 to 100%.

Concerning the history of unilateral cryptorchidism, the contralateral testis that undergoes normal descent also presents with tissue injuries, and shows decreased numbers of gonocytes than in normal testis. (44) Underlying mechanisms leading to infertility in cryptorchid patients are multiple and are still not clear.

Gonadal hyperthermia is recognized as one of the first incriminating factors. To achieve their proper exocrine function, the testicles must be maintained at a temperature two degrees lower than the core body temperature (ideally between 33 and 35 °C). (45) Hyperthermia induced by prolonged abdominal location plays a part in spermatogenesis dysfunction. The hyperthermic state leads to a relative increase in the metabolic needs of the gonads that leads to testicular hypoxia. This hypoxic state increases production of oxidative molecules that cause irreversible damage to the testicular tissue. (46) Stigma of oxidative stress can also be found in the healthy testicle of the unilateral cryptorchid patient.

Thirty-six to 45% of the population with a history of cryptorchidism present with congenital anomalies of the seminal canal presenting as secondary atresia of the epididymis or testicular cords. (47) The exact mechanism of this phenomenon is still not fully understood and also partly gives rise to the fertility etiology in patients with cryptorchidism.



Iatrogenic lesions of the testicular and seminal ducts include dissections of testicular vessels during orchidopexy that can cause testicular ischemia. Incidence of this complication increases with a high testicular position and can range from 8 to 25%.

In men treated with unilateral orchidopexy a higher rate of testicular arterial anomalies are associated with the cryptorchid testis. Moreover, if surgery is performed too early in life, surgical orchidopexy can injure the seminal ducts since visualization is more difficult. (48)

The immunologic phenomenon is seen in 30 to 66% of patients with a history of cryptorchidism and has antibody anti-spermatozooids in seminal fluid. These antibodies come from spermatozoid exposure of the immune system following hemato-testicular barrier rupture during orchidopexy. (49)

Histological testicular lesions have been noticed in patients with orchidopexy, these lesions are characterized by; (50)

- diminution of germ cell count
- diminution of seminiferous tract diameter
- thickening of the peritubular sheath
- interstitial tissue fibrosis

All these findings combined contribute to the mechanism of infertility in males( 51)

## 8.0 LONG TERM OUTCOME, TESTICULAR CANCER

Patients presenting with a clinical history of UDT are at an increased risk for malignant transformation at an older age and long-term follow-up should be performed in those patient after puberty. Incidence of malignancy in cryptorchid patients varies from 0,05 to 1%. Self-examination and education of patients should be taught in order to detect early cancer symptoms and provide early management. Studies have shown that early age orchidopexy decreases the risk for malignant transformation.(52,53) Most testicular cancers comprise a diverse group of neoplasms among which germ cell tumor are most commonly found; seminomas is the most common type encountered with patients with cryptorchidism and account for 60% of germ cell tumors. Patients usually come to clinical attention because of a painless testicular mass or increased testicular volume and a decreased libido. Additional symptoms include asthenia, anorexia, and weight loss.

Testicular examination should be bilateral with comparative inspection for intra-testicular nodules, persistence of epididymo-testicular creases (Chevassus sign) as infiltration of the spermatic cord should be oriented toward a potential malignancy.

Diagnosis: an emergency inguinal orchidectomy must be performed to access positive diagnosis and therapeutic options.

Further investigation should be carried out to assess metastatic potential using MRI and TEP scan. Histologic markers include HCG, LDH, AFP and are of clinical significance for diagnosis, prognosis and follow up.

Testicular cancer usually presents with a good positive outcome with a total 5-year survival rate over 90% as GCT are responsive to both chemotherapy and radiotherapy. Treatment options mostly include surgical orchidectomy and adjuvant chemotherapy and radiotherapy treatment depending on TNM staging.

Life-long clinical follow up will be mandatory in order to detect early or late relapse.

## 9.0 CONCLUSION

Cryptorchidism is a common anomaly that presents as a challenge for the paediatric endocrinologist, paediatric urologist and the general pediatrician. Better training and education of general practitioners should benefit male patients in the early diagnosis and treatment.

The lack of understanding of the intrinsic mechanisms involved in the pathogenesis of this anomaly can be reviewed in the literature, which provides clear guidelines for diagnosis and management of cryptorchidism and provides male patients with a better fertility outcome. Despite improvement in functional outcome, cryptorchid patients are still at an increased risk for testicular cancer and should be kept under continuous surveillance of the disease.

## 10.0 BIBLIOGRAPHY

### Bibliography :

1. Hutson J. A biphasic model for the hormonal control of testicular descent. *Lancet* 1985;2:419-21.
2. Tuchmann-Duplessis H, Haegel P. 2 ed., *Embryologie*, vol. 2, 2 ed. Paris: Masson; 1979. p. 72–103.
3. Encha-Razavi F, Escudier E. In: *Embryologie humaine de la molécule à la clinique* 2 ed., Paris: Masson; 2001. p. 223–41.
4. Hutson JM, Beasley SW. The mechanisms of testicular descent. *Aust Paediatr J* 1987;23(4):215–6.
5. Hughes IA, Acerini CL. Factors controlling testis descent. *Eur J Endocrinol* 2008;159(Suppl. 1):S75–82.
6. Chan JJ, Farmer PJ, Southwell BR, et al. Calcitonin gene-related peptide is a survival factor, inhibiting apoptosis in neonatal rat gubernaculum in vitro. *J Pediatr Surg* 2009;44:1497-501.

7. Yong EX, Huynh J, Farmer P, et al. Calcitonin gene-related peptide stimulates mitosis in the tip of the rat gubernaculum in vitro and provides the chemotactic signals to control gubernacular migration during testicular descent. *J Pediatr Surg* 2008;43:1533-9.
8. Berkowitz GS, Lapinski RH, Dolgin SE, et al. Prevalence and natural history of cryptorchidism. *Pediatrics* 1993;92:44-9. cryptorchidism: a record linkage study. *Paediatr Perinat Epidemiol*
9. Foresta C, et al. Role of hormones genes and environment in human cryptorchidism. *Endocrinol Rev* 2008;29(5):560–80.
10. Ferlin A, et al. The INSL3-LGR8/GREAT ligand-receptor pair in human cryptorchidism. *J Clin Endocrinol Metab* 2003;88(9):4273–9.
11. Ivell R, Hartung S. The molecular basis of cryptorchidism. *Mol Hum Reprod* 2003;9(4):175–81.
12. Tomboc M, et al. Insulin-like 3/relaxin-like factor gene mutations are associated with cryptorchidism. *J Clin Endocrinol Metab* 2000;85(11):4013–8.
13. Emmen JM, et al. Involvement of insulin-like factor 3 (Insl3) in diethylstilbestrol-induced cryptorchidism. *Endocrinology* 2000;141(2):846–9.

14. Nef S, Parada LF. Cryptorchidism in mice mutant for *Insl3*. *Nat Genet*. 1999;22:295-299.
15. Zimmermann S, Steding G, Emmen JM, et al. Targeted disruption of the *Insl3* gene causes bilateral cryptorchidism. *Mol Endocrinol*. 1999;13:681-691.
16. Nguyen MT, Showalter PR, Timmons CF, et al. Effects of orchidopexy on congenitally cryptorchid insulin-3 knockout mice. *J Urol*. 2002;168:1779-1783.
17. Ferlin A, et al. Male infertility and androgen receptor gene mutations: clinical features and identification of seven novel mutations. *Clin Endocrinol (Oxf)* 2006;65(5):606–10.
18. Ferlin A, et al. Androgen receptor gene CAG and GGC repeat lengths in cryptorchidism. *Eur J Endocrinol* 2005;152(3):419–25.
19. Yoshida R, et al. Association of cryptorchidism with a specific haplotype of the estrogen receptor alpha gene: implication for the susceptibility to estrogenic environmental endocrine disruptors. *J Clin Endocrinol Metab* 2005;90(8): 4716–21.
20. Galan JJ, et al. Molecular analysis of estrogen receptor alpha gene AGATA haplotype and SNP12 in European populations: potential protective effect for cryptorchidism and lack of association with male infertility. *Hum Reprod* 2007;22(2):444–9.

21. Bergere M, et al. Prise en charge actuelle du syndrome de Klinefelter en assistance medicale a la procreation. *Mt Med Reprod* 2006;8(3):218–24.
22. Ferlin A, et al. Molecular and clinical characterization of Y chromosome microdeletions in infertile men: a 10-year experience in Italy. *J Clin Endocrinol Metab* 2007;92(3):762–70.
- insights and potential new downstream effects. *Fertil Steril* 2008;89(2 Suppl.):e33–8.
23. Lewis AG, Pecha BR, Smith EP, et al. Early orchiopexy restores fertility in the Hoxa 11 gene knockout mouse. *J Urol.* 2003;170: 302-305.
24. Kolon TF, Wiener JS, Lewitton M, et al. Analysis of homeobox gene HOXA10 mutations in cryptorchidism. *J Urol.* 1999;161:275- 280.
25. Duckett JW. The prune-belly syndrome. In : Welch KJ , Randolph JG , Ravitch MM, et al, eds. *Clinical pediatric urology.*
26. Attah AA, Hutson JM. The role of intra-abdominal pressure in cryptorchidism. *J Urol* 1993;150(3):994–6.
27. Hadziselimovic F, et al. The importance of mini-puberty for fertility in cryptorchidism. *J Urol* 2005;174(4 Pt 2):1536–9 [discussion 1538–9].

28.Suomi AM, et al. Hormonal changes in 3-month-old cryptorchid boys. J Clin Endocrinol Metab 2006;91(3):953–8.

29.Skakkebaek NE, Rajpert-De Meyts E, Main KM. Testicular dysgenesis syndrome: an increasingly common developmental disorder with environmental aspects. Hum Reprod 2001;16(5):972–8. 2004;127(3):305–15.

30.Sharpe RM, Skakkebaek NE. Are oestrogens involved in falling sperm counts and disorders of the male reproductive tract. Lancet 1993;341(8857):1392–5.

31.Tasian GE, Yiee JH and Copp HL: Imaging use and cryptorchidism:determinants of practice patterns. J Urol 2011; 185: 1882.

32.Bartone FF, Huseman CA, Maizels M et al: Pitfalls in using human chorionic gonadotropin stimulation

33.Saggese G, Ghirri P, Gabrielli S et al: Hormonal therapy for cryptorchidism with a combination of human chorionic gonadotropin and follicle-stimulating hormone. Success and relapse rate.  
Am J Dis Child 1989; 143: 980.



34. Therapeutic results in cryptorchidism after combination therapy with LH-RH nasal spray and hCG. Eur J Pediatr 1987; 146; S31.
35. Evaluation of low-dose hCG treatment for cryptorchidism. Turk J Pediatr 2006; 48: 228.
36. De Muinck Keizer-Schrama SM, Hazebroek FW, Matroos AW et al: Double-blind, placebo-controlled study of luteinising-hormone-releasing-hormone nasal spray in treatment of undescended testes. Lancet 1986; 1: 876.
37. Neoadjuvant gonadotropin-releasing hormone therapy before surgery may improve the fertility index in undescended testes: A prospective randomized trial. J Urol 2005; 173: 974.
38. Kollin C, Karpe B, Hesser U et al: Surgical treatment of unilaterally undescended testes:
39. Bianchi A and Squire BR: Trans-scrotal orchidopexy: orchidopexy revised. Pediatr Surg Int 1989; 4: 189.
40. Na SW, Kim SO, Hwang EC et al: Single Scrotal Incision Orchiopexy for children with palpable low-lying undescended testis: Early outcome of a prospective randomized controlled study. Korean J Urol 2011; 52: 637.

41.Chandrasekharam VV: Laparoscopy vs inguinal exploration for nonpalpable undescended testis. Indian J Pediatr 2005; 72: 1021.

42.Dhanani NN, Cornelius D, Gunes A e al: Successful outpatient management of the nonpalpable intra- abdominal testis with staged Fowler-Stephens orchiopexy. J Urol 2004; 172: 2399.

43..Hadziselimovic F , Hoecht B. Testicular histology related to fertility outcome and postpubertal hormone status in cryptorchidism. Klin Pädiat 2008;220;302-7

44.Thorup J, Cortes D , Peterson BL . Histopathogy of the intra-abdominal testis. J Ped Uro 2007;3 ( Suppl 1) : 39-40

45.Thonneau P, et al. Occupational heat exposure and male fertility: a review. Hum Reprod 1998;13(8):2122–5.

46.Peltola V, Huhtaniemi I, Ahotupa M. Abdominal position of the rat testis is associated with high level of lipid peroxidation. Biol Reprod 1995;53(5): 1146–50.

47. De Miguel MP, et al. Epididymal growth and differentiation are altered in human cryptorchidism. *J Androl* 2001;22(2):212–25.
48. Taskinen S, et al. Ultrasonography and colour Doppler flow in the testes of adult patients after treatment of cryptorchidism. *Br J Urol* 1996;78(2):248–51.
49. Urry RL, et al. The incidence of antisperm antibodies in infertility patients with a history of cryptorchidism. *J Urol* 1994;151(2):381–3.
50. Gaudio E, Paggiarino D, Carpio F. Structural and ultrastructural modifications of cryptorchid human testes. *J Urol* 1984;131(2):292–6.
51. Moretti E, et al. Cryptorchidism and semen quality: a TEM and molecular study. *J Androl* 2007;28(1):194–9.
52. Cromie WJ: Cryptorchidism and malignant testicular disease, in Hadziselimovic F (ed): *Cryptorchidism: Management and Implications*. New York, Springer-Verlag, 1983; 83.
53. Walsh TJ, Dall'Era MA, Croughan MS et al: Prepubertal orchiopexy for cryptorchidism may be associated with lower risk of testicular cancer. *J Urol* 2007; 178: 1440.

## 11.Biography:

### Education:

- medical faculty of Zagreb : medical studies in English Zagreb , Croatia 2007-2014
- University : Bordeaux Victor Segalen: 2005-2007

### French clinical experience:

- Clinical rotation at University of Bordeaux : 2 semesters with Erasmus program 2012-2013
- Clinical rotation at Hospital Robert Debre : pediatric department : 2011
- Clinical rotation at Clichy Hospital , ENT department : 2011