

Clinical characteristics and treatment outcome of patients with adrenocortical carcinoma

Mugisha, Aude

Master's thesis / Diplomski rad

2014

Degree Grantor / Ustanova koja je dodijelila akademski / stručni stupanj: **University of Zagreb, School of Medicine / Sveučilište u Zagrebu, Medicinski fakultet**

Permanent link / Trajna poveznica: <https://um.nsk.hr/um:nbn:hr:105:669084>

Rights / Prava: [In copyright](#)/[Zaštićeno autorskim pravom.](#)

Download date / Datum preuzimanja: **2024-03-03**



Repository / Repozitorij:

[Dr Med - University of Zagreb School of Medicine Digital Repository](#)



**UNIVERSITY OF ZAGREB
SCHOOL OF MEDICINE**

Aude Mugisha

**Clinical Characteristics and Treatment
Outcome of Patients with Adrenocortical
Carcinoma**

GRADUATE THESIS



Zagreb, 2014

University of Zagreb

This graduation thesis was made at the Department of Internal Medicine KBC Zagreb – Rebro, under the guidance of prof. dr. sc. Darko Kaštelan dr. med. and was submitted for evaluation in the academic year of 2013/2014.

Division of Endocrinology, Department of Internal Medicine KBC Zagreb – Rebro

Mentor: prof. dr. sc. Darko Kaštelan, dr. med

ABBREVIATIONS

ACC	Adrenocortical Carcinoma
ACTH	Adrenocorticotrophic Hormone
CBG	Cortisol- Binding Globulin
DDT	Dichlorodiphenyltrichloroethane
DHEAS	Dehydroepiandrosterone Sulphate
EPD/ M	Etoposide, Doxorubicin, Cisplatin plus Mitotane
FDG-PET- ¹⁸ F	Fluorodeoxyglucose – Positron Emission Tomography
GGT	Gamma-glutamyl transpeptidase
HU	Hounsfield Unit
IGF- RI	Insulin Growth Factor I- Receptor
IGF-II	Insulin Growth Factor II
IVC	Inferior Vena Cava
LA	Laparoscopic Adrenalectomy
LOH	Loss of Heterozygosity
MEN I	Multiple Endocrine Neoplasia I syndrome
OA	Open Adrenalectomy
o, p' -DDD	1,1-dichloro-2- (<i>o</i> -chlorophenyl)-2-(<i>p</i> -cholophenyl)-ethane
NP59	¹³¹ I-6β-iodomethyl-norcholesterol
RT	Radiotherapy
SF-1	Steroidogenic factor 1
SPECT	Single Photon Emission Computed Tomography
Sz/ M	Streptozotocin plus Mitotane
TSH	Thyroid –Stimulating Hormone

Table of contents

Acknowledgements	1
Abstract	2
1. Introduction	3
1.1. Epidemiology.....	3
1.2. Pathogenesis.....	3
1.3. Clinical presentation.....	4
1.4. Diagnosis.....	5
1.5. Staging.....	8
1.6. Treatment.....	9
1.7. Prognosis.....	14
2. Aim of study	15
3. Methods	15
4. Results	16
4.1. Clinical characteristics of patients with ACC.....	16
4.2. Surgical treatment.....	17
4.3. Pathohistological findings.....	17
4.4. Medical treatment of patients with ACC.....	18
4.5. Treatment outcome of patients with ACC.....	18
5. Discussion	18
6. Conclusions	20
7. References	21
8. Curriculum Vitae	22

Acknowledgements

I would like to give my deepest gratitude and thanks to my mentor and teacher prof. dr. sc. Darko Kaštelan, dr. med. for his advice, patience and guidance during the making of this thesis.

Additionally, I would like to express my heart- felt gratitude to my family. None of this would have been possible without their love, patience, emotional and financial support during my six years of medical studies in Zagreb. I would like to also acknowledge my father who always believed in me.

Abstract

Adrenocortical carcinoma is a very rare and aggressive endocrine tumor, which generally conveys poor overall 5-year survival. Worldwide incidence is estimated at 1-2 million /year. Patients who suffer from ACC can present with symptoms of hormone excess, including Cushing's syndrome, virilization, feminization and less frequently hypertension associated with hypokalemia.

In almost all cases, histopathological research can distinguish between adrenocortical adenoma and carcinoma, using one of the international classification methods. Other diagnostic techniques include hormone work up and imaging methods. Radical surgery is considered the therapy of choice in the first stages of ACC, and when surgery is not feasible, after incomplete resection or for metastatic disease, adjuvant mitotane is added. Control of excessive hormone production is a vital part of management in all patients.

Nevertheless, despite complete resection, there are high recurrence rates. Management of recurrent ACC should take place in a specialist center and the individual biology of each case of recurrence must be considered when making treatment decisions. Early detection of recurrent disease is important as well as close follow up with clinical examination and imaging. Liver, pulmonary and bone metastasis are most often involved in systemic recurrence and management usually consists of mitotane, with or without combination chemotherapy. Surgical resection only plays a limited role in systemic recurrence, and only in selected patients. Unfortunately, treatment for this aggressive tumor is still ineffective.

1. Introduction

1.1. Epidemiology

Adrenocortical carcinoma (ACC) is a rare disease, in contrast to the prevalence of adrenal incidentalomas, which occurs in at least 3 % of the population over the age of 50 years. The precise incidence of ACC is a challenge itself because of its infrequent occurrence. However, according to Fassnacht et al., most authors estimate ACC to have an incidence of 1-2 per million population (1). Although, ACC is responsible for only approximately 0.2% of all cancer deaths in the United States annually, it is the second most aggressive endocrine malignancy behind anaplastic thyroid cancer. In addition, women seem to be more affected than men with a ratio about 1.5:1(2).

ACC has been observed to have a bimodal distribution, with the first peak occurring in children younger than 5 years and the second and higher peak appearing in the fourth and fifth decades of life (3). In a study by Maluf et al., it was noticed that there is a significant incidence in Southern Brazil with 3.4 – 4.2 cases per million children under the age of 15 years, even though adrenocortical tumors are rare in childhood (4).

1.2. Pathogenesis

The etiology of most cases of ACC is unknown, though it is understood that genetic factors and heredity play an important role in the occurrence of the tumor in some patients (3). Inherited risk factors for ACC include Beckwith-Wiedemann syndrome, Li-Fraumeni syndrome, McCune-Albright syndrome, MEN- syndrome and familial adenomatous polyposis coli (Gardner syndrome). However, sporadic cases are more frequent (3,5). Molecular changes lead to the inactivation of the tumor suppressor genes as well as the activation of oncogenes. The insulin growth factor II (IGF-II) system, located at 11p15 is highly associated with the pathogenesis of ACC (6). In addition, IGF-II has been found to be overexpressed in 90 % of patients with sporadic ACC compared to adrenal cortical adenomas (7). Moreover, the loss of heterozygosity (LOH) at chromosome region 11p15, which is related with higher risk of tumor recurrence, is more common in ACC than in adrenal adenomas (6).

1.3. Clinical presentation

The majority of patients with ACC (60%) presents with signs and symptoms of adrenal steroid excess. Rapidly progressing Cushing's syndrome with or without virilization is the most frequent presentation (1). This can be a sudden developing disease with skin atrophy, hyperglycemia, muscle weakness, hypertension and psychiatric disorders (5). The evolution is rapid, generally with less than one year lapsing from the first clinical changes to advanced Cushing's syndrome (8).

In addition, androgen-secreting ACCs in women present with hirsutism, male-pattern baldness, low voice and oligomenorrhea of recent onset. Estrogen-secreting tumors are less frequent (5 -10 % of male patients), but when present are almost pathognomonic for ACC. They produce gynecomastia and testicular atrophy in males. Rare aldosterone –producing adrenocortical carcinomas present with severe hypertension and profound hypokalemia (1,5).

Moreover, patients with a non-functioning ACC usually have symptoms of abdominal discomfort, abdominal fullness, back pain and gastrointestinal complaints such as nausea and vomiting. In those cases without clinical hormone excess, the most common presentation is related to tumor growth and intrusion on the surrounding structures. A small number of patients present with fever, weight loss and loss of appetite and in a few cases, a palpable mass can be felt on physical examination. In fact, it is possible for patients to have a large tumor without much evidence of systemic disease besides signs and symptoms of hormone excess (1,5, 8). In addition, Symeonidis et al. state in a case report that the clinical picture of an acute abdomen is an extremely rare presentation of adrenocortical carcinoma, which requires the spontaneous rupture or infarction of a large adrenal mass (9). Furthermore, adrenocortical carcinoma tends to spread by both hematogenous (most frequently the lungs, followed by the liver and bone in some cases) and lymphatic route (to regional and paraaortic lymph nodes). Metastases to the other adrenal gland, or the occurrence of bilateral adrenocortical carcinoma may develop in around 4 % of cases (5).

1.4. Diagnosis

The variable clinical manifestations of adrenal carcinomas make the correct diagnosis a challenging procedure. The various diagnostic tests include hormonal workup, imaging modalities and histopathology.

Hormonal work-up

With patients presenting with adrenal lesions, endocrine assessment is of the utmost importance in the initial elective workup. The diagnostic evaluation of ACC depends upon the clinical appearance. Cushing's syndrome at time of presentation necessitates the measurement of urinary cortisol excretion for 24 hours, early morning cortisol after 1mg dexamethasone at 23:00 hours the night before (known as the 1mg overnight suppression test), or the late night (salivary) cortisol level. A positive (elevated) result of one of these tests confirms Cushing's syndrome (5, 9).

Abnormal steroidogenesis (depicted by elevated levels of cortisol precursors such as 17-OH- progesterone and 17-OH-pregnenolone) with gas chromatography separation of 17-ketosteroids establishes the clinical diagnosis of adrenocortical carcinoma. In addition, elevated plasma levels of DHEAS (dehydroepiandrosterone sulphate) and testosterone in women and 17- β -estradiol in men are markers for ACC, however, their specificity is unknown (5).

Imaging

Proper imaging of the tumor and possible metastases is required for best patient care. For differential diagnosis of an adrenal mass, computerized tomography (CT) and magnetic resonance imaging (MRI) are currently equally reliable. Although these techniques cannot determine the precise identity of the mass, both are able to show clear evidence of a benign tumor in most cases when performed appropriately. Most ACCs usually have higher density (i.e. lower lipid content) and are inhomogeneous, with irregular margins and irregular enhancement of solid components after intravenous

contrast media. In addition, calcifications can often be seen. Local invasion or tumor extension into the inferior vena cava (IVC), as well as lymph node or other metastases (lung and liver) are frequently found in advanced ACC. Measurements of Hounsfield Units (HU) in unenhanced CT is of great value in differentiating malignant from benign adrenal lesions (1, 3). ACCs display a considerably higher density on non-contrast CT than adenomas, with specificity for discerning adenoma from carcinoma of 100 % and 96.9%, using 10 and 20 HU cutoffs, respectively (8). However, lipid-poor benign adenomas show frequently unenhanced HU values more than 10 HU. To improve the differentiation of these lipid-poor adenomas from ACC, delayed contrast-enhanced CT is used, analyzing washout of contrast medium. Fassnacht et al. report that “adrenal lesions with an attenuation value of >10 HU in unenhanced CT or on enhancement washout of < 50 % and a delayed attenuation of >35 HU (on 10- 15 minute delayed enhanced CT) are suspicious for malignancy” (1).

Another reliable method for demonstrating adrenal lesions is MRI with gadolinium and chemical shift technique. Once more, the fat content provides an indication as to whether the tumor is benign or malignant. ACCs are usually isointense with liver on T1-weighted image, with intermediate to increased intensity on T2-weighted sequences (1, 3). Enhancement with after gadolinium is characteristic and washout is typically slow. Based on these qualities, the sensitivity of MRI to distinguish between benign and malignant adrenal masses is 81-89% with a specificity of 92-99% (1). If there is a suspicion of vascular involvement, MRI should be conducted before surgical resection as it better in evaluating the extent of vascular invasion, especially into the IVC with right adrenal tumors (3).

Moreover, the use of [18F] fluorodeoxyglucose (FDG) – positron emission tomography (PET) is not suggested in baseline routine evaluation. High uptake of 18 F-FDG demonstrates increased glucose metabolism and indicates malignancy, however, it does not distinguish between ACC and other tumors with high metabolic activities. In addition, although adrenal scintigraphy with ¹³¹I-6β-iodomethyl-norcholesterol (NP59) was used in the past to visualize adrenal tumors, it is a time-consuming technique and associated with a high radiation dose. A new method for adrenal imaging employing metomidate as radiotracer is promising as it specifically binds to adrenal 11β -

hydroxylase and aldosterone synthase and, therefore, uptake indicates the adrenocortical origin of a lesion (1, 5).

Imaging is important not only for characterizing adrenal lesions but also for staging. Approximately one third of patients present initially with metastases of which lung and liver are the most frequent sites. Therefore, high-resolution CT of chest and abdomen (alternatively MRI) is mandatory. CT is better in detecting lung lesions, while MRI is more sensitive for liver lesions. In cases of uncertainty, FDG-PET can be of great help. With the presentation of bone pain or suspected brain metastases, a bone scintigraphy followed by conventional x-ray studies in regions with high uptake and a cerebral CT/MRI should be performed (1).

Furthermore, fine-needle biopsy should only be performed if the tumor cannot be surgically resected and medical therapy requires pathological evaluation of the tumor. Biopsy for ACC is almost never warranted, as it is associated with risk of needle-track metastasis (1).

Histopathology

The pathological diagnosis of ACC may be problematic to determine due to the lack of clear-cut morphological criteria as well as the difficulty in distinguishing small ACCs without local spread or distant metastases from a benign adenoma. Therefore, several multiple parameters have been proposed for establishing malignancy. Among these, the Weiss criteria, first proposed in 1984, is most commonly used (3). It combines nine morphological parameters: three parameters related to tumor structure (description of cytoplasm, diffuse architecture, necrosis), three related to cytology (atypia, atypical mitotic figures, mitotic count), and three related to invasion (veins, sinusoids, tumor capsule) (1). It is uncertain whether the presence of a greater number of criteria is associated with a worse prognosis but tumors with higher Weiss scores clinically often behave more aggressively (3).

Immunohistochemistry also offers valuable information. Ki-67 expression can be used both for differentiating benign from malignant tumors and for prognosis in ACC. A cut off value between adenomas and ACCs ranging from 1.5% to 4% has been reported.

A high Ki-67 index (> 10%) is strongly associated with a poor clinical outcome, a shortened disease-free status and a decreased overall survival (1,7).

In addition, other markers such as Melan A, D11, inhibin α , and SF-1 are useful in determining the adrenocortical origin of the tumor, whereas ACCs are typically negative for chromogranin A, cytokeratins and S100. A number of new markers – loss of heterozygosity (LOH) at 17p13, IGF-2 overexpression, cyclin E, matrix metalloproteinase-2 (MMP-2), telomerase activity, topoisomerase II α , and N-cadherin- have been used to differentiate between benign and malignant adrenal lesions. However, none of these markers have been recognized to be reliable (1).

1.5. Staging

Various staging systems have been introduced for classification of ACC to evaluate the prognosis and to select treatment strategies.

TABLE 1: Staging systems of ACC according to the criteria UICC (Union Internationale Contre Cancer) and the ENSAT (European Network for the Study of Adrenal Tumors).

Stage	UICC/WHO 2004	ENSAT 2008
I	T1, N0, M0	T1, N0, M0
II	T2, N0, M0	T2, N0, M0
III	T1-2, N1, M0 T3, N0, M0	T1-2, N1, M0 T3-4, N0-1, M0
IV	T1-4, N0-1, M1 T3, N1, M0 T4, N0-1, M0	T1-4, N0-1, M1

T1: tumor \leq 5 cm; T2: tumor > 5cm; T3: tumor infiltration in surrounding tissue; T4: tumor invasion into adjacent organs or venous tumor thrombosis; N0: no positive lymph nodes; N1: positive lymph node(s); M0: no distant metastasis; M1: distant metastasis.

1.6. Treatment

A multidisciplinary approach is required for the management and treatment of patients with ACC, both at initial presentation and at disease recurrence.

Surgery

Surgery and adjuvant therapy are two important and critical issues to consider when dealing with patients with localized ACC. In all patients with stage I-II and most patient with stage III, complete resection is possible. However, surgical resection of ACC is challenging, and requires surgeons to be skillful in order to avoid tumor spillage and incomplete resection (1). Open adrenalectomy (OA) is the most widely accepted approach in the treatment of ACC. Stigliano et al. support is that open adrenalectomy is the only curative option when a margin-free complete resection (R₀ resection) is achieved and it is of predictive value for long-term survival. Nonetheless, subsequent follow-up commonly (85%) shows regional recurrence or presence of distant metastases even after complete resection of the tumor (6).

In addition, laparoscopic adrenalectomy (LA) while technically achievable is still greatly contentious due to tumor seeding that can occur as a result of the procedure. It is especially believed to occur in adrenal masses that appear malignant radiologically and therefore, LA is contraindicated in such cases. Most authors report that there is an increased rate of local recurrence and peritoneal carcinomatosis in those receiving laparoscopic adrenalectomy, postulating loss of capsule integrity and port site seeding as probable causes (3, 8).

Moreover, for tumors invading adjacent tissues or organs, concomitant resection of kidneys, liver, spleen, pancreas, stomach, colon, wall of the vena cava should be considered. Surgery often requires excision en bloc of the ipsilateral kidney, spleen, and partial pancreatectomy in the case of a left adrenal cancer and a partial hepatectomy for a right adrenal cancer. Cardiac bypass technique is sometimes needed for complete tumor removal in cases of a tumor thrombus in the IVC or the renal vein. The abdominal lymph nodes must also be excised to achieve complete resection of ACC (1, 6).

Further treatment is mandatory in patients where the resection was incomplete and a second surgical approach is not practical. For recurrent disease, reoperation is vital for the purpose of radical resection, especially if sufficient time (arbitrarily defined as 6 months to a year) has elapsed since the initial operation and if the patients are fit for reoperation (1,6,7). Metastatic disease debulking surgery, which removes as much of the tumor as possible, aids in reducing the mass effect, as well as the hormonal excess produced by the tumor (6). According to Fassnacht et al., tumor debulking, in most patients, is not an acceptable treatment option due to the fact that the recuperation from an extensive surgery is usually slow and postpones administration of systemic therapy. They also add that patients with profound Cushing's syndrome may profit from debulking surgery as it can reduce the tumor mass and hormone excess (1). However, medical palliation alone is the treatment of choice in patients with widely metastatic disease or rapidly enlarging tumors at diagnosis (8).

Medical treatment

The risk of post-operative recurrence is perhaps as high as 60-80%, and adjuvant therapy is recommended for most patients with ACC. Mitotane alone or mitotane in combination with chemotherapy serves as conventional or first line treatments. If complete resection of the primary tumor and all metastases can be performed at the time of diagnosis (even if two steps are needed), it should be followed by adjuvant mitotane therapy. In cases where surgery is not possible, mitotane is the backbone therapy (1,7).

Mitotane (1,1-dichloro-2- (*o*-chlorophenyl)-2-(*p*-chlorophenyl)-ethane or *o'p'*-DDD) is an isomer of the insecticide DDT (dichlorodiphenyltrichloroethane). It was first described in 1948 when it was shown to produce adrenal atrophy in dogs. This drug acts by inhibiting 11 β -hydroxylation and cholesterol side chain cleavage in the mitochondria of steroidogenic cells, therefore blocking cortisol synthesis hence decreasing both plasma and urine steroid levels (3,6,12). Mitotane exhibits a cytotoxic and degenerative effect on the fasciculata and reticularis areas of the adrenal cortex while the zona glomerulosa is barely affected (6,11). Metabolic activation is necessary for its adrenolytic effect. Mitotane is formulated as 500 mg tablets (Lysodren) for oral administration and is poorly

absorbed as 60 % is excreted in stool, usually unchanged while 40% concentrates in liver, brain, adipose and adrenal tissues. Attainment of therapeutic serum levels is delayed for 12-14 weeks after induction of therapy due to accumulation of the drug in adipose tissue. On the other hand, mitotane is released slowly from adipose tissue and can be measured in the serum months after cessation of the drug (3,5). The drug's accumulation in adipose tissue increases the plasma half-life from 2 -3 hours at the beginning of the therapy to 18-159 days (6).

A preferable administration schedule is to start with 1.5 g/day and to rapidly increase the daily dose to 4.5 to 6-g/ day within 3 to 4 days. The dose is adjusted according to the mitotane plasma concentration and lower doses are needed as the body stores become saturated. In patients who receive long-term therapy, mitotane doses should be adjusted every 4- 8 weeks until a stable level (14– 20 mg/L) is reached with tolerable side effects and subsequently at 3-month intervals (3, 5). It is critical to note that blood levels > 20mg/L are associated with higher risk of toxicity (1).

Adverse effects of mitotane treatment are diverse and common; most are correlated to its plasma concentrations. However, some gastrointestinal side effects such as anorexia, nausea, vomiting, and diarrhea, appear to be related to the daily dose (especially in patients receiving 2 g or more per day). In such cases, the use of 5-hydroxytryptamine blockers and loperamide may be beneficial. At higher doses, neuromuscular manifestations including ataxia, speech disturbance, muscle tremors, confusion, somnolence, and vertigo may develop. Mitotane treatment needs to be halted in cases of severe side effects, and can be restarted at lower dose when symptoms improve.

In addition, mitotane treatment causes adrenal insufficiency due to its adrenolytic effects as well as the increase of metabolic clearance of glucocorticoids and the concentration of cortisol- binding globulin (CBG) thus necessitating glucocorticoid replacement (50 -80 mg hydrocortisone daily). Mineralocorticoid secretion is less altered as mitotane mainly targets the cells of the zona fasciculata and the zona reticularis. Though, if mitotane is used for an extended period, renin concentration/ activity needs to be observed and may require replacement with fludrocortisone. Furthermore, some patients can profit from testosterone replacement as mitotane elevates the levels of sex

hormone binding globulin, which brings about low free testosterone concentrations in males. In most patients, alterations in thyroid hormones will ensue (low free T4 and low TSH), thus requiring monitoring every few months, and replacement when necessary (1, 3). Regardless of the many side effects of mitotane, most patients can be managed with tolerable toxicity for a vast period of time and the treatment needs to be prolonged for one to two years after the tumor regression (5).

Excess secretion of hormonal steroids due to ACC commonly disturbs the quality of life, especially Cushing's syndrome that usually produces hypokalemia, muscle wasting, osteoporotic fractures and infectious complications. In some patients, mitotane treatment alone is inadequate in regulating the hormonal excess because of its slow onset of action and its dose-limiting toxicity. Therefore, adrenostatic drugs such as ketoconazole, metyrapone, and etomidate have been efficaciously employed to inhibit steroidogenic enzymes and to return circulating cortisol into its normal range (1).

Furthermore, since less than 50 % of tumors respond to cytotoxic treatment and only for a short period of time, a large number of patients need salvage therapies, and the recommended first-line treatment in advanced ACC is a combination of etoposide, doxorubicin, cisplatin plus mitotane (EDP/M) (1, 5).

Radiotherapy

Radiotherapy (RT) is a valuable adjuvant therapy in all patients with ACC who receive surgical treatment since most resections are unsuccessful (4). However, there are limitations to its use in ACC. First of, ACCs are not very radiosensitive tumors. Secondly, they are in the vicinity of radiosensitive viscera such as the small bowel, kidney and spinal cord. Nonetheless, RT has an important value in the treatment of metastatic ACC, especially in the presence of bone disease, as well as improving symptoms in patients with massive abdominal tumors that impossible to remove surgically. At large, most authors recommend adjuvant RT to lessen the high probability of local disease relapse seen in ACC (8).

The lack of strong evidence supporting RT has resulted in a variety of treatment recommendations. Lebastchi et al. state that the German ACC group presently

recommends radiotherapy in the following cases: 1) all patients with incomplete (R1- detectable microscopic tumor residues after surgery or R2- macroscopic visible residual tumors) or uncertain (Rx) resections, 2) all patients with stage III disease regardless of resection adequacy, 3) strong consideration in cases of > 8 cm tumor size, Ki67 index > 10 %, and invasion of adjacent vasculature, even in cases of complete resection. At present, there are no specific guidelines for RT usage in patients with complete tumor removal (R0)(6, 8).

Adjuvant RT should begin no later than 3 months after surgery. The recommended fractionation protocol is made of single doses of 1.8-2.0 Gy per fraction on 5 days per week for a 5-6 weeks period treatment. The preferable total doses should range from 50 to 60 Gy and should not be lower than 40 Gy (8). Some authors advocate the use of mitotane treatment in conjunction with radiotherapy for patients on whom R1 and Rx resection was performed. However, mitotane dosages should be < 3g/day to avoid serious hepatic toxicity (6).

Targeted therapies

Recent innovations in the genetic alterations associated with ACC onset and progression made the discovery of several potential molecular targets possible for selective therapy of ACC such as IGF-IR antagonists, β -catenin antagonists, SF-1 inverse agonists, etc. (4, 6). As 90 % of ACCs patients express high levels of IGF-II acting via IGF-I receptor (IGF- IR), thus blockage of the IGF- IR is an important possibility to explore in treatment of these patients (1,6).

1.7. Prognosis

Even though many breakthroughs regarding ACC have been made, prognosis is still very poor and about 70 % of patients present with extra-adrenal disease at the time of diagnosis (8). The most critical factor for the prognosis of patients with ACC is an early diagnosis, which can greatly improve the survival rate (6). The average survival time of patients not receiving treatment is approximately 2.9 months and mostly relies on the size of the tumor (5). Three factors have been attributed to a shorter survival: older age at diagnosis, stages III (involvement of local lymph nodes) to IV (local organ invasion or distant metastases) disease, and cortisol hypersecretion. (4).

Furthermore, prognosis still mainly depends on tumor stage and 5-year survival rates are 84% for stage I, 63% for stage II, 51% for stage III and 15% for stage IV. Large tumor size (diameter > 12 cm) has been implicated in poor survival rate after complete resection and the 5 year- survival rate being as low as 5 %. Also, approximately 70% to 80 % of patients relapse after resection. In addition, a high mitotic rate, tumor necrosis, atypic mitotic figures, high Ki-67 values and evidence for mutated TP53 have been associated with advanced ACC and poor prognosis (1).

2. Aim of study

The purpose of the study is to present the treatment results of patients at the ACC referral center – KBC University Hospital Zagreb and to highlight the approach in the management of ACC in terms of diagnosis, follow-up, and treatment.

3. Methods

In a retrospective study, during the period of 1.1.2005 to 1.9.2013, 18 patients, consisting of 5 males and 13 females, were diagnosed with adrenocortical carcinoma at the ACC referral center – KBC University Hospital Zagreb. The patients had a mean age of 44 years (range, 17-74 years). ACC was diagnosed by utilizing the appropriate hormonal work-up, imaging methods and histopathological analysis. Stage of disease was assigned according to the ENS@T system given in **Table 1**.

The criteria for the histologic diagnosis of ACC was based on the Weiss scoring system which consist of nine histological parameters: high nuclear grades (nuclear grades III and IV), mitotic rate $>5/50$ high power fields (HPF), atypical mitotic figures, clear tumor cell cytoplasm (less than 25% tumor cells), diffuse architecture (greater than 33% of tumor), necrosis, venous invasion, sinusoidal invasion, and capsular invasion. A tumor is labeled malignant when it meets three or more of the stated criteria. Additionally, immunostaining for the proliferation marker Ki- 67 was performed in all patients.

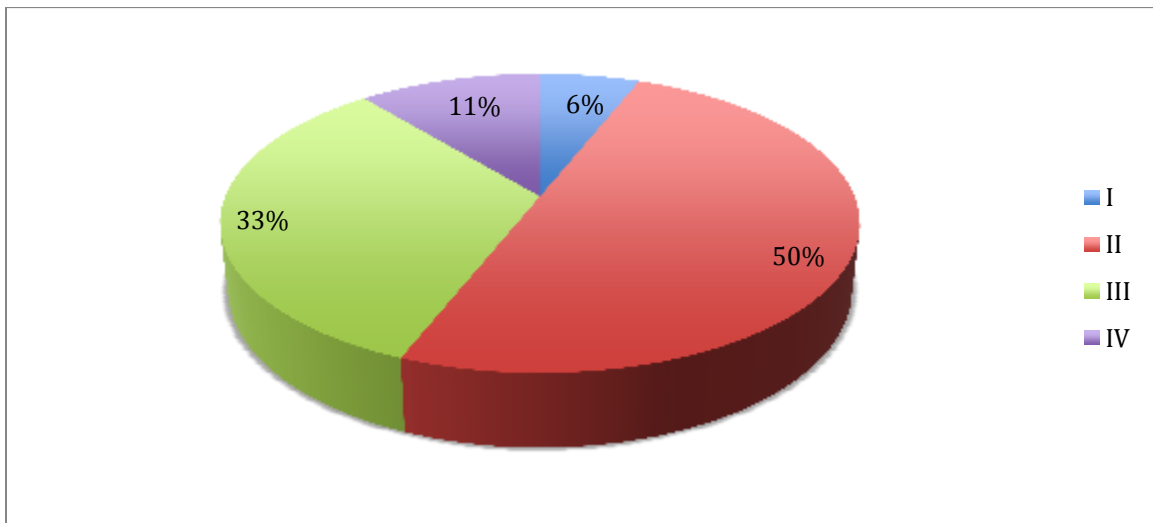
Moreover, 16/18 patients underwent radical surgical resection (Ro). Afterwards, selected patients with a Ki- 67 index greater than 10 % (11/18) received adjuvant therapy with mitotane. From March 2010, the concentration of mitotane received by patients was achieved according to the Lysosafe program, which included 14/18 patients. The aim was to reach mitotane plasma levels of 14-20 mg/L, and therefore, the mitotane doses were adjusted accordingly. Furthermore, chemotherapy was given if there was disease progression while receiving mitotane and in patients with metastatic disease at the time of diagnosis. One of the patients was treated with a combination chemotherapy, which consisted of etoposide, doxorubicin and cisplatin as well as the administration of mitotane (EPD/ M).

4. Results

4.1. Clinical characteristics of patients with ACC

Adrenocortical carcinoma was diagnosed as an adrenal incidentaloma in 13 out of 18 patients. In addition, 5 out of 18 (28 %) presented with and were diagnosed due to symptoms of hypersecretion of hormones. Functional tumors secreting increased levels of one or more hormones were identified in 12 patients (67%). Androgen- secreting tumors were the most common functional tumors, comprising 50 % (6/12), followed by cortisol-secreting tumors in 33% (4/12), 17- OHP in 17% (2/12), aldosterone- secreting tumors in 17% (2/12), and estradiol- secreting tumors in 8% (1/12), out of which mixed hormonal-secreting tumors were found in 3 cases. The tumor was located on the left in 11 and right in 7 patients. The median size of the tumor was 92 mm with the range of 45 to 160 mm. Moreover, at the time of diagnosis, stage I tumors were found in one patient (6 %), stage II in 9 (50 %), stage III in 6 (33 %), and stage IV in 2 (11 %) (**Figure 1**).

FIGURE 1: Stages at diagnosis



Stage I (1/18 – 6%), stage II (9/18 – 50%), stage III (6/18- 33%) & stage IV (2/18 – 11%).

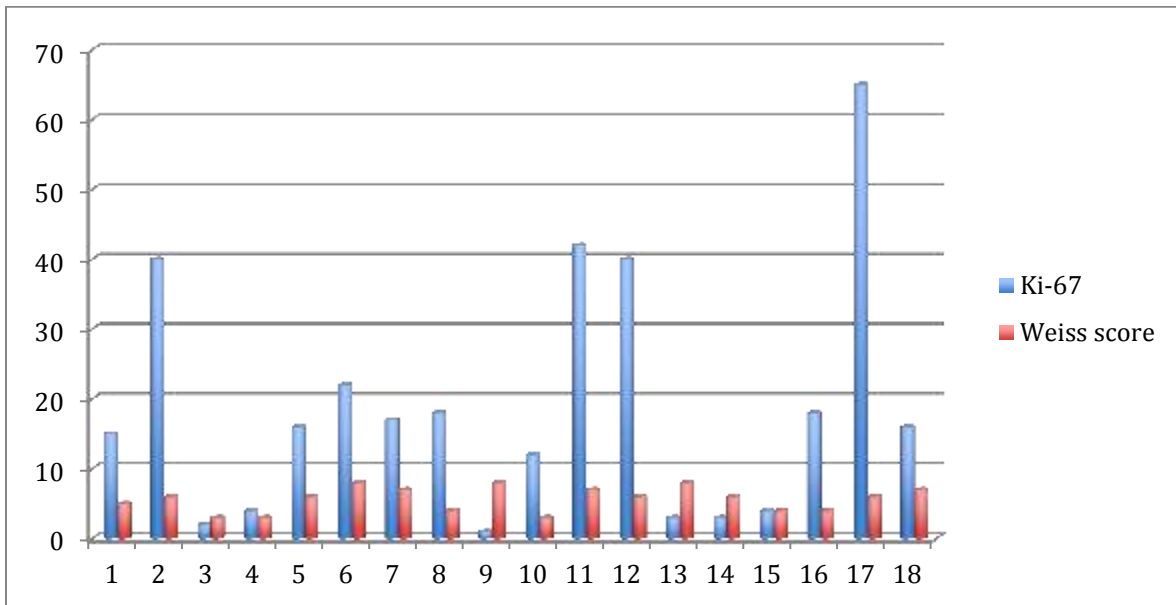
4.2. Surgical treatment

Surgical management consisted of curative resection (R0 resection – no gross residual disease) and was performed in 17 out of 18 patients (94%). Open adrenalectomy was performed in 11 patients and laparoscopic adrenalectomy in 7 patients. During the surgical procedures and in the post-operation period, no complications were encountered.

4.3. Pathohistological findings

The Ki-67 proliferation index was greater than 10 % in 11 out of 18 patients (61 %) with a median of 16 % and a range of 1 to 65%. In addition, 8/18 patients (44%) had a high mitotic index $\geq 9/50$ HPF. The median Weiss score was 6 with a range from 3 to 8 (Figure 2).

FIGURE 2: Ki-67 expression and Weiss score



Ki-67 >10% in 11/18 patients (median 16%, range 1–65%) and a median Weiss score: 6 (range 3–8).

4.4. Medical treatment of patients with ACC

The time that elapsed from the diagnosis to the operation was 40.7 ± 15.8 days and from the surgery to the mitotane therapy 48.8 ± 27.6 days. Mitotane was initiated using 1.5 g/day and was rapidly increased over the next 3 to 4 days to reach the dosage of 4.5 to 6-g/ day. All patients that were included in the Lysosafe program (14/18) reached the optimum mitotane concentration, which is between 14 to 20 mg/L. Mitotane alone was used in 13 patients; and mitotane plus etoposide, doxorubicin and cisplatin (EPD/ M) were utilized in one patient. Adverse effects due to mitotane treatment were observed in 8 patients. These mainly included gastrointestinal symptoms, dizziness, increased levels of cholesterol and high GGT (Gamma-glutamyl transpeptidase) ranging from 2x to 8x greater than the normal values.

4.5. Treatment outcome of patients with ACC

The median time of follow-up was 19 months and it ranged from 1 to 102 months. Moreover, 2/18 patients (11%) died; one because of advanced disease and the other the cause of death was not related to ACC. In addition, recurrence occurred in two patients (11%). With one of the patients, local recurrent tumor was surgically treated and with another one there was a solitary metastasis on the lungs, which was resected on two occasions. With the other patients (78%) there was no progression of the disease.

5. Discussion

This study presented results of 18 patients who were diagnosed with adrenocortical carcinoma at the ACC referral center – KBC University Hospital Zagreb. Most of our patients were diagnosed with adrenal incidentalomas (13/18). These are adrenal masses of >1 cm in diameter found incidentally on imaging performed for unrelated reasons. These incidentally discovered adrenal masses have increased due to widespread use of imaging procedures and new diagnostic techniques. In addition, only

5/18 patients presented with symptoms of hormone hypersecretion. Nonetheless, 12/18 patients were later diagnosed with functional tumors, of which androgen-secreting tumors were the most prominent, followed by cortisol-secreting tumors. However, many studies have showed that rapidly progressing Cushing's syndrome with or without virilization is the most frequent presentation in the majority of patients.

Many ACC patients suffer from a locally advanced or metastatic disease at the time of diagnosis. Stage II disease was predominant in our patients (9/18), followed by stage III (6/18), stage IV (2/18) and lastly, stage I (1/18). Both patients with stage IV disease underwent surgical resection and received adjuvant therapy; nevertheless, they died after 11 and 18 months follow-up respectively. The rest of the patients underwent radical surgical resection (R0), which has been the mainstay treatment of ACC tumors and has been shown to improve the survival rates. Open adrenalectomy was the main procedure performed (11/18) when compared to laparoscopic adrenalectomy (7/18). Usually laparoscopic surgery in ACC is feared due to the seeding of the tumor cells in the abdomen that can occur as well as the high rates of local recurrence due to the loss of capsular integrity. The resection status (R0, R1, R2) is a major predictor of prognosis for ACC. A margin-free complete resection (R0 resection), in fact, provides the only means to achieve long-term survival. To obtain an R0 resection of a locally advanced ACC, it is often necessary to resect parts of the adjacent organs such as the wall of the vena cava, liver, spleen, colon, pancreas and/or stomach.

In addition, mitotane has been used principally as the agent of choice in treating patients with ACC. By following serum mitotane levels, the lowest dose is given that achieves a 'therapeutic' level ($>14\text{mg/L}$). Since the majority of the patients (80%) received mitotane adjuvant therapy and since 14/18 went into remission, the importance of mitotane in prolonging survival cannot be stressed enough. In a study by Terzolo et al., the maintenance of plasma mitotane concentration $\geq 14\text{mg/L}$ was shown to predict tumor response and better survival rates in patients with ACC, especially in advanced disease (13). In selected cases, other combination chemotherapy can be given such as EPD/ M (etoposide, doxorubicin, cisplatin plus mitotane), which was administered to one patient.

Moreover, in case of painful metastasis, palliative radiotherapy is an option, especially in bone lesions. However, none of our patients were treated with radiotherapy

since ACCs are not very radiosensitive tumors as well as their location, which is in close proximity to radiosensitive viscera such as the small bowel, kidney and spinal cord. Nevertheless, radiotherapy has a significant role in the treatment of metastatic ACC, particularly in the presence of bone disease, as well as improving symptoms in patients with large abdominal tumors that cannot be removed surgically.

Even though many discoveries have been made regarding ACC, prognosis is still very poor and the majority of patients present with extra-adrenal disease at the time of diagnosis. The most essential aspect for the prognosis of patients with ACC is an early diagnosis, which can significantly improve the survival rate. Three factors have been associated to a shorter survival rate: older age at diagnosis, stages III to IV disease, and cortisol-secreting tumors. In addition, the only parameter related to patients' survival rates is a Ki-67 proliferation index of more than 10%. Ki-67 >10% was found in 11/18 patients (61%), and it is strongly associated with a poor clinical outcome, a shortened disease-free status and a decreased overall survival. A 5 year- follow-up could only be documented with five patients, out of which two died (diagnosed at stage IV) and three went into remission (diagnosed at stages I &II). Additionally, 13/18 patients have not yet reached the 5 year- follow-up necessary for this study to well assess the overall 5-year survival rates.

6. Conclusion

ACC is a rare endocrine tumor that has to be taken care of in a specialized center with great experience in treating this tumor. Radical resection with adjuvant mitotane therapy in patients with high-risk progression of the disease is the foundation of a successful treatment. In our cohort, 14/18 patients had no recurrence of disease after Ro resection and adjuvant mitotane therapy. In addition, 2/18 patients died after 11 and 18 months follow-up respectively, and 2/18 had recurrence of the disease. However, our data is limited due to a short follow-up period and therefore, we cannot assess the overall 5-year survival rates.

7. References

1. Fassnacht M, Eder M, Allolio B (2009) Clinical management of adrenocortical carcinoma. *Best practice & Research clinical endocrinology & metabolism* 23: 273-289.
2. Bilimoria KY, Shen WT, Elaraj, Bentrem DJ, Winchester DJ, Kebebew E, Sturgeon C (2008) Adrenocortical carcinoma in the United States. Treatment utilization and prognostic factors. *Am Canc Soc* 113:3131-3136.
3. Veytsman I, Nieman L, Fojo T (2009) Management of endocrine manifestations and the use of mitotane as a chemotherapeutic agent for adrenocortical carcinoma. *J Clin Oncol* 27: 4619-4629.
4. Maluf DF, de Oliveira BH, Lalli E (2011) Therapy of adrenocortical cancer: present and future. *Am J Cancer Res* 1(2): 222 -232.
5. Van Ditzhuijsin CIM, Van de Weijer R, Haak HR (2007) Adrenocortical Carcinoma. *Nether J Med* 65 (2): 55-59.
6. Stigliano A, Cerquetti L, Sampaoli C, Bucci B, Toscano V (2012) Current and emerging therapeutic options in adrenocortical cancer treatment. *J Onc* doi: 10.1155/2012/408131.
7. Glover AR, Ip JCY, Zhao JT, Soon PSH, Robinson BG, Sidhu SB (2013) Current management options for recurrent adrenocortical carcinoma. *OncoTargets and Therapy* 6:635-643.
8. Lebastchi AH, Kunstman JW, Carling T (2012) Adrenocortical carcinoma:current therapeutic state-of-the-art. *J Onc* doi: 10.1155/2012/234726.
9. Symeonidis D, Chatzinikolaou I, Koukoulis G, Mamaloudis I, Tepetes K (2013) Adrenocortical carcinoma presenting with signs of acute abdomen. doi.org/10.1155/2013/132726.
10. Kendrick ML, Llyod R, Erickson L, Farley DR, Grant CS et al. (2001) Adrenocortical carcinoma. Surgical progress or status quo? *Arch Surg*136: 543-549.
11. Ghataore L, Chakraborti I, Aylwin SJ, Schulte KM, Dworakowska D, Coskeran P, Taylor NF (2012) Effects of mitotane treatment on human steroid metabolism: implications for patient management. *End Conn* 1:37-47.
12. Maclere-Denost S, Leboulleux S, Borget I, Paci A, Young J et al. (2012) High-dose mitotane strategy in adrenocortical carcinoma prospective analysis of plasma mitotane measurement during the first 3 months of follow-up. *Eur J Endocr* 166: 261-268.
13. Terzolo M, Baudin AE, Ardito A, Kroiss M, Leboulleux S, Daffara F, Perotti P, Feelders RA, deVries JH, Zaggia B, De Francia S, Volante M, Haak HR, Allolio B, Al Ghuzlan A, Fassnacht M, Berruti A (2013) Mitotane levels predict the outcome of patients with adrenocortical carcinoma treated adjuvantly following radical resection. *Eur J Endocr* 169 (3): 263 -70 doi: 10.1530/EJE-13-0242.

8. Curriculum Vitae

PERSONAL INFORMATION Aude Mugisha

15 D, Jordanovacki Odvojak,
10000 Zagreb (Croatia)
+385997940146
aude.ndamama@gmail.com

EDUCATION AND TRAINING

September 2008–Present **Doctor of Medicine**
University of Zagreb Medical School in English, Zagreb (Croatia)

January 2008–August 2008 **Doctor of Medicine**
University of Seychelles American Institute of Medicine, Victoria (Seychelles)

September 2005–May 2007 **Bachelor of Science**
Montclair State University,
Montclair, NJ (United States)
Major: Molecular Biology
Minor: Biochemistry

September 2002–May 2005 **Associate of Arts**
Union County College,
Cranford, NJ (United States)
Major: Biology

PERSONAL SKILLS

Mother tongue(s) French, English, Kirundi

Other language(s)
WRITING

UNDERSTANDING

SPEAKING

Listening

Reading

Spoken interaction

Spoken
production

Croatian
A1

A1

A1

A1

A1

Levels: A1/A2: Basic user - B1/B2: Independent user - C1/C2: Proficient user
[Common European Framework of Reference for Languages](#)

Communication skills	- good communication skills gained as a tutor
Organisational / managerial skills	- good organisational skills gained as secretary of Phi Theta Kappa (2004-2005), responsible for promoting events
Job-related skills	- mentoring skills gained as a tutor for Chemistry, Biology, Physics, Mathematics and French courses
Computer skills	- good command of Microsoft Word, Microsoft PowerPoint, Microsoft Excel, Internet Research

ADDITIONAL INFORMATION

Additional Work Experience	<p>University Hospital Centre Zagreb, Croatia(2012-2013) Teaching assistant for the course Clinical Propaedeutics</p> <p>Montclair State University, NJ, USA (2006-2007) Oversaw activities in the Microbiology Laboratory Set up and proctor the laboratory practical exams</p> <p>Union College County, NJ, USA (2003-2005) Certified tutor for Chemistry, Biology, Physics. Mathematics and French courses</p>
Volunteer Work	<p>- First International Congress of the international College of person - centered medicine (Nov2013), Zagreb, Croatia</p> <p>- Burundi Red Cross - (Aug 2013) Shadowing doctors during consultations</p> <p>- Robert Wood Johnson University Hospital (2007) Hamilton, NJ Assisting with day to day operations in the Central Sterile Supply Department Pre-med/ physician shadowing program (summer 2007)</p>
Honours and awards	<p>University of Zagreb School of Medicine- Dean's Award 2011 (awarded at most once in the course of medical studies)</p> <p>Montclair State University- Dean's List (2005-2007)</p> <p>Phi Theta Kappa Science Honors Scholarship (2005 -2007)</p> <p>Union Hospital Foundation/ Biological Science Award for Outstanding Biology Student (2005)</p> <p>Who's who Among Students at Union County College (2005)</p> <p>Union County College - Dean's List (2003-2005)</p>