

Actual grafts used for anterior crucial ligament reconstruction

Pourci, Francois Ezechiel

Master's thesis / Diplomski rad

2014

Degree Grantor / Ustanova koja je dodijelila akademski / stručni stupanj: **University of Zagreb, School of Medicine / Sveučilište u Zagrebu, Medicinski fakultet**

Permanent link / Trajna poveznica: <https://urn.nsk.hr/urn:nbn:hr:105:943690>

Rights / Prava: [In copyright](#) / [Zaštićeno autorskim pravom.](#)

Download date / Datum preuzimanja: **2024-04-24**



Repository / Repozitorij:

[Dr Med - University of Zagreb School of Medicine Digital Repository](#)



**UNIVERSITY OF ZAGREB
SCHOOL OF MEDICINE**

François Ezechiel Pourci Rosenthal

**ACTUAL GRAFTS USED FOR ANTERIOR
CRUCIATE LIGAMENT RECONSTRUCTION**

GRADUATE THESIS



Zagreb, 2014

This graduate thesis was made at the Department of Orthopaedic, University Hospital Center Zagreb, School of Medicine, Zagreb University mentored by Assistant Professor Tomislav Smoljanovic, MD, PhD and was submitted for evaluation in the academic year 2013/2014.

LIST OF ABBREVIATIONS

ACL – Anterior Cruciate Ligament

ADL – Activities Daily Living

AM – AnteroMedial

ALL – Antero-Lateral Ligament

BTB – Bone Tendon Bone graft

CANSs – Computer-Assisted Navigation Systems

IKDC – International Knee Documentation Committee

LARS – Ligament Advanced Reinforcement System

LCL – Lateral Collateral Ligament

MCL – Medial Collateral Ligament

PCL – Posterior Cruciate Ligament

PDLLA – Poly-D,L-lactide

PGA –Polyglycolic Acid,

PL – PosteroLateral

PLA – Polylactic Acid

PLLA – Poly-L-lactic acid

PDS – Polydioxanone

TLS – Tape Locking Screw

TABLE OF CONTENTS

1. SUMMARY	1
2. INTRODUCTION.....	2
2.1. General information about the Anterior Cruciate Ligament (ACL).....	2
2.2. Characteristics of the ACL.....	3
2.3. The ACL Injury.....	3
2.4. Criteria for a knee surgery:.....	6
2.5. The different techniques of ACL reconstruction over the years.....	8
3. TUNNEL DRILLING FOR ACL AND FIXATION METHODS OF GRAFTS.....	10
3.1 Tunnel drilling for ACL fixation.....	10
3.2. Fixation methods of graft for ACL replacement.....	11
4. AUTOGRAPH.....	14
4.1. Pathophysiology of graft incorporation, the ligamentization.....	14
4.2. The Bone-Tendon-Bone grafts.....	15
4.3. Hamstrings tendon.....	17
4.4. Quadriceps tendon:.....	21
4.5. Fascia lata graft.....	22
5. ALLOGRAFT TENDON	23
6. SYNTHETIC LIGAMENTS	24
7. COMPUTER ASSISTED LIGAMENTOPLASTY	25
8. DISCUSSION	26
9. CONCLUSION	27
10. ACKNOWLEDGEMENTS	29
11. REFERENCES	30
12. BIOGRAPHY	42

1. SUMMARY

The primary role of Anterior Cruciate Ligament (ACL) is to resist to anterior translation of the tibia on the femur. Its secondary role is to stabilize the knee in order to be able to resist excessive varus and valgus stress, hyperextension of the knee and also to facilitate proprioception. ACL is the most commonly injured ligament in the knee. If patients are unable to continue with sports and regular daily activities due to knee instability, reconstruction surgery is proposed. There are a wide variety of grafts used for ACL reconstruction. Artificial materials have been historically shown not to be the appropriate solution for ACL reconstruction. Grafts of human origin are referred to as autografts when created from the patient's own tissues and allografts when harvested from a separate human donor. Grafts can be further categorized according to the tissue from which they are derived. There are tendon grafts (such as hamstrings tendons or iliotibial bands), bone-tendon grafts (such as quadriceps tendon or Achilles tendon) and bone-tendon-bone grafts (such as patellar bone, patellar ligament, tibial tuberosity bone graft). All of these grafts can be fixed within the knee by numerous different systems depending on different grafts and surgeon's preferences.

This thesis will present an overview of the graft types and techniques currently in use for ACL reconstruction.

2. INTRODUCTION

2.1. General information about the Anterior Cruciate Ligament (ACL):

The knee is the largest and the most superficial joint structure. It is a hinged synovial joint allowing flexion and extension. The bony structures are the distal part of the femur, the patella and the proximal part of the tibia. The hinge movements are combined with gliding and rolling and rotation about a vertical axis. It is composed of a joint capsule consisting of an external fibrous layer and an internal synovial membrane that lines all internal surfaces of the articular cavity not covered with articular cartilage. The joint capsule is reinforced by six extracapsular ligaments: the lateral collateral ligament (LCL), the medial collateral ligament (MCL), the anterolateral ligament (ALL)⁽¹⁾, the patellar ligament, the oblique popliteal ligament and the arcuate popliteal ligament. The intra-articular ligaments of the knee joints consist of the anterior cruciate ligament (ACL) and the posterior cruciate ligament (PCL). The ACL and PCL maintain contact with the femoral and tibial articular surfaces during flexion of the knee. They also allow extension and slight rotation of the knee. The ACL's primary function is anteroposterior stabilization of the knee. Other constraints on knee movement, such as rotation of the tibial plateau on the femur or varus and valgus stress are also partially controlled by the ACL^(2,3,4). In almost 40% of cases, the patients suffering an ACL injury describe having felt or heard a pop from within the knee when the injury occurred⁽⁵⁾. The majority of the patients who continue to experience knee instability following an ACL tear are unable to continue with sports or daily activities. The variety of surgical options available allows

selection of a specific procedure based upon the individual characteristics of the injury as well as the preferences of the patient.

2.2. Characteristics of the ACL:

The ACL originates on the posteromedial aspect of the lateral femoral condyle. It courses anteromedially and its insertion point is localized in a depressed area anterior to and between the intercondylar eminences of the tibia. It has two distinct bundles, the anteromedial bundle that is tight in flexion and the posterolateral bundle that is tight in extension. There is a small blood supply from the middle geniculate artery and innervation from branches of the tibial nerve. From previous studies we know that the cross sectional area of ACL is 44 mm^2 with a tensile load up to 2160 N, a stiffness of 242 N/m and a strain rate of 20% before failure ^(6,7,8). Forces on the ACL range from 100 N during passive knee extension to approximately 400 N during walking and up to 1730 N during cutting and acceleration-deceleration activities ^(9,10).

2.3. The ACL Injury:

The ACL injury is the most common ligament injury of the knee ⁽¹¹⁾. In the United States the annual incidence of ACL injuries is approximately 200000 annually, resulting in 100000 ACL reconstructions each year ^(12,13).

Of the various circumstances that lead to knee injuries, 30% involve direct trauma in situations such as traffic accidents or contact sports. The remaining 70% occur through non-contact mechanisms, especially in pivot sports associated with stopping suddenly and slowing down while running ⁽¹⁴⁾.

The physiologic mechanisms that can cause an isolated ACL injury are of two types. Firstly, injury can occur during the contraction of the quadriceps muscle concurrent with internal rotation of the leg when the foot is on the ground. This is seen in basketball when the athlete lands while grabbing a rebound. ACL rupture can also be caused by a sudden active contraction of the quadriceps that induces a hyperextension of the knee and an anterior translation of the tibia when the leg is not touching the ground. This can occur when shooting a football ball. Additional injuries to the knee can also occur along with ACL rupture. These can include meniscus damages, tear or rupture of the posterior cruciate ligament and injuries to the collateral ligaments. Such complex injuries occur when external rotation of the femur on a fixed tibia is combined with a valgus load on a flexed knee (figure 1). It is seen in twisting or cutting type movements in football, skiing and soccer. Finally, varus flexion of the knee associated with its internal rotation can also induce complex ACL injuries. A complex injury including the ACL, the MCL and the lateral meniscus is referred to as the O'Donoghue's triad but is also known as the "unhappy triad" ⁽¹⁵⁾.

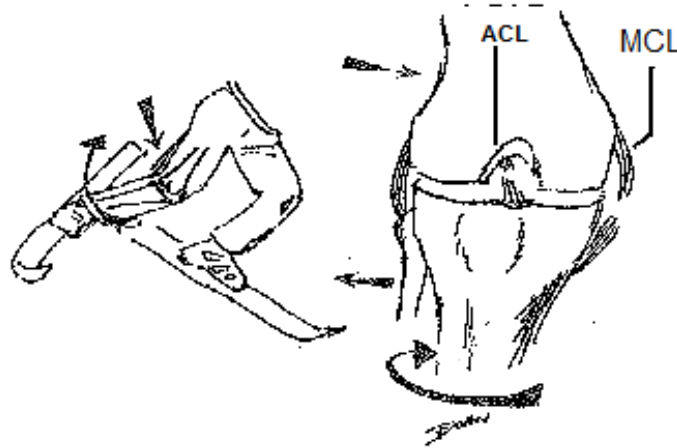


Figure 1: the left side of the scheme presents a specific position in skying where in the distal right leg, is in external tibial rotation during an inward movement of the knee. This position involves rotation of the tibial during an inward movement of the knee that leads to rupture of the Anterior Cruciate Ligament (ACL) and Medial Collateral Ligament (MCL) as shown on the right side of the scheme ⁽¹⁶⁾

If an ACL injury is suspected, precise history taking, inspection, palpation and range of motion testing should be performed. Knee oedema and ecchymosis can occur, but those are not specific to ACL injury. The Lachman test is the most sensitive test for clinically assessing an ACL rupture ⁽¹⁷⁾. It is even more accurate if it is done as early as possible after the knee injury before the development of knee oedema and extreme pain. This assessment is performed by placing the patient in a supine position on the examination table with the knee flexed to 20-30° and the foot resting on the table. The femur is stabilized with one hand, while the other hand applies an anteriorly directed force on the posterior tibia side. The degree of tibial displacement is determined and graded. Grade 1 ACL instability displays anterior movement of the tibia from 0 mm to 5

mm, meaning that the ACL has been slightly stretched, but is still able to help keep the knee joint stable. Grade 2 instability allows forward movement of the tibia between 5mm to 10 mm meaning that the ACL is stretches to the point where it becomes loose. A grade 3 instability displays displacement of more than 10 mm which is the consequence of a complete tear of the ligament. The quality of the endpoint is also important to mention as “soft” or “firm”. Other sensitive tests can be added to increase the accuracy of the clinical diagnosis of ACL rupture like the anterior drawer test, the flexion-rotation-drawer test, the pivot shift test, the MacIntosh test ⁽¹⁸⁾ and the Losee test.

2.4. Criteria for a knee surgery:

When a patient is seen for a suspected ACL rupture, the clinical evaluation are the first tests to assess the presence of an ACL tear or rupture. These do not, however, provide sufficient information for justifying either conservative treatment or surgical reconstruction. A magnetic resonance imaging (MRI) of the knee with weighted T1 and T2 with sagittal, coronal and axial slice is integral to the standard of care as it allows more precise evaluation of the injuries sustained by all knee ligaments and surrounding structures (figure 2). It is also important to evaluate the degree to which the injury places limitations on activities daily living (ADL) and participation in athletic activities. The level and the type of sports activity the patient plans to resume after the injury are also important criteria for ACL surgery. Patients engaging in pivot sports, in particular, require the knee stability that only an intact ACL can provide. The patient's psychological state, behaviour patterns and degree of comprehension concerning the injury should be assessed in order to design a specific rehabilitation program with the best chances for

successful recovery from ACL injury. Minor criteria such as the time passed after the injury, the skeletal age of the patient and the chronicity of the injury should be taken into consideration. It is common to allow the acutely injured knee to settle, giving time for resolution of effusion, restoration of range of motion and recovery from of concomitant ligamentous injuries ⁽¹⁹⁾. Furthermore a delayed reconstruction allows patients to trial conservative therapy to see if surgery is indicated.

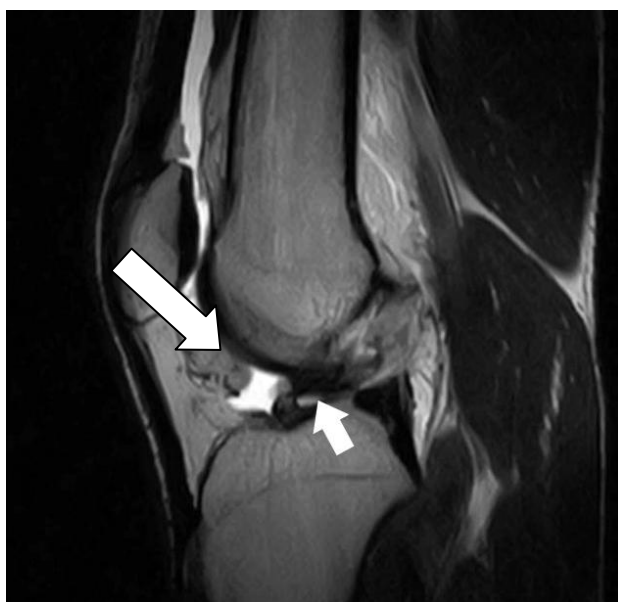

Figure 2: Sagittal T2-weighted magnetic resonance imaging (MRI) of ruptured anterior cruciate ligament (ACL) pointed by white arrow.

As with any surgery, some general factors influence the outcome of a successful operation. The standard criteria for general anaesthesia such as the patient's age and comorbidities can have an impact on the final outcome of the surgery. The risk of disease transmission, the characteristics of the ACL graft (age of the donor, size of the graft, tissue availability) and the patient's preference concerning the type of graft can all

influence the outcome of the surgery. The goal of this surgery is to regain a normal knee function with full athletic range of motion and with a secure and a good strength fixation. The surgery should result in neither clinical nor radiologic evidence of osteoarthritis later in life. The operative approach should provide maximal graft quality with minimal donor site morbidity. The final factors determining the selection of a specific surgical technique include the surgeon's experiences and preferences.

2.5. The different techniques of ACL reconstruction over the years:

In 1895, the first direct suturing of the native ACL with wrenching of the tibial plateau was performed by A.W. Mayo Robson ⁽²⁰⁾. In 1903, F. Lange ⁽²¹⁾ performed the first ACL replacement, using braided silk attached to the semitendinosus as a ligament substitute. The results were close to 100% failure. Orthopaedic surgeons pioneered another approach to repairing ACL ruptures. Iliotibial band transplants performed in 1917 by Ernest W. Hey Groves ⁽²²⁾ were the first direct open surgical repairs of the ACL using tendon grafts. This became the standard of care until D. J. Dandy introduced arthroscopy surgery in 1981 ⁽²³⁾. After a few years, the operations of ACL replacements with arthroscopy were relatively easy to obtain. They quickly showed improvements over open surgery that include a decrease in nosocomial infections and surgical complications. Arthroscopy also allows the surgeon to position the graft more precisely and to also treat associated injuries such as meniscal or chondral damage, all during a single procedure. The majority of the grafts that were used at the beginning of this new era were the patellar ligaments after which the hamstring tendon, the fascia lata, the quadriceps and the allografts were introduced. Improved understanding of ACL anatomy

allowed surgeons to develop new techniques from double to quadruple branded ligament grafts. This also includes techniques such as the use of the unifascicular ligament to repair partial ruptures of the anteromedial and posterolateral part of ACL. In the last 5 years a new technique call the double bundle brunch was introduced (figure 3). This technique consists of creating four intra-articular tunnels that allows a higher surface contact between the bones and the graft and enhances healing at the graft insertion sites ⁽²⁴⁾. The double bundle reconstruction tends to imitate the ACL anatomy which consists of two bundle branches that are stuck together. This technique seemed to provide a better control of the anterior laxity of the knee. Until a recent study, it was commonly accepted that this technique also has a better control on the rotational laxity of the knee which is now questionable with the discovery of the ALL hypothetic role ⁽¹⁾. For the moment, the recent clinical studies didn't show significant differences with other surgery techniques for ACL replacement outcome ⁽²⁵⁾. As it stands, the low cost effectiveness of this Lemaire technique associated with intra articular LCA reconstruction and the longer operating time lead the surgeons to avoid this specific type of operation.

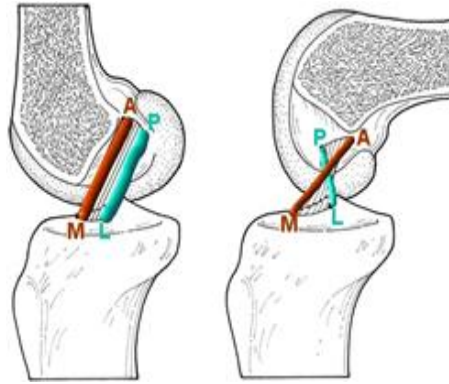


Figure 3: schematic view of the anterior cruciate ligament reconstruction using the double-bundle reconstruction. On the schematic left side: view of anteromedial (AM) bundle graft parallel to the posterolateral (PL) bundle graft. On the right schematic side: view of AM graft and PL bundle graft implemented in a cruciate position ⁽²⁶⁾

The most recent innovations in ACL repair involve computer assisted ligamentoplasty. While this method was developed as a means to further assist surgeons in improving outcomes they have not yet demonstrated superior clinical results when compared to arthroplasty ⁽²⁷⁾.

This review paper will present an overview of the methods currently used for ACL reconstruction.

3. TUNNEL DRILLING FOR ACL AND FIXATION METHODS OF GRAFTS

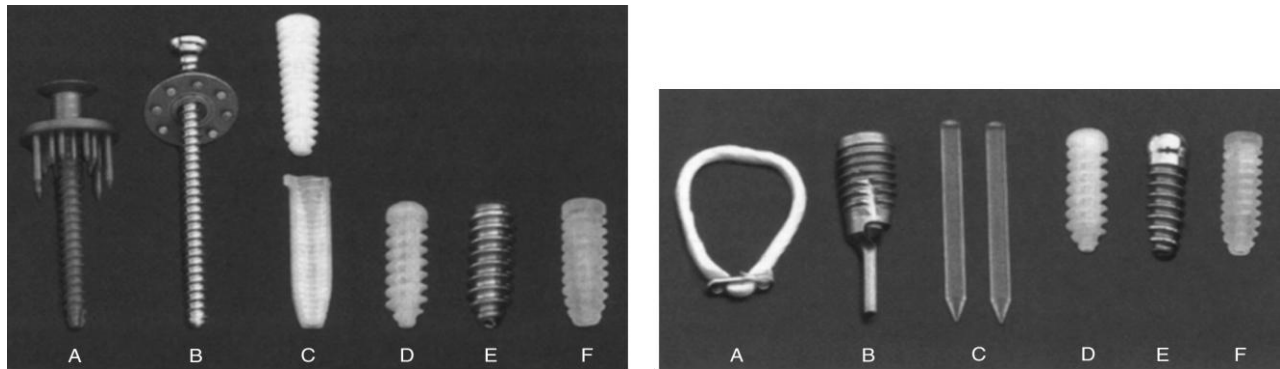
3.1. Tunnel drilling for ACL fixation:

Before a graft fixation occurs, the creation of bone tunnels on the tibial and femoral side could be made from the outside to the inside or from the inside to the outside. The use of a retrograde bio-interference screw (figure 4) in the tunnel is known to decrease bone trauma ⁽²⁸⁾. The validity of this method is confirmed by the study of

Mac Adams ⁽²⁹⁾ on cadavers where antegrade drills provoked subchondral microfractures, which is not the case in retrograde drilling. The angle of drilling on the tibial side is also an influencing factor on the outcome of the surgery. The drilling induces a post-operative stress redistribution that can potentiate a tunnel widening. This can be alleviated if the tunnel drill-guide angle range is from 55° to 65° ⁽³⁰⁾.

3.2. Fixation methods of graft for ACL replacement:

Fixation is the weakest link in the initial 6- to 12-week period, during which the healing of the graft to the host bone occurs. It needs to withstand early rehabilitation, which consists of forces as high as 450 to 500 N ⁽⁸⁾. If the graft is poorly fixed, slipping may occur that will result in knee instability. This problem usually occurs on the tibial side of the knee ⁽³¹⁾. One of the ACL fixation types, the so called trans-fixation system (Rigidfix, Transfix, figure 4A and 6) consists of a nail or a pin that goes through the femur to fix the ligament inside the femoral tunnel. At the tunnel exit clips are used to block the ligament against the bone (figure 5) and can also be associated with pins. The endobutton system (figure 4B) allows the mooring of the graft in the femoral tunnel by a thread which passes in the loop made by the ligament and moors on a button on the outside of the bone it leans on.



A Figure 4.A. Tibial side hamstring fixation devices: A = WasherLoc, B = spiked washer, C = Intrafix, D = BioScrew, E = SoftSilk, F = Smart-Screw ⁽³¹⁾.

B Figure 4.B. Femoral side hamstring fixation devices: A = EndoButton, B = Bone Mulch Screw, C = RigidFix, D = Bioscrew, E = RCI Screw, F= SmartScrew ⁽³¹⁾

The interference screw (figure 4) is another type of fixation that is also referred to as the TLS (Tape Locking Screw). They can be metallic with titanium or resorbable made of polyglycolic acid (PGA), polylactic acid (PLA), poly-L-lactic acid (PLLA), poly-D, L-lactide (PDLLA), polydioxanone (PDS). They diminish the mobility of the graft in the tunnel, limiting the tunnel widening and facilitating the graft healing ⁽³²⁾.

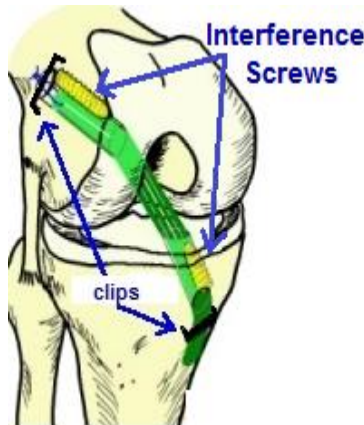


Figure 5: Schematic view of the knee showing clips and interference screws on the tibial and femoral part ⁽³³⁾.

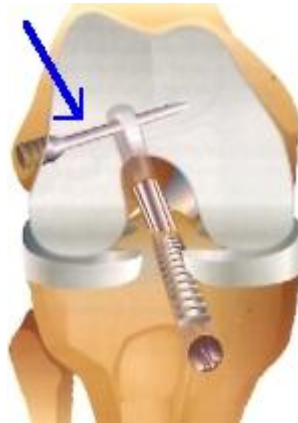

Figure 6: Schematic representation of TransFix femoral fixation system (blue arrow) and tibial interference screw ⁽³⁴⁾.

The metallic screw allows rigid fixation and is well tolerated ^(31,35). Some types of metals can interfere with the interpretation of MRI images due the artefacts that they cause ⁽³⁶⁾, but the use of titanium screws and tomodynamometry facilitate radiology interpretation. Repair with resorbable screws create risk of knee instability after the material resorbs ^(35, 37, 38), knee synovitis ⁽³⁹⁾ and an increased in recovery time. The screw diameter and screw divergence from the bone block are also influencing factors on the graft fixation

result ⁽³⁶⁾. For soft tissue graft fixation, suture, staples, screw (figure 5) with washer constructs and interference screw can be used on the tibial fixation side. On femoral side, cross-pins and buttons can also be added. For hamstring fixation, the Bone Mulch Screw (figure 6) on the femoral side is the screw of choice for fixation strength, stiffness and resistance to load compared to EndoButton, RigidFix, Smart Screw ⁽⁴⁰⁾. On the tibial side, Intrafix should be the gold standard ⁽³¹⁾.

4. AUTOGRAPH

4.1. Pathophysiology of graft incorporation, the ligamentization:

The incorporation of the graft in the knee in the drilled tunnel induces an inflammatory process. In its first phase, white blood cells induce acellular and avascular necrosis of the graft cells. The remaining intact collagen of the graft serves as a scaffold for host cell migration and matrix production. The second phase begins 20 days and last 3-6 months post-surgery. It is characterized by revascularisation and fibroblast migration into the graft tissue ⁽⁴¹⁾. In this period the strength of the graft decreases 11% and the stiffness decreases 13% compared to a normal ACL ⁽⁴²⁾. The final phase from 6 to 9 months post-surgery consists of graft healing with remodelling of the collagen structure into more organized pattern with improvement of strength and stiffness. Histologically, the mature grafts may resemble the normal human anterior cruciate ligament, but ultrastructural differences regarding collagen fibril distribution do persist ⁽⁴³⁾.

4.2. The Bone-Tendon-Bone grafts (BTB):

The Kenneth Jones procedure consists of harvesting from either the ipsilateral or contralateral (figure 7) knee. Including such bony anchor points in the graft allows the most rapid incorporation of the graft into the bone ^(44,45). Harvesting the central third of the patellar tendon does not diminish quadriceps strength or functional capacity in highly active patients who undergo intense rehabilitation after surgery ^(46,47). The rigid fixations on the tibial side graft are problematic due to a fixation into an area of low bone density which results in possible weakness caused by graft slippage around the screw. On the femoral side, the graft is fixed into an area of higher bone density, making suspensory fixation possible. There remains, however, the risk of tunnel widening and inhibition of healing.

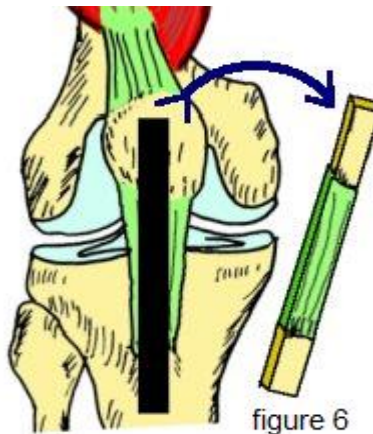


Figure 7: Kenneth Jones procedure showing the harvesting of bone plugs and patellar graft ⁽⁴⁸⁾

The gold standard procedure for fixation of BTB grafts is with interference screws as this prevents any slippage of the graft.

The BTB graft has the largest number of reported outcomes in the literature and is the most widely used graft ⁽⁴⁹⁾. Its advantages have been pointed out in recent studies

where a follow-up after ACL reconstruction has been made. It has been found that knee laxity and knee instability as measured by the Lachman and Pivot Shift tests were decreased compared to hamstring techniques ⁽⁵⁰⁾. In certain reviews, this surgery is the treatment of choice for very active patients. These include patients who participate sports with ample cutting, pivoting, or jumping motions as well as those who aim to return to play as quickly as possible ⁽⁴⁷⁾.

The BTB technique is characterized by a few disadvantages that must be considered before selecting this method of treatment. Firstly, these grafts are of fixed length graft, a characteristic that can cause a graft tunnel length mismatch if not adjusted correctly. This does not present an issue in soft tissue grafts were the graft can be shortened to the desired length. Another disadvantage is that patients commonly experience pain while kneeling as a result of the BTB reconstruction. Additionally, this graft is associated with moments of decreased knee flexion during the stance phase of gait, resulting in higher impact loads in the medial compartment when compared to hamstring tendon grafts. It may explain the aetiology of medial compartment degenerative change associated with the patellar tendon graft ⁽²⁾. This effect might be reduced with bone graft impacted into the bone defects and/or a two-incision approach surgery. Another concern is the anterior knee pain commonly reported by patients after BTB surgery. One study suggests that it is due to quadriceps inhibition associated with reduced extension strength ⁽⁵⁰⁾. Two other studies conducted by Sachs et al ⁽²⁸⁾ and Shelbourn and Nitz ⁽⁵¹⁾ suggest that it is due to loss of motion and poor rehabilitation techniques rather than donor site. Iatrogenic localized tenderness and numbness sensory disturbance through damage to the infrapatellar branch of the saphenous nerve

can also be seen as in hamstring graft ⁽⁴⁹⁾. This problem is reduced through a two incision subcutaneous technique. Osteoarthritis can also occur post-surgery but it is not yet clear if the BTB grafts surgery increases the risk of early degenerative bone disease or if other factors influence this side effect. Such influencing factors may include damage to the articular cartilage at the time of injury, previous knee surgery and insufficient activity after surgery ⁽⁵²⁾.

Some rare but serious complications like patellar fractures ⁽⁵³⁾ or patellar tendon ruptures after removal of the central third of the patella ⁽⁵⁴⁾ can also occur. The surgeon can minimize the risk of such complications by assuring that a bone plug of no more than half the length of the patella is taken, making cuts angled and no more than 10mm deep, avoiding cross-hatching at the corners and creating a trapezoidal cut rather than triangular or square one.

It is recommended to avoid this surgery with certain diseases such as patellar tendinopathy and Osgood Schlatter's disease, even though adequate studies providing sufficient evidence for these recommendation have not yet been conducted.

4.3. Hamstrings tendon:

Semitendonosis is one of the three muscles that compose the hamstring muscles (figure 9). It is a long, thin muscle approximately 25 cm long and 3 to 4 mm wide. It is harvested using a small incision 2cm from the internal side of the tibia by using a muscle stripper (figure 9).

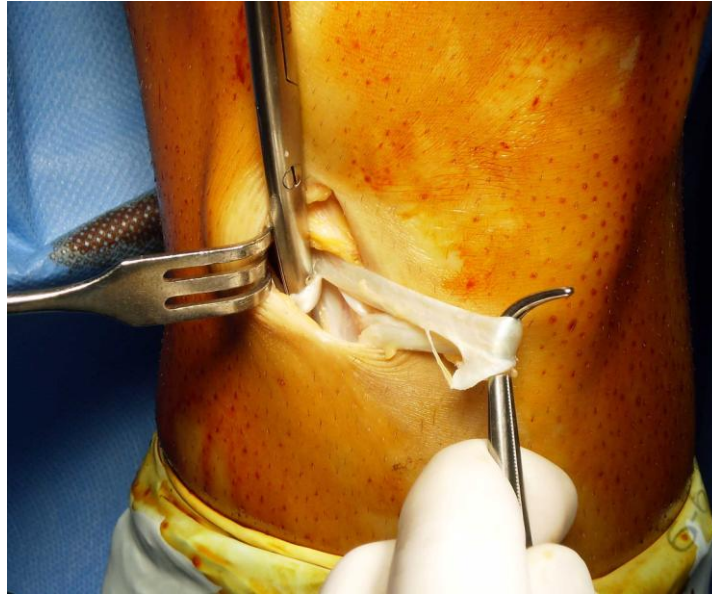

Figure 9: Intraoperative photo of semitendinosus muscle tendon harvesting through small vertical incision on medial side of knee placed above pes anserinus.

The tendons can be converted to grafts that remain intact at their anatomical insertion point on the tibia or grafts that are formed through complete detachment from the tibia during harvest. A double, triple or quadruple stranded graft is formed to obtain a diameter of 7-10 mm. At the extremities of the graft two small strips of Tape Locking Screw (TLS) made of polyethylene terephthalate stranded in 7mm of diameter are passed at the two loop extremities. In order to ensure the capacity to function in place of the ACL, a traction table is used to place the newly formed graft under 500N of tension. Then graft is then wrapped in a moistened sponge until the insertion sites are prepared. Two small incisions are made on both sides of the patellar ligament for camera and instruments insertion needed for the ligamentoplasty. Grafts formed from the hamstring

tendon are fixed in place using the same procedure as that described in the previous chapters.

One advantage of the hamstring graft compared to BTB autografts is the cosmetic aspect of the knee post-surgery. Hamstring grafts require smaller incisions at the distal anatomical insertion points that are used for both graft harvest and tibial tunnel drilling, and as a result, this procedure is associated with less post-operative scarring. It appears an additional benefit of the hamstring grafts that is a decreased anterior knee pain as compared to BTB grafts, as demonstrated by several studies ^(38,55,56).

The past idea that hamstring ligament wasn't stable enough due to the fact that it can stretch has been rejected by the study from L. Pinczewski et al.⁽⁵⁷⁾. They showed that the material does not inherently provide laxity to the graft. Any laxity in the graft is due to improper placement and fixation techniques. When fixation is standardized, there is no significant difference between the laxity of hamstring and other types of grafts. Also important to note is that rates of rupture for BTB and hamstring grafts are not significantly different when fixation is standardized ^(58,59,60,61). The risk of hamstring graft rupture is equivalent to that for the native contralateral ACL. Although the effective outcome for the patient is the same regardless of graft choice, surgeons may shy away from hamstring grafts over concern that any re-rupture would be related to surgical technique.

A prospective study that lasted for 15 years found better outcomes with hamstring grafts as compared to BTB graft in terms of osteoarthritis, motion loss, single leg hop and kneeling pain, but no difference in International Knee Documentation Committee (IKDC) scores ⁽⁶²⁾.

A disadvantage of hamstring grafts is the longer healing time required for soft-tissue to bone fixation. Through studies conducted on dogs, the ACL graft-bone healing process is understood to rely on the development of a fibrovascular scar tissue layer adhering the tendon to the bone at the graft-tunnel interface. This process requires approximately 12 weeks in order for the graft to fully incorporate and heal but leads to a reduced lifetime failure rate when compared to BTB autografts ⁽⁶³⁾.

A few studies have noted a higher propensity of tunnel widening with hamstring grafts but the specific factor the soft tissue graft ^(64, 65,66) or the suspensory fixation ⁽⁶⁷⁾ is not clear. Other factors play a role in the bone tunnel widening such as graft micromotion, stress shielding, drill-related necrosis, accelerated rehabilitation, bone resorption and remodeling, graft swelling, synovial fluid propagation and increased synovial cytokine production ^(68,69). One study on hamstring graft showed that although there is a reduction in knee flexion strength as compared to the contralateral extremity, this has no effect on IKDC scores ⁽⁷⁰⁾. When comparing hamstring grafts to allograft, there is no significant difference in of strength extension ⁽⁷¹⁾. An injury to the superficial branch of the saphenous nerve ⁽⁴⁹⁾ can occur causing a local numbness of the leg as in BTB graft operation. The increased ligamentous laxity, as in BTB graft operation, is a contraindication to ACL reconstruction surgery.

In some hamstring grafts studies the authors showed a lower return to pre-injury activity levels ^(38,72,73) and therefore this type of graft is preferably used for lower-demand patients, recreational athletes, younger patients with open growth plates, and patients who are concerned about knee appearance. It is a better option in patients at risk of anterior knee pain or those with professional demands that require extensive kneeling.

4.4. Quadriceps tendon:

The central quadriceps tendon, proximal to the patella, is thicker and wider than the patellar ligament. The advantage of quadriceps tendon grafts is the ability to a large cross-sectional area of tissue with high biomechanical strength. It can be harvested with a bone plug from the superior pole of the patella that is dense and thus, bone-to-bone healing can occur in one of the tunnels. The length of the graft can be adjusted more easily than a BTB autograft, avoiding concerns and risks of graft-tunnel mismatch ^(74,75). The quadriceps tendon graft is also used for repairs in adolescents with open growth plates as it does not violate the tibial tubercle apophysis. In a recent prospective randomized study ⁽⁷⁶⁾, the quadriceps tendon graft was shown to result in less kneeling pain compared to the use of BTB graft.

The harvesting of the quadriceps tendon graft is more problematic than for other donor sites due to its close adherence to the suprapatellar pouch ⁽⁷⁵⁾. Other potential disadvantages concern the cosmetic results and interference with the quadriceps extensor mechanisms. This graft, however, has not been studied as extensively as the patellar tendon and hamstring grafts making additional prospective studies essential to understanding the full spectrum of post-surgery outcomes.

The procedure for harvesting the quadriceps tendon graft begins with either a 6 to 8 cm vertical incision above the patella or one small horizontal incision, just above the patella and an identical incision 8 cm above the first. Next a bone plug 10 mm wide, 20 mm long and 6 to 8 mm thick is harvested from the proximal patella. This is followed by

harvesting of the superficial layer of the tendon. The remainder of the procedure is the same as the tendon grafts replacements described in previous chapters.

4.5. Fascia lata graft:

The fascia lata is a fibrous connective tissue that composes the deep fascia of the thigh. The Macintosh technique modified by Jaeger is used to harvest fascia lata and to reconstruct the rupture of the ACL ⁽⁷⁷⁾. Only the area where the graft is harvested is opened to the outside. Patient is placed in a decubitus position with his knee flexed at 70°. As with other procedures, an arthroscopic exam of the injured knee is made to evacuate any hemarthrosis, to examine the meniscus and to look for any additional damages or disinsertions.

A 10 to 15 cm longitudinal cutaneous incision is made on the external side of the thigh and knee. The fascia lata graft should be 4 cm of diameter at its proximal end and 1 cm at its distal insertion on the Gerdy tubercle, which remains intact. The donor materials are stranded in order to obtain a 7-8 mm diameter graft.

The fascia lata graft is partially extra-articular and partially intra-articular, the extra-articular penetration point of the graft through the femur is 1cm behind the LCL and it exits at the ACL native insertion point on the femoral side of the knee joint. Then the graft is placed into the tibial tunnel that has been created at the ACL native insertion point on the tibial side. The graft is usually fixed with interference screw and pinned on the tibial internal tuberosity and interference screw is inserted on the femoral side (figure 10).

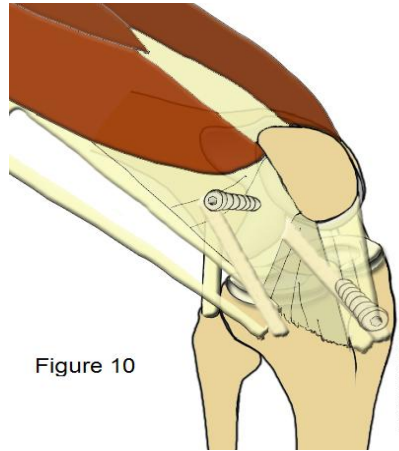


Figure 10

Figure 10: Schematic representation of graft insertion through the tunnels and fixation by screw on the tibial side and femoral side ⁽⁷⁸⁾.

5. ALLOGRAFT TENDON

The primary advantage of allografts is the absence of morbidity at the donor site. Low dose irradiation of the allograft decreases the risk of transmission of infectious disease without compromising the graft's biomechanical properties. Donor screening and testing procedures have been developed to further avoid disease transmission to the recipient. Once incorporated into the recipient site bone tunnels, the allograft must undergo the same process of avascular necrosis, creeping substitution and ligamentization as autografts. Jackson et al. found that donor DNA within the allograft material was replaced completely by host DNA within 4 weeks ⁽⁷⁹⁾.

One advantage of allografts is the wide range of graft sources that include the tibialis, achilles, quadriceps, patellar, hamstring, fascia lata and anterior and posterior tibialis tendons. There is also a decreased muscle weakness, kneeling pain and risk of patellar fracture post-surgery compared to other graft types. One of important indications is multi-ligaments knee injury. It is necessary to restore several ligaments at the same

time, and all the ligaments cannot be easily harvested from the patient. This makes allografts a frequent choice for revision ACL surgery and multi-ligament injured knee as the amount of collagen needed is higher than what can be obtained from autograft sources.

A major disadvantage of the allograft is the longer incorporation time compared to autograft ⁽⁸⁰⁾. No direct correlation between graft incorporation and clinical performance has been significantly shown, but allograft tissue has demonstrated inferior performance in the younger patient population with a 2.3 times greater risk of graft rupture with allograft reconstructions for each 10-year decrease in age. The highest risks of allograft rupture have been in patients who had surgery between age 10 and 19 years old ⁽⁸¹⁾.

For the above mentioned reasons, the use of allograft will be for lower-demand patients, older patients who prefer an easier rehabilitation and patients with knees that have multiple injured ligaments.

6. SYNTHETIC LIGAMENTS

The use of synthetic carbon fiber grafts was explored during the late 20th century but high rates of early ruptures confined this technology to initial stage animal experiments. Other attempts at developing synthetic grafts have also been made using materials such as polypropylene, Dacron, Kennedy Ligament Augmentation Device, Gore-Tex and the Ligament Advanced Reinforcement System (LARS) artificial ligaments were also developed. Each was developed for use as either a stand-alone prosthesis or as an augmentation of biological ACL grafts. Nevertheless, every material presented

serious drawbacks that included cross-infections, immunological responses, ruptures and debris dispersion. These problems were leading to synovitis, chronic effusions, recurrent instability and knee osteoarthritis ⁽⁸²⁾. There is as of yet no ideal synthetic prosthesis mimicking natural human tissue and research to find an ideal substitute for the native ACL is ongoing.

7. COMPUTER ASSISTED LIGAMENTOPLASTY

Computer assisted ligamentoplasty was pioneered during the 1990s to prevent the failure of ACL replacement caused by improper positioning of knee tunnels. With arthroscopic surgery proper positioning of tunnels is surgeon- and specific material-dependent.

Computer-assisted navigation systems (CANSs) have been developed to further improve the accuracy of tunnel positioning by the surgeon. They allow proper alignment with respect to knee anatomy and the isometry of the ligament which prevents tearing of the graft during flexion and extension. The exact anatomic points of the knee can be formed by 3D reconstruction, by tomodensitometry or by the Bone Morphing method where captors are fixed on the tibia and femur external side. Passive flexion and extension of the knee and anatomical knee movement allows calibration of the binocular infrared camera used for the procedure. The computer recognizes both sides of the knee independently and is able to precisely guide the surgeon during the arthroscopic operation to the native insertion of the ACL on the tibial and femoral position. All different types of grafts can be used. More studies should be conducted to confirm the decrease in operating time ⁽⁸³⁾, effectiveness of precise graft insertion and the better graft isometry

estimation. Currently this assistant technique is not yet cost efficient from a hospital's perspective.

8. DISCUSSION

In the past 40 years, better understanding knee anatomy and improved surgical techniques have created great changes in the surgical repair of the anterior cruciate ligament. As a result, post-operative outcomes such as efficient knee function and stability continue to improve. The most popular autografts used for ACL reconstruction are the BTB and hamstring grafts. The strength and bio-physiology characteristics of these two grafts are approximate those of the native ACL. No specific recommendations have been developed for choosing one of these two main operation techniques over the other as each have their own advantages and disadvantages. The choice of graft depends primarily on the surgeon's preference. Surgeons performing reconstructions with one type of graft are more likely to understand the nuances and subtleties associated with a particular graft. On the other hand, those who use different techniques can become comfortable enough to alternate between graft types. As a general recommendation, surgeons who perform only a small number of procedures should use only one graft type and refer patients requiring other grafts to their colleagues ⁽⁸⁴⁾.

The BTB technique has the advantage of having a better fixation in the knee drilled tunnels with the consequence of a lower knee laxity and instability. Its main disadvantage is an increased risk of persistent anterior knee pain post-surgery and rare but dramatic complications of patellar fracture. It stays, however, the major graft for professional athletes and high demanding activities patient.

The hamstring graft has a better cosmetic outcome and the post-surgery complications are lower. The main disadvantage is longer healing time for soft-tissue to bone fixation. It is mainly used in patients with no intense sports activity. The more recent use of allograft shows that it is mainly used for revision surgery, lower-demand patients, older patients who prefer an easier rehabilitation and patients with knees that have multiple ligament injuries. Quadriceps graft are also used but additional clinical studies are required to fully assess the outcomes. For the time being, quadriceps remain the graft of choice only in young patient due to its lack of interference with the growth plate since it doesn't disturb any growth plate. The other ongoing advantages and disadvantages are to be confirmed. One of the techniques that seem to be the next gold standard for ACL replacement surgery is the Lemaire technique and it should be overseen in the next years to see its outcome in the longer terms.

As it stands, the quality of surgical outcomes from ACL repair depend primarily on the position of the graft and the fixation.

9. CONCLUSION

The purpose of this graduation paper was to examine various types of surgeries used for the ACL replacements in patients and to explain the procedures in detail in order to compare their efficiency. The studies conducted by the experts helped us define the advantages and the disadvantages of the above mentioned procedures and they have shown their both positive and negative points. It is now well understood that the position and the type of the graft are the key for a successful ligamentoplasty. Computer guidance has also begun to become a great asset during ACL surgery and appears to

reduce the surgeon-dependent surgery outcome. The autograft with Bone to Bone and hamstring graft remain the two most used grafts in the world. Up to this day, no international recommendations have been made to suggest choosing one over the other surgery. Quadriceps and fascia lata grafts have more recently become well accepted graft sources but are still under evaluation for their long term advantages and disadvantages. The use of allograft should be in lower-demand patients and avoided in the younger population. Surgeons should be aware of the evidence behind the use of each graft and thus the choice should be based on the surgeon's experience and specific requirements of a given patient. It is reasonable to assume that the rapid developments of new technologies will also result in new ways of treating this type of injuries.

10. ACKNOWLEDGEMENTS

First and foremost, I would like to thank my mentor, Assistant Professor Tomislav Smoljanovic, MD, PhD (Department of Orthopaedic, University Hospital Center Zagreb, , Croatia) for letting me chose this topic as well as for his guidance and support along the way. His comments and remarks throughout the learning process of this thesis helped me reach my goal with success.

At last, I would like to thank my parents for their endless love and unconditional support, both financially and emotionally, throughout my University studies and also to Petra Hesky and my friends who helped me in this last year as a medical student at the University of Zagreb School of Medicine.

11. REFERENCES

1. Claes S, Vereecke E, Maes M, Victor J, Verdonk P, Bellemans J. Anatomy of the anterolateral ligament of the knee. *J. Anat.* 2013; 223:321-328.
2. Pinczewski LA, Lyman J, Salmon LJ, et al. A ten-year comparison of anterior cruciate ligament reconstruction with hamstring tendon and patellar tendon autograft: A controlled, prospective trial. *Am. J. Sports Med.* 2007; 35:564–574.
3. Markolf KL, Mensch JS, Amstutz HC. Stiffness and laxity of the knee: The contributions of the supporting structures. A quantitative in vitro study. *J. Bone Joint Surg. Am.* 1976; 58:583-593.
4. Butler DL, Noyes FR, Grood ES. Ligamentous restraints to anterior-posterior drawer in the human knee. *J. Bone Joint Surg. Am.* 1980; 62:259-270.
5. Silbey MB, Fu. FH. Knee injuries: Mechanisms, prevention, treatment, 2nd Edition ed., Fu FH, David A, Stone MD. *Sports Injuries: Mechanisms, Prevention and Treatment*, Philadelphia, Lippincott W.W. 2001; p.1102-p.1134.
6. Noyes FR, Butler DL, Grood ES, Zernicke RF, Hefzy MS. Biomechanical analysis of human ligament grafts used in knee ligament repairs and reconstructions. *J. Bone Joint Surg. Am.* 1984; 66:344-352.
7. Woo SL-Y, Hollis JM, Adams DJ, Lyon RM, Takai S. Tensile properties of the human femur-anterior cruciate ligament- tibia complex: The effects of specimen age and orientation. *Am. J. Sports Med.* 1991; 19:217-225.
8. Frank CB, Jackson DW. The science of reconstruction of the anterior cruciate ligament. *J. Bone Joint Surg. Am.* 1997; 79:1556-1576.

-
- 9.** Butler DL, Grood ES, Noyes FR, Sodd AN. On the interpretation of our anterior cruciate ligament data. Clin. Orthop. 1985; 196:26-34.
 - 10.** Markolf KL, Burchfield DM, Shapiro MM, Cha CW, Finerman GAM, Slauterbeck JL. Biomechanical consequences of replacement of the anterior cruciate ligament with a patellar ligament allograft. Part II: Forces in the graft compared with forces in the intact ligament. J. Bone Joint Surg. Am. 1996; 78:1728-1734.
 - 11.** Hirshman HP, Daniel DM, Miyasaka K. The fate of the unoperated knee ligament injuries. In knee ligaments: structure, function, injury, and repair. Edited by Daniel DM, Akeson WH, O'Connor JJ. New York, Raven Press. 1990; p.481-503.
 - 12.** Miyasaka KC, Daniel DM, Stone ML. The incidence of knee ligament injuries in the general population. Am. J. Knee Surg. 1991; 4:43-48.
 - 13.** Brown CH, Carson EW. Revision anterior cruciate ligament surgery. Clin. Sports Med. 1999; 18:109-171.
 - 14.** Griffin LY. Noncontact anterior cruciate ligament injuries: Risk factors and prevention strategies. J. Am. Acad. Orthop. Surg. 2000; 8:141-150.
 - 15.** Shelbourne KD, Nitz PA. The O'Donoghue triad revisited. Combined knee injuries involving anterior cruciate and medial collateral ligament tears. Am. J. Sports Med. 1991; 19:474-477.
 - 16.** Doan. Schematic representation of a specific knee injury. Orthopédie Traumatologie. 7th Edition Vernazobres-Grego. ed., Edgard-Rosa G, Aharoni C. 2012; p.88

-
- 17.** Kim SJ, Kim HK. Reliability of the anterior drawer test, the pivot shift test, and the Lachman test. *Clin. Orthop. Relat. Res.* 1995; 317:237-242.
- 18.** Galway HR, MacIntosh DL. The lateral pivot shift: a symptom and sign of anterior cruciate ligament insufficiency. *Clin. Orthop. Relat. Res.* 1980; (147):45-50.
- 19.** Church S, Keating JF. Reconstruction of the anterior cruciate ligament: timing of surgery and the incidence of meniscal tears and degenerative change. *J. Bone Joint Surg. Br.* 2005; 87:1639-1642.
- 20.** Robson MAW. Ruptured cruciate ligaments and their repair by operation. *Ann. Surg.* 1903; 37:716-718.
- 21.** Lange F. Über die Sehnenplastik. *Verh. Dtsch. Orthop. Ges.* 1903; 2:10-12.
- 22.** Hey Groes, E.W. Operation for the repair of cruciate ligament. *Lancet.* 1917; 2:674-675.
- 23.** Dandy DJ, Flanagan JP, Steemerey V. Arthroscopy and the management of the ruptured anterior cruciate ligament. *Clin. Orthop.* 1982; 167:43-49.
- 24.** Brucker P, Lorenz S, Imhoff A. Aperture fixation in arthroscopic anterior cruciate ligament double-bundle reconstruction. *Arthroscopy.* 2006; 22:1251-1256.
- 25.** Tiamklang T, Sumanont S, Foocharoen T, Laopaiboon M. Double-bundle versus single-bundle reconstruction for anterior cruciate ligament rupture in adults. *Cochrane Database Syst. Rev.* 2012; 11:CD008413.

-
- 26.** Chassaing V, Lemoine J, Ehkirch FP. Schematic view of the anterior cruciate ligament reconstruction using the double-bundle reconstruction.
<http://www.genou.com/didt/didt.htm> (accessed June 2014).
- 27.** Zaffagnini S, Klos TV, Bignozzi S. Computer-assisted anterior cruciate ligament reconstruction: an evidence-based approach of the first 15 years. *Arthroscopy*. 2010; 26:546-554.
- 28.** Sachs RA, Daniel DM, Stone ML, Garfein RF. Patellofemoral problems after anterior cruciate ligament reconstruction. *Am. J. Sports Med*. 1989; 17:760-765.
- 29.** McAdams TR, Biswal S, Stevens KJ, Beaulieu CF, Mandelbaum BR. Tibial aperture bone disruption after retrograde versus antegrade tibial tunnel drilling: a cadaveric study. *Knee Surg. Sports Traumatol Arthrosc*. 2008; 16:818-822.
- 30.** Yao J, Wen CY, Zhang M, Cheung JT, Yan C, Chiu KY, Lu WW, Fan Y. Effect of tibial drill-guide angle on the mechanical environment at bone tunnel aperture after anatomic single-bundle anterior cruciate ligament reconstruction. *Int. Orthop*. 2014; 38:973-981.
- 31.** Kousa P, Jarvinen TL, Vihavainen M, Kannus P, Jarvinen M. The fixation strength of six hamstring tendon graft fixation devices in anterior cruciate ligament reconstruction: Part II. Tibial site. *Am. J. Sports Med*. 2003; 31:182-188.
- 32.** Ishibashi Y, Rudy TW, Livesay GA and al. The effect of anterior cruciate ligament graft fixation site at the tibia on knee stability: evaluation using a robotic system. *Arthroscopy*. 1997; 13:177-182.

-
- 33.** Chassaing V., Lemoine J., Ehkirch FP. Schematic view of the knee showing clips and interference screws on the tibial and femoral part.
<http://www.genou.com/didt/didt.htm> (accessed June 2014).
- 34.** Chassaing V., Lemoine J., Ehkirch FP. Schematic representation of TransFix femoral fixation system and tibial interference screw.
<http://www.genou.com/didt/didt.htm> (accessed 15 June 2014).
- 35.** Caborn DN, Urban WP Jr, Johnson DL, Nyland J, Pienkowski D. Biomechanical comparison between BioScrew and titanium alloy interference screws for bone-patellar tendon-bone graft fixation in anterior cruciate ligament reconstruction. *Arthroscopy*. 1997; 13:229-232.
- 36.** Butler JC, Branch TP, Hutton WC. Optimal graft fixation: the effect of gap size and screw size on bone plug fixation in ACL reconstruction. *Arthroscopy*. 1994; 10:524-529.
- 37.** Lemos MJ, Jackson DW, Lee TQ, Simon TM. Assessment of initial fixation of endoscopic interference femoral screws with divergent and parallel placement. *Arthroscopy*. 1995; 11:37-41.
- 38.** Aune AK, Holm I, Risberg MA, Jensen HK, Steen H. Four-strand hamstring tendon autograft compared with patellar tendon-bone autograft for anterior cruciate ligament reconstruction: A randomized study with two-year followup. *Am. J. Sports Med*. 2001; 29:722-728.
- 39.** Benedetto KP, Fellingner M, Lim TE, Passler JM, Schoen JL, Willems WJ. A new bioabsorbable interference screw: preliminary results of a prospective, multicenter, randomized clinical trial. *Arthroscopy*. 2000; 16:41-48.

-
- 40.** Kousa P, Jarvinen TL, Vihavainen M, Kannus P, Jarvinen M. The fixation strength of six hamstring tendon graft fixation devices in anterior cruciate ligament reconstruction: Part I. Femoral site. *Am. J. Sports Med.* 2003; 31:174-181.
- 41.** Falconiero RP, DiStefano VJ, Cook TM. Revascularization and ligamentization of autogenous anterior cruciate ligament grafts in humans. *Arthroscopy* 1998; 14:197-205.
- 42.** Beynnon BD, Johnson RJ. Anterior cruciate ligament injury rehabilitation in athletes: Biomechanical considerations. *Sports Med.* 1996; 22:54-64.
- 43.** Claes S, Verdonk P, Forsyth R, Bellemans J. The "ligamentization" process in anterior cruciate ligament reconstruction: what happens to the human graft? A systematic review of the literature. *Am. J. Sports Med.* 2011; 39:2476-2483.
- 44.** Rodeo SA, Arnoczky SP, Torzilli PA, Hidaka C, Warren RF. Tendon-healing in a bone tunnel: A biomechanical and histological study in the dog. *J. Bone Joint Surg. Am.* 1993; 75:1795-1803.
- 45.** Jackson DW, Grood ES, Goldstein JD, et al. A comparison of patellar tendon autograft and allograft used for anterior cruciate ligament reconstruction in the goat model. *Am. J. Sports Med.* 1993; 21:176-185.
- 46.** Shelbourne KD, Patel DV. Timing of surgery in anterior cruciate ligament-injured knees. *Knee Surg. Sports Traumatol Arthrosc.* 1995; 3:148-156.
- 47.** Shelbourne KD, Nitz P. Accelerated rehabilitation after anterior cruciate ligament reconstruction. *Am. J. Sports Med.* 1990; 18:292-299.

-
- 48.** Chassaing V., Lemoine J., Ehkirch F.P. Schematic representation of Kenneth Jones procedure showing the harvesting of bone plugs and patellar graft.
<http://www.genou.com/didt/kj.htm> (accessed on June 2014).
- 49.** Miller SL, Gladstone JN. Graft selection in anterior cruciate ligament reconstruction. *Orthop. Clin. NorthAm.* 2002; 33:675-683.
- 50.** Mohtadi NG, Chan DS, Dainty KN, Whelan DB. Patellar tendon versus hamstring tendon autograft for anterior cruciate ligament rupture in adults. *Cochrane Database Syst Rev.* 2011; (9):CD005960.
- 51.** Shelbourne KD, Nitz P. Accelerated rehabilitation after anterior cruciate ligament reconstruction. *Am. J. Sports Med.* 1990; 18:292-299.
- 52.** Murray JR, Lindh AM, Hogan NA, Trezies AJ et al. Does anterior cruciate ligament reconstruction lead to degenerative disease? Thirteen-year results after bone-patellar tendon-bone autograft. *Am. J. Sports Med.* 2012; 40:404-413.
- 53.** Viola R, Vianello R. Three cases of patella fracture in 1,320 anterior cruciate ligament reconstructions with bone-patellar tendon-bone autograft. *Arthroscopy.* 1999; 15:93-97.
- 54.** Marumoto JM, Mitsunaga MM, Richardson AB, Medoff RJ, Mayfield GW. Late patellar tendon ruptures after removal of the central third for anterior cruciate ligament reconstruction: A report of two cases. *Am. J. Sports Med.* 1996; 24:698-701.
- 55.** Corry IS, Webb JM, Clingeleffer AJ, et al. Arthroscopic reconstruction of the anterior cruciate ligament. A comparison of patellar tendon autograft and four-strand hamstring tendon autograft. *Am. J. Sports Med.* 1999; 27:444-454.

-
- 56.** Aglietti P, Buzzi R, D'Andria S, Zaccherotti G. Patellofemoral problems after intraarticular anterior cruciate ligament reconstruction. *Clin. Orthop.* 1993; 288:195-204.
- 57.** Pinczewski L, Roe J, Salmon L. Why autologous hamstring tendon reconstruction should now be considered the gold standard for anterior cruciate ligament reconstruction in athletes. *Br. J. Sports Med.* 2009; 43; 325-327.
- 58.** Prodromos CC, Joyce BT, Shi K, Keller BL. A meta-analysis of stability after anterior cruciate ligament reconstruction as a function of hamstring versus patellar tendon graft and fixation type. *Arthroscopy.* 2005; 21:1202-1209.
- 59.** Goldblatt J, Fitzsimmons S, Balk E, et al. Reconstruction of the anterior cruciate ligament: meta-analysis of patellar tendon versus hamstring tendon autograft. *Arthroscopy.* 2005; 21:791-803.
- 60.** Yunes M, Richmond J, Engels E, et al. Patellar versus hamstring tendons in anterior cruciate ligament reconstruction: a meta-analysis. *Arthroscopy.* 2001; 17:248-257.
- 61.** Spindler KP, Kuhn JE, Freedman KB, et al. Anterior cruciate ligament reconstruction autograft choice: bone-tendon-bone versus hamstring: does it really matter? A systematic review. *Am. J. Sports Med.* 2004; 32:1986-1995.
- 62.** Leys T, Salmon L, Waller A, Linklater J, Pinczewski L. Clinical results and risk factors for reinjury 15 years after anterior cruciate ligament reconstruction: a prospective study of hamstring and patellar tendon grafts. *Am. J. Sports Med.* 2012; 40:595-605.
- 63.** Tomita F, Yasuda K, Mikami S, Sakai T, Yamazaki S, Tohyama H. Comparisons of intraosseous graft healing between the doubled flexor tendon graft and the bone-patellar

tendon bone graft in anterior cruciate ligament reconstruction. *Arthroscopy*. 2001; 17:461-476.

64. L'Insalata JC, Klatt B, Fu FH, Harner CD. Tunnel expansion following anterior cruciate ligament reconstruction: a comparison of hamstring and patellar tendon autografts. *Knee Surg. Sports Traumatol Arthrosc.* 1997; 5:234-238.

65. Webster KE, Feller JA, Hameister KA. Bone tunnel enlargement following anterior cruciate ligament reconstruction: a randomised comparison of hamstring and patellar tendon grafts with 2- year follow-up. *Knee Surg. Sports Traumatol Arthrosc.* 2001; 9:86-91.

66. Hersekli MA, Akpinar S, Ozalay M, et al. Tunnel enlargement after arthroscopic anterior cruciate ligament reconstruction: comparison of bone-patellar tendon-bone and hamstring autografts. *Adv. Ther.* 2004; 21:123-131.

67. Baumfeld JA, Diduch DR, Rubino LJ, et al. Tunnel widening following anterior cruciate ligament reconstruction using hamstring autograft: a comparison between double cross-pin and suspensory graft fixation. *Knee Surg. Sports Traumatol Arthrosc.* 2008; 16:1108-1113.

68. Fahey M, Indelicato PA. Bone tunnel enlargement after anterior cruciate ligament replacement. *Am. J. Sports Med.* 1994; 22:410-414.

69. Zysk SP, Fraunberger P, Veihelmann A, et al. Tunnel enlargement and changes in synovial fluid cytokine profile following anterior cruciate ligament reconstruction with

patellar tendon and hamstring tendon autografts. *Knee Surg. Sports Traumatol Arthrosc.* 2004; 12:98-103.

70. Landes S, Nyland J, Elmlinger B, Tillett E, Caborn D. Knee flexor strength after ACL reconstruction: comparison between hamstring autograft, tibialis anterior allograft, and non-injured controls. *Knee Surg. Sports Traumatol Arthrosc.* 2010; 18:317-324.

71. Kim JG, Yang SJ, Lee YS, Shim JC, Ra HJ, Choi JY. The effects of hamstring harvesting on outcomes in anterior cruciate ligament-reconstructed patients: a comparative study between hamstring-harvested and -unharvested patients. *Arthroscopy.* 2011; 27:1226-1234.

72. Colombet P, Allard M, Bousquet V, de Lavigne C, Flurin PH, Lachaud C. Anterior cruciate ligament reconstruction using four-strand semitendinosus and gracilis tendon grafts and metal interference screw fixation. *Arthroscopy.* 2002; 18:232-237.

73. Jansson KA, Linko E, Sandelin J, Harilainen A. A prospective randomized study of patellar versus hamstring tendon autografts for anterior cruciate ligament reconstruction. *Am. J. Sports Med.* 2003; 31:12-18.

74. Theut PC, Fulkerson JP, Armour EF, Joseph M. Anterior cruciate ligament reconstruction utilizing central quadriceps free tendon. *Orthop. Clin. North. Am.* 2003; 34:31-39.

75. Fulkerson JP, Langeland R. An alternative cruciate reconstruction graft: The central quadriceps tendon. *Arthroscopy* 1995; 11:252-254.

76. Lund B, Nielsen T, Faunø P, Christiansen SE, Lind M. Is quadriceps tendon a better graft choice than patellar tendon? A prospective randomized study. *Arthroscopy.* 2014; 30:593-598.

-
- 77.** Khiami F, Wajsfisz A, Meyer A, Rolland E, Catonné Y, Soriali E. Anterior cruciate ligament reconstruction with fascia lata using a minimally invasive arthroscopic harvesting technique. *Orthop. Traumatol Surg. Res.* 2013; 99:99-105.
- 78.** Lefevre N, Bohu Y, Herman S. Schematic representation of graft insertion through the tunnels and fixation by screw on the tibial side and femoral side.
http://chirurgiedusport.com/Traitements-GENOU-Ligament-Ligamentoplastie_du_LCA___les_techniques_actuelles___DIDT_KJ_DT4_TLS_Macintosh_au_Fascia_Lata__tendon_quadricipital__double_faisceau__Lemaire__rupture_partiell-f-4-c-2336-sc-16-a-760193.html (accessed on June 2014).
- 79.** Jackson DW, Simon TM, Kurzweil PR, Rosen MA. Survival of cells after intra-articular transplantation of fresh allografts of the patellar and anterior cruciate ligaments. DNA-probe analysis in a goat model. *J. Bone Joint Surg. Am.* 1992; 74:112-118.
- 80.** Gulotta LV, Rodeo SA.: Biology of autograft and allograft healing in anterior cruciate ligament reconstruction. *Clin. Sports Med.* 2007; 26:509-524.
- 81.** Kaeding CC, Aros B, Pedroza A, et al. Allograft versus autograft anterior cruciate ligament reconstruction: predictors of failure from a Moon prospective longitudinal cohort. *Sports Health.* 2011; 3:73-81.
- 82.** Savarese A, Lunghi E, Budassi P, Agosti A. Remarks on the complications following ACL reconstruction using synthetic ligaments. *J. Orthop. Traumatol.* 1993; 19:79-86.

83. Margier J, Tchouda SD, Banihachemi JJ, Bosson JL, Plaweski S. Computer-assisted navigation in ACL reconstruction is attractive but not yet cost efficient. *Knee Surg. Sports Traumatol Arthrosc.* 2014 Jan 21. [Epub ahead of print].

84. Feller JA. Graft choices for anterior cruciate ligament reconstruction.
<http://www.isakos.com/assets/innovations/feller.graft%20selection%20for%20acl%20reconstruction.pdf>

12. BIOGRAPHY

François POURCI

Born : August 12, 1987 in Paris (XIII district)

Address : Vlaska 86, 10000 Zagreb, Croatia

Citizenship: French

Education :

2013: Currently in 6th year at the University of Zagreb School of Medicine (Croatia)

2008 to 2011: completed 2nd to 5th year studies at the University of Zagreb School of Medicine

2007, 2006: 1st year in Medicine at Paris XI University (France)

2005: High School Diploma (in French education system: General Science-Biology option)

Experiences:

Mai, Juin 2013 : Clinical Rotation at hôpital Notre Dame (Montréal, Canada), one month in the Endocrinology department (Dr Jean-Louis Chiasson) and one month in the Pulmonology department (Dr Charles Poirier)

May-June 2012: Free mover exchange, one month in the NeuroPediatric department and one month in Pediatric Emergency at Robert-Debré Hospital (Paris, France)

July 2011 : One month stage at Pitié Salpêtrière in Internal Médecine (Paris, France)

August 2010 : One month stage at Hôpital Européen George Pompidou (HEGP) in Intensive Care Unit of Pneumology (Paris, France)

January 2008 : Three-week stage at Hôpital Bicêtre, in the Cardiology Department
2002: « Practical work » in 9th grade of high school in Tenon Hospital (Paris, France) concerning Digestive Endoscopy