

Reanimation surgery for facial nerve paralysis

Kelc, Nika

Master's thesis / Diplomski rad

2020

Degree Grantor / Ustanova koja je dodijelila akademski / stručni stupanj: **University of Zagreb, School of Medicine / Sveučilište u Zagrebu, Medicinski fakultet**

Permanent link / Trajna poveznica: <https://um.nsk.hr/um:nbn:hr:105:292523>

Rights / Prava: [In copyright](#)/[Zaštićeno autorskim pravom.](#)

Download date / Datum preuzimanja: **2025-01-22**



Repository / Repozitorij:

[Dr Med - University of Zagreb School of Medicine Digital Repository](#)



**UNIVERSITY OF ZAGREB
SCHOOL OF MEDICINE**

Nika Kelc

**Reanimation surgery for facial nerve
paralysis**

GRADUATE THESIS



Zagreb, 2020

This graduate thesis was made at Department of Plastic Surgery mentored by Prof. dr. Davor Mijatović and was submitted for evaluation 2019/2020.

ABBREVIATIONS:

ALT- Anterolateral thigh

CFNG- Cross-facial nerve graft

CULLP- Congenital unilateral lower lip palsy

EBD- Extensor digitorum brevis

eFACE- Electronic, clinician-graded facial function scale

LABC- Lateral antebrachial cutaneous

LD- Latissimus dorsi

MABC- medial antebrachial cutaneous

MIT3- Minimally invasive temporalis tendon transfer

OSCAR- Objective Scaling of Facial Nerve Function Based on Area Analysis

PM- Pectoralis minor

SA- The serratus anterior

T3- Temporalis tendon transfer

Table of Contents

<i>Summary</i>	<i>i</i>
<i>Sažetak</i>	<i>ii</i>
1.INTRODUCTION	1
2.REANIMATION SURGERY FOR FACIAL NERVE PARALYSIS	4
2.1.STATIC PROCEDURES	5
2.1.1. TARSORRHAPHY	5
2.1.2. CANTHOPEXY	6
2.1.3. LOWER EYELID	6
2.1.4. EYELID WEIGHTS.....	7
2.1.5. PALPEBRAL SPRING	8
2.1.6. BROW LIFT.....	8
2.1.7. FORHEAD SKIN EXCISION	8
2.1.8. STATIC SLINGS AND GRAFTS	9
2.2 DYNAMIC PROCEDURES	10
2.2.1 NEURORRHAPHY	10
2.2.1.1 DIRECT NERVE REPAIR.....	10
2.2.1.2 PRIMARY NERVE GRAFTS	11
2.2.1.3 CROSS-FACIAL NERVE GRAFTING	11
2.2.1.4 NERVE TRANSFER	12
2.2.2 MUSCLE TRANSFER TECHNIQUES.....	15
2.2.2.1 LOCAL MUSCLE FLAPS	15
2.2.2.1.1 TEMPORALIS MYOPLASTY	16
2.2.2.1.2 MASSETER MUSCLE	17
2.2.2.2 FREE MUSCLE TRANSFER	18
2.2.2.2.1 GRACILIS MUSCLE	19
2.2.2.2.2 PLATYSMA	20
2.2.2.2.3 STERNOHYOID MUSCLE.....	21
2.2.2.2.4 EXTENSOR DIGITORUM BREVIS	21
2.2.2.2.5 SERRATUS ANTERIOR	22
2.2.2.2.6 ANTEROLATERAL THIGHT FLAP	23
2.2.2.2.7 LATISSIMUS DORSI	23
2.2.2.2.8 PECTORALIS MINOR.....	24
2.2.2.2.9 RECTUS ABDOMINIS.....	25

3.CONCLUSION.....	26
4.ACKNOWLEDGEMENTS	28
5.REFERENCES	29
6.BIOGRAPHY.....	41

Summary

Title: Reanimation surgery for facial nerve paralysis

Author: Nika Kelc

Facial nerve paralysis has a great effect on patient's quality of life. Treatment is very complex and not always with satisfactory results. Facial nerve paralysis can have many different etiologies. It can be caused by trauma, infection, neurological diseases, toxins, or it can be iatrogenic or congenital. History and clinical examination are very important for treatment. Through decades many different surgical treatments have been described. They can be divided in static and dynamic procedures. Selection of treatment depends on the time of paralysis, patient's general health, age, and motivation for rehabilitation, type of injury, etiology of the paralysis, location of injury, and oncologic status. Static procedures can be done alone or in combination with dynamic procedures. They include temporary or permanent tarsorrhaphy, insertion of gold weights, palpebral springs or lid magnets, brow lift or suspension, forehead skin excision, unilateral facelift type procedures, static slings, nasolabial fold modification, and external nasal valve repair. Dynamic procedures include nerve repair, facial nerve decompression, harvesting nerve grafts (greater auricular nerve, sural nerve), primary nerve grafting, cross-facial nerve grafting (one or 2 stage), nerve transfer (hypoglossal nerve, nerve to masseter, glossopharyngeal nerve, accessory nerve, phrenic nerve), local muscle flaps (masseter, temporalis myoplasty), cross-facial nerve grafting with free muscle transfer in 1 or 2 stage procedures (gracilis muscle, pectoralis minor, latissimus dorsi, rectus femoris, extensor digitorum brevis, serratus anterior, rectus abdominis, platysma).

Key words: facial nerve paralysis, static procedures, dynamic procedures, facial nerve, facial reanimation

Sažetak

Naslov: Kirurška reanimacija kod pareze ličnog živca

Avtor: Nika Kelc

Paraliza facijalnog živca ima veliki utjecaj na kvalitetu pacijentovog života. Terapija je vrlo kompleksna i često bez zadovoljavajućih rezultata. Paralizu uzrokuju traume, infekcije, neurološke bolesti, toksini, a može biti i ijatrogena ili kongenitalna. Anamneza i status vrlo su bitni za daljnje liječenje. Kroz desetljeća opisivani su mnogi kirurški terapijski postupci koje možemo podijeliti na statičke i dinamičke. Izbor postupka ovisi o trajanju paralize, općem stanju pacijenta, lokalizaciji ozlijede i onkološkom stanju. Statički postupci se mogu obavljati samostalno ili u kombinaciji s dinamičkim postupcima. Oni uključuju privremenu ili trajnu tarzorafiju, postavljanje zlatnih utega, palpebral springs or lid magnets, podizanje ili suspenzija obrva, ekscizija kože čela, jednostrano podizanje lica, statički kaiševi, modifikacija nazolabijalne brazde i popravak vanjske nosne valvule. Dinamički postupci uključuju zahvate na samom živcu kao što su dekompresija facijalnog živca, uzimanje grafta živca (aurikularni živac, suralni živac), primarno presađivanje živaca, presađivanje cross-facijalnog živca (za prvi ili drugi stadij), prijenos živca (hipoglosalni živac, maseterni živac, glosofaringealni živac, akscesorni živac, frenični živac), lokalnim mišićnim režnjevima (masseter, myoplastia temporalisa), presađivanje cross-facijalnog živca sa slobodnim prijenosom mišića u 1 ili 2 faze (m. gracilis, m. pectoralis minor, m. latismus dorsi, m. rectus femoris, m. extensor digitorum brevis, m. serratus anterior, m. rectus abdominis, m. platysma)

Ključne riječi: paraliza facijalnog živca, statički postupci, dinamički postupci, živac lica, reanimacija lica

1. INTRODUCTION

Facial nerve paralysis has a significant effect of patient's quality of life. It can have big influence on his or her ability to eat, drink, emotional expression and psychosocial disorders. In the past, until end of 19th century, treatment of facial nerve paralysis involved non-surgical methods, such as medicines, ointments and electrotherapy (1). In 1821 Sir Charles Bell for the first time attempted to repair the facial nerve (2). In 1895 he restored facial muscle function by operating on facial nerve for the first time (3,4). Drobnik performed in 1879 first nerve transfer via an end-to-end neurorrhaphy between the distal facial nerve and the proximal spinal accessory nerve (5). In 1901 Korte performed first hypoglossal facial neurorrhaphy (6). Lexer did first regional muscle transposition using masseter and temporalis muscle in 1908 (7). In 1934, Gillies (8) first describe use of the middle third of the temporalis muscle with strip of the fascia lata. It was effective, but not physiological. McLaughling (9) described in 1949 anterograde temporalis myoplasty method that used entire muscle after separating the coronoid process and a strip of fascia lata. Scaramella (10) first described cross-facial nerve grafting in 1971. In his first case in 1968 he sutured the cervical branch of the normal facial nerve to an autologous sural nerve and in the second case he used the buccal branch of donor nerve. This technique was popularized by Smith (11) and Anderl (12). In 1971, Tompson (13) first attempted transfer of non-vascularised, denervated muscle graft to restore active movements. First combined free muscle transplantation with nerve and vessel microanastomosis was performed by Harii in 1976 using deep temporal motor branch of the trigeminal nerve as the donor nerve and gracilis as the muscle for reanimation (14). Over the years more muscles were introduced for muscle transfer. Terzis and Gustavson (15) described use of extensor digitorum brevis as neuromuscular graft, Terzis and Mantkeltow (16) introduced pectoralis minor muscle for facial reanimation, Nakajima (17) one-stage rhomboideus major muscle transfer, O'brien (18) one-stage gracilis muscle transfer, Jiang and Kuo (19) one stage abductor hallucis transfer, and Koshima (20) one-stage rectus femoris transfer. Today management of consist of a combination of pharmacologic therapy, physical therapy, and dynamic and static surgical therapies (21).

Etiology of facial nerve paralysis can be congenital or acquired. Congenital causes include obstetric, developmental facial paralysis, Möbius syndrome and idiopathic

mandibular division palsy (congenital unilateral lower lip palsy, CULLP). Obstetric injury is the most common among them. It is often with forceps delivery. CULLP is associated also with other congenital anomalies and causes unilateral weakness of depressor *anguli oris*. In Möbius syndrome children present with incomplete eye closure, mask-like face, inability to follow gaze, drooling and difficulty sucking. It usually also involves other cranial nerves and could involve abnormalities of limbs, spinal anomalies, neuropathies, heart disease, hypotonia and Pierre-Robin sequence (22). Acquired causes include traumatic temporal bone fracture or facial injury, neoplastic (schwannoma, teratoma, parotid tumor, hemangioma, sarcoma), infectious (Lyme disease, otitis media, varicella zoster, Coxsackivirus, poliomyelitis, syphilis, HIV, mastoiditis, cholesteatoma), neurological (lacunar infarct, multiple sclerosis, myasthenia gravis, pseudotumor cerebri), toxic (botulism, ethanol, tetanus, thalidomide, diphtheria, ethylene glycol) and iatrogenic (23). From acquired facial palsy, Bell's palsy is the most common. Etiology of it is unknown, but some studies suggest it might be viral. Clinical presentation includes prodromal taste disturbance, upper eyelid retraction, ectropion, brow and forehead ptosis, decreased blink reflex and decreased ability to close the eye. The second commonest cause is trauma due to temporal bone fracture and penetrating wounds (22).

Assessment of facial nerve paralysis should include history, physical examination, functional assessment, electromyography and grading scales. In history taking should be included general past medical history, current medications, allergies, occupation, hobbies, demographic details, smoking and alcohol consumption. It is important to determine the nature of facial palsy; when it was first noticed, its onset, if it is bilateral or unilateral, if it is complete or partial, if there is any improvement or deterioration. Patient should also describe main functional, esthetic and psychosocial problems. Physical examination should include inspection of face for skin quality, symmetry, scars, trauma and presence of synkinesis at rest. Each facial nerve should be assessed by raise of eyebrows, closure of eyes, smile, showing teeth, and blow out of cheeks. In functional assessment, speech, drinking, and eating is appraised. (22)

For the measurement of facial nerve function a grading system is essential. Many grading scales have been developed to evaluate the facial nerve function after onset of paralysis and during rehabilitation. The House-Brackmann scale (24) (table 1) was first

introduced in 1985 and is a universal standard for grading facial nerve recovery. It is six-point grading scale, it is very subjective, which can lead to errors (25). Because it lacks sensitivity (26), newer scales have been developed. Bures-Fischer system has three separate divisions, patient's self-evaluation of his or her percent recovery since the initial paralysis, physician's detailed analysis, and physician's Global evaluation. The final score is the average calculated from the results of three parts (27). This system allows finer distinctions of facial function, but lacks evaluation of resting symmetry and secondary defects and is time consuming (25). Nottingham system (28) is performed in three steps and is objective. In first step distances between supraorbital point to infraorbital point and lateral canthus to angle of mouth are bilaterally measured at rest and maximum effort during three motions. The differences between the measurements are summed up for both sides. The value of the affected side is expressed as percentage of the contralateral side. In the second step any absence or presence of secondary defects like hemifacial spasm, contractures and synkinesis is documented. At last absence or presence of gustatory tears, dry eyes, or dysgeusia is documented (28). This system has inability to assess bilateral facial impairment (25). The most commonly used is the Sunnybrook scale (29). It is based on evaluation of different regions including resting symmetry, symmetry of voluntary movement and severity of synkinesis. It provides more sensitivity to finer differences in facial nerve function. Facial Nerve Disorder Committee of the AAO-HNS published in 2009 a revised version of House-Brackmann scale named the Facial Nerve Grading System 2.0 (30). The new system includes regional scoring of facial movements and synkinesis but remains simple (30). In addition, many other scales exist, like eFACE (31), Facial Clinimetric Evaluation scale (32), The Facial Disability Index (33), Landmarks system (34), Objective Scaling of Facial Nerve Function Based on Area Analysis (OSCAR) (35), and Moiré Topography(36).

Table 1 – House-Brackmann facial nerve grading scale.

GRADE/DESCRIPTION	REST	MOVEMENT
I / NORMAL	Symmetry	Normal facial function
II / MILD DYSFUNCTION	Normal tone and symmetry	Forehead: moderate to good function Eye: complete closure with minimum effort Mouth: slight asymmetry
III / MODERATE DYSFUNCTION	Normal tone and symmetry	Forehead: slight to moderate movement Eye: complete closure with effort Mouth: slight weakness with maximum effort
IV / MODERATELY SEVERE DYSFUNCTION	Normal tone and symmetry	Forehead: none Eye: incomplete closure Mouth: asymmetry with maximum effort
V / SEVERE DYSFUNCTION	Asymmetry	Forehead: none Eye: incomplete closure Mouth: slight movement
VI / TOTAL PARALYSIS	Asymmetry	No movement

According to: House JW, Brackmann DE. Facial nerve grading system. *Otolaryngol Head Neck Surg* 1985;93:146–147.

2. REANIMATION SURGERY FOR FACIAL NERVE PARALYSIS

In this review we are going to talk about different surgical techniques to correct facial nerve paralysis. We can divide surgical techniques in two different categories: static procedures and dynamic procedures. Static procedures include temporary or permanent tarsorrhaphy; insertion of gold weights, palpebral springs or lid magnets; brow lift or suspension; forehead skin excision; unilateral facelift type procedures; static slings; nasolabial fold modification, and external nasal valve repair. Dynamic procedures include nerve repair, facial nerve decompression, harvesting nerve grafts (greater auricular nerve, sural nerve), primary nerve grafting, cross-facial nerve grafting (one or 2 stage), nerve transfer (hypoglossal nerve, nerve to masseter, glossopharyngeal nerve, accessory nerve, phrenic nerve), local muscle flaps (masseter, temporalis myoplasty) cross-facial nerve grafting with free muscle transfer (1 or 2 stage) (gracilis muscle,

pectoralis minor, latissimus dorsi, rectus femoris, extensor digitorum brevis, serratus anterior, rectus abdominis, platysma). Surgical treatment option depends on duration of facial paralysis. Acute facial paralysis lasts less than 3 weeks. For its management facial nerve decompression (trans-mastoid approach, middle fossa approach, trans-labyrinthine approach) and facial nerve repair (primary nerve repair, cable grafting) are used. Intermediate duration facial paralysis lasts between 3 weeks to 2 years and surgical treatment options include cross-face nerve grafting and nerve transfer (hypoglossal, masseteric, spinal accessory). In chronic facial paralysis regional muscle transfer (temporalis, masseter, digastric) and free muscle transfer (gracilis, serratus anterior, latissimus dorsi, pectoralis minor) techniques are used.

Selection of the most appropriate reanimation method depends on type of injury, etiology of the paralysis, location of injury, and oncologic status. (37)

2.1.STATIC PROCEDURES

The aim of the static facial reanimation is to protect the eye globe from potential injury, create support and lifting the paralyzed facial muscle to counteract overacting of opposing muscles and effects of the gravity, and to restore the symmetry of the face (8). They are good option for poor surgical candidates who cannot tolerate the longstanding operation for dynamic reconstruction (38) and for patients interested in immediate restore of symmetry with low morbidity and without extensive surgical procedure (39). Static procedures are a good choice for repairing specific functional or cosmetic deficits of the perioral, periorbital region and to address nasal obstruction due to nasal valve collapse (40).

2.1.1. TARSORRHAPHY

Tarsorrhaphy is a procedure that joint all of or part of the upper and lower eyelids. The procedure can be permanent or temporary. Most of the time suture is used to join the lids, but sometimes botulinium toxin tarsorrhaphy or cyanoacrylate glue can be used. Temporary tarsorrhaphy is performed if there is an expectation of recovery and will be effective for 2-8 weeks. In permanent tarsorrhaphy central lid is left open and only the

lateral eyelid is closed. It may be indicated if there is little expectation of recovery of eyelid closure (41). An example is the McLaughlin tarsorrhaphy (42). Tarsorrhaphy results in decreased peripheral vision and secondary complications, like trichiasis (43).

2.1.2. CANTHOPEXY

Lower lid laxity can also be corrected by a lateral tarsal strip canthopexy, a lid-tightening procedure. First lateral canthal tendon is transected and then an inferior cantholysis is performed. It results in tarsal strip, which is sutured to the periosteum of the lateral orbital rim (44,45). Tarsal strip restores the normal tear film, reduces exposure keratopathy, and improves ocular symptoms (46). With tarsal strip, suborbicularis oculi fat pad lift is often used as an adjuvant to improve ocular outcomes (47). Azuma *et al.* (48) describe a correction of paralytic ectropion of the lower eyelid by the vertical orbicularis oculi muscle turn-over (VOTO) technique. With a muscle flap of orbicularis oculi, the inferior tarsus is pulled postero-laterally and rotated inward. Orbicularis oculi is sutured to the Whitnall tubercle and the orbicularis oculi of the lower eyelid and skin are resected in that way that the ectropion is adequately corrected. Ectropion was corrected in all of their cases and there was significant improvement of symptoms. According to their experience, VOTO procedure has longer durability and stronger effect in ectropion fixing in correlation to lateral tarsal strip procedure and simple canthoplasty.

Medial canthopexy should be performed to patients with medial lid malposition. Medial orbital rim is accessed below the subciliary and lacrimal punctum through a transcutaneous incision(49) or transnasally(50). Anchoring spot should be just superior to the medial canthal tendon insertion site and Mitek Micro bone anchor system can be used (49).

2.1.3. LOWER EYELID

Lower eyelid can be retracted by a graft using hard palate mucosa, conchal and septal cartilage, acellular dermal matrices, and mucosa (51,52). For patients with anterior lamellar deficiency graft is placed between the orbital septum and the orbicularis oculi. When a patient has posterior lamellar deficiency, graft is placed between the retracted lid retractors and the tarsus (53). Hard palate spacer grafting in combination with lateral

canthoplasty and midface suspension was effective in treating lower eyelid retraction (54).

Sulyan *et al.* (55) described a single- procedure for repair of paralytic ectropion and lagophthalmos using a modification of the tarsoconjunctival flap. A lateral canthotomy incision is done and inferior aspect of the lateral canthal tendon is cut so that the lower eyelid is completely free from the lateral orbital rim periosteum. A full-thickness wedge resection of lateral 3 to 4 cm of the lateral eyelid tarsus is done. The lateral internal tarsorrhaphy is performed by retraction of upper eyelid centrally and everting it over retraction, incising of lateral tarsus and creation of tarsoconjunctival flap, leaving only conjunctiva attached. After, to form a groove for the tarsoconjunctival flap, a horizontal incision in lower eyelid tarsus is performed, posterior to the mucocutaneous junction. The tarsoconjunctival flap is sutured to the lower eyelid tarsus and tarsus is reattached to the lateral orbital rim periosteum in a bit higher position in a horizontal mattress fashion. This technique addresses ectropion and lagophthalmos in a single-stage procedure. It also avoids phimosis and cosmetic deformities.

2.1.4. EYELID WEIGHTS

Implantation of platinum and gold eyelid weights into the upper eyelid is procedure for treating lagophthalmos. Procedure is done under general anaesthesia (37). Incision is placed in an upper eyelid crease and deepened through the skin and orbicularis oculi muscle. A pocket for lid weight is made and the weight is then sutured to the superior tarsal plate (44). The weights are centered over the pupil with the patient in centric gaze (56). Golden weights were previously used for lid loading, but have been associated with poor esthetic outcomes, because of thick profile (57). Complications of gold weight insertion include infection of graft, position shift, overclosure of the eyelid due to insertion of the weight too low, and extrusion (37). Platinum weights have recently acquired popularity, because they have more density, which allows for the weight to have a lower profile for same degree of lid loading (57,58,59). With almost all weights complete eye closure and corneal protection is achievable (44,59,60).

2.1.5. PALPEBRAL SPRING

The palpebral spring procedure is used when there is poor levator action. It is a technically difficult procedure and has higher extrusion rate (37). The spring spans between the superior orbital rim periosteum and a pocket at the superior aspect of the tarsus (61). Complications include infection, migration, wearing out, extrusion, and breakage (37).

2.1.6. BROW LIFT

Brow lift can be used to correct brow ptosis. A variety of treatment approaches can be used: direct brow lift (coronal, mid-forehead, or brow incision), endoscopic brow lift, or minimally invasive temporal brow lift using a biodegradable stabilization device (62,63). Direct brow lift is done with incision just inside the superior brow hairline. Soft tissue is then excised and the height of the brow is adjusted. To secure the brow at its height, a deep suture can be used to the periosteum of the forehead. If patient has deep forehead wrinkles, the incision can be made within a mid-forehead skin crease (63). Direct brow lift can be done also by coronal brow lift. In this procedure incision is placed 4 to 6 cm posterior to the forehead hairline. It can cause pulling of the hairline more posteriorly. In pretrichial approach incision is placed immediately posterior to the hairline. Because anteriorly excised skin has no hair, location of the hairline is preserved (63). In endoscopic technique 3 to 5 small access incisions posterior to the hairline are required. Depressor muscles of the brow are divided and the elevated brow is secured (64). This technique has a favor because of minimal incision with similar results (65).

2.1.7. FOREHEAD SKIN EXCISION

Forehead skin excision is effective in patients with complete facial palsy and brow ptosis. Skin is excised in the temple or above eyebrow. Procedure leaves visible scar and is mostly done in older patients (22).

2.1.8. STATIC SLINGS AND GRAFTS

Static slings for facial support use number of materials, including Gore-Tex (polytetrafluoroethylene), AlloDerm (acellular dermal graft), fascia lata and palmaris longus. It is typically placed from the temporalis fascia and zygomatic arch to nasolabial fold and oral commissure. They are used to support several(?) structures, for example: lower eyelid, to recreate the nasolabial fold, elevate the cheek and nose and draw the nasal ala laterally to open the external nasal valve, and to elevate corner of the mouth.

Fascia lata grafts can be used to support the paralyzed muscles in the midface to elevate the oral commissure and with that improve oral incompetence, the static esthetic appearance, and speech articulation (66). In procedure two fascial slings are subcutaneously inserted in upper and lower lips and sutured at 4 points to each lip, which also include unaffected part of orbicularis oris muscle. With an osteosynthesis plate slings are suspended against zygomatic arch. With those attachments an active movement of the mouth corner and static esthetic appearance can be achieved (66). By using unaffected part of orbicularis muscle for attachment, success of reanimation does not majorly depend on patient's compliance. An advantage of loop attachment against a fixed support is the accomplishment of reliable and sufficient overcorrection with an immediate improvement of facial symmetry and functionality. Because grafts stretch and relax over time, overcorrection is necessary (66). The disadvantages of use of fascia lata graft include morbidity at the donor site and additional incision in the lateral leg. Use of autologous grafts reduces the risk of extrusion and infection (66). Gore Tex is associated with major wound complications, midface abscesses, graft extrusion, and unacceptable long-term results particularly in patients with history of radiotherapy (67,68). AlloDerm has fewer adverse reactions in patients with compromised soft tissues, but unpredictable postoperative extension of the sling with loss of oral competence and recurrence of facial ptosis is limiting wide use of it (39). Commercially produced slings also have risk of infection (69).

Split palmaris tendon graft as a minitendon graft can be used for treatment of lower eyelid suspension. A thin strip of palmaris tendon put just beneath the lash line. After that, it is wrapped around the medial canthal tendon and fixed to itself. Tendon is then elevated up around the lateral canthal tendon to superior orbital rim. There it is secured

to a drill hole. It is an effective treatment regardless of patients age, cause of injury and denervation time (70).

2.2 DYNAMIC PROCEDURES

Dynamic reanimation goal is to improve smile and eyelid function and to improve facial symmetry (71).

2.2.1 NEURORRHAPHY

When continuity of facial nerve is broken, it fundamental to reinnervate the facial muscles in as little time as possible(72). If it is possible, the best way is by direct repair (73). Neurorrhaphy with interpositional graft is also a competent way to accomplish facial reanimation, when primary repair is not possible(72). Because in use of interpositional graft sprouting axon has to overcome 2 coaptation sites, the innervation is poorer in comparison to primary nerve repair (74). Patients may benefit from nerve repair if it is done in one year or earlier, because of less muscle atrophy and replacement by fatty and fibrous tissue (72). Distance of the repair from the motor end plates determine timing of reanimation after nerve repair. Axons regenerate at approximately 1mm/d and motor end plates deteriorate 1% per week. Problems associated with facial nerve repair and grafting are dyskinesia, weakness, and mass movement (synkinesia) (73).

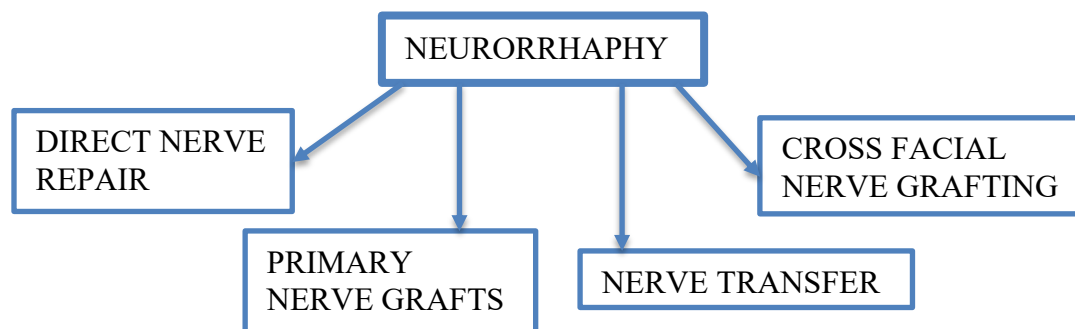


Figure 1: Types of neurorrhaphy

2.2.1.1 DIRECT NERVE REPAIR

Direct nerve repair is the best surgical option for acute injury, if it is possible. Repair should be done in 72 hours after nerve injury and should be tension-free. Epineural repair with 3 or 4 simple sutures is recommended, with 8-0 to 10-0 nylon suture and

under operating microscope or high-powered loupes(37). Factors that influence the achievement of repair include the character of the wound, tension, time lag to repair, and presence of scar tissue (37).

2.2.1.2 PRIMARY NERVE GRAFTS

Nerve grafts are indicated when the proximal and distal cut stumps of the facial nerve exist but the intervening gap is too wide for effective a tension-free direct nerve repair (72). The sural, greater auricular nerve, medial antebrachial cutaneous (MABC), lateral antebrachial cutaneous (LABC) nerve, nerve to vastus lateralis can all be used as donors (75). Motor nerves have shown some evidence of improved outcomes over sensory, but harvesting may have unacceptable side effects (40). Best results are if procedure is done within 1 year of facial paralysis because of less muscle atrophy. Long-term outcomes depend also on the condition of the nerve and the type of primary lesion (72). Great auricular nerve is the most commonly used donor nerve when small nerve graft is required, because of its ease of exposure and proximity. (37)

2.2.1.3 CROSS-FACIAL NERVE GRAFTING

Cross-facial nerve grafting is an option when proximal nerve stump is unavailable, but distal segment remains intact with functioning motor endplates. Grafting can be done in 1-stage or 2 stages (22).

When 2-stage technique is done, in first stage branches of the facial nerve using a nerve stimulator are identified and are carefully selected for sacrifice depending on the desired innervations function. Long sural nerve is harvested and tunneled to contralateral face. The proximal end of the sural nerve graft is then coapted to the donor facial nerve branches. Second stage is done 9 to 12 months later. Neurotrophies are performed between cross-face nerve grafts and selected facial nerve branches (76). In one-stage technique both ends are repaired at the same procedure (22). Best results are achieved in cases of paralysis for less than 6 months (76).

The benefit is its ability to provide a spontaneous smile, but the muscular contraction produced is often significantly weaker than that on the normal side. As regenerating axons must cross 2 suture lines and travers a sural nerve graft, a period of 9 to 12

months is necessary for the axon to migrate through the graft. This time causes further fibrosis and atrophy of the muscles (77). While axonal regeneration proceeds in the cross-face graft, “baby-sitting” procedure with partial hypoglossal transfer to selected buccal and zygomatic branches can be applied to maintain the neuromuscular junction of the denervated muscle. (78) Cross-face nerve grafts are useful in individuals with incomplete paralysis. (77)

Jeong et al. (79) described a novel approach, per-oral cross-facial nerve graft, for facial reanimation. They performed this technique on three patients with unilateral facial palsy. A cross-facial nerve graft was successfully performed by an intraoral mucosal incision and dissection without wide elevation of the facial skin. This approach is advantageous for several reasons. It has a stable anatomical landmark (parotid papilla), which aids to location of papillary duct that is in close association with buccal branch of facial nerve. By avoiding unnecessary invasive extraoral skin flap elevation and wide dissection to the anterior border of parotid gland, the scar on facial skin can be evaded. Intraoral approach also requires a shorter operation time. As they described additional research in this technique should be done before it can be substituted for the extraoral approach.

In one study (80) they compared VII-to-VII and XII-to-VII coaptation techniques for early facial nerve reanimation after surgical intra-cranial injuries. They concluded that XII-to-VII side-to-end coaptation technique provides better functional outcome in House-Brackman grading, but is associated with high risk for complications. Direct VII-to-VII repair should be performed if facial nerve interruption is intraoperatively noticed at the end of tumor debulking.

2.2.1.4 NERVE TRANSFER

Local cranial nerves produce a source of motor axons that can be redirected for facial reanimation. Indications for nerve transfer include presence of distal stump, facial muscles are capable of useful function after reinnervation, and proximal facial nerve stump is unavailable for grafting. Hypoglossal nerve, nerve to masseter, phrenic nerve, accessory nerve, or glossopharyngeal nerve may be used.

Each nerve donor site carries advantages and disadvantages. Attention should be given to the functional defect that is going to be produced by sectioning the donor nerve, the degree of motor power that can be expected, potential for motor

reeducation, technical difficulty, need for nerve grafting, presence of coexisting cranial nerve lesions, and recovery time. (77) It is particularly useful to treat facial paralysis resulting from intracranial or intratemporal disorders or surgery. (37)

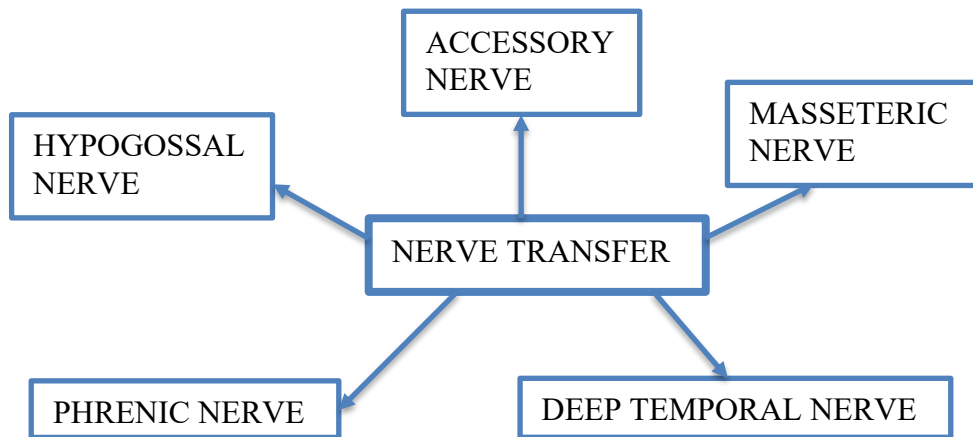


Figure 2: Types of nerve transfer

Hypoglossal nerve transfer is most commonly used and represents gold standard nerve transfer. Several techniques are used. The classic XII-VII transfer includes transection of the entire hypoglossal nerve distal to the ansa cervicalis and joining to the main trunk of the facial nerve (81). In “Split” XII-VII transfer reported by Asaoka et al. (82) 30-40% of the hypoglossal nerve is divided longitudinally for several centimetres and approximated to the lower division of the facial nerve. This technique causes less tongue atrophy and no severe dysfunction in speech and swallowing (83). May et al. (84) introduced XII-VII jump graft technique, in which end-to-side neurotomy between hypoglossal nerve and a donor cable nerve graft (e.g. great auricular nerve, sural nerve) which serves as a jump graft to the main trunk of the facial nerve is done (81). This technique successfully reinnervates the facial nerve without producing tongue paralysis, but power of innervation is weak and needs a lot of time for reinnervation (84). In mobilization of mastoid segment of facial nerve developed by Sawamura and Abe (85) the facial nerve is mobilized in its mastoid segment from the 2nd genu distally and rotated inferiorly to allow direct coaptation to the hypoglossal nerve. It usually requires removal of the mastoid tip (81). Recovery generally occurs over 6-24 months and may be observed for up to 5 years (22). Classic XII-VII transfer is associated with significant donor side morbidity, like tongue atrophy, impaired speech, difficulty eating (86), synkinesis and mass motion. (87) Hemiatrophy of the tongue does not always lead to a permanent

deficit in tongue function (88) and sometimes is considered as a positive factor in facilitating the lingual function by diminishing the mass of the nonfunctioning side (89). It is contraindicated in patients susceptible to the development of multiple cranial nerve deficits. (77) Success depends on the time interval between initial denervation and nerve transfer and it is the best when performed within the first 3 months (86).

Masseteric nerve transfer has many advantages in comparison to hypoglossal nerve. It causes less difficulties with eating and speech impairment. Utilization of this nerve does not result in complete paralysis of the masseter muscle, atrophy producing a visible cosmetic deformity, or temporal mandibular joint dysfunction (77), proximity between masseteric nerve and facial nerve branches eliminates the need to use a nerve graft (90). Transfer is done by dividing the descending branch distally and transporting the nerve into a more superficial location, which facilitates microsurgical anastomosis while preserving proximal innervation. Active motion of the facial musculature develops an average of 6 months after surgery and there is rapid motor reeducation. The masseteric nerve appears to have some advantage in comparison to other nerve donor sites with respect to reeducation and production of an effortless smile (77). The main disadvantage of masseteric nerve is the issue of movement dissociation and spontaneity (90).

Accessory nerve is not a first-line donor site for facial reanimation. Sectioning of complete nerve may produce significant shoulder weakness (91) and shoulder movement can produce mass contraction of the facial musculature(77). Transfer is appropriate when preexisting speech and swallowing problems are present or motor branch to masseter and hypoglossal nerves are absent (77). By selecting branch to sternocleidomastoid muscle, donor site morbidity can be decreased. (92)

Phrenic nerve is used in rare situations, when better donor nerves are unavailable. (77) Good resting facial tone is achieved, but marked contractions and asymmetry develops with laughing, coughing, and deep inspiration. (93) It produces hemidiaphragmatic paralysis and is contraindicated in individuals with chest wall abnormalities or pulmonary disease. (94)

Mahan et al. (95) explored the option of using deep temporal nerve in facial reanimation of upper facial musculature. They demonstrated that it can be used as direct neurotizer of frontal and temporal branches of facial nerve. Middle deep temporal nerve can be identified approximately 1 cm posterior to the jugular point of the zygoma. Their experience showed that they restored independent periorbital muscle control without considerable temporalis atrophy, which is not commonly achieved with other techniques.

2.2.2 MUSCLE TRANSFER TECHNIQUES

Patient with long-standing facial paralysis (>3 years) will probably not benefit from neural techniques. Because of severe fibrosis in distal neuromuscular unit with atrophy of facial musculature reinnervation is unlikely (37). Muscle transfer techniques include local muscle flaps and free muscle transfer.

2.2.2.1 LOCAL MUSCLE FLAPS

Local muscle flap is usually used to reanimate lower third of the face. It may be done in conjunction with nerve graft or a cross-over implanted in the transferred muscle. Flap is composed of transposed muscle with its original nerve supply. Masseter, temporalis, and digastric muscles can be used. (37) To achieve the intended dynamics intense muscular retraining is required (73).

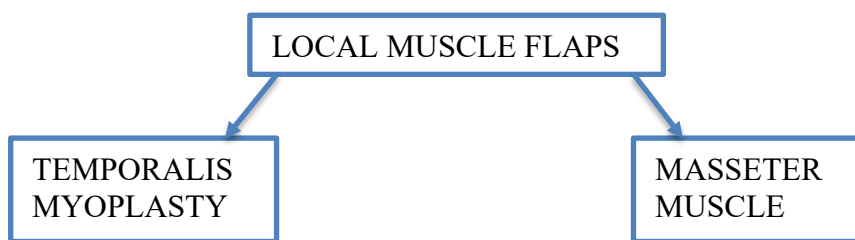


Figure 3: Local muscle flaps

2.2.2.1.1 TEMPORALIS MYOPLASTY

Golovine (1898) was the first one who described the use of temporalis myofascial flap for the reconstruction of an orbital defect. Recent advancements have made it viable for reconstruction of various defects in maxillofacial region (96). Temporalis muscle is innervated by trigeminal nerve and has a blood supply from deep temporal branch of internal maxillary artery. The muscle is released along with its aponeurosis from temporal fusion line, reflected inferomedially, and attached to the modiolus at the oral commissure, the nasolabial fold, and the orbicularis oculi (73). The procedure is quick and easy, and immediate correction of soft tissue ptosis is achieved. The procedure is a good option for bilateral facial paralyses and is associated with low morbidity (97, 98). It is good for intraoral reconstruction because of its proximity, muscle is easily accessible through a skin incision that is hidden in the hair bearing scalp and in a preauricular crease, it is highly mobile, has a wide arch of rotation and transposition (99). Disadvantages of this flap are temporomandibular joint dysfunction, lack of spontaneous movement, and soft tissue fullness over the zygomatic arch (73). When temporalis muscle is used for reconstruction of large defects, temporal hollowing can occur. Because it is covered by hair, it is mostly not a big concern. Some suggestions for repairing the defect are use of silastic or acrylic and positioning of posterior part of temporalis muscle anteriorly, if only anterior part of muscle was used (100,101). One of modified approaches of temporalis muscle transfer involves the attachment of the fascia lata graft to the reflected temporalis and suturing this to the orbicularis oris. It has best results in long-standing cases (102). The technique gives immediate results in food intake, facial symmetry, speech and has only 7% complication rate (66). In place of fascia lata sling, tendon of palmaris longus muscle can be used (103). Balaji (104) compared this technique to conventional technique of temporalis muscle transfer. Technique with fascia lata graft has better symmetry, pull of muscle, motor control, and faster recovery time than only temporalis pull-through technique. As muscle is not traumatized, original muscle architecture and vascular channel supply is preserved and no fibrosis occurs.

Silan *et al.* (105) described temporalis tendon transfer with use of cryopreserved fascia lata allograft. Facial dynamic reanimation is achieved in a single procedure with fast postoperative recovery. With use of cadaveric fascia lata graft satisfactory long-term results were obtained and there was no loss of strength of fascia. No

additional scars are needed and complications of donor site complications are avoided, like postoperative hematoma, muscle herniation, superficial phlebitis, pain, numbness, wound infection, weakness of hip flexion, and cosmetic concerns (106).

They observed high grade of patient's satisfaction (105).

Temporalis tendon transfer is an orthodromic procedure in which the muscle insertion is transferred to the oral commissure (107). Procedure may be done by a single incision at the site of insertion (transoral or melolabial) (108) or with a temporal incision to allow muscle mobilization (109). It provides immediate correction of facial paralysis. Advantages of this procedure include stronger attachment, no temporal depression in the donor site, better vector of pull, no tissue protrusion over the zygomatic arch, and greater motor force (110). Minimally invasive temporalis tendon transfer (MIT3) is performed through the transoral or the melolabial approach (107). Brichaek *et al.* (107) described no significant difference in symmetry with smiling in melolabial or transoral approach. In their study they achieved some degree of improvement in each patient. Candidates for this procedure must have a functioning temporalis muscle. It is effective procedure in cases of long-standing paralysis in patients who desire a single-stage procedure with rapid recovery or who are not good candidates for free tissue transfer. Procedure can be done together with nerve grafting. The advantage of the MIT3 procedure over the classic temporalis sling is the elimination of any newly created changes in facial symmetry. They found that MIT3 procedure is predictable, effective, and easy-to-perform, scar of melolabial approach have minimal impact as it is hidden in the melolabial fold, and that transoral approach does not create a scar.

2.2.2.1.2 MASSETER MUSCLE

Masseter muscle rotation has been almost wholly abandoned because of poor aesthetic outcomes (97). Many modifications of the regional masseter muscle transfer are described in the literature. Shinohara *et al* (111) uses the tensor fascia lata as the string, zygomatic arch as the wheel in a pulley, and the masseter muscle as a force. Sachs and Conley (112) suggested an intraoral approach to masseter muscle transposition.

As a disadvantage of conventional masseteric muscle transfer postoperatively is muscle elongation due to the weight of face. Abbasi (113) proposed modified

masseteric transfer with the underlying mandibular periosteum as unit to prevent it. Procedure seemed to produce better results with time, more contraction and more constant elevation.

Lesavoy *et al.* (114) described staged, split masseter muscle transfer. Surgical technique is a 3-stage operation. In the first stage, hemioral fasci lata graft is placed to act as an anchor reinforcement. It provides an attachment site for the masseter transfer and reinforces the oral commissure. The second stage is done after 3 months. Transfer of split masseter muscle is performed via a nasolabial or a preauricular incision and sutured to the fascia lata reinforced oral commissure. After 6 to 10 months, third stage is performed under local anesthesia to reinforce attachments. It can be done several times until suitable results are accomplished. The procedure is suited for subtle smile and speech and restores oral competence, but does not allow for reanimation in exaggerated movements. It is a good choice for those unable or unwilling for ling and complex operation to restore static and dynamic function and to provide bulk. The disadvantage of this technique is necessity for multiple stages.

2.2.2.2 FREE MUSCLE TRANSFER

Free-muscle flap may be used in cases of long-term paralysis in which considerable muscle atrophy or soft tissue contracture has taken place or for facial reanimation with large defects (37). The procedure may be done as single stage or as two stage. Single stage procedure may be done if proximal facial stamp is available or if a long enough donor muscle nerve is present to reach the contralateral facial nerve branches. In staged procedure first a local neural source via cross-facial nerve grafting is established. Extend of axonal regeneration through graft is monitored by Tinel's test. Sufficient axonal progression usually takes 6 to 12 months. After this free muscle transfer is performed by vascular anastomoses to the superficial temporal or facial vessels, recipient and donor nerve coaptation, and fixation of the muscle to the zygoma superolaterally and to the nasolabial fold, upper lip orbicularis, and lower lip orbicularis inferomedially. Disadvantages of this procedure are lengthy surgical times, donor side morbidity, and the need for specialized microsurgical skills (73). For free muscle transfer gracilis muscle, pectoralis minor, latismus dorsi, rectus femoris, extensor digitorum brevis, serratus anterior, sternohyoid muscle, rectus abdominis, and platysma can be used.

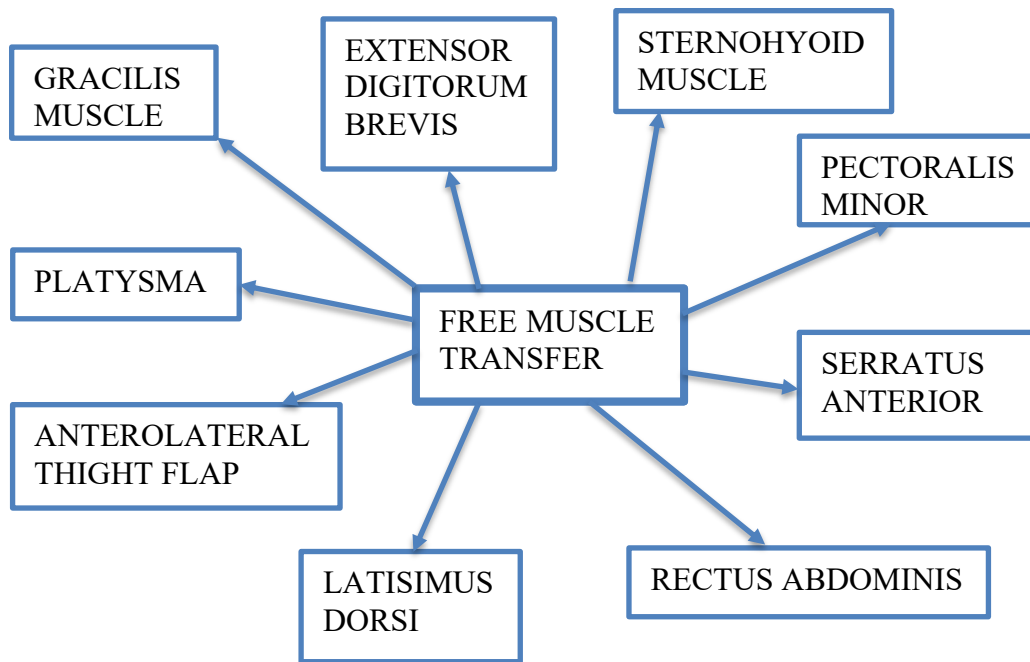


Figure 4: Types of free muscle transfer

2.2.2.2.1 GRACILIS MUSCLE

Gracilis muscle is probably most often used flap (115) and it was first introduced by Harii and his coworkers (14). It is often used because of its predictable pedicle anatomy, favorable muscle microarchitectural features, and acceptable donor site morbidity (116). Gracilis free flap can be used with different innervation techniques by masseteric nerve, contralateral facial nerve, or both, in a 1- or 2-stage procedure (117,118). Operation with masseteric branch of trigeminal nerve is performed in single procedure under general anesthesia with 2 fields at once. Gracilis muscle is dissected with its vascular pedicle and branch of obturator nerve. A muscle segment of approximately 10-12 cm is required. The masseteric nerve has been shown to be considered a safe, strong donor that provides movement similar to that of the non-impaired half of the face (117). It produces functionality in a mean of about 4 months and over time some patients manage with rehabilitation to achieve a spontaneous and involuntary smiling. There seems to be some plasticity or cerebral adaptation, leading to cortical reorganization, producing new connections between the nuclei of the cranial nerves VII and V (119).

Glacilis flap reinnervation using a cross-face nerve graft is the gold-standard treatment (115). It consists of a 2-stage procedure with primary cross-face nerve graft surgery and following free muscle tree muscle transferred muscle transfer surgery that

is performed 6 to 12 months later. This technique can create a spontaneous and natural smile (120). It has the disadvantage of requiring 2 operations with time between them, delaying functional results for approximately 1 year (119).

1-stage double-powered free gracilis muscle flap transfer can be done by splitting the obturator nerve and anastomosing the 2 free ends to the masseteric nerve and to the facial nerve through sural graft (118). This procedure was introduced by Biglioli et al. (121). Advantage of double innervation is a possibility of a spontaneous smile from cross-face nerve graft and it guarantees strong nerve input by masseteric nerve (121,122). Baccarani et al. (118) modified Biglioli et al. (121) technique. Motor nerve is split longitudinally and 2 free ends are coapted to the sural graft and the ipsilateral masseteric nerve. Difficulty of this approach is that imaging technologies cannot provide information, if the cross-section of the gracilis motor nerve is large enough for splinting. Because of that, decision can be made only after microsurgical inspection during surgery (118).

2.2.2.2.2 PLATYSMA

Use of free neurovascular platysma transfer with cross-facial nerve graft (CFNG) for dynamic eye closure in long-standing facial paralysis was initially presented by Lee and Terzis in 1984 (123). The platysma is similar to the orbicularis oculi in terms of embryological origin and the fiber-type distribution (124). The procedure is performed in 2 steps. In the first step is selection of the donor branches for the cross-facial nerve graft for the eye. Sural nerve graft is placed supraorbitally in an orthodromic manner. Second stage involves platysma transfer from contralateral side and is performed at least 9 months later (125). Platysma transfer is the only possible dynamic method of restoring eye closure and blink, allowing restoration of a natural physiological eye sphincter, which can withstand sunlight, wind and other weather conditions (125). Surgery makes some challenges with selection and sacrifice of the ocular branches of the facial nerve, avoiding the small arterial and venous branches of the facial nerve vessels towards the platysma, discrepancy in size between the CFNG and the small motor branch to platysma (125). This technique can be modified by rehabilitating only the upper lid with platysma graft and cross-face sural nerve graft and lower lid being pulled upward by a simple fascia lata string suspension (126). Technique does not always lead to positive results, probably because of a weak

axonal source, a paucity of axons growing through a cross-facial nerve graft, direct neurotization is not as effective as end-to-end neurotization to the motor nerve proper of a specific muscle segment, and it is known that long nerve grafting is not completely reliable to carry on neural regrowth (126).

2.2.2.2.3 STERNOHYOID MUSCLE

Sternohyoid muscle has been described as a potential free flap for microvascular transfer. The sternohyoid has better anatomic size match to the zygomaticus major muscle, better fiber type match compared with the gracilis and causes less muscle bulk in temporal region and zygoma. Preliminary results have been promising. Flap is harvested with ansa cervicalis. The pedicle is anastomosed to superficial temporal artery and the superficial and/or deep temporal vein. Alternatively, facial vessel can be used. Nerve can be transferred in a single stage across the upper lip in a subcutaneous plane to the contralateral facial nerve(127). Alam (127) described patient outcome after 6 months. He underwent a sternohyoid flap using an ipsilateral masseter nerve donor. There was minimal bulk, smile was equal to that seen of a full smile on his normal side. They describe this technique as good option for older patient population with malignant etiologies. (127)

2.2.2.2.4 EXTENSOR DIGITORUM BREVIS

Extensor digitorum brevis is a trapezoid-shaped muscle whose function is to assist extensor digitorum longus in extension of the second through fourth toes. Because of synergistic function, harvesting the EBD produces little to no functional deficit at donor side (128,129). EBD has blood supply from lateral tarsal artery, a branch from dorsalis pedis artery(130), and innervation from the lateral terminal branch of the deep peroneal nerve (128). Advantage of use of EBD are a predictable and constant blood supply with similar muscle bulk to the facial muscles, tendinous structure that facilitate the fixation and function of the muscle strips, minimal donor site morbidity, straightforward flap dissection, multiple independent force vectors, and use in single- and double-stage procedures. Disadvantages are smaller size compared with other donor muscle groups and sacrifice of dorsalis pedis artery(131). An absolute contraindication for use of EBD is peripheral vascular occlusive disease, as the dorsalis pedis artery may be the only source of blood supply to the remaining foot and

it may cause reconstruction failure (132). Because of that, if there is any suspicion of compromised artery patency, further investigation with computed tomography angiogram or ankle-brachial index is indicated. Often contralateral forehead is used in relation to affected side of the face because of the medial to lateral trajectory of EBD's neurovascular pedicle and facilitation of inset of the flap. Flap is fixated at proximal insertion to deep temporalis fascia. Distally, the tendinous insertions are fixated to the nasal alar base, the upper lip medial to the nasolabial fold, the modiolus, and to the midline of the lower lip at the labiomental crease (131).

2.2.2.2.5 SERRATUS ANTERIOR

The serratus anterior (SA) is a fan-shaped muscle consisting of 9 or 10 independent slips (133). Primary function of SA is to stabilize the scapula against the chest wall with rhomboids (134). 3 or 4 of the most inferior slips can be harvested for functional muscle transfer without causing winging of the scapula (134,135). SA has 2 dominant blood supplies, lateral thoracic artery for upper two-thirds and serratus branch of the thoracodorsal artery for lower one-third (136), and innervation from the long thoracic nerve (131). Advantages of SA use are ease of flap harvest, long and consistent pedicle, multiple independent force vectors, and acceptable donor site morbidity. Disadvantages are that it must be harvested from the lateral decubitus position, which often requires an intraoperative position change, and it may not provide enough volumetric fill in patients with large soft-tissue defect. Before operation, a detailed neurological examination of upper extremity and hand must be done, with emphasis on the upper roots of the brachial plexus by testing elbow flexion, shoulder abduction, and elbow extension. Because of the cranial to caudal trajectory of SA neurovascular pedicle, contralateral SA is often used in relation to affected side of the face. Proximal part of flap is fixated to the deep temporalis fascia and distal slips are secured to the nasal alar base, upper lip, modiolus, and midline lower lip (131). Sakuma and his co-workers (137) developed a method using thinned and multi-vector neurovascularized serratus anterior muscle slip for facial reanimation. On the basis of cadaveric studies, they demonstrated that only superficial subslips can be harvested and that each subslip can be safely divided up to the common artery and transferred without compromising vascularity. Superficial subslips are harvested with the thoracodorsal vessels and upper branches of the long thoracic nerve are preserved to prevent

scapular winging postoperatively. Advantages of their technique include lack of bulkiness observed with full-layered serratus anterior or other donor muscles, more complex multiple force vectors because of ability of separation of medial and lateral margin of muscle subslips from each other and contractile force in the mimetic muscles because of parallel fiber orientation. Upper superficial subslip elevates the upper lip and helps to reveal maxillary teeth when smiling, middle superficial subslip elevates oral commissure, and lower superficial subslip retracts the oral commissure and compresses the cheek against teeth and gums (137).

2.2.2.2.6 ANTEROLATERAL THIGHT FLAP

Anterolateral thigh (ALT) flap is a fasciocutaneous flap (138). Because it lacks functional muscle, it cannot be used alone to restore motion to the paralyzed face, unless combined with another dynamic procedure (139). For dynamic reconstruction combined ALT flap-reinnervated rectus femoris or sartorius muscle flap have been used (140). Advantages of this flap are versatility in flap design, long pedicle, ability to be sensate or raised as a composite flap, minimal donor site morbidity, and large soft tissue yield (141,142,143). Disadvantages are variable perforation route and location and inconsistent flap thickness (138,144).

2.2.2.2.7 LATISSIMUS DORSI

Latissimus dorsi (LD) has many possibilities to be used as flap for facial reanimation, for example it can be used as a mixed flap with serratus anterior or scapular flap or it can be raised up with overlying skin paddles when the soft tissue is deformed (145,146). LD is supplied by thoracodorsal artery and single vein that have multiple secondary branches into the muscle. Flap has a long neurovascular pedicle that allows a single-stage procedure and larger choice of recipient vessels (147,148). In comparison to gracilis flap, LD has no considerable difference in acquired smile function and represents a better option than gracilis muscle after ablative parotid surgery for the reconstruction of facial paralysis (145). Advantage of this flap is also minimal donor site morbidity and straightforward harvest of the flap. Latissimus can be split into 4 to 6 smaller segments used as independent functional units to the face (148).

As the patient is positioned supine, the incision is made over the anterior border of the LD muscle or along the anterior axillary line. Either lateral or medial branch of the thoracodorsal artery to the muscle can be used for harvest and the average length of pedicle is 8 to 12 cm. Thoracodorsal nerve combines with the pedicle at the entrance to the muscle and there it divides to lateral and medial branch from which 8 to 12 cm can be harvested (150). Usually 3-4 cm wide and 8-10 cm muscle segment is required. LD is thinned if the thickness is more than 1 cm, to avoid bulkiness of the cheek (151). LD flap can be hard to harvest in larger patients and there can be positioning difficulties of the patient (149). Muscle segment is directly transferred to the face (151). Thoracodorsal nerve is first passed through the tunnel to midway tied to the guide. Proximal end of the muscle is pushed toward the nasolabial fold line simultaneously with pulling of thoracodorsal nerve. Proximal end of muscle is fixed to the nasolabial fold line, thoracodorsal vessels are anastomosed by end-to-end fashion, and thoracodorsal nerve is sutured to fitting facial nerve branch under the microscopy. After excess amount of the transferred muscle is cut, distal end is fixed to the zygomatic arch (151). In the middle-aged man patients, who have heavy and fatty cheeks, power produced by the one-stage LD transfer can be weak. Because of that ipsilateral trigeminal nerve could be better than the contralateral facial nerve branch (151).

2.2.2.2.8 PECTORALIS MINOR

Pectoralis minor is a pyramidal, flat, thin muscle with dual nerve supply (152) that arises from the third to fifth costochondral surface and is inserted in the coracoid process of the scapula (153). PM is located deep and has complex and short neurovascular anatomy. Muscle has vascular supply from axillary artery, lateral thoracic, or the acromiothoracic vessels and nerve supply from medial and lateral branches of the pectoral nerve (152,153). Procedure is done in two stages. In the first stage sural nerve is harvested as a nerve graft and sutured to suitable buccal branch of the facial nerve. The second stage is done after 6 to 36 months. In between axonal regeneration is monitored by Tinel sign (154). In second stage the patient is put in the supine position and the ipsilateral upper extremity is in abducted position to 90°. The incision is made few centimeters posterior to landmark from the level of the coracoid process of scapula to the fifth rib (154). Then PM is harvest and care should be taken

not to injure the intercostobrachial nerve. Neurovascular pedicle is exposed by dividing tendinous insertion and flipping muscle onto itself (149). There are variable 3 dominant vessels and decision is made intraoperatively to include the largest vessel with the flap (155). For venous anastomosis to the facial vein, vein that bleeds most is chosen (149). The lateral and medial pectoral nerves are also identified on the undersurface of the muscle (156). Origin of the PM should be released before cutting the pedicle (152). To approach the paralyzed side of the face, an extended parotidectomy is used (154). 3 slips of muscle are secured to commissure and lower lip, upper lip and nasolabial fold, and to alar base (152). The cross-facial nerve graft is repaired to the nerves supplying the pectoralis minor and hilar vessels are anastomosed to facial artery and vein (154). Because of small size muscle does not need a lot of reduction and has good tendinous insertions. Because its function is relatively unimportant, its removal does not cause donor side morbidity (157).

2.2.2.2.9 RECTUS ABDOMINIS

Rectus abdominis has anatomically reliable vascular supply from deep superior and inferior epigastric system (158) with pedicle length of 6 to 10 cm. It is innervated segmentally from lower intercostal nerves, which can be anastomose to more than 1 branch of the contralateral facial nerve. The length of the nerves is up to 15 cm (159). Operation can be done in single-stage. Rectus abdominis is small enough to replace the intrinsic facial muscles and has enough mass to tolerate loss of function and provide enough contractility (158,160). Contralateral muscle of side of facial paralysis is used, so that deep inferior epigastric artery and its vein is positioned immediately to the facial artery and vein when flap is inserted (160). The incision is made directly on the linea alba and around umbilicus. Anterior rectus is incised longitudinally in the paramedian plane and then dissected off the underlying muscle with its tendinous inscriptions (149). Usually deep inferior epigastric artery is used because of easy dissection, length up to 15 cm, and consistent diameter (158). It is found by retracting medially the lateral border of the muscle. Along the lateral border of muscle 2 or 3 thoracoabdominal nerves can be identified. Origin of the muscle from pubic symphysis is released before clamping the pedicle (149).

3.CONCLUSSION

Facial paralysis is a condition that causes serious esthetic, functional, and psychosocial problems. Social interaction is compromised by disruption of facial expression and emotion and this adversely affects quality of life (161). There are many causes of facial palsy, from which Bell palsy is the most common, pursued by benign or malignant tumors, iatrogenic injury, Varicella-zoster virus-associated facial palsy, trauma and congenital palsy (162). The goal of facial palsy treatment is to restore facial symmetry and movement. Static techniques improve facial resting look but lack true reanimation. To chose appropriate dynamic technique, understanding of the mechanism and extent of facial injury, variability of musculature, the duration of palsy, and age, overall health, goals, and motivation of patient is essential. The holistic approach tends to yield more effective results. (163). Primary facial nerve repair produces the best results where it is possible. A nerve interposition graft, when tension-free primary repair is not possible is the next best choice (164). When proximal facial nerve stump is not available but native muscles remain viable for reinnervation, nerve transfer using a new motor nerve (motor nerve to masseter muscle and hypoglossal nerve) is an option (71). When native muscles are irreversibly paralyzed or congenitally absent, regional muscle transfer or free muscle transfer can be used. Physical therapy, nonsurgical procedures, and static suspension techniques can be used as adjuvant therapy or as a primary treatment for some patients (71).

Timing of the nerve repair is clear when facial nerve is interrupted. Immediate repair with tension-free primary repair or interposition grafting is recommended. The timing is not clear when facial nerve is anatomically continued. Period of 1 year is traditionally recommended, if there is a potential of recovery. This approach can delay recovery in patients, who do not recover spontaneously (165). Rivas et al. found out that early reinnervation should be considered if a patient with anatomically intact facial nerve and HB grade V to VI after 6 months show no improvement of at least one HB grade (166).

In dynamic facial reanimation most commonly used donor nerves are the masseteric nerve, contralateral facial nerve, and hypoglossal nerve. Phrenic, accessory, and C4 and C' root nerves can also be used (76). Cross-facial nerve graft (CFNG) first introduced

by Scaramella (10) and Smith (11) is the only procedure capable of producing a truly spontaneous smile with improvement of resting tone. Spira (167) reported first in 1978 use of the motor nerve to the masseter for facial reanimation. Both of procedures have their advantages and disadvantages. Classic hypoglossal nerve transfer is no longer in favor because of significant donor site morbidity (168). Many modifications of this technique have developed with less donor morbidity. When use of CFNG is desired, dual innervation or babysitter procedure can be done. First this kind of procedure was described by Terzis in 1988 (169). Mini-hypoglossal nerve transfer or masseteric nerve can be used. Regional muscle transfer is still one of the options for long-standing, irreversible paralysis. Temporalis muscle transfer is mainly used for the smile reanimation. Sometimes masseter muscle is also used alone or in the combination with the temporalis. For the lower lip, anterior belly of the digastric muscle can be transferred (170). Erni et al (171) reported that there is no difference at rest between temporalis tendon transfer (T3) and free muscle transfer, but oral commissure excursion was significantly better after free muscle transfer. The advantage of T3 is shorter postoperative recovery, early dynamic movements, immediate improvement in symmetry and no additional bulk. Nevertheless, the degree of movement is less than that achieved with free muscle transfer. The disadvantage of free muscle transfer is that it is more complicated, results are delayed, and there may be additional bulk (171).

As mentioned above, many muscles can be used for free muscle transfer, but gracilis muscle is the most commonly used. Harii (14) first reported use of free functional gracilis muscle transfer. The procedure may be performed in either 1 or 2 stages. In single-staged transfer masseteric nerve is most commonly used as a donor nerve. In 2-stage procedure free muscle transfer with CFNG is performed. 1-stage procedure has shorter recovery time and less number of surgical procedures, but 2-staged CFNG currently prevails because is more predictable (71). Some experts recommend the 2-staged approach with CFNG innervation for all younger than 18 years and 1-stage procedure with masseteric innervation for adults older than 30 years (172).

4.ACKNOWLEDGEMENTS

First, I would like to express deep and sincere gratitude to my mentor Professor Dr. Davor Mijatović and rest of the committee (doc.dr. sc. Krešimir Bulić and Prof. dr. sc. Ervina Bilić), which gave me the idea of this topic and provided proficiency, qualitative feedback.

Besides, I would also like to thank Zagreb University, School of Medicine, who gave me the opportunity to pursue medical studies and who is providing me with medical knowledge.

At least, I would like to thank my parents for all the support they have me through medical school.

5. REFERENCES

1. van de Graaf RC, Nicolai JP. Bell's palsy before Bell: Cornelis Stalpart van der Wiel's observation of Bell's palsy in 1683. *Otol Neurotol* 2005;26:1235-1238.
2. Bell C. On the nerves, giving an account of some experiments on their structure and functions, which leads to a new arrangement of the system. *Trans R Soc Lond* 1821;3:398
3. Ghali S, MacQuillan A, Grobbelaar AO. Reanimation of the middle and lower face in facial paralysis: review of the literature and personal approach. *J Plast Reconstr Aesthet Surg* 2011;64:423-431.
4. van de Graaf RC, Nicolai JP. Was Thomasz Drobnik really the first to operate on the facial nerve? *Otol Neurotol* 2003;24:686-690.
5. Sawicki B. In: Chepault. *The Status of Neurosurgery*. Paris: J Reuff; 1902. p. 189.
6. Korte W. Ein Fall von Nerven Fropfung: des Nervus facialis auf den Nervus hypoglossus. *Dtsch Med Wochenschr* 1903;29:293-295.
7. Lexer E, Eden R. Uber die chirurgische Behandlung der peripherin Facialislaehmung. *Beitr Klin Chir* 1911;73:116-126.
8. Gillies H. Experiences with fascia lata grafts in the operative treatment of facial paralysis. *Proc R Soc Med* 1934;27:1372-1382.
9. McLaughlin CR. Surgical support in permanent facial paralysis. *Plast Reconstr Surg* 1953(1946);11:302-314.
10. Scaramella LF. Anastomosis between the two facial nerves. *Laryngoscope* 1975;85:1359-1366.
11. Smith JW. A new technique of facial animation. In: Hueston JH, editor. *Transactions of the Fifth International Congress of Plastic and Reconstructive Surgery*. Chatswood. New South Wales, Australia, 1971. London: Butterworths; 1971. p. 83-4.
12. Anderl H. Reconstruction of the face through cross-face nerve transplantation in facial paralysis. *Eur J Plast Surg* 1973;2:17-45.
13. Thompson N. Autogenous free grafts of skeletal muscle. A preliminary experimental and clinical study. *Plast Reconstr Surg* 1971;48:11-27.
14. Harii K, Ohmori K, Torii S. Free gracilis muscle transplantation, with microneurovascular anastomoses for the treatment of facial paralysis. A preliminary report. *Plast Reconstr Surg* 1976;57:133-143.

15. Thompson N, Gustavson E. The use of neuromuscular free autograft with microneural anastomosis to restore elevation to the paralyzed angle of the mouth in cases of unilateral facial paralysis. *Eur J Plast Surg* 1976;3:165-74.
16. Terzis JK, Manktelow RT. Pectoralis minor: a new concept in facial reanimation. *Plast Surg Forum* 1982;69:760-9.
17. Nakajima H. One-stage reconstruction of facial paralysis using the rhomboideus major muscle. Presented at the 12th Local Meeting of the Tokyo District of the Japanese Society of Plastic and Reconstructive Surgery, Tokyo, Japan, April 1986.
18. O'Brien BM. One-stage reconstruction of facial paralysis using the gracilis muscle transfer. Presented at the 10th Symposium of the International Society of Reconstructive Microsurgery, Munich, Germany, Sept. 1991.
19. Jiang H, Kuo ET. One-stage reconstruction of facial paralysis using the abductor hallucis muscle. Presented at the Third Joint Meeting of Chinese and Japanese Plastic and Reconstructive Surgery, Shanghai City, China, Oct. 1991.
20. Koshima I, Moriguchi T, Soeda S, et al. Free rectus femoris muscle transfer for one-stage reconstruction of establishing facial paralysis. *Plast Reconstr Surg* 1994;94:421-430.
21. Mehta, R. Surgical Treatment of Facial Paralysis. *Clinical and Experimental Otorhinolaryngology* 2009;2(1):1.
22. Sainsbury D, Borschel G, Zuker R. Surgical Reanimation Techniques for Facial Palsy/Paralysis [Internet]. *Vula.uct.ac.za*. 2020 [cited 16 January 2020]. Available from: https://vula.uct.ac.za/access/content/group/ba5fb1bd-be95-48e5-81be-586fbaeba29d/Surgical%20reanimation%20techniques%20for%20facial%20palsy%200_paralysis.pdf
23. Kosin A, Hurvitz KA, Evans GRD, et al. Facial Paralysis for the Plastic Surgeon. *Can J Plast Surg* 2007;15:77-82.
24. House JW, Brackmann DE. Facial nerve grading system. *Otolaryngol Head Neck Surg* 1985;93:146–147.
25. Meng-yao, Z., Guo-dong, F. and Zhi-qiang, G. Facial Grading System: Physical and Psychological Impairments to Be Considered. *Journal of Otology* 2008; 3(2):61-67.
26. Kang TS, Vrabec JT, Giddings N, et al. Facial nerve grading systems (1985-2002): beyond the House-Brackmann scale. *Otol Neurotol* 2002;23:767–771.
27. Burres S, Fisch U. The comparison of facial grading systems. *Arch Otolaryngol Head Neck Surg*. 1986; 112(7):755-758.
28. Murty GE, Diver JP, Kelly PJ et al. The Nottingham system: Objective assessment of facial nerve function in the clinic. *Otolaryngol Head Neck Surg*. 1994; 110(2): 156-161.

29. Ross BG, Fradet G, Nedzelski JM. Development of a sensitive clinical facial grading system. *Otolaryngol Head Neck Surg* 1996;114:380–386.
30. Vrabc JT, Backous DD, Djalilian HR, et al. Facial nerve grading system 2.0. *Otolaryngol Head Neck Surg* 2009;140:445–450.
31. Banks CA, Bhama PK, Park J, et al. Clinician-graded electronic facial paralysis assessment: the eFACE. *Plast Reconstr Surg* 2015;136:223e–230e.
32. Kahn JB, Gliklich RE, Boyev KP, et al. Validation of a patient-graded instrument for facial nerve paralysis: the FaCE scale. *Laryngoscope* 2001;111:387–398.
33. VanSwearingen JM, Brach JS. The facial disability index: reliability and validity of a disability assessment instrument for disorders of the facial neuromuscular system. *Phys Ther* 1996;76:1288–1298.
34. Johnson PC, Brown H, Kuzon WM Jr et al. Simultaneous quantitation of facial movements: the maximal static response assay of facial nerve function. *Ann Plast Surg*. 1994;32(2): 171-179.
35. Meier-Gallati V, Scriba H, Fisch U. Objective Scaling of Facial Nerve Function Based on Area Analysis (OSCAR). *Otolaryngol Head Neck Surg*. 1998; 118(4): 545-550.
36. Yuen K, Inokuchi I, Maeta M et al. Evaluation of facial palsy by moiré topography index. *Otolaryngol Head Neck Surg*. 1997;117(5): 567-572.
37. Goldenberg D, Goldstein B. *Handbook of Otolaryngology-Head and Neck Surgery*. Thieme Medical Publishers; 2011;620-626
38. Chu EA, Byrne PJ: Treatment considerations in facial paralysis. *Facial Plast Surg* 2011;24:164.
39. Liu YM, Sherris DA: Static procedures for the management of the midface and lower face. *Facial Plast Surg* 2008;24:211.
40. Brooks DN, Weber RV, Chao JD, et al. Processed nerve allografts for peripheral nerve reconstruction: a multicentre study of utilization and outcomes-in sensory, mixed, and motor nerve reconstruction. *Microsurgery* 2012; 32:1-14.
41. Rajak, S. Performing a tarsorrhaphy. *Community Eye Health Journal* 2015;28(89):10-11.
42. McLaughlin CR. Epiphora in facial paralysis. *Bt J Plast Surg* 1950-1;3:87-95.
43. Ali, R., Lee, M., Massry, G. and Azizzadeh, B. Facial Paralysis Reconstruction. *Otolaryngol Clin N Am* 2016;49:459-473.
44. Razfar A, Afifi AM, Mancers EK, et al. Ocular outcomes after gold weight placement and facial nerve resection. *Otolaryngol Head Neck Surg* 2009; 140(1):82-85.

45. Becker FF. Lateral tarsal strip procedure for the correction of paralytic ectropion. *Laryngoscope* 1982;92(4):382-4.
46. Golio D, De Martelaere S, Anderson J, et al. Outcomes of periocular reconstruction for facial nerve paralysis in cancer patients. *Plast Reconstr Surg* 2007; 119(4):1233-7.
47. Oliver JM. Raising the subocularis oculi fat (SOOF): its role in chronic facial palsy. *Br J Ophthalmol* 2000;84(12):1401-6
48. Azuma, R., Aoki, S., Aizawa, T., Kuwabara, M. and Kiyosawa, T. The vertical orbicularis oculi muscle turn-over procedure for the correction of paralytic ectropion of the lower eyelid. *Archives of Plastic Surgery* 2018;45(2):135-139.
49. Baek, S., Chung, J., Yoon, E., Lee, B. and Park, S. Algorithm for the management of ectropion through medial and lateral canthopexy. *Archives of Plastic Surgery* 2018;45(6):525-533.
50. Antonyshyn OM, Weinberg MJ, Dagum AB. Use of new anchoring device for tendon reinsertion in medial canthopexy. *Plast Reconstr Surg* 1996;98:520-523.
51. Krastinova D, Franchi G, Kelly MB, et al. Rehabilitation of the paralysed or lax lower eyelid using a graft of conchal cartilage, *Br J Plast Surg* 2002;55(1):12-19.
52. Li TG, Shorr N, Goldberg RA. Comparison of the efficiency of hard palate grafts with acellular human dermis grafts in lower eyelid surgery. *Plast Reconstr Surg* 2005;116(3):873-878 [discussion: 879-80].
53. Marks MW, Argenta LC, Friedman RJ, et al. Conchal cartilage and composite grafts for correction of lower lid retraction. *Plast Reconstr Surg* 1989;83(4):629-635.
54. Patel MP, Shapiro MD, Spinelli HM. Combined hard palate spacer graft, midface suspension, and lateral canthoplasty for lower eyelid retraction: a tripartite approach. *Plast Reconstr Surg* 2005;115(7):2105-2114 [discussion: 2115-7].
55. Sufyan, A., Lee, H., Shah, H., Nunery, W., Kokoska, M. and Shipchandler, T. Single-Stage Repair of Paralytic Ectropion Using a Novel Modification of the Tarsoconjunctival Flap. *JAMA Facial Plastic Surgery* 2014;16(2):151.
56. Jobe RP. A technique for lid loading in the management of the lagophthalmos of facial palsy. *Plast Reconstr Surg* 1974;53:29-32.
57. Silver AL, Lindsay RW, Cheney ML, et al. Thin-profile platinum eyelid weighting: a superior option in the paralyzed eye. *Plst Reconstr Surg* 2009;123(6):1697-1703.
58. Henstrom DK, Lindsay RW, Cheney ML, et al. Surgical treatment of the periocular complex and improvement of quality of life in patients with facial paralysis. *Arch Facial Plast Surg* 2011;13(2):125-128.
59. Berghaus A, Neumann K, Schrom T. The platinum chain: a new upper-lid implant for facial palsy. *Arch Facial Plast Surg* 2003;5(2):166-170.

60. Yu Y, Sun J, Chen L, et al. Lid loading for treatment of paralytic lagophthalmos. *Aesthetic Plast Surg* 2011;35(6):1165-1671.
61. Bergeron CM, Moe KS. The evaluation and treatment of upper eyelid paralysis. *Facial Plast Surg*. 2008;24(2):220-230.
62. Hadlock TA, Greenfield LJ, Wernick-Robinson M, Cheney ML. Multimodality approach to management of the paralyzed face. *Laryngoscope* 2006 Aug;116(8):1385-1389.
63. Metzler NE, Byrne PJ. Management of the brow in facial paralysis. *Facial Plast Surg* 2008 May;24(2):216-219.
64. Angelos PC, Stallworth CL, Wang TD. Forehead lifting: state of art. *Facial Plast Surg* 2011;27(1):50-57.
65. Rautio J, Pignatti M. Endoscopic forehead lift for ptosis of brow caused by facial paralysis. *Stand J Plast Reconstr Surg Hand Surg* 2001;35(1):51-56.
66. Lemound J, Stoetzer M, Kokemuller H, Schumann P, Gellrich NC. Modified technique for rehabilitation of fascial paralysis using autogenous fascia lata grafts. *J Oral Maxillofac Surg* 2015;73:176-183.
67. Moser G, Oberascher G: Reanimation of paralyzed face with new gold weight implants and Goretex soft-tissue patches. *Eur Arch Otolaryngology* 254(Suppl 1);S76, 1997.
68. Skourtis ME, Weber SM, Kriet JD, et al: Immediate Gore-Tex sling suspension for management of facial paralysis in head and neck extirpative surgery. *Otolaryngol Head Neck Surg* 2007;137:228.
69. Citarella ER, Sterodimas A, Green AC, et al: Use of triple-convergence polypropylene thread for the aesthetic correction of partial facial paralysis. *Aesthetic Plast Surg* 2008;32:688.
70. Terzis JK, Kyere SA. Minitendon graft transfer for suspension of the paralyzed lower eyelid: our experience. *Plast Reconstr Surg* 2008;121:1206-1216.
71. Kim, L. and Byrne, P. Controversies in Contemporary Facial Reanimation. *Facial Plastic Surgery Clinics of North America* 2016;24(3):275-297.
72. Gao, Z., Jia, X., Xu, J., Yu, J., Wang, J., Zhao, W., Chi, F., Dai, C., Li, H., Zhong, P., Chen, B. and Yuan, Y. Neurotomy for Facial Reanimation with Interpositional Graft: Outcome in 23 Patients and the Impact of Timing on the Outcome. *World Neurosurgery* 2019;126:e688-e693.
73. Andersen D, Billiar T, Brunnicardi F, Dunn D, Hunter J, Matthews J et al. *Schwartz's principles of surgery*. 10th ed. McGraw-Hill Education; 2015;1865-1866.
74. Mark M, Barry MS. *Facial Paralysis: Rehabilitation Techniques*. New York: Theme; 2003.

75. Rovak J, Tung T, Mackinnon S. The Surgical Management of Facial Nerve Injury. *Seminars in Plastic Surgery*. 2004;18(1):23-29.
76. Terzis JK, Konofaos P. Nerve transfers in facial palsy. *Facial Plast Surg*. 2008;24(2):177-210.
77. Klebuc, M. and Shenaq, S. Donor Nerve Selection in Facial Reanimation Surgery. *Seminars in Plastic Surgery* 2004;18(1):53-59.
78. Endo T, Hata J, Nakayama Y. Variations on the »baby-sitter« procedure for reconstruction of facial paralysis. *J Reconstr Microsurg* 2000;16:37-43.
79. Jeong, J., Almansoori, A., Park, H., Byun, S., Min, S., Choung, H., Park, J., Choi, S., Kim, B., Kim, S. and Lee, J. Per-oral cross-facial sural nerve graft for facial reanimation. *Maxillofacial Plastic and Reconstructive Surgery* 2018;40(1).
80. Ricciardi, L., Stifano, V., Pucci, R., Stumpo, V., Montano, N., Della Monaca, M., Lauretti, L., Olivi, A., Valentini, V. and Sturiale, C. Comparison between VII-to-VII and XII-to-VII coaptation techniques for early facial nerve reanimation after surgical intra-cranial injuries: a systematic review and pooled analysis of the functional outcomes. *Neurosurgical Review* 2020.
81. Hadlock TA, Cheney ML, McKenna MJ. Facial reanimation surgery. In: Nabol JB Jr, McKenna MJ, editors. *Surgery of the ear and temporal cone*. Philadelphia (PA): Lippicott Williams and Wilkins; 2005:461-72.
82. Asaoka K, Sawamura Y, Nagashima M, Fukushima T: Surgical anatomy for direct hypoglossal-facial nerve side-to-end “anastomosis”. *J Neurosurg* 1995;91:268-275.
83. Hayashi A, Nishida M, Seno H, Inoue M, Iwata H, Shirasawa T et al. Hemihypoglossal nerve transfer for acute facial paralysis. *Journal of Neurosurgery*. 2013;118(1):160-166.
84. May M, Sobol SM, Mester SJ: Hypoglossal-facial nerve interpositional-jump graft for facial reanimation without tongue atrophy. *Otolaryngol Head Neck Surg* 1991;104:818-825.
85. Sawamura Y, Abe H: Hypoglossal-facial nerve side-to-end anastomosis for preservation of hypoglossal function: results of delayed treatment with a new technique. *J Neurosurg* 1997;86:203-206.
86. May M. Nerve substitution techniques: XII-VII hook-up, XII-VII jump graft and cross-face graft. In: May M, ed. *The Facial Nerve*. May’s 2nd ed. New York: Thieme Medical Publisher; 2000:611-633.
87. Conley J. Hypoglossal crossover-122 cases. *Trans Am Acad Ophthalmol Otolaryngol* 1977;84:763-768.
88. Tanbouzi Husseini S, Kumar D, De Donato G, Almutair T, Sanna M. Facial Reanimation After Facial Nerve Injury Using Hypoglossal to Facial Nerve

- Anastomosis: The Gruppo Otorologico Experience. *Indian Journal of Otolaryngology and Head & Neck Surgery*. 2012;65(4):305-308.
89. Clemis JD, Gavron JP (1982) Hypoglossal-facial nerve anastomosis: report on 36 cases with posterior fossa facial paralysis. In: Graham MD, House WF(eds) *Disorders of the facial nerve*. Raven, New York:499-505.
 90. Hontanilla B, Marre D. Masseteric-facial nerve transposition for reanimation of the smile in incomplete facial paralysis. *British Journal of Oral and Maxillofacial Surgery*. 2015;53(10):943-948.
 91. Jørgensen BG, Pedersen CB. Acoustic neuroma. Follow-up of 78 patients. *Clin Otolaryngol Alliee Sci* 1994;19:478-484.
 92. Griebie MS, Huff JS. Selective role of partial XI-VII anastomosis in facial reanimation. *Laryngoscope* 1998;108:1664-1668.
 93. Perret G. Results of phrenicofacial nerve anastomosis for facial paralysis. *Arch Surg* 1967;94:505-508.
 94. Fackler CD, Perret Ge, Bedell GN. Effect of unilateral phrenic nerve section on lung function. *J Appl Physiol* 1967;23:923-926.
 95. Mahan M, Sivakumar W, Weingarten D, Brown J. Deep Temporal Nerve Transfer for Facial Reanimation: Anatomic Dissections and Surgical Case Report. *Operative Neurosurgery*. 2017;15(1):81-88.
 96. Mani V, Panda AK. Versality of temporalis myofascial flap in maxillofacial reconstruction. Analysis of 30 cases. *Int J Oral Maxillofac Surg* 2003;30:189-193.
 97. Biglioli F. Facial reanimations: part II—long-standing paralyses. *British Journal of Oral and Maxillofacial Surgery*. 2015;53(10):907-912.
 98. Bajpai H, Saikrishna D. The Versatility of Temporalis Myofascial Flap in Maxillo-Facial Reconstruction: A Clinical Study. *Journal of Maxillofacial and Oral Surgery*. 2011;10(1):25-31.
 99. Koranda FC, McMohan MF, Jernstrom VR. The temporalis muscle flap for intra oral reconstruction. *Arch Otolaryngol Head Neck Surg* 1987;113:740-743.
 100. Su Gwan K. Treatment of temporomandibular joint ankylosis with temporalis muscle and fascia flap. *Int J Oral Maxillofac Surg* 2001;30:189-193.
 101. Balaji SM. Modified temporalis anchorage in craniomandibular reankylosis. *Int. J. Oral Maxillofac Surg* 2003;32:480-485.
 102. Singha S, Dhirawani R, Balaji S, Agrawal A. Temporalis muscle transfer with fascia lata sling: A novel technique for facial reanimation. *Annals of Maxillofacial Surgery*. 2018;8(2):307.

103. Volk GF, Pantel M, Guntinas-Livhius O. Modern concepts in facial nerve reconstruction. *Head Face Med* 2010;6:25
104. Balaji S. Temporalis pull-through vs fascia lata augmentation in facial reanimation for facial paralysis. *Annals of Maxillofacial Surgery*. 2016;6(2):267.
105. Silan F, Consiglio F, Dell'Antonia F, Montagner G, Trojan D, Berna G. Cryopreserved fascia lata allograft use in surgical facial reanimation: a retrospective study of seven cases. *Maxillofacial Plastic and Reconstructive Surgery*. 2020;42(1).
106. Naugle TC. Complications of fascia lata harvesting for ptosis surgery. *Br J Ophthalmol* 1998;82:333-334.
107. Brichacek M, Sultan B, Boahene K, Ishii L, Byrne P. Objective Outcomes of Minimally Invasive Temporalis Tendon Transfer for Prolonged Complete Facial Paralysis. *Plastic Surgery*. 2017;25(3):200-210.
108. Boahene KD, Farrag TY, Ishii L, Byrne PJ. Minimally invasive temporalis tendon transposition. *Archives of facial plastic surgery*. 2011;13(1):8-13.
109. McLaughlin CR. Permanent facial paralysis; the role of surgical support. *Lancet*. 1952;2(6736):647-651.
110. Boahene KD. Dynamic muscle transfer in facial reanimation. *Facial Plast Surg*. 2008;24(2):204-210.
111. Shinohara H, Matsuo K, Osada Y, et al. Facial reanimation by transposition of the masseter muscle combined with tensor fascia lata, using the zygomatic arch as a pulley. *Scand J Plast Reconstr Surg Hand Surg*. 2008;42:17-22.
112. Sachs ME, Conley J. Intraoral masseter muscle transposition: use with reconstruction of regional facial paralysis. *Arch Otolaryngol* 1982;108:397-400.
113. Abbasi R. Facial Reanimation by Masseteric Muscle-Mandibular Periosteum Transfer. *World J Plast Surg* 2013;2(1):44-46.
114. Lesavoy M, Fan K, Goldberg A, Dickinson B, Herrera F. Facial Reanimation by Staged, Split Masseter Muscle Transfer. *Annals of Plastic Surgery*. 2014;73(1):33-38.
115. Gousheh J, Arasteh E. Treatment of facial paralysis: dynamic reanimation of spontaneous facial expression-apropos of 655 patients. *Plast Reconstr Surg*. 2011;128:693e-703e.
116. Hadlock TA, Malo JS, Cheney ML, et al. Free gracilis transfer for smile in children: the Massachusetts eye and ear infirmary experience in excursion and quality-of-life changes. *Arch Facial Plast Surg*. 2011;13:190-194.
117. Doménech Juan I, Tornero J, Cruz Toro P, Ortiz Laredo N, Vega Celiz J, Junyent J et al. Facial Reanimation Surgery With Micro-vascular Gracilis Free Flap

- for Unilateral Facial Palsy. *Acta Otorrinolaringologica (English Edition)*. 2014;65(2):69-75.
118. Baccarani A, Starnoni M, Zaccaria G, Anesi A, Benanti E, Spaggiari A et al. Obturator Nerve Split for Gracilis Free-flap Double Reinnervation in Facial Paralysis. *Plastic and Reconstructive Surgery - Global Open*. 2019;7(6):e2106.
 119. Manktelow RT, Tomat LR, Zuker RM, Chang M. Smile reconstruction in adults with free muscle transfer innervated by the masseter motor nerve: effectiveness and cerebral adaptation. *Plast Reconstr Surg*. 2006;118:885-899.
 120. Faria JC, Scopel GP, Busnardo FF, et al. Nerve sources for facial reanimation with muscle transplant in patients with unilateral facial palsy: clinical analysis of 3 techniques. *Ann Plast Surg* 2007;59:87-91.
 121. Biglioli F, Colombo V, Tarabbia F, et al. Double innervation in free-flap surgery for long-standing paralysis. *J Plast Reconstr Aesthet Surg* 2012;65:1343-1349.
 122. Cardenas-Mejia A, Covarrubias-Ramirez JV, Bello-Margolis A, et al. Double innervated free functional muscle transfer for facial reanimation. *J Plast Surg Hand Surg* 2015;49:183-188.
 123. Lee KK, Terzis JK. Reanimation of the eye sphincter. In: Portmann M, ed. *Proceedings of the Fifth International Symposium on the Facial Nerve, Bordeaux, FRANCE; September 3-6, 1984*. New York: Masson Publishing; 1985:119-131.
 124. Goodmurphy CW, Ovalle WK. Morphological study of two human facial muscles: orbicularis oculi and corrugator supercilia. *Clin Anat*. 1999;12:1-11.
 125. Guelinckx P. Blink Restoration in Long-standing Facial Paralysis: Use of Free Neurovascular Platysma Transfer. *Plastic and Reconstructive Surgery - Global Open*. 2018;6(10):e1939.
 126. Biglioli F, Zago M, Allevi F, Ciprandi D, Dell'Aversana Orabona G, Pucciarelli V et al. Reanimation of the paralyzed lids by cross-face nerve graft and platysma transfer. *Journal of Cranio-Maxillofacial Surgery*. 2018;46(3):521-526.
 127. Alam D. The Sternohyoid Flap for Facial Reanimation. *Facial Plastic Surgery Clinics of North America*. 2016;24(1):61-69.
 128. Alagöz MS, Alagöz AN, Comert A: Neuroanatomy of extensor digitorum brevis muscle for reanimation of facial paralysis. *J Craniofac Surg* 2011;22:2308-2311.
 129. Pai CH, Lin GT, Lin SY, et al: Extensor digitorum brevis rotational muscle flap for lower leg and ankle coverage. *J Trauma* 2000;49:1012-1016.
 130. del Piñal F, Herrero F: Extensor digitorum brevis free flap: anatomic study and further clinical applications. *Plast Reconstr Surg* 2000;105:1347-1356.

131. Sugg K, Kim J. Dynamic reconstruction of the paralyzed face, part II: Extensor digitorum brevis, serratus anterior, and anterolateral thigh. *Operative Techniques in Otolaryngology-Head and Neck Surgery*. 2012;23(4):275-281.
132. le Nobel GJ, Higgins KM, Enepekides DJ: Predictors for complications of free flap reconstruction in head and neck surgery: analysis of 304 free flap reconstruction procedures. *Laryngoscope* 2012;122:1014-1019.
133. Takayanagi S, Ohtusak M, Tsukie T: Use of the latissimus dorsi and the serratus anterior muscle as a combined flap. *Ann Plast Surg* 1988;20:333-339.
134. Whitney TM, Buncke HJ, Alpert BS, et al: The serratus anterior free-muscle flap: experience with 100 consecutive cases. *Plst Reconstr Surg* 1990;86:481-490 [discussion 491].
135. Takayanagi S, Tsukie T: Free serratus anterior muscle and myocutaneous flaps. *Ann Plast Surg* 1982;8:277-283.
136. Vu P, Guedon C, Gehanno P, et al: Anatomic basis of serratus anterior muscle flap transposition. *Surg Radiol Anat* 1988;10:173-185.
137. Sakuma H, Tanaka I, Yazawa M, Shimizu Y. Multivector functioning muscle transfer using superficial subslips of the serratus anterior muscle for longstanding facial paralysis. *Journal of Plastic, Reconstructive & Aesthetic Surgery*. 2019;72(6):964-972.
138. Seth R, Manz RM, Dahan IJ, et al: Comprehensive analysis of the anterolateral thigh flap vascular anatomy. *Arch Facial Plast Surg* 2011;13:347-354.
139. Revenaugh PC, Knott PD, Scharpf J, et al: Simultaneous anterolateral thigh flap and temporalis tendon transfer to optimize facial form and function after radical parotidectomy. *Arch Facial Plast Surg* 2012;14:104-109.
140. Koshima I, Umeda N, Handa T, et al: A double-muscle transfer using a divided rectus femoris muscle for facial-paralysis reconstruction. *J Reconstr Microsurg* 1997;13:157-162.
141. Yu P: Characteristics of the anterolateral thigh flap in a western population and its application in head and neck reconstruction. *Head Neck* 2004;26:759-769.
142. Kuo YR, Seng-Feng J, Kuo FM, et al: Versatility of the free anterolateral thigh flap for reconstruction of soft-tissue defects: review of 140 cases. *Ann Plast Surg* 2002;48:161-166.
143. Nosrati N, Chao AH, Chang DW, et al: Lower extremity reconstruction with the anterolateral thigh flap. *J Reconstr Microsurg* 2012;28:227-234.
144. Celik N, Wei FC, Lin CH, et al: Technique and strategy in anterolateral thigh perforator flap surgery, based on an analysis of 15 complete and partial failures in 439 cases. *Plast Reconstr Surg* 2002;109:2211-2216 [discussion 2217-2218].

145. Takushima A, Harii K, Asato H, et al: One-stage reconstruction of facial paralysis associated with skin/soft tissue defects using latissimus dorsi compound flap. *J Plast Reconstr Aesthet Surg* 2006;59:465-473.
146. Takushima A, Harii K, Asato H, et al: Neurovascular free-muscle transfer for the treatment of established facial paralysis following ablative surgery in the parotid region. *Plast Reconstr Surg* 2004;113:1563-1572.
147. Biglioli F, Frigerio A, Rabbiosi D, et al: Single-stage facial reanimation in the surgical treatment of unilateral established facial paralysis. *Plast Reconstr Surg* 2009;124:124-133.
148. Wei W, Zuoliang Q, Xiaoxi L, et al: Free split and segmental latissimus dorsi muscle transfer in one stage for facial reanimation. *Plast Reconstr Surg* 1999;103:473-480.
149. Spector M, Kim J. The latissimus dorsi, pectoralis minor, and rectus abdominis free flaps for dynamic reconstruction of the paralyzed face. *Operative Techniques in Otolaryngology-Head and Neck Surgery*. 2012;23(4):268-274.
150. Wei F, Mardini S: *Flaps and Reconstructive Surgery*. Philadelphia,PA, Elsevier, 2009
151. Takushima A, Harii K, Asato H, Kurita M, Shiraishi T. Fifteen-year survey of one-stage latissimus dorsi muscle transfer for treatment of longstanding facial paralysis. *Journal of Plastic, Reconstructive & Aesthetic Surgery*. 2013;66(1):29-36.
152. Terzis JK: Pectoralis minor: a unique muscle for correction of facial palsy. *Plast Reconstr Surg* 1989;83:767-776.
153. Harrison DH: The pectoralis minor vascularized muscle graft for the treatment of unilateral facial palsy. *Plast Reconstr Surg* 1985;75:206-213.
154. Harrison D, Grobbelaar A. Pectoralis minor muscle transfer for unilateral facial palsy reanimation: An experience of 35 years and 637 cases. *Plast Reconstr Aesthet Surg* 2012;65:845-850.
155. MacQuillan A, Horlock N, Grobbelaar A, et al: Arterial and venous anatomical features of the pectoralis minor muscle flap pedicle. *Plast Reconstr Surg* 2004;113:872-876.
156. Scevola S, Cowan J, Harrison DH: Does the removal of pectoralis minor impair the function of pectoralis major? *Plast Reconstr Surg* 2003;112:1266-1273.
157. Takushima A, Harii K, Asato H, et al. Revisional operations improve results of neurovascular free muscle transfer for treatment of facial paralysis. *Plast Reconstr Surg* 2005;116(2):371-380.

158. Sajjadian A, Song AY, Khorsandi CA, et al: One-stage reanimation of the paralyzed face using the rectus abdominis neurovascular free flap. *Plast Reconstr Surg* 2006;117:1553-1559.
159. Koshima I, Tsuda K, Hamanaka T, et al: One-stage reconstruction of established facial paralysis using a rectus abdominis muscle transfer. *Plast Reconstr Surg* 1997;99:234-238.
160. Hata Y, Yano K, Matsuka K, et al: Treatment of chronic facial palsy by transplantation of the neurovascularized free rectus abdominis muscle. *Plast Reconstr Surg* 1990;86:1178-1187 [discussion 1188-1189].
161. Ishii LE, Godoy A, Encarnacion CO, et al. What faces reveal: impaired affect display in facial paralysis. *Laryngoscope* 2011;121:1138–1143.
162. Hohman MH, Hadlock TA. Etiology, diagnosis, and management of facial palsy: 2000 patients at a facial nerve center. *Laryngoscope* 2014;124:E283–293.
163. Boahene K, Byrne P, Schaitkin BM. Facial reanimation: discussion and debate. *Facial Plast Surg Clin North Am* 2012;20:383–402.
164. Malik TH, Kelly G, Ahmed A, et al. A comparison of surgical techniques used in dynamic reanimation of the paralyzed face. *Otol Neurotol* 2005;26:284–291.
165. Boahene K. Facial reanimation after acoustic neuroma resection: options and timing of intervention. *Facial Plast Surg* 2015;31:103–109.
166. Rivas A, Boahene KD, Bravo HC, et al. A model for early prediction of facial nerve recovery after vestibular schwannoma surgery. *Otol Neurotol* 2011;32:826–833.
167. Spira M. Anastomosis of the masseteric nerve to lower division of facial nerve for correction of lower facial paralysis. Preliminary report. *Plast Reconstr Surg* 1978;61:330–334.
168. Hammerschlag PE. Facial animation with jump interpositional graft hypoglossal facial anastomosis and hypoglossal facial anastomosis: evolution in management of facial paralysis. *Laryngoscope* 1999;109:1–23.
169. Terzis JK, Tzafetta K. The “babysitter” procedure: minihypoglossal to facial nerve transfer and crossfacial nerve grafting. *Plast Reconstr Surg* 2009;123:865–876.
170. Lindsay RW, Edwards C, Smitson C, et al. A systematic algorithm for the management of lower lip asymmetry. *Am J Otolaryngol* 2011;32:1–7.
171. Erni D, Lieger O, Banic A. Comparative objective and subjective analysis of temporalis tendon and microneurovascular transfer for facial reanimation. *Br J Plast Surg* 1999;52:167–172.
172. Garcia RM, Hadlock TA, Klebuc MJ, et al. Contemporary solutions for the treatment of facial nerve paralysis. *Plast Reconstr Surg* 2015;135:1025e–1046e.

6. BIOGRAPHY

Nika Kelc was born in Maribor, Slovenia on April 7th, 1995 as a daughter of Andrej Kelc (born 1958 in Maribor, Slovenia) and Silva Mlakar Kelc (born 1957 in Ptuj, Slovenia). Her father works as a surgeon in Maribor and her mother as a nurse. She is a second child in family preceded by her sister Tina Kelc (born 1991 in Maribor, Slovenia).

The author's interest for medicine developed after she finished her carrier in skiing. After finishing high school in 2014, she got accepted at the medical faculty at the medical faculty at the University of Zagreb. Besides her studies Nika Kelc would work as a skiing instructor in Maribor and during the summer holidays as a waitress. The main interest of the author in medicine lies in surgery. Throughout her medical studies, she has also been a part of rowing team at her university and went to a lot of competitions. In academic year 2017/2018 she got Dean's commendation for distinguished academic record.

Besides that Nika Kelc loves doing sport, especially skiing, and spending her time with family and friends. She speaks Slovenian, English and Croatian fluently and knows German.