

The role of 3D computing planning in maxillofacial surgery

Gecaj, Alban

Master's thesis / Diplomski rad

2022

Degree Grantor / Ustanova koja je dodijelila akademski / stručni stupanj: **University of Zagreb, School of Medicine / Sveučilište u Zagrebu, Medicinski fakultet**

Permanent link / Trajna poveznica: <https://um.nsk.hr/um:nbn:hr:105:595720>

Rights / Prava: [In copyright](#)/[Zaštićeno autorskim pravom.](#)

Download date / Datum preuzimanja: **2024-08-22**



Repository / Repozitorij:

[Dr Med - University of Zagreb School of Medicine Digital Repository](#)



UNIVERSITY OF ZAGREB SCHOOL OF MEDICINE

Alban Gecaj

**ROLE OF 3D COMPUTER PLANNING IN
MAXILLOFACIAL SURGERY**

GRADUATE THESIS



Zagreb, 2022

This graduate thesis was made at the Department of Maxillofacial Surgery, Dubrava University Hospital, and School of Medicine, Zagreb, Croatia, mentored by Assistant Professor Emil Dediol, MD, Ph.D., and was submitted for evaluation in the academic year of 2021/2022.

ABREVIATION

- VSP – Virtual Surgical Planning
- CAM – Computer assisted manufacturing
- CAD – Computer assisted design
- CAS – Computer assisted surgery
- UHD – University Hospital Dubrava
- CT - Computer Tomography
- CBCT - Cone Beam Computer Tomography
- PSI – Patient Specific Implant
- DCIA – Deep Circumflex Iliac Artery
- ALT – Anterolateral Thigh
- FFF – Free Fibula Flap
- RFFF – Radial Forearm Free Flap

Table of contents

ABSTRACT	5
SAŽETAK	6
INTRODUCTION	7
MAKING USE OF 3D COMPUTING TO FORMULATE A VSP	7
DATA ACQUISITION AND PROCESSING.....	9
VIRTUAL SURGICAL PLANNING.....	10
SURGERY WITH 3D COMPUTING	10
DEEP CIRCUMFLEX ILIAC ARTERY (DCIA) FLAPS	11
FREE FIBULA FLAPS (FFF)	11
RADIAL FOREARM FREE FLAP (RFFF)	11
ALT FLAPS.....	12
PATIENT SPECIFIC IMPLANTS	10
<i>Surgical splints</i>	10
<i>Titanium mesh</i>	10
<i>Reconstruction plates</i>	10
TEMPLATES.....	11
INTRAOPERATIVE NAVIGATION.....	11
MATERIAL AND METHODS	12
RESULTS	12
RECONSTRUCTION OF MANDIBLE WITH DCIA FLAP	12
RECONSTRUCTION OF MANDIBLE WITH FFF	12
RECONSTRUCTION OF THE MANDIBLE WITH RFFF	13
RECONSTRUCTION OF THE MAXILLA USING ALT FLAPS	14
RECONSTRUCTION OF THE MAXILLA USING DCIA FLAP, FFF OR RFFF.....	14
CORRECTION OF JAW DEFORMITIES.....	15
RECONSTRUCTION OF THE ORBIT	16
MISCELLANOUS INDICATIONS.....	18
DISCUSSION	19
CONCLUSION	22
ACKNOWLEDGMENT	23
REFERENCES	24
BIOGRAPHY	26

Abstract

Title: The role of 3D computing planning in maxillofacial surgery

Author: Alban Gecaj

The role of 3D computing in reconstructive surgery is still not clearly established, yet the advancements of virtual surgical planning (VSP) and its implementation for various indications is slowly elucidating its purpose.

VSP consist of multiple techniques which are being used to complement surgery in its planning stage as well as during it. Such techniques can be divided into computer assisted surgery (CAS), computer assisted design (CAD) and computer assisted manufacturing (CAM). Depending on the case there is a vast array of reconstruction methods that can be employed. Its usage depends on specifics of the case and the result of the VSP. The team UHD used titanium mesh and reconstruction plates, templates, intraoperative navigation, osteotomy guides as wells as flap guides for the different indications necessitating reconstructive surgery. Those indications are grouped into five categories: reconstruction of the mandible, reconstruction of the maxilla, correction of jaw deformities, reconstruction of the orbit and miscellaneous indications. The experienced benefits were, increased accuracy, decreased intraoperative time and overall increased satisfaction with the results due to the usage of 3D computing.

Keywords: VSP, CAS, CAD, CAM, reconstructive surgery, 3D planning

SAŽETAK

Naslov: Uloga 3D kompjuterskog planiranja u maksilofacijalnoj kirurgiji

Autor: Alban Gecaj

Uloga 3D kompjuterskog planiranja u rekonstruktivnoj kirurgiji još uvijek nije jasno utvrđena, ali napredak virtualnog kirurškog planiranja (VSP) i njegova implementacija za različite indikacije polako rasvjetljava njegovu svrhu.

VSP se sastoji od više tehnika koje se koriste kao dopuna kirurgiji u fazi planiranja kao i tijekom nje. Takve se tehnike mogu podijeliti na računalno potpomognutu kirurgiju (CAS), računalno potpomognuto projektiranje (CAD) i računalno potpomognutu proizvodnju (CAM). Ovisno o slučaju, postoji širok raspon metoda rekonstrukcije koje se mogu primijeniti. Njegova uporaba ovisi o specifičnostima slučaja i rezultatu VSP-a. Tim Kliničke bolnice Dubrava koristio je titansku mrežicu i rekonstruktivne titanske ploče, intraoperativnu navigaciju, razne vodilice za osteotomiju kao i vodilice za oblikovanje reznja. Te su indikacije grupirane u 5 kategorija: rekonstrukcija mandibule, rekonstrukcija maksile, korekcija deformiteta čeljusti, rekonstrukcija orbite i razne indikacije. Prednosti virtualnog kirurškog planiranja bile su povećana točnost, skraćeno intraoperativno vrijeme i ukupno povećano zadovoljstvo rezultatima zbog korištenja 3D kompjuterskog planiranja.

Ključne riječi: VSP, CAS, CAD, CAM, rekonstruktivna kirurgija, 3D planiranje

Introduction

The head and neck region is one of the most complex area in the human body. The proximity of structures to each other as well as the anatomic variability of them is increasing the difficulty and operative time of any head and neck surgery.

Furthermore, the visibility of the result dictates that the focus of the surgery needs to include aesthetics. The priority of the patient and surgeon shifts even further towards aesthetics in regard to reconstructive surgery because of the nature of its purpose.

The difficulty of it is being eased by 3D computing and virtual surgical planning (VSP). VSP diminish the guesswork during the surgery, reducing the intraoperative time and increases the precision of surgery(1) (2).

The old ways of planning surgeries are making ways for the computerized methods and new implementations of imaging techniques in this field are being produced. (3)

The usage of 3D computing and VSP is elucidating more and more its usefulness in this field.

This paper's purpose is to give an overview of the 3D computing methods that were used for the various indications and to establish a general role of the various techniques to their respective indications in regard to their benefits.

Making use of 3D computing to formulate a VSP

The first step in utilizing 3D computing for head and neck reconstructive surgeries is to formulate a VSP. Be it for the reconstruction of boney defect with a titanium mesh or the treatment of a defect with a free flap. The process is generally the same, yet it can differ in some nuances depending on the location of the hospital and their inner processing structures. In UHD the process was split into 3 steps as seen in Figure 1.

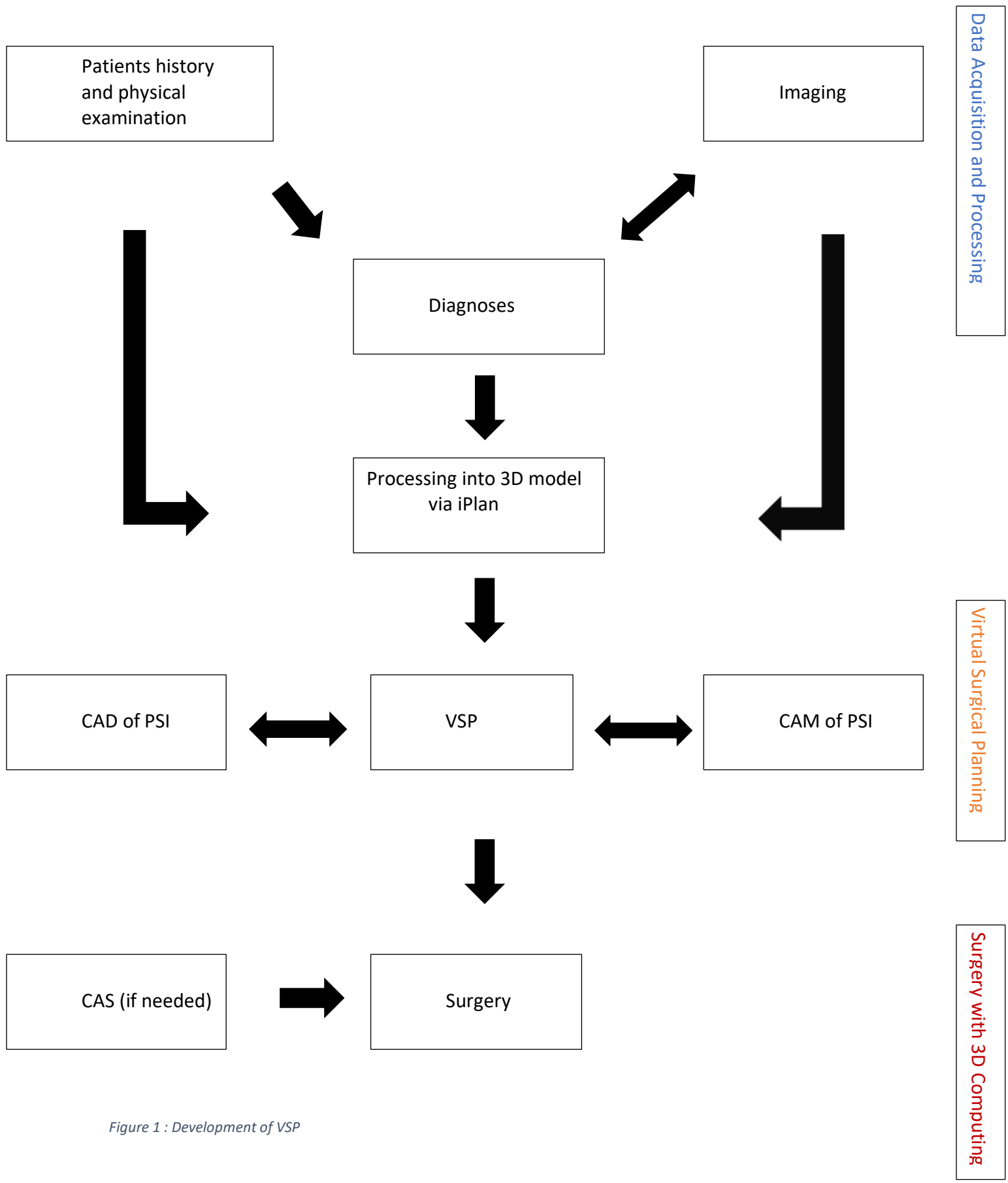


Figure 1 : Development of VSP

Data acquisition and processing

The information that is needed to formulate a VSP consist of the clinical examination, patient history and CT/MRI images. Depending on the habits of the hospital as well as the need of the case, there can be different imaging techniques employed. This step depends on the diagnosis. As soon as there is one, the next step is to initiate the VSP by understanding which imaging technique is needed for which of the surgeries that should be augmented with 3D computing.

Commonly what is being used for visualization are:

- Radiographs

Easily acquired, cost effective and the toxicity is low. Those 2D x-ray films can be the initial step in visualizing the head and neck. Radiographs provide 2D information about hard/soft tissue form and structure.

- 2D – Photographs

By far are the easiest information that can be acquired and the cheapest with no toxicity. Those images allow the assessment of the texture, form, color and defect of the skin as well as teeth and various other structures.

Furthermore, this technique allows to illustrate the result by showing the change before and after the surgery.

- CT/CBCT/MRI

Tomographic data from traditional CT scans or cone-beam provide a series of planar images that can be easily combined to produce a 3D image. The downside of CT and CBCT imaging is the exposure to radiation that the patient experience during the procedure. In this instance, CBCT scans are preferred over traditional CT scans due to their lower levels of exposure(3). CBCT scans are generally preferred over CT scans on bases of their toxicity, yet their image clarity is inferior to them. In contrast, MRI scans do not make use of ionizing radiation and therefore MRI scanning is usually the preferred imaging technique when the planning revolves around soft tissue. The issue with MRI's however is the difficulty for a patient to hold steady for the duration of the scan.

The resulting data is being collected and formatted into DICOM. As soon as all those data is acquired, they are used to create a 3D-Model. In UHD BrainLabs iPlan CMF program was used for the construction of every 3D model.

Virtual Surgical Planning

After the 3D model has been acquired the next step is to take all the information available and to formulate a plan to approach and perform the surgery.

The goal of this step is to come as close as the real surgery and be able to have a “game plan” beforehand. Data such as volume of the defect, anatomy of the defect and harvest area, accessibility of the area, the need of area exposure are evaluated to choose the best reconstruction method and increase the probability of success for the surgery.

The last step of VSP is to manufacture and design the needed patient specific implants (PSI). The needed implant is designed, and 3D printed from the mirrored area of the not affected portion – e.g., orbit. This process is being called computer assisted manufacturing after the computer assisted design has been completed – short CAM and CAD respectively. For the surgeries the following PSIs were produced: surgical splints, mesh, 3D templates as well as reconstruction plates.

In UHD, the usual process is to produce those PSIs from a 3D printer using PLA filaments as the building material or to shape titanium mesh or plate on the PLA printed model.

Surgery with 3D computing

The PSIs that were printed are at this point being utilized. Those are, prebend reconstruction plates, osteotomy guides, prebend titanium mesh and surgical splints. Intraoperative navigation or templates can be used to augment the surgery if needed.

Patient Specific Implants

Surgical splints

The treatment of a jaw deformity can be, as its etiology, various and complex. It can involve only the maxilla, mandible or even both. Surgical splints are being used for the positional manipulation of the upper or lower jaw in regard to each other. Those surgical splints are being designed in iPlan and printed via a 3D printer.

Titanium mesh

Titanium mesh is being used for reconstruction in the maxillofacial region and being formed on a 3D model preoperatively. The side where the defect is being reconstructed is being printed as the mirrored image of the unaffected side. They are biocompatible, cover large defects, and deformable, allowing it to adapt to the individual anatomy (4,5)

Reconstruction plates

Reconstruction titanium plates are a stable in fixating fractures as well as flaps. The plates are being formed on a 3D model that was designed with iPlan and a realized in a 3D printer. Titanium plate

contour and fixation points are designed to optimize bony apposition, diminish periosteal stripping and to prevent damage to nearby structures.

Templates

Templates are constructed via CAD in 3D software and can be 3D printed as soon as the design is achieved. The design can be changed digitally as often as needed. The template works as a reference for the form of the reconstructed structure during the surgery.

Intraoperative navigation

Navigation is a 3D computing technique that utilizes the acquired images to produce a real time mapping of the anatomy of the patient which corresponds to the position of the surgeon. This is possible due to implantations of transmitters and the realization of those into a navigation system as so-called fiducial markers. There are two types of markers that can be employed:

- I. Invasive markers: Those markers are usually screws that are fixated into the skull of the patient. (6)
- II. Noninvasive markers. Those are markers that are not invasive and don't need any fixation of any sort. They usually are specific bone prominences of the skull from the patient. A major disadvantage of using bony landmarks is that it requires bone exposure for the registration in the program. Another form of those markers is the use of skin markers.(6,7)

Material and Methods

We used for the purpose of this paper the inhouse data that was collected over 7 years. The data consist of all the patients who underwent any 3D computer assisted surgical procedures at the Department of Oral and Maxillofacial Surgery, University Hospital Dubrava, Zagreb, Croatia, between 2015 to 2022. Retrospectively we analysed the patient demographics, diagnosis and indications for the VSP.

Results

The results are summarized across subclasses based on indication (procedure) and used flap. In total 164 reconstructive surgeries were performed. Out of those 54 were done on women and 110 on men.

The youngest patient was 18 and the oldest 86 years old. The following 3D methods were used:

Preoperatively bending of titanium mesh on a 3D model (n = 82), preoperatively bending of reconstruction plates on a 3D model (n = 22), construction of surgical splints (n = 22), guide for flap design (n = 7), navigation (n = 3), osteotomy guide (n = 22) and soft tissue templates (n = 5).

The data is grouped into 5 categories and analyzed in regard to use of 3D computing to indication: reconstruction of the orbit (n = 61) , reconstruction of the mandible (n = 49), correction of a jaw deformity (n = 22), reconstruction of the maxilla (n = 15) , miscellaneous group (n = 13) consisting of indications for the frontal bone, nose, zygoma, temporal bone and indications that necessitated the use of navigation as a 3D computing technique.

Reconstruction of mandible with DCIA flap

A total of 6 patients, 3 males and 3 females, with ages ranging from 22 to 80 years. Diagnoses included retromolar carcinoma (n = 3), carcinoma of the mandibular gingiva (n = 2), ameloblastic carcinoma of the mandible (n = 1) and tm mandible (n = 1). A major reason for the usage of 3D technique in the DCIA flap was for the flap design (n = 5).

Table 1: Reconstruction of the mandible(DCIA)

Age	Gender	Diagnosis	Op	Indication	Type of 3D usage
80	M	Ameloblastic carcinoma mandible	Mandibular resection	reconstruction of the mandible(DCIA)	guide for flap osteotomy
59	F	Ca retromolare	Commando (SRM)	reconstruction of the mandible(DCIA)	guide for flap osteotomy
68	M	Ca retromolare	Commando (SRM)	reconstruction of the mandible(DCIA)	3d model for reconstruction plate
53	F	Ca gingivae mandibulae	reconstruction of the mandible(DCIA)	reconstruction of the mandible(DCIA)	guide for flap design
59	M	Ca retromolare	Commando (SRM)	reconstruction of the mandible(DCIA)	guide for flap design
22	F	Tm mandible	SRM	reconstruction of the mandible(DCIA)	guide for flap design

Reconstruction of mandible with FFF

This technique together with 3D computing was used in 25 patients.

A total of 18 males and 7 females, with ages ranging from 30 to 80 years. Diagnoses included sublingual carcinoma (n = 3), carcinoma of the mandibular gingiva (n = 11), ameloblastic carcinoma on the mandible (n = 2), tm mandible (n = 2), lingual carcinoma (n = 2), retromolar carcinoma (n = 1), osteonecrosis of the mandible (n = 3) and metastasis (n = 1).

The implementation of 3D computing in FFF was for the production of the osteotomy guides (n = 16) and for the creation of reconstruction plate that were prebend on a 3D model (n = 9).

Table 2: Reconstruction mandible(FFF)

Age	Gender	Diagnosis	Op	Indication	Type of 3D usage
30	M	Posttraumatic defect of the mandible	osteotomy of the mandible, augmentation	reconstruction of the mandible (plate)	3d model for reconstruction plate
53	M	Ca linguae	Commando (SRM)	reconstruction of the mandible (fibula)	3d model for reconstruction plate
53	M	Ca sublinguale	Commando (SRM)	reconstruction of the mandible (fibula)	3d model for reconstruction plate
56	M	Carcinoma gingivae mandibulae	Commando (SRM)	reconstruction of the mandible (fibula)	3d model for reconstruction plate
57	M	Ca gingivae mandibulae	Commando (SRM)	reconstruction of the mandible (fibula)	3d model for reconstruction plate
57	M	Ca sublinguale	Commando (SRM)	reconstruction of the mandible (fibula)	3d model for reconstruction plate
60	M	Ca gingivae mandibulae	Commando (SRM)	reconstruction of the mandible (fibula)	3d model for reconstruction plate
61	F	Meta colli	Commando (SRM)	reconstruction of the mandible (fibula)	3d model for reconstruction plate
80	M	Ca gingivae mandibulae	Commando (SRM)	reconstruction of the mandible (fibula)	3d model for reconstruction plate
43	F	Osteonecrosis mandible	SRM	reconstruction of the mandible (fibula)	osteotomy guide
45	M	Ca gingivae mandibulae	Commando (SRM)	reconstruction of the mandible (fibula)	osteotomy guide
50	F	Ca retromolare	Commando (SRM)	reconstruction of the mandible (fibula)	osteotomy guide
51	M	Carcinoma gingivae mandibulae	Commando (SRM)	reconstruction of the mandible (fibula)	osteotomy guide
52	M	Ameloblastoma manddile	SRM	reconstruction of the mandible (fibula)	osteotomy guide
53	F	Ca gingivae mandibulae	Commando (SRM)	reconstruction of the mandible (fibula)	osteotomy guide
54	M	Ca gingivae mandibulae	Commando (SRM)	reconstruction of the mandible (fibula)	osteotomy guide
55	M	Carcinoma gingivae mandibulae	Commando (SRM)	reconstruction of the mandible (fibula)	osteotomy guide
57	F	Ca gingivae mandibulae	Commando (SRM)	reconstruction of the mandible (fibula)	osteotomy guide
58	F	Ca linguae	Commando (SRM)	reconstruction of the mandible (fibula)	osteotomy guide
58	M	Ca sublinguale	Commando (SRM)	reconstruction of the mandible (fibula)	osteotomy guide
59	M	Ameloblastoma mandible	Mandibular resection	reconstruction of the mandible (fibula)	osteotomy guide
60	F	Tm mandible	SRM	reconstruction of the mandible (fibula)	osteotomy guide
62	M	Ca gingivae mandibulae	Commando (SRM)	reconstruction of the mandible (fibula)	osteotomy guide
70	M	Osteonecrosis mandible	reconstruction of the mandible (fibula)	reconstruction of the mandible (fibula)	osteotomy guide
75	M	Osteonecrosis mandible	reconstruction of the mandible fibula flap)	reconstruction of the mandible (fibula)	osteotomy guide

Reconstruction of the mandible with RFFF

Eight cases underwent mandibular reconstruction with RFFF. Of those 8 patients, 6 were male and 2 were female. The oldest being 82 and the youngest 49 years.

Diagnoses included, carcinoma of the mandibular gingiva (n = 6), sublingual carcinoma (n = 1) and metastasis of the mandible (n = 1). 3D computing was used in those patients for the preoperative bending of titanium reconstruction plates (n = 8) used for fixation of the radius to the remaining mandible.

Table 3: Reconstruction mandible(RFFF)

49 M	Ca gingivae mandibulae	Commando (SRM)	reconstruction of the mandible (radius)	3d model for reconstruction plate
86 M	Ca gingivae mandibulae	Commando (SRM)	reconstruction of the mandible (radius)	3d model for reconstruction plate
64 M	Ca gingivae mandibulae	Commando (SRM)	reconstruction of the mandible (radius)	3d model for reconstruction plate
55 M	Ca gingivae mandibulae	Commando (SRM)	reconstruction of the mandible (radius)	3d model for reconstruction plate
82 F	Ca gingivae mandibulae	Commando (SRM)	reconstruction of the mandible (radius)	3d model for reconstruction plate
65 F	Ca gingivae mandibulae	Commando (SRM)	reconstruction of the mandible (radius)	3d model for reconstruction plate
70 M	Ca sublinguale	Commando (SRM)	reconstruction of the mandible (radius)	3d model for reconstruction plate
65 M	Meta mandible	Commando (SRM)	reconstruction of the mandible (radius)	3d model for reconstruction plate

Reconstruction of the Maxilla using ALT flaps

Anterior lateral thigh flaps were used in 3 patients - 2 females and 1 male. The oldest being 82 and youngest 63 years.

The diagnoses were carcinoma of the nose (n = 1) and carcinoma of the maxilla (n = 2).

Prebent titanium mesh (n = 3) on a 3D printed model was used for all of the 3 patients.

Table 4: Reconstruction maxilla (ALT)

Age	Gender	Diagnosis	Op	Indication	Type of 3D usage
82	F	Ca nasi	reconstruction of the maxilla et nose	mesh + ALT	mesh
80	F	Carcinoma of the maxillae	Radical maxillectomy	Reconstruction of the maxilla + ALT	mesh
63	M	Ca maxillae	Radical maxillectomy	Reconstruction of the maxilla + ALT	mesh

Reconstruction of the Maxilla using DCIA flap, FFF or RFFF

Thirteen patients which underwent a procedure which made use of one of the three aforementioned flaps in the reconstruction of the maxilla. Seven of them were male and 6 of them were female. The oldest being 73 and the youngest 21 years.

The following diagnoses were made for this patient group: squamous cell carcinoma of the maxilla (n = 6), osteosarcoma of the maxilla (n = 1), sarcoma of the palate (n = 1), carcinoma of the palate (n = 1), postoncologic defect of the maxilla and orbit (n = 2) and mucoepidermoid carcinoma of the maxilla (n = 1).

In 7 of those patients FFF, in 2 patient DCIA flap and for 4 patient RFFF was used for the reconstruction of the maxilla.

Mesh (n = 7) was mainly used for the reconstruction with RFFF (n = 4) as well as with FFF (n = 3).

The guide for the flap design (n = 2) was used for the reconstruction with DCIA flap.

Table 5: Reconstruction maxilla (DCIA/FFF/RFFF)

Age	Gender	Diagnosis	Op	Indication	Type of 3D usage
73	M	Ca maxillae	Maxillectomy total	reconstruction of the maxilla (fibula)	osteotomy guide
56	M	Ca maxillae	Total maxillectomy	reconstruction of the maxilla (fibula)	osteotomy guide
57	M	Ca maxillae	Maxillectomy partial	reconstruction of the maxilla (fibula)	osteotomy guide
71	M	Osteosarcoma maxillae	Total maxillectomy	reconstruction of the maxillae (fibula)	osteotomy guide
65	M	Ca maxillae	Maxillectomy partial	reconstruction of the maxilla (fibula)	mesh
39	F	Sarcoma palate	Maxillectomy partial	reconstruction of the maxilla (fibula)	mesh
70	F	Ca maxillae	Maxillectomy partial	reconstruction of the maxilla (radius mesh)	mesh
65	F	Ca maxillae	Maxillectomy total	reconstruction of the maxilla (radius)	mesh
60	M	Ca palati	Partial maxillectomy	reconstruction of the maxilla (radius)	mesh
22	F	Mucoepidermoid carcinoma maxillae	Maxillectomy partial	Reconstruction of the maxilla radial flap	mesh
65	M	Carcinoma of the maxillae	Total maxillectomy	reconstruction of the maxilla (fibula)	mesh
21	F	Defect of the maxilla orbit	Reconstructio of the maxilla (DCIA) and orbit	(reconstruction of the maxilla (DCIA)	guide for flap design
61	F	Defect of the maxilla orbit	reconstruction of the maxilla (DCIA) and orbit	reconstruction of the maxilla (DCIA)	guide for flap design

Correction of Jaw Deformities

In the last 7 years 25 patients were encountered that underwent a correction of a jaw deformity using 3D computing. Out of those 25 patients, there were 15 male and 10 female. The following surgeries for the correction of the jaw deformity were performed in UHD:

Bimaxillary osteotomy (n = 15), sagittal split mandibular osteotomy (n = 5), genioplasty (n = 3), mandible augmentation (n = 1) and a reconstruction of the mandible (n = 1).

The diagnoses which merited those surgeries were in 21 cases a jaw deformity with mandibular prognathism being most common. In 3 cases which had a traumatic episode which led to the deformity – one on the maxilla and two on the mandible. The remaining case was mandibular atrophy.

The usage of 3D computing for those cases were in all but two cases for the design and production of surgical splints (n = 23).

In the remaining two cases, the usage was for the preoperative bending of the titanium plate (n = 1) and titanium mesh (n = 1) respectively.

Table 6: Correction of jaw deformity

Age	Gender	Diagnosis	Op	Indication	Type of 3D usage
69	M	Atrophy of the mandible	Mandible augmentation	augmentation of the mandible (mesh)	mesh
23	F	Jaw deformity	Bimaxillary osteotomy	Correction of the jaw deformity	construction of surgical splints
21	F	Jaw deformity	Bimaxillary osteotomy	Correction of the jaw deformity	construction of surgical splints
27	F	Jaw deformity	Bimaxillary osteotomy	Correction of the jaw deformity	construction of surgical splints
42	F	Jaw deformity	Bimaxillary osteotomy	Correction of the jaw deformity	construction of surgical splints
27	M	Jaw deformity	Bimaxillary osteotomy	Correction of the jaw deformity	construction of surgical splints
35	M	Jaw deformity	Bimaxillary osteotomy	Correction of the jaw deformity	construction of surgical splints
20	M	Jaw deformity	Bimaxillary osteotomy	Correction of the jaw deformity	construction of surgical splints
27	M	Jaw deformity	Bimaxillary osteotomy	Correction of the jaw deformity	construction of surgical splints
24	M	Jaw deformity	Bimaxillary osteotomy	Correction of the jaw deformity	construction of surgical splints
45	M	Jaw deformity	Bimaxillary osteotomy	Correction of the jaw deformity	construction of surgical splints
36	M	Jaw deformity	Bimaxillary osteotomy	Correction of the jaw deformity	construction of surgical splints
23	M	Jaw deformity	Bimaxillary osteotomy	Correction of the jaw deformity	construction of surgical splints
37	M	Jaw deformity	Bimaxillary osteotomy, distractor	Correction of the jaw deformity	construction of surgical splints
48	F	Jaw deformity	Genioplasty	Correction of the jaw deformity	construction of surgical splints
26	M	Jaw deformity	Genioplasty	Correction of the jaw deformity	construction of surgical splints
22	M	Jaw deformity	Genioplasty	Correction of the jaw deformity	construction of surgical splints
45	F	Jaw deformity	Mandibular osteotomy	Correction of the jaw deformity	construction of surgical splints
40	F	Jaw deformity	Mandibular osteotomy	Correction of the jaw deformity	construction of surgical splints
20	F	Jaw deformity	Mandibular osteotomy	Correction of the jaw deformity	construction of surgical splints
20	M	Jaw deformity (cleft)	Bimaxillary osteotomy	Correction of the jaw deformity	construction of surgical splints
56	F	Mandibular posttraumatic deformity	Mandibular osteotomy		construction of surgical splints
18	m	Mandibular prognathism	Bimaxillary osteotomy	Correction of the jaw deformity	construction of surgical splints
30	M	Posttraumatic defect of the mandible	osteotomy of the mandible, augmentation	reconstruction of the mandible (plate)	3d model for reconstruction plate
32	F	Posttraumatic defect of the maxilla	reconstruction of the maxilla (osteoplastica)		mesh

Reconstruction of the Orbit

61 patients that merited a reconstruction of the orbit were encountered during that period. Most of those cases (n = 51) came to our department due to a traumatic fracture of the orbit. They can be divided into complex fractures (n = 45) and orbital floor fracture (n = 6). Out of those, we divided the fractures in acute orbital-trauma-related fractures (n = 38) and posttraumatic orbital fractures (n = 13). The rest (n = 10) needed the procedure because of the defect that followed the resection of a tumor. The specific tumors were, BCC nose face (n = 1), skin ca medial canthus (n = 4), mucocele sinus maxillaries (n = 1), Tm orbit (n = 1), Tm ethmoid sinus (n = 1) and skin cancer forehead (n = 1). In all of the 62 cases CAD/CAM was used for constructing a 3D model on which the titanium mesh was formed.

Table 7: Reconstruction of orbit(mesh)

Age	Gender	Diagnosis	Op	Indication	Type of 3D usage
74	F	BCC nose fase	resection of the tumor and bone	reconstruction of the orbit (mesh)	mesh
67	M	PCC medial canthus	resection of the tumor and bone	reconstruction of the medial canthus	mesh
60	M	Skin ca medial canthus	frontal flap, resection of the tumor	reconstruction of the medial wall	mesh
41	M	BCC medial canthus	resection of the tumor and bone	reconstruction of the medial wall	mesh
75	M	Mucocela sinus maxillaris	extirpation	reconstruction of the orbit	mesh
46	M	Tm orbit	resection of the tumor and bone	reconstruction of the orbit	mesh
65	M	Tm etmoid sinus	resection of the tumor and orbit	reconstruction of the orbit	mesh
78	F	Skin cancer forehead	Resection	reconstruction of the orbit (mesh)	mesh
49	M	BCC medial canthus	resection of the tumor and bone	reconstruction of the supraorbital rim and medial wall	mesh
80	M	Skin cancer medial canthus	Reconstruction of the medial wall of the orbit + frontal flap		mesh
23	M	Posttraumatic defect of the orbit	Reconstruction of the orbit		mesh
60	M	Posttraumatic defect of the orbit	Reconstruction of the orbit		mesh
49	M	Orbital fracture	reconstruction of the orbit		mesh
20	M	Fractura orbitae	reconstruction of the orbit		mesh
56	M	Fractura orbitae	reconstruction of the orbit		mesh
61	F	Fractura orbitae	reconstruction of the orbit		mesh
29	M	Fractura orbitae	reconstruction of the orbit		mesh
62	M	Fractura orbitae	reconstruction of the orbit		mesh
25	M	Fractura orbitae	reconstruction of the orbit		mesh
32	F	Posttraumatic defect of the orbit	reconstruction of the orbit		mesh
51	M	Fractura orbitae	reconstruction of the orbit		mesh
61	M	Posttraumatic defect of the orbit	reconstruction of the orbit		mesh
49	F	Posttraumatic defect of the orbit/zygoma	reconstruction of the orbit		mesh
52	M	Fractura orbitae	reconstruction of the orbit		mesh
52	F	Fractura orbitae	reconstruction of the orbit		mesh
37	F	Posttraumatic defect of the orbit	reconstruction of the orbit		mesh
68	F	Posttraumatic defect of the orbit	reconstruction of the orbit		mesh
20	M	Fractura orbitae	reconstruction of the orbit		mesh
35	M	Fractura orbitae	reconstruction of the orbit		mesh
21	M	Fractura orbitae	reconstruction of the orbit		mesh
62	F	Posttraumatic defect of the orbit	reconstruction of the orbit		mesh
19	F	Posttraumatic defect of the orbit	reconstruction of the orbit		mesh
46	M	Posttraumatic defect of the orbit	reconstruction of the orbit		mesh
42	M	Fractura orbitae	reconstruction of the orbit		mesh
24	M	Fractura orbitae	reconstruction of the orbit		mesh
29	F	Fractura orbitae	reconstruction of the orbit		mesh
66	M	Fractura orbitae	reconstruction of the orbit		mesh
35	M	Fractura orbitae	reconstruction of the orbit		mesh
30	M	Fractura orbitae	reconstruction of the orbit		mesh
32	M	Posttraumatic defect of the orbit	reconstruction of the orbit		mesh
25	M	Fractura orbitae	reconstruction of the orbit		mesh
35	M	Fractura orbitae	reconstruction of the orbit		mesh
34	M	Fractura orbitae	reconstruction of the orbit		mesh
44	M	Fractura orbitae	reconstruction of the orbit		mesh
40	M	Fractura orbitae	reconstruction of the orbit		mesh
39	M	Posttraumatic defect of the orbit	reconstruction of the orbit		mesh
40	M	Fractura orbitae	reconstruction of the orbit		mesh
57	F	Posttraumatic defect of the orbit	reconstruction of the orbit		mesh
34	M	Fractura orbitae	reconstruction of the orbit		mesh
69	M	Fractura orbitae	reconstruction of the orbit		mesh
31	M	Fractura orbitae	reconstruction of the orbit		mesh
61	M	Fractura orbitae	reconstruction of the orbit		mesh
31	M	Fractura orbitae	reconstruction of the orbit		mesh
59	F	Fractura orbitae	reconstruction of the orbit		mesh
62	F	Fractura orbitae	reconstruction of the orbit		mesh
24	M	Fractura orbitae	Reconstruction of the orbital floor		mesh
39	M	Fractura orbitae	Reconstruction of the orbital floor		mesh
60	F	Fractura orbitae	Reconstruction of the orbital floor		mesh
49	M	Fractura orbitae	Reconstruction of the orbital floor		mesh
30	M	Fractura orbitae	Reconstruction of the orbital floor		mesh
18	M	Orbital fracture	Reconstruction of the orbital floor		mesh

Miscellaneous indications

For this indication group 15 cases underwent 3d computer assisted surgery. Out of those patients, 10 were male and 5 female. The age of those patients ranged from 19 to 86 years. The following diagnoses were made and necessitate surgery accordingly:

Defect of the nose (n = 1), Deformation of the nose (n = 2), Fibrous dysplasia maxilla (n =1), Mucocele frontal sinus (n = 3), Osteofibroma mandible (n = 1), Osteosarcoma zygoma (n =1), Posttraumatic defect of the temporal region (n =1), skin cancer (n = 4) and Tm mandible (n =1).

Out of those patients, 3D computing was used for the preoperatively forming of mesh on a 3D model (n = 7). Templates (n =5) were used in the reconstruction of the nose and navigation (n = 3) was used in the modelation of the maxilla as well as the resection of bone and tumor.

Table 8: Reconstruction for miscellaneous indications

Age	Gender	Diagnosis	Op	Indication	Type of 3D usage
86	F	BCC face	Resection of the tumor and bone	reconstruction of the zygoma (mesh)	mesh
66	M	BCC scalp	resection of the tumor and bone	Mesh for calvarium	mesh
65	M	Mucocele frontal sinus	reconstruction of the frontal bone	reconstruction of the frontal bone	mesh
53	M	Mucocele frontal sinus	Resection	reconstruction of the frontal bone	mesh
48	M	Mucocele frontal sinus	reconstruction of the frontal bone		mesh
82	M	Osteosarcoma zygoma	Resection of the tumor and bone	reconstruction of the zygoma (mesh)	mesh
29	M	Posttraumatic defect of the temporal region	Reconstruction with ALT		mesh
19	F	Fibrous dysplasia maxilla	Modelation of the maxilla	navigation	navigation
40	F	Osteofibroma mandible	tumor resection	navigation	navigation
32	M	Tm mandible	resection of the tumor and bone	navigation	navigation
67	M	Ca nose	resection of the nose	reconstruction of the nose (forehead flap)	template
65	M	Defect of the nose	Nose reconstruction radial forearm flap	reconstruction of the nose (template)	template
35	F	Deformation of the nose	Rhinoplasty	reconstruction of the dorsum with the rib	template
43	M	Deformation of the nose	Septorhinoplasty	cartilage graft	template
32	F	SCC nose	resection of the nasal ala	reconstruction of the nose (radial FF)	template

Discussion

Depending on the region of the defect, patients' characteristics and the indication, the team in UHD made use of different surgical techniques. Those techniques were augmented with complementing 3D computing techniques.

In the reconstruction of the mandible with a DCIA flap the design is important. The length, thickness and contour of the defect needs to be congruent to each other.

One of the reasons for the decline of this technique in North America is the bulk of the flap and the perceived difficulties working with it(8). There were no perceived difficulties in UHD when it came to the bulk of the flap. Most likely because the designing of the flap with 3D computing led to a size reduction of the DCIA flap to a level which is appropriate for the defect.

Another issue which is often brought up is the pedicle length of this flap. The short pedicle length was circumvented with the use of VSP by knowing beforehand how long the pedicle needs to be and if the DCIA flap is therefore applicable on an individual basis. If not FFF, RFFF or any other flap were used. If applicable, the flap was designed with iPlan. During the surgery the team in UHD fixated the flap with reconstruction plates that were preoperatively bend on a CAD/CAM 3D model. Those plates were used to fixate the neomandible in place, to allow for proper orthognathic alignment of the jaw and with it, to reestablish its function - since every slight deviation can lead to a change in how it operates and therefore to problems eventually (9).

Aside from DCIA flaps the team in UHD used FFF in mandibular reconstruction as well.

For FFF multiple osteotomies were used on the fibula and later the wanted shape was fixated with reconstruction plates or even miniplates. The main disadvantage that is perceived with the use of this flap is how difficult and time consuming it is to perform the needed osteotomies on the mandible and fibula. The cuts need to be congruent to each other and they need to allow the proper angle to be realized - resulting in increased intraoperative time as well as multiple corrective surgeries(10). The usage osteotomy guides alleviated those disadvantages.

The cuts were selected in accordance with the future neomandibles angulation and form that was needed. They were translated into the osteotomy guides that were used in the surgery. The margin of error was decreased and the intraoperative time as well. Furthermore, the learning curve to perform this kind of surgery was flattened as well. All of this is because the surgeon doesn't need to estimate the needed angle and position of the cuts since the osteotomy guides are taking over that role. This means that the experience needed to perform the surgery is reduced.

The overall accuracy to perform the osteotomies including the shaping procees of the reconstruction plates benefited from the use of 3D computing.

As in the reconstruction with DCIA flaps and FFF, in RFFF reconstruction a proper angulation is adamant for the function of the neomandible. With the use of a 3D model, the needed variables (angle, length etc.) were found and secured with reconstruction plate.

This increase in accuracy that was experience is in line with multiple reviews on this matter.(11–14)

As in the reconstruction of the mandible, the same benefits with 3D computing were experience in the reconstruction of the maxilla. The only difference was in why the specific flaps for the reconstruction in the maxilla was chosen. FFF and RFFF are both versatile in its pliability and can be seen as universal flaps.(15,16)

The guide for the flap design was used for the reconstruction with DCIA flap.

Reason for using 3D techniques was the volume of the flap as well as the short pedicle as mentioned before. With VSP we can orient the flap on a iliac crest more posteriorly in a way to make pedicle a bit longer and also to make iliac curvature with shape of the maxilla as similar as possible.

ALT flaps were used in concomitants with titanium mesh.

The titanium mesh was preoperatively bent on a 3D model and used for reconstruction of the defect in the maxilla. The team in UHD used the ALT flap to cover the mesh used for hard tissue reconstruction in order to prevent exposure of the mesh(17). ALT together with titanium mesh allowed for great versatility handling it and the ALT flap grants enough tissue to cover larger defects including prevention of exposing the mesh(17).

For the correction of jaw deformities, it is common practice to use surgical splints to reduce of the jaw deformity.

The usage of surgical splints in mandibular osteotomy and genioplasty lies in the intraoperatively positioning of a mobile osteotomized jaw against the other stable jaw before the internal fixation process. In bimaxillary osteotomy we needed two surgical splints. The first one is used after osteotomy of the first jaw as a transitional splint, the remaining one after the second jaw has been osteotomized as a final splint.

The perceived benefits were twofold. The overall accuracy in the angle of the osteotomies was increased as in FFF. This is usually the experience that was observe with osteotomies guides. Another benefit that was perceived was the overall reduction in time during the surgery. This experience again, aligns with the other institutions experience in those regards.(11,13,18,19)

Reconstructive surgery of the orbit can be quite complicated because of the proximity of the structures to each other. The reduced overview of the area as well as the difficulty exposing the defect is further increasing the difficulty.

Since misfitting implants and inaccurate surgical technique may lead to visual disturbance, unaesthetic results as well as lead to multiple corrective surgeries(20), there is a need for any surgery to adhere to

a high standard to accuracy. The usage of 3D computing is counteracting those problems to a major degree.

The prebend titanium mesh reduced the intraoperative time by eliminating the need to bend and rebend the mesh during the surgery. Furthermore, the ability to get familiarized with the defect on a model decreased the needed time and increased the success of the surgery. This is mainly because of the reduced overview and the overall complexity of orbital defects – especially post trauma fractures – with which the surgeon can familiarize himself with. Before the usage of 3D computing the titanium mesh used to be bend manually which led to multiple corrective surgeries if the implants did not fit properly. The accuracy of PSIs placement as well as its complementing form to the defect increased with the use of CAD/CAM and reduced corrective surgeries to a minimum. This experience is common with the use of 3D computing in reconstructive orbit surgery which helps to establish its role in this field (5,20).

For the reconstruction of the nose, templates were used. The benefits of using it was twofold. First, it decreased the time needed to form the neose since there was a template showing how it should be formed. Secondly, the constructed template could be changed digitally as often as needed to produce a satisfying result for patient and surgeon. This benefit is especially important for the nose since it is one of the most difficult areas for reconstructive surgery as well as the most common performed plastic surgery procedure in the US. (21)

The use of intraoperative navigation was tremendously helpful in the resection tumors of the mandible and maxilla. The main advantage that you have is the mapping of the region with transmitters which gives feedback to where the surgeon is at every time. This allowed our surgeons to be more precise in making the resections. Another benefit is the reduced exposure of radiation. That's because the transmitter allowed via the computer to make changes on the go as the surgeon was working. This made frequent reevaluation with a CT obsolete. Furthermore, the accuracy of navigation limited the need for wide surgical exposure, reduced morbidity, and shortened the surgical time. Our observation lined up with multiple studies on this matter.(6,7)

Conclusion

During the evaluation of the data the cause of the benefits of 3D computing in head and neck reconstruction became clearer and clearer. The increased accuracy, reduced morbidity, shortened surgical time had all something to do with the fact that the planning process as well as the surgery was enriched with the meticulous planning which resulted due to the use of 3D computing. Furthermore, the production of PSIs with the data of the patient reduced the difficulty of their placement and the need to perform corrective surgery because of the accuracy of their shape to the defect.

Another helpful feature was the possibility of prebending the PSIs - titanium mesh and reconstruction plates - on a 3D model. This was reducing the intraoperative time by reducing the need to rebend the PSI as well as them being easier to work with. Titanium mesh was namely used for reconstruction after fractures as well as bone defect resulting from the tumor resection. The orbit was the region with the most indications for the implementation of mesh. The majority of them being posttraumatic. Reconstruction plates were used in the context of mandibular reconstruction with FFF, DCIA flaps or RFFF.

Osteotomy guides found their use when it came to the reconstruction of the maxilla and mandible with the use of FFF and DCIA flaps. This can be explained with the need of high accuracy in the cuts for maintaining the function of the jaw. The majority of the diseases which led to the reconstructive surgery was some form of tumor.

Flap designs were used mainly in concomitant with DCIA for the reconstruction of the mandible and maxilla. Their bulky flap needed to be designed as accurately as possible in order to fit the defect and to not hinder the function of the jaw.

The construction of surgical splints was indicated in jaw deformities. The main benefit is the increased precision. Templates were being used for the reconstruction of the nose. The use of it decreased the intraoperative time, as well as increased the satisfaction of the product. The template was made preoperative and could be changed as often as needed before the surgery which led to those benefits. Intraoperative navigation was used in the resection of tumor and allowed, with its real time feedback, to increase the precision, decrease the exposure of radiation and reduce the need for wide surgical exposure.

Acknowledgment

First, I would like to express deep and sincere gratitude to my mentor Professor Emil Dediol, MD., PhD. The chance to work with him together on this paper with the degree of autonomy – and with the level of trust that comes with it - that he gave me was more than I could ask for.

This allowed me to wander of in many areas of this field and gave me a new insight of what I want from my career as a future physician.

Furthermore, I would like to thank Zagreb University, School of Medicine, who gave me the opportunity to pursue medicine here in Zagreb and who is continuously providing me with medical knowledge.

I am forever grateful.

My final gratitude goes out to my family, who never stop supporting me in all aspects of my life.

References

1. Singh GD, Singh M. Virtual surgical planning: Modeling from the present to the future. Vol. 10, *Journal of Clinical Medicine*. MDPI; 2021.
2. Weijs WLJ, Coppens C, Schreurs R, Vreeken RD, Verhulst AC, Merckx MAW, et al. Accuracy of virtually 3D planned resection templates in mandibular reconstruction. *Journal of Cranio-Maxillofacial Surgery*. 2016 Nov 1;44(11):1828–32.
3. Shenaq DS, Matros E. Virtual planning and navigational technology in reconstructive surgery. Vol. 118, *Journal of Surgical Oncology*. John Wiley and Sons Inc.; 2018. p. 845–52.
4. Seen S, Young S, Lang SS, Lim TC, Amrith S, Sundar G. Orbital Implants in Orbital Fracture Reconstruction: A Ten-Year Series. *Craniofacial Trauma & Reconstruction*. 2021 Mar;14(1):56–63.
5. Mustafa SF, Evans PL, Bocca A, Patton DW, Sugar AW, Baxter PW. Customized titanium reconstruction of post-traumatic orbital wall defects: A review of 22 cases. *International Journal of Oral and Maxillofacial Surgery*. 2011;40(12):1357–62.
6. Demian N, Pearl C, Woernley TC, Wilson J, Seaman J. Surgical Navigation for Oral and Maxillofacial Surgery. Vol. 31, *Oral and Maxillofacial Surgery Clinics of North America*. W.B. Saunders; 2019. p. 531–8.
7. Lübbers HT, Jacobsen C, Matthews F, Grätz KW, Kruse A, Obwegeser JA. Surgical navigation in craniomaxillofacial surgery: Expensive toy or useful tool? A classification of different indications. *Journal of Oral and Maxillofacial Surgery*. 2011 Jan;69(1):300–8.
8. Cariati P, Farhat MC, Dyalram D, Ferrari S, Lubek JE. The deep circumflex iliac artery free flap in maxillofacial reconstruction: a comparative institutional analysis. *Oral and Maxillofacial Surgery*. 2021 Sep 1;25(3):395–400.
9. Hirsch DL, Garfein ES, Christensen AM, Weimer KA, Saddeh PB, Levine JP. Use of Computer-Aided Design and Computer-Aided Manufacturing to Produce Orthognathically Ideal Surgical Outcomes: A Paradigm Shift in Head and Neck Reconstruction. *Journal of Oral and Maxillofacial Surgery*. 2009 Oct;67(10):2115–22.
10. Pucci R, Weyh A, Smotherman C, Valentini V, Bunnell A, Fernandes R. Accuracy of virtual planned surgery versus conventional free-hand surgery for reconstruction of the mandible with osteocutaneous free flaps. *International Journal of Oral and Maxillofacial Surgery* [Internet]. 2020 Sep;49(9):1153–61. Available from: <https://linkinghub.elsevier.com/retrieve/pii/S0901502720300862>
11. Kreutzer K, Steffen C, Koerdt S, Doll C, Ebker T, Nahles S, et al. Patient-Specific 3D-Printed Miniplates for Free Flap Fixation at the Mandible: A Feasibility Study. *Frontiers in Surgery*. 2022 Mar 14;9.
12. Rodby KA, Turin S, Jacobs RJ, Cruz JF, Hassid VJ, Kolokythas A, et al. Advances in oncologic head and neck reconstruction: Systematic review and future considerations of virtual surgical planning and computer aided design/computer aided modeling. Vol. 67, *Journal of Plastic, Reconstructive and Aesthetic Surgery*. Churchill Livingstone; 2014. p. 1171–85.
13. Yang W fa, Choi WS, Wong MCM, Powcharoen W, Zhu W yong, Tsoi JKH, et al. Three-Dimensionally Printed Patient-Specific Surgical Plates Increase Accuracy of Oncologic Head and Neck Reconstruction Versus Conventional Surgical Plates: A Comparative Study. *Annals of Surgical Oncology*. 2021 Jan 1;28(1):363–75.

14. Wang Y, Qu X, Jiang J, Sun J, Zhang C, He Y. Aesthetical and Accuracy Outcomes of Reconstruction of Maxillary Defect by 3D Virtual Surgical Planning. *Frontiers in Oncology*. 2021 Oct 19;11.
15. Kim JH, Rosenthal EL, Ellis T, Wax MK. Radial forearm osteocutaneous free flap in maxillofacial and oromandibular reconstructions. *Laryngoscope*. 2005 Sep;115(9):1697–701.
16. Patel SY, Kim DD, Ghali GE. Maxillofacial Reconstruction Using Vascularized Fibula Free Flaps and Endosseous Implants. Vol. 31, *Oral and Maxillofacial Surgery Clinics of North America*. W.B. Saunders; 2019. p. 259–84.
17. Dediol E, Uglešić V, Zubčić V, Knežević P. Brown class III maxillectomy defects reconstruction with prefabricated titanium mesh and soft tissue free flap. *Annals of Plastic Surgery*. 2013 Jul;71(1):63–7.
18. Zoabi A, Redenski I, Oren D, Kasem A, Zigran A, Daoud S, et al. 3D Printing and Virtual Surgical Planning in Oral and Maxillofacial Surgery. *Journal of Clinical Medicine*. 2022 May 1;11(9).
19. Melville JC, Manis CS, Shum JW, Alsuwied D. Single-Unit 3D-Printed Titanium Reconstruction Plate for Maxillary Reconstruction: The Evolution of Surgical Reconstruction for Maxillary Defects—A Case Report and Review of Current Techniques. *Journal of Oral and Maxillofacial Surgery*. 2019 Apr 1;77(4):874.e1-874.e13.
20. Gander T, Essig H, Metzler P, Lindhorst D, Dubois L, Rucker M, et al. Patient specific implants (PSI) in reconstruction of orbital floor and wall fractures. *Journal of Cranio-Maxillofacial Surgery*. 2015 Jan 1;43(1):126–30.
21. Halepas S, Lee KC, Castiglione C, Ferneini EM. Grafting in Modern Rhinoplasty. Vol. 33, *Oral and Maxillofacial Surgery Clinics of North America*. W.B. Saunders; 2021. p. 61–9.

Biography

Alban Gecaj was born in Verice, Kosovo on October 1st, 1993, and grew up in Munich, Germany. He went to school in Munich and went abroad to study medicine in Zagreb, Croatia.