

A retrospective study of recalcitrant macular edema following vitreoretinal surgery

Sanchis, Pierre

Master's thesis / Diplomski rad

2018

Degree Grantor / Ustanova koja je dodijelila akademski / stručni stupanj: **University of Split, School of Medicine / Sveučilište u Splitu, Medicinski fakultet**

Permanent link / Trajna poveznica: <https://urn.nsk.hr/urn:nbn:hr:171:000434>

Rights / Prava: [In copyright / Zaštićeno autorskim pravom.](#)

Download date / Datum preuzimanja: **2024-04-25**



Repository / Repozitorij:

[MEFST Repository](#)



UNIVERSITY OF SPLIT



**UNIVERSITY OF SPLIT
SCHOOL OF MEDICINE**

Pierre Sanchis

**A RETROSPECTIVE STUDY OF RECALCITRANT MACULAR
EDEMA FOLLOWING VITREORETINAL SURGERY**

Diploma thesis

**Academic year:
2017/2018**

**Mentor:
Assist. Prof. Ljubo Znaor, MD, PhD**

Split, July 2018

**UNIVERSITY OF SPLIT
SCHOOL OF MEDICINE**

Pierre Sanchis

**A RETROSPECTIVE STUDY OF RECALCITRANT MACULAR
EDEMA FOLLOWING VITREORETINAL SURGERY**

Diploma thesis

**Academic year:
2017/2018**

**Mentor:
Assist. Prof. Ljubo Znaor, MD, PhD**

Split, July 2018

TABLE OF CONTENTS:

1. INTRODUCTION	1
1.1. Definition	2
1.2. Pathogenesis	2
1.3. Diagnostic methods	5
1.4. Treatment modalities	6
1.5. Diseases-related macular edema	7
1.5.1. Macular edema and retinal vascular diseases	7
1.5.1.1. Diabetic macular edema	7
1.5.1.2. Retinal vein occlusion	9
1.5.2. Macular edema and uveitis	10
1.5.3. Postoperative cystoid macular edema	11
2. OBJECTIVES	14
3. MATERIALS AND METHODS	16
3.1. Ethical background of data collection	17
3.2. Study purpose	17
3.3. Subjects	17
3.4. Methods	17
3.5. Statistical methods	19
4. RESULTS	20
4.1. Baseline characteristics	21
4.2. Study outcome	23
4.2.1. Preoperative and first postoperative OCT recordings comparison	23
4.2.2. 1 st postoperative and 2 nd postoperative OCT follow-up comparison	25
4.2.3. 2 nd postoperative and 3 rd postoperative OCT follow-up comparison	25
4.2.4. Summary of study outcome	26
5. DISCUSSION	29
6. CONCLUSIONS	32
7. REFERENCES	34
8. SUMMARY	38
9. CROATIAN SUMMARY	40
10. CURRICULUM VITAE	42

ACKNOWLEDGEMENT

To my thesis mentor, Assist. Prof. Ljubo Znaor for his help and dedication in the field of ophthalmology that have inspired me for the future.

To my parents, for providing me the opportunity to fulfil my dream of becoming a doctor. Their constant love and selfless encouragements to follow my own path made my last past six years unforgettable.

To my fiancé, Charlotte Narloch for her patience, humour, devotion and continuous love. She has always been of great value and made me better.

To my brothers, for their love and support despite the long distance between us.

To my friends, for their continued encouragements.

1. INTRODUCTION

1.1. Definition

Macular edema (ME) describes the abnormal accumulation of fluid in the central portion of the retina around the fovea. The increase in retinal volume leads to inflammatory reparative response and distortion of the vision. Macular edema is encountered in various eye conditions (uveitis, trauma, intraocular surgery, vascular retinopathies, vitreoretinal adhesions, hereditary dystrophies, diabetes, and age-related macular degeneration) and it is defined as a nonspecific sign (1).

The process of fluid accumulation is most commonly linked to an alteration of the blood-retinal barrier (BRB). For this reason, the highly selective barrier do not carry out its primary role of maintaining an adequate environment for the neural tissue (2, 3).

Characteristically, the expansion of the fluid in the macula begins in the outer plexiform layer and extend towards the inner nuclear and inner plexiform layers of the retina (1, 4).

For that matter, different clinical method or imaging techniques have been used, with more or less success, in order to diagnose macular edema: direct and indirect ophthalmoscopy; fluorescein angiography; optical coherence tomography.

1.2. Pathogenesis

The process of fluid accumulation is most commonly linked to an alteration of the blood-retinal barrier (BRB) (1).

The BRB is composed of a double barrier: an inner blood retinal barrier (iBRB) and outer blood retinal barrier (oBRB). Similar to the blood brain barrier (BBB), the iBRB is designed as tight junctions surrounding the retinal capillary endothelial cells and preventing arbitrary solutes diffusion. Similarly, the oBRB is formed of tight junctions between retinal pigment epithelial (RPE) cells. The BRB architecture provides the adequate environment for the retinal cells through the exchange of ions, water, proteins and sugars, and preserves the neural tissue from inflammatory reactions (2, 3, 5).

Characteristically, the expansion of the fluid in the macula begins in the outer plexiform layer and extend towards the inner nuclear and inner plexiform layers of the retina. In the case of overexpansion of the macula, the increase in fluid content can reach the internal limiting membrane and cause a rupture of the retina, creating macular holes. The origin of the edema build-up may be intracellular, extracellular or both (1, 4).

Intracellular fluid accumulation, secondarily to a disruptive event spearing the BRB, results of an alteration of the ionic osmotic gradient between the retinal cells. This phenomenon is called cytotoxic edema and may be the consequence of a trauma or non-traumatic conditions (e.g., ischemia and toxic cell damage). In contrast, the increase in extracellular volume is caused by the failure of the iBRB or oBRB. Inflammatory cells, described as locally mediated cytokines, influence directly and indirectly the permeability of the BRB tight junctions (Figure 1) (1, 4).

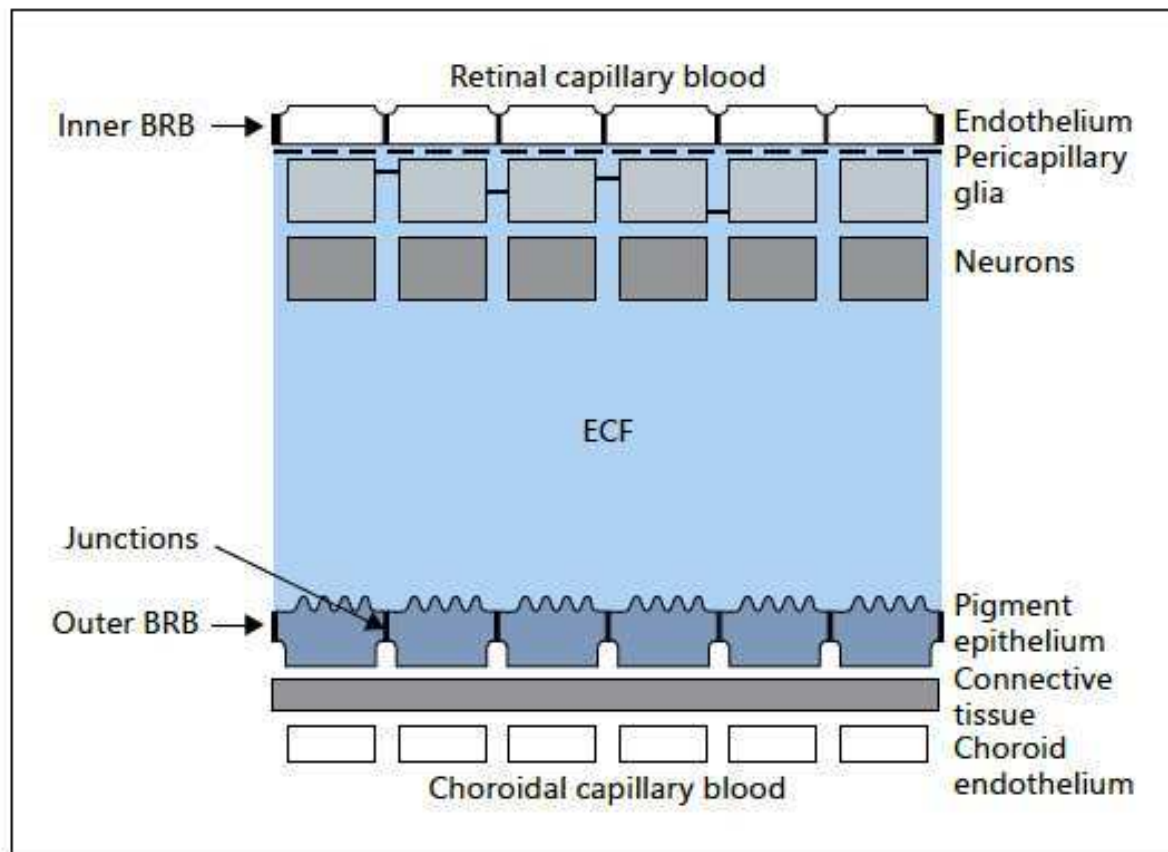


Figure 1. Schematic presentation of the inner and outer BRBs and their relative location. ECF = Extracellular fluid (1)

Macular edema formation is governed by five important elements the Starling's law is based on: the BRB permeability; the capillary hydrostatic pressure; the tissue hydrostatic pressure; the tissue osmotic pressure; and the osmotic pressure (4). The BRB permeability increases in the case of direct damage to retinal endothelial cells and/or retinal pigment epithelial cells. Moreover, any changes in the homeostasis between hydrostatic and oncotic pressure gradients across the BRB leads to increase in the volume of the edema (2, 4).

Nevertheless, other structural barriers are present in the retina and play a no less important role in the prevention of macular edema (4).

The inner limiting membrane (ILM), boundary in between the retina and the vitreous body, has not the necessary properties to prevent proteins and fluid from passing across this barrier (Figure 2) (4, 6). At this level, the intraocular passive pressure propel water into the retina. On the choroidal side, by the effect of osmotic pressure, the water is dragged out passively (4, 7).

On the other hand, the external limiting membrane (ELM) is situated at the bases of the rods and cones, and is composed of zonulae adherents (Figure 2). The later, are not consider as dense and compact as the BRB that are, as previously mentioned, tight junctions. For this reason, the ELM selectively restrict large molecules movement (e.g. albumin and other proteins) and, as a result of this increase in oncotic pressure, keep the water into the retina. In consequence, the active transport of water, across the RPE, is required in order to keep the neural tissue free and dry of proteins and fluid (4).

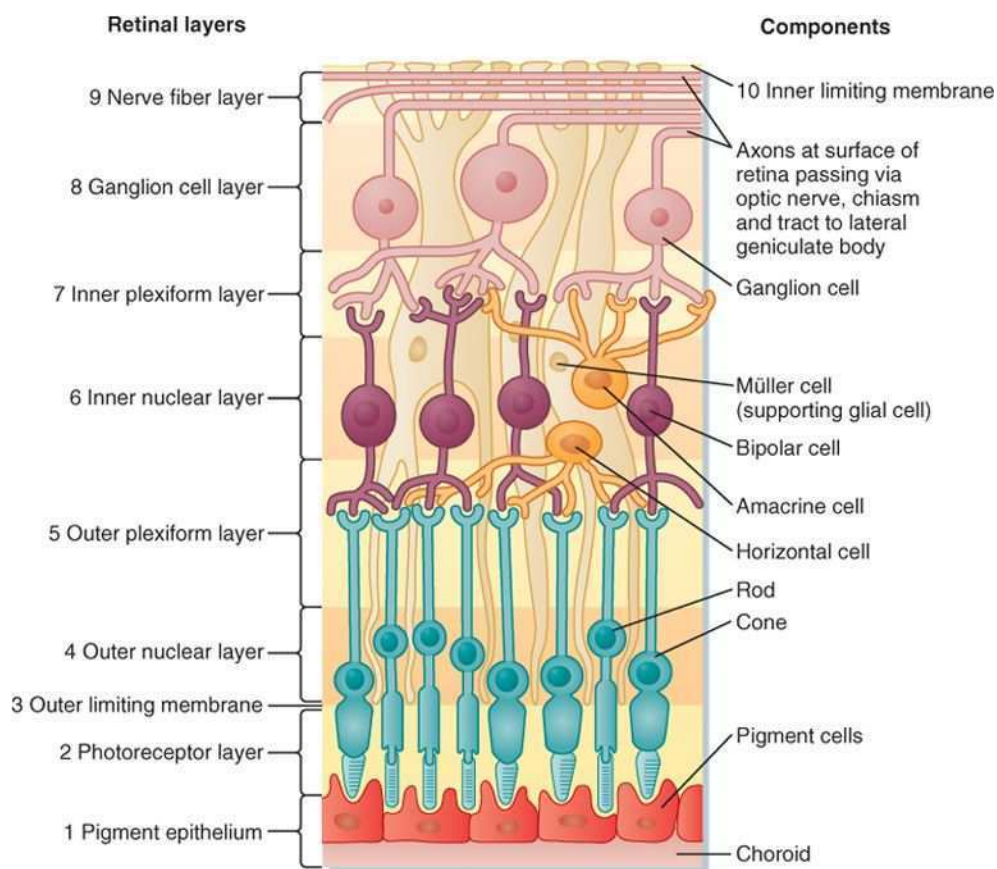


Figure 2. Layers of the retina. Light impinging on the retina comes from the top of the figure and passes through all the superficial layers to reach the photoreceptor rods and cones (8)

Consequently, the active transport at the RPE plays a protective role against fluid accumulation. On the contrary, in the case of retinal alteration, this compensatory mechanism is not properly maintained and the build-up of fluid is more pronounced in the area of protein aggregation, as the ELM limit the proteins diffusion (4).

1.3. Diagnostic methods

Macular edema assessment is of upmost concern. As described by Staurenghi *et al.* (9), a broad range of parameters needs to be taken into account when evaluating macular edema: “extent of the macular edema (i.e., the area that shows increased retinal thickness); distribution of the edema in the macular area (i.e., focal versus diffuse macular edema); central fovea involvement (central area 500 μm); fluorescein leakage (evidence of alteration of BRB or ‘open barrier’) and intraretinal cysts; signs of ischemia (broken perifoveolar capillary arcade and/or areas of capillary closure); presence or absence of vitreous traction; increase in retinal thickness and cysts in the retina (inner or outer), and chronicity of the edema (i.e., time elapsed since first diagnosis and response to therapy).”.

For that matter, different clinical method or imaging techniques have been used in order to diagnose macular edema.

In the first place, direct and indirect ophthalmoscopy have been useful in determining the fluctuation of volume in the retina. Nevertheless, slit lamp lack reproducible measurement of the macular thickness variation and are based on ophthalmologist’s skills to recognize macular changes and anatomic details (Figure 3) (1, 9, 10).

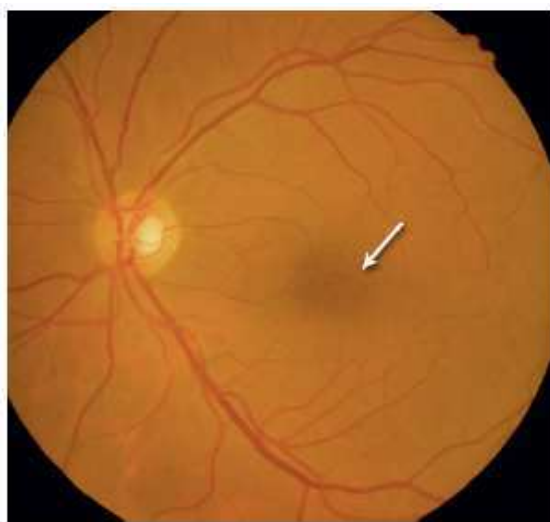


Figure 3. Postoperative fundus examination photo. Arrow = CME (9)

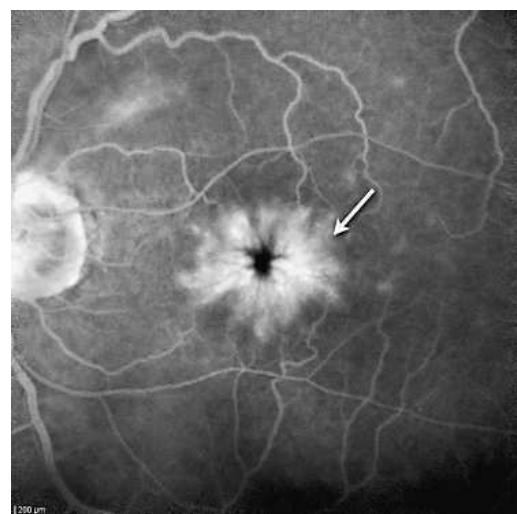


Figure 4. Postoperative FA. Arrow = CME (9)

Therefore, fluorescein angiography (FA) has become the gold standard imaging method to analyse retinal capillary bed and choroidal anatomy, and to recognize breakdown in the BRB causing macular edema (i.e. fluorescein leakage) (Figure 4) (9, 11). Accordingly, FA may help to diagnose the aetiology of the macular edema: in case of DR, microaneurysms leakage are common; whereas in the case of RVO, vascular branches leakage running horizontally are identified. Nonetheless, the technique lack two-dimensional depth perspective to allow the visualization of all retinal capillary layers and, as a matter of fact, exclude the observation of deeper vascular network (9, 12-14).

All things considered, optical coherence tomography (OCT) has the advantage to allow non-invasive, in vivo visualization of the retina in two- or three-dimensional space. As a result, OCT gives the best images, thanks to cross-sectional images through the macula, for the identification of ME, its evolution and response to treatment in time (Figure 5) (1, 9).

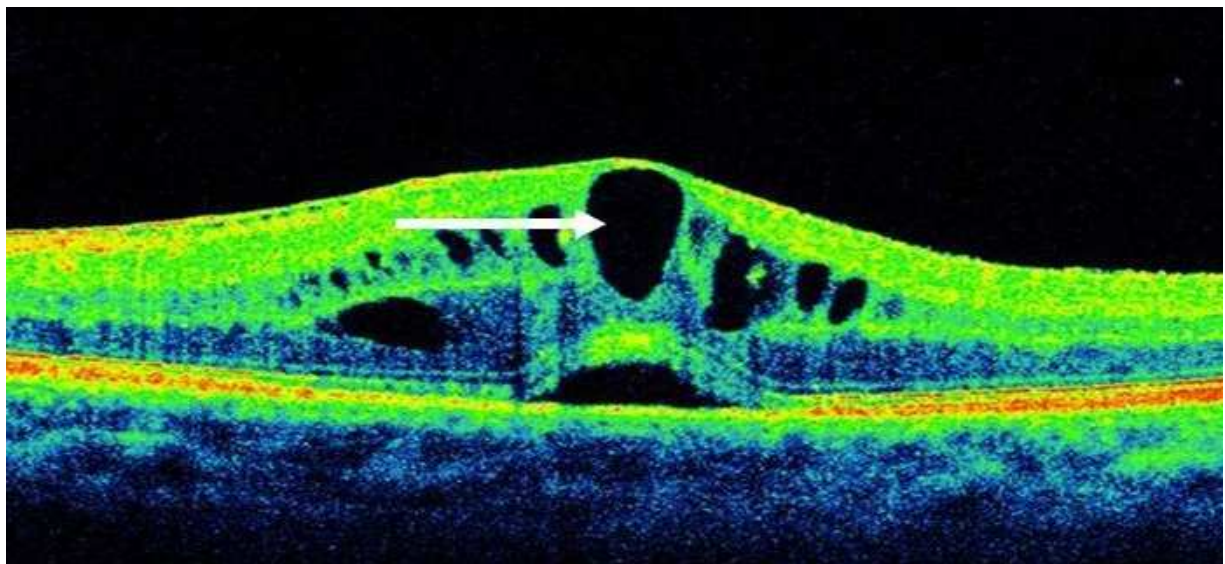


Figure 5. Macular edema on OCT. Arrow = CME.

1.4. Treatment modalities

The pathophysiologies leading to macular edema are as varied and diverse as the number of diseases causing it: intraocular inflammation, ocular retinopathies, intraocular surgery, and other diseases. For this reason, a good understanding of the different pathophysiological mechanisms is essential in order to design the right treatment for macular edema.

Macular edema is mainly the result of systemic and ocular diseases. This way, macular edema caused by systemic factors (e.g. hypertension, diabetes mellitus, hyperlipidaemia or inflammatory diseases) is best managed by preventing and treating of those risks.

On the other hand, macular edema caused by ocular conditions are more commonly the consequence of an increase in permeability (i.e. inflammation) or a breakdown in the BRB. Therefore, drugs have been implemented to act at this level of the retina, such as: nonsteroidal anti-inflammatory drugs (NSAIDs), corticosteroids, carbonic anhydrase inhibitors (CAI), and anti-vascular endothelial growth factor agents (anti-VEGF).

In the same way as medical care, successful surgical therapy of macular edema is based on good understanding of the cellular and biochemical mechanisms that the surgery triggers. Accordingly, Wolfensberger (15) considers pars plana vitrectomy and peeling internal limiting membrane success dependent on: the release of vitreomacular traction, good oxygenation of the inner retina, removal of excessive growth factors from the posterior hyaloid.

1.5. Diseases-related macular edema

Macular edema is a frequent end-result of multiple pathological insult such as diabetes, intraocular surgery (i.e. cataract extraction), intraocular inflammation, trauma and vascular retinopathies (1, 16).

1.5.1. Macular edema and retinal vascular disease

1.5.1.1. Diabetic macular edema

Diabetic retinopathy (DR) is considered as an ophthalmic complication damaging the neurovascular arrangement of the retina in diabetic patients. DR is the leading cause of new blindness and loss of vision in the world (17, 18). The later, may be directly caused by diabetic macular edema (DME), a severe consequence of DR, or by an abnormal retinal blood vessel growth (19).

Various risk factors have been identified for DR and DME, such as: systemic (20, 21) (e.g. diabetes severity and duration, hypertension, insulin resistance and deficiency, hyperlipidaemia, and hypothyroidism), lifestyle (e.g. obesity (22) and alcohol consumption (23)), inherited traits (24, 25) and specific periods of life (e.g. puberty (26, 27) and pregnancy (28)) (17, 29).

The way the DME develops depend on multiple factors but occurs more often proportionally with diabetes duration and DR severity. BRB breakdown, and consequently intra-retinal fluid build-up, is the most common event that leads to DME initiation (30, 31). Diabetes macular edema is the leading cause of vision loss in patients affected by diabetes mellitus and occurs in approximately 14% of these patients (30, 32). The condition is seen in both type of diabetes: type 1 and type 2. Ding *et al.* (18) observed DME prevalence ranging from 3% among participants within 10 years of diabetes to 20 % in those with 20 or more years of disease, without differences in between men and women. Nevertheless, the prevalence estimates are highest among African Americans and lowest among Asians. Klein *et al.* (33), in the Wisconsin Epidemiologic Study of Diabetic Retinopathy (WESDR), found that about 20% diabetes type 1 and 14-25 % of diabetes type 2, depending on insulin use or not, ended-up with DME formation over a 10 year follow-up period (18, 29).

Clinically significant macular edema (CSME) has been classified by the Early Treatment of Diabetic Retinopathy Study (ETDRS) and defined as retinal thickening of the center of the macula and its adjacent area (within 500 μm) with increase propensity for visual impairment (30, 32, 34). Ocular symptoms of DME patients are related to CSME extend and range from asymptomatic or slight blurry vision to total blindness if not treated (35). The patients very seldomly complain of partial loss of vision (e.g. scotomas) when the center of the macula is speared. Furthermore, it is not uncommon to draw the same conclusion if the macular thickening at its center is recent (36). The loss of vision is progressive, weeks to months, and can manifests as: metamorphopsia, faded colour vision that is more pronounced in bright sunlight, difficult adaptation of the vision in the darkness, and commonly, oscillation of the vision throughout the day or from one day to another (30, 36-38).

Fundoscopy use in patients affected by diabetic retinopathy is a convenient tool to identify DME as diffuse or localized thickened and depends on how severe the retinopathy is. On the other hand, FA grants the differentiation of focal and diffuse edemas leakage (9). Kim *et al.* (39) described 5 morphological models of macular edema on OCT: diffuse retinal thickening, cystoid macular edema (CME), posterior hyaloidal traction, serous retinal detachment and tractional retinal detachment with posterior hyaloidal traction.

The management of diabetic macular edema is first dedicated to control the systemic risk factors mentioned above (hyperglycemia, hypertension and hyperlipidemia). New noninvasive treatment methods use intravitreal administration to treat DME: steroids and anti-VEGF drugs (e.g. ranibizumab).

Laser photocoagulation have been used for the treatment of DME with the aim of more stabilizing visual acuity than improving the vision.

At last, vitrectomy is recommended in the case of DME with associated traction (30).

DME evolution is a slow, fluctuating process and when left untreated, the long-term prognosis is poor (30).

1.5.1.2. Retinal vein occlusions

Another frequently encountered retinal vascular vision loss causing disease usually associated with macular edema is retinal vein occlusions (RVO). As its name implies, RVO represent a blockage in the venous blood flow draining the retina and is affected by different risk factors, among which the most frequent are hypertension, diabetes, increasing age and glaucoma. Therefore, the obstruction produces an increase of the venous blood pressure and consequently homeostatic changes: swelling of the veins; hemorrhages within the retina; intraretinal extravasation of fluid (i.e. macular edema); and finally macular ischemia (16, 40-48).

RVO are classified according to the level at which the blockage is present. For this reason, RVO are referred such as: central retinal vein occlusion (CRVO) at the beginning of the optic nerve; hemiretinal vein occlusion (HRVO) at the main bifurcation of the vein; and branch retinal vein occlusion (BRVO) at further embranchment (40, 41).

RVO represent the second most common cause of blindness du to vascular impairment, after DR. RVO's prevalence and incidence vary in accordance with its classification, BRVO being more common than CRVO. BRVO prevalence in the world among men and women represent 0.4% and CRVO prevalence approximately 0.08%. The cumulative rate for both BRVO and CRVO at 15 years display the same pattern (1.8% and 0.5% respectively) (40, 41).

Clinical manifestations of RVO range from mild visual field abnormalities, if the severity is mild and the macula is speared, to loss of visual acuity. The latter is caused by retinal hemorrhages, optic nerve edema and other conditions. It is interesting to point out that the quantity of macular edema in RVO's patients changes throughout the day (low in the morning and high in the evening) (40, 41).

Conventional fundoscopy is an important primary diagnostic tool for the diagnosis and prognosis of RVO. Indeed, this technique allows differentiation of RVO into CRVO and BRVO, and also into ischemic (non-perfused) and non-ischemic (perfused) RVO.

Just as important, slit lamp biomicroscopy is obligatory for all patients affected by RVO as it enables the observation of iris neovascularization (i.e. blood vessels on the anterior surface of the iris in response to retinal ischemia).

As mentioned above, FA is the gold standard diagnostic procedure for the diagnosis and prognosis of RVO. Since it allows direct qualitative observation and localization of large retinal vessels and retinal capillary bed, and differentiation between nonperfused and perfused types. For all those reasons, FA is considered a successful method for macular edema diagnosis and follow-up. OCT is as well frequently used, in the course of RVO, to determine retinal thickness (i.e. the amount of fluid in macular edema and its localization), and any modifications in retinal arrangement (40).

In the Central Retinal Vein Occlusion, associations have been proven in between RVO, arterial hypertension and glaucoma. However, RVO risk factors management remains a debatable concern as no conclusive studies present decrease of intraocular pressure in glaucoma or improved hypertension control as visually favourable for patient affected by RVO. Laser photocoagulation has been shown to have beneficial gain on visual acuity for: CRVO patients presenting neovascularization on examination and BRVO patients with associated macular edema (40).

Intraocular injections of steroids or anti-VEGF drugs seems to have a fast and positive action on CRVO but last for a short period (40).

On the other hand, surgical treatment (i.e. vitrectomy) of RVO has a long-lasting effect. It seems that the combination of intravitreal injection of steroids and vitrectomy should allow quick and durable effect (40).

1.5.2. Macular edema and uveitis

Uveitis is an inflammation of the uveal tract and, secondarily to macular edema, can commonly lead to permanent visual loss (49).

As described above (cf. 1.2. Pathogenesis), homeostasis prevails in retinal layers thanks to the compensatory mechanisms. However, in the case of inflammation (acute or chronic), triggered by traumatic, immune or infectious mechanisms, the equilibrium is disturbed and it results in uveitic macular edema (UME). The latter, affects 20-30% of patients with uveitis and 60% or higher when uveitis lasts for more than a year. UME is the most common cause of vision loss in patient affected by uveitis. It is interesting to note that UME tends to happen in younger population (30-50 years old) (50).

Uveitis symptoms are based on the duration of the disease. Therefore, in acute condition, patients can complain of pain, redness, photophobia, blurred vision, lacrimation; in chronic condition, they mainly complain of blurred vision and mild redness (51). Importantly, UME particularly affects vision-related quality of life: reading acuity, speed (words per minute) and distance visual acuity (VA) are diminished (50, 52).

Diagnostic techniques used to identify the vasculature involved in uveitis are indocyanine green angiography (ICGA) and FA. ICGA is a water-soluble fluorescent molecule, intravenously injected and allows better visualisation of choroidal vasculature compared to FA that shows retinal vessels better.

OCT in the course of uveitis is a superior diagnostic tool to determine any alteration at the vitreoretinal border, inflammation of the epiretinal membrane and most importantly uveitic macular edema (9, 50).

The first important step in the management of uveitis is the administration of anti-inflammatory drugs in order to control the inflammation. They often lead to resolution of the edema in the case of nonischemic, nonatrophic macular edema. Therefore, oral and local steroids delivery are good first-choice agents but their use should be temporary because of the possible side effects. Newly developed systemic immunomodulators (i.e. biologic agents) show promising result for the control of inflammation (50).

Unfortunately, anti-inflammatory drugs potency is not the same for every patient. For this reason, retinal pigmented epithelium (RPE) pump stimulator have been used to thwart the inflammatory effect with more or less conclusive result (50).

Finally, well timed surgical intervention improves the vision and reduces injuries from previous inflammatory insults. Moreover, advanced UVE with vitreomacular traction can be managed by vitrectomy (50).

1.5.3. Postoperative cystoid macular edema

Postoperative cystoid macular edema (PCME) represents an abnormal accumulation of fluid in the macula and is responsible of blurred or distorted vision following operative procedures, such as: cataract surgery (known as Irvine-Gass syndrome), vitreoretinal surgery; and more severely after neodymium:yttrium-aluminum-garnet (Nd:YAG) capsulotomy, penetrating keratoplasty, scleral buckling, filtering procedures, and panretinal photocoagulation (53).

CME etiology is not fully understood and remains hypothesis. The first hypothesis presents CME etiology as a macular prolapse caused by traction of the vitreous. The second, being the main theory, is based on the inherent inflammatory reaction triggered by surgical procedures that causes edema as a consequence of inflammatory mediators' release (e.g. prostaglandins) (53). As explained above (cf. 1.2. Pathogenesis), the inflammation increases the permeability of the retinal layers by disrupting the blood-retinal barrier.

Chu *et al.* (54) reported a clinical CME incidence of 1.17-4.04% following modern cataract surgery performed by phacoemulsification. Angiographically proven CME is much more common with incidence ranging from 20% up to 70% depending on the studies (55). When considering CME diagnosed by optical coherence tomography (OCT) the incidence is between 4 and 10.9%.

Various risk factors promote the development of PCME and it is of utmost importance to identify them in order to prevent any visual alteration and provide the appropriate treatment. There are three main risks for CME to occur postoperatively: systemic factors, complicated surgery and previous ocular diseases.

Systemic risk factors are principally diabetes mellitus and systemic hypertension. They both increase the incidence of PCME.

Thanks to the introduction of new surgical procedures, such as phacoemulsification (cataract surgery), the PCME incidence have remarkably decreased and PCME is not anymore the principal consequence of intraoperative complications. However, surgical complications are still a recurrent risk increasing the likelihood of CME.

Last but not least, pre-operative ocular conditions increase the risk for PCME, this includes: uveitis, diabetic retinopathy, retinal vein occlusion, etc. Interestingly, pre-operative drugs used in glaucoma patients increase the rate of CME (53).

Patients affected by PCME complain of visual symptoms (e.g. diminished visual acuity, eye redness, ocular irritation) mostly 4-12 weeks after the operation.

On slit-lamp examination the most common sign of CME is a flattened fovea that is usually having a characteristic depressed appearance. However, biomicroscopy is not the most accurate diagnostic method as it misses 5-10% of the time CME.

In consequence, more precise methods like FA or OCT are more commonly used in unsure PCME cases. OCT has the advantage to be noninvasive and able to quantify the evolution of the edema. Nonetheless, FA allows to define angiographic CME (i.e. leakage of fluorescein on FA examination of CME).

Thanks to the diagnostic techniques mentioned, PCME has been classified in 4 different degrees: acute (within 4 months postoperatively), late (more than 4 months postoperatively), chronic (more than 6 months postoperatively), and recurrent (53).

Interestingly, most of PCME cases resolve spontaneously with time. Zur *et al.* (53) have taken into consideration the newest available treatments and proposed, according to them, the best logical order for the management of PCME. Firstly, treatment of PCME with a combination of topical NSAIDs (e.g. ketorolac tromethamine, diclofenac or nepafenac) and topical steroids (i.e. prednisolone). Second-line treatment involves steroid (i.e. triamcinolone) sub-Tenon injection and intravitreal injection, with or without anti-VEGF agents, if the former is ineffective. At last, in the case of persistent inflammatory reaction, vitrectomy is advised.

Therefore, the literature has not yet provided enough evidence regarding the results of pars plana vitrectomy (PPV) on non-existing and existing macular edema prior to surgery. Furthermore, there is a lack of information concerning the persistence of postoperative macular edema after pars plana vitrectomy. All of that reinforces our idea to conduct the necessary investigations to help answer these incertitudes.

2. OBJECTIVES

AIMS:

1. Determine the impact of pars plana vitrectomy on the evolution of pre-existing and non-existing macular edema.
2. Determine the quantitative persistence of macular edema postoperatively throughout time.

HYPOTHESIS:

1. The macular thickness of non-existing macular edema prior to surgery will be significantly increased after PPV.
2. The macular thickness of existing macular edema prior to surgery will be significantly decreased after PPV.
3. Delayed postoperative macular edema will persist over time.

3. MATERIALS AND METHODS

3.1. Ethical background of data collection

All data used for this thesis was obtained at the Ophthalmology outpatient department of University Hospital of Split, and was approved by the Ethics Committee of University Hospital of Split.

3.2. Study purpose

On the basis of findings, from a study reviewing patients affected by macular edema after surgical interventions of the eye (53), the decision was made to conduct the study.

The purpose of the study was to evaluate the impact of pars plana vitrectomy on non-existing and pre-existing macular edema prior to surgery, and to assess the persistence of macular edema after PPV with the help of OCT.

3.3. Subjects

The retrospective study included 91 eyes in 91 patients, with 51 right eyes and 40 left eyes, for 30 women and 61 men who were affected by postoperative cystoid macular edema. Participants were middle to older aged adults, ranging from 32-85 years with an average patient age of 68,5 years.

Data were collected from the 10th of February 2015 until the 16th of November 2018. Data have been systemized and analysed from the 26th of March 2018 until the 1st of June 2018.

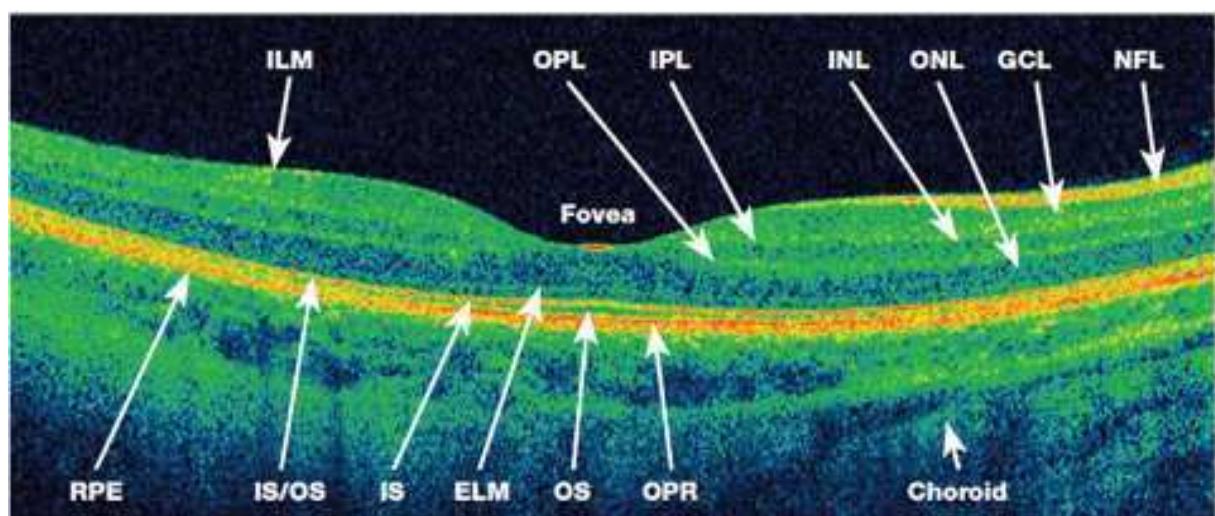
All patients included in the study have had pars plana vitrectomy (PPV).

3.4. Methods

Ninety-one patients were included in the study and has many eyes underwent pars plana vitrectomy. No preoperative treatment was intended in any of the patients. Postoperative treatment has been the same for all the 91 patients: topical eye drops composed of a combination of steroids (dexamethasone) and antibiotics (neomycin and polymyxin b) that were administered 3 to 4 times per day for 3 weeks.

The data were collected with a Zeiss Cirrus HD-OCT (Cirrus version 6.1 software) and macular cube 512 × 128 protocol.

Preoperative OCT results were gathered within 1 month to 1 year prior to surgery. In addition, the 1st, 2nd and 3rd OCT postoperative check-up were collected approximately a week, a month, and 3 months postoperatively. Spectral domain optical coherence tomography (SD-OCT) measurements included four main information about the macula: central subfield thickness (CST), cube volume (CV), cube average thickness (CAT), and macular foveal thickness (MFT). The latter, have been manually measured for each patient OCT scan. The measure was performed from the retinal pigmented membrane until the foveal groove at the fovea centralis (Figure 6). A MFT value superior to 220 μm was considered as the threshold for macular edema (56).



NFL: Nerve fiber layer	OPL: Outer plexiform layer	IS/OS: Interface between IS and OS
ILM: Inner limiting membrane	ONL: Outer nuclear layer	RPE: Retinal pigment epithelium
GCL: Ganglion cell layer	ELM: External limiting membrane	OPR: Outer photoreceptor/ RPE complex
IPL: Inner plexiform layer	IS: Photoreceptor inner segment	
INL: Inner nuclear layer	OS: Photoreceptor outer segment	

Figure 6. The retinal architecture of a healthy eye on OCT scan.

The study outcome measures were CST, CV, CAT and MFT. The Early Treatment Diabetic Retinopathy Study (ETDRS) has defined clinical significant macular edema (CSME) and divided the macula into nine different areas (Figure 7) (34). The SD-OCT automatically calculates: CST as the mean thickness of the central circle that is 1 mm in diameter and is expressed in μm ; CV as the sum of all nine retinal regions volume, normal CV is 6mm x 6mm and is expressed in mm^3 ; CAT is the macular cube average thicknesses of the retina, measured

from the ILM to the RPE, and expressed in μm ; MFT is the mean macular foveal thickness and, as mentioned above, is measured manually and expressed in μm (Figure 8).

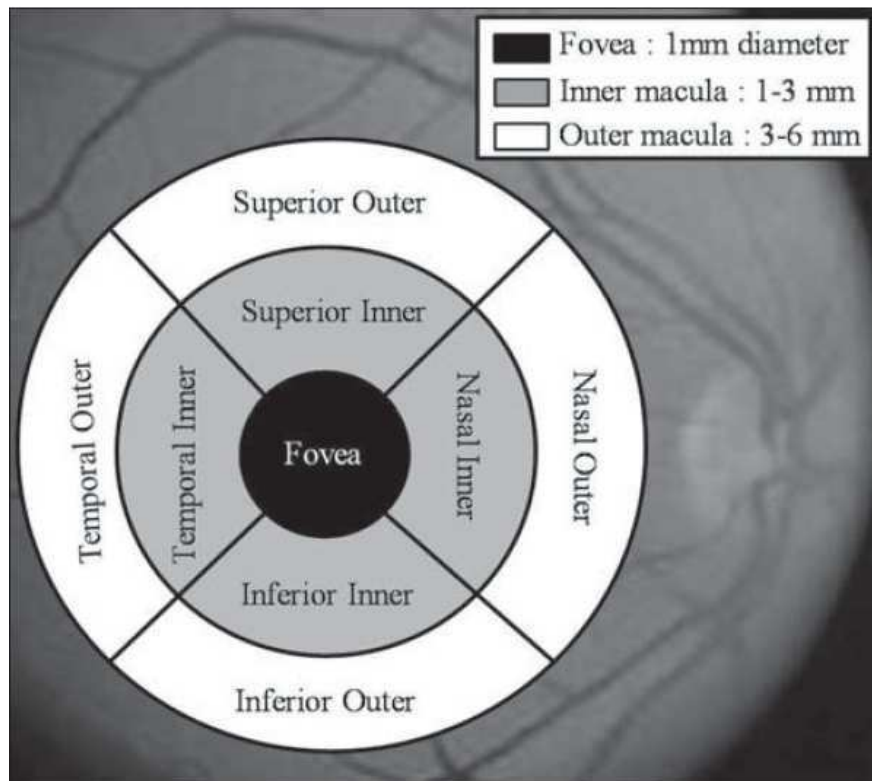


Figure 7. ETDRS areas of the macula as measured by fast macula program of OCT (57).

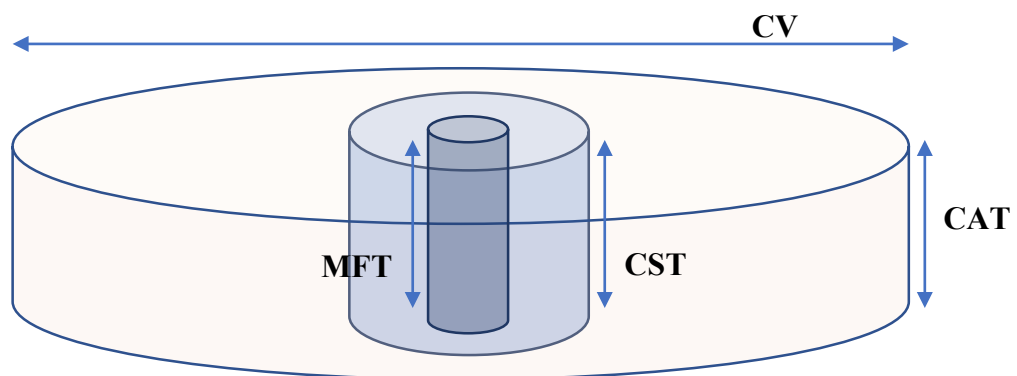


Figure 8. Macular foveal thickness (MFT), central subfield thickness (CST), cube average thickness (CAT) and cube volume (CV) representation of the macula.

3.5. Statistical methods

Statistical analysis was performed using the statistical software Statistica 12 (StatSoft Inc., Tulsa, OK, USA) applying Chi square test and Wilcoxon matched pairs test. Chi square test was performed to measure the differences existing in the sample. Wilcoxon matched pairs test was used to analyse the impact of surgery on macular thickness and the persistence of macular edema over time. The statistical significance value was set at $P < 0.05$.

4. RESULTS

4.1. Baseline Characteristics

The retrospective study included 91 eyes in 91 patients, with 51 right eyes (56 %) and 40 left eyes (44%), for 30 women (33%) and 61 men (67%) who were affected by postoperative cystoid macular edema. Participants were middle to older aged adults, ranging from 32-85 years with an average patient age of 68,5 years (CI 65-71) (Table 1).

There was statistical significant difference in between the number of men and women involved in the study, with a majority of men 67% ($P=0.001$). On the other hand, no statistical significant difference was observed in between the left and the right eyes ($P=0.249$).

In preoperative database, 55 patients out of 91 patients included in the study have had a preoperative optic coherence tomography (OCT) recording (60.4% of total sample). In postoperative database, 76 patients have had a single postoperative OCT recording (83.5% of total sample); 35 patients have had a second postoperative OCT recording (38.5% of total sample); 15 patients have had a third postoperative OCT recording (16.5% of total sample).

Table 1. Demographic data

Characteristic	N (%)	P*
Gender		0.001
Male	61 (67)	
Female	30 (33)	
Eye		0.249
Right	51 (56)	
Left	40 (44)	
Preoperative OCT	55 (60,4)	
Postoperative OCT		
1	76 (83.5)	
2	35 (38.5)	
3	15 (16.5)	
4	6 (6.6)	
5	4 (4.4)	
6	2 (2.2)	
7	1 (1.1)	

Data are presented as median or as general number (%)

*empirical p value of Chi square test

The results for 37 of the 91 eyes were excluded from the study because of absent preoperative OCT measures. Indeed, preoperative OCT data are not possible to be obtain in patients affected by certain eye conditions, such as: haemophthalmus, retinal detachments, severe vitreous opacities, etc. Additionally, the results for 14 eyes were not included because of the absence of the first postoperative OCT scan. Consequently, 51 eyes were excluded from the study and 40 eyes having both preoperative and first postoperative OCT check-up were able to be compared. Among the 40 eyes, 6 had non-existing macular edema preoperatively and the rest were considered has pre-existing preoperative macular edema (i.e. 34 eyes). Complete OCT data on the 2nd check-up were available for 35 eyes as 5 participants dropped out from the study (Figure 8).

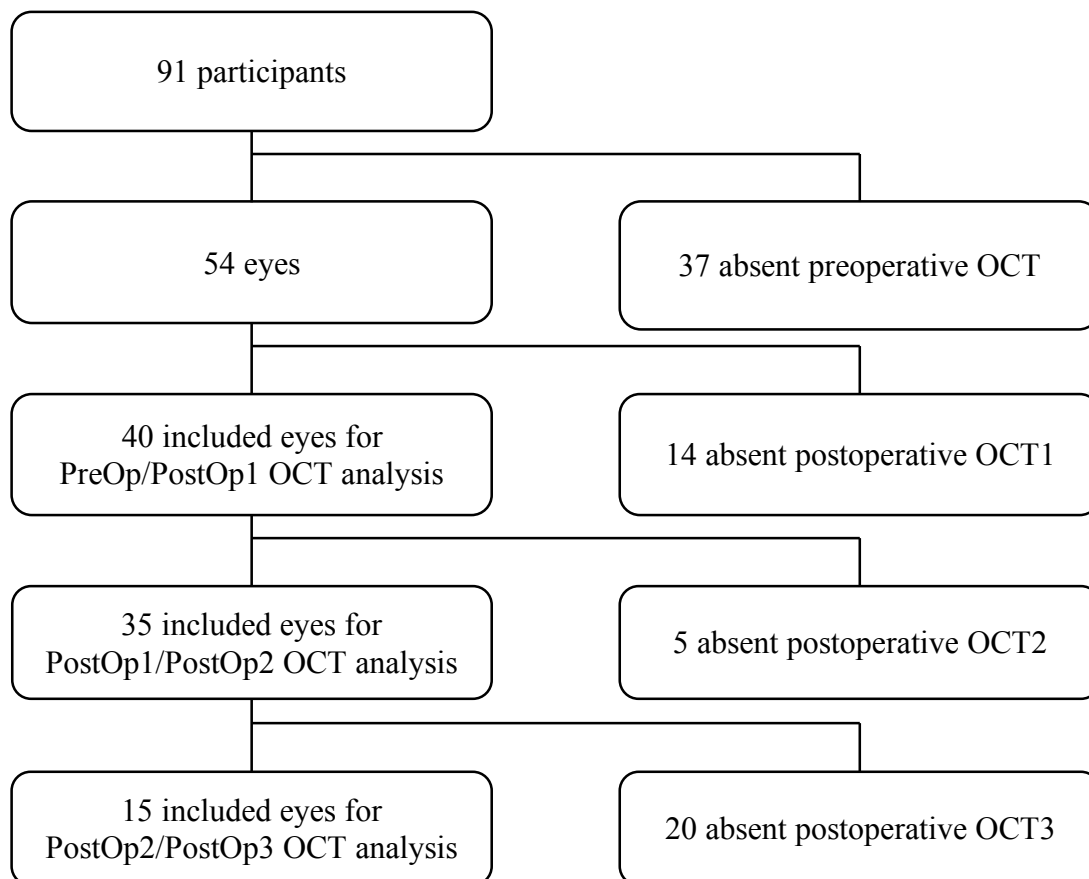


Figure 8. Study flow chart. PreOp = preoperative OCT; PostOp1 = 1st postoperative OCT; PostOp2 = 2nd postoperative OCT; PostOp3 = 3rd postoperative OCT.

4.2. Study Outcome

SD-OCT measurements included four main information about the macula: central subfield thickness (CST), cube volume (CV), cube average thickness (CAT), and macular foveal thickness (MFT in μm). MFT have been manually measured for each patient OCT scan. The measure was performed from the retinal pigmented membrane until the foveal groove at the fovea centralis.

4.2.1. Preoperative and first postoperative OCT recordings comparison

There was significant difference in between preoperative macular thickness compared to postoperative macular thickness. CST, CV, CAT and MFT were significantly decreased on first optical coherence tomography (OCT1) ($P=0.004$, $P=0.016$, $P=0.026$, $P=0.047$). CST, CV, CAT and MFT measurements were compared for 40 matched pairs eyes (Table 2).

Table 2. Preoperative and postoperative 1 OCT data comparison

Parameters	Preoperative OCT	Postoperative OCT1	Differences	
	Median (IQR)	Median (IQR)	Z	P*
CST	344 (264-468)	297 (244-352)	2.91	0.004
CV	11 (10-13)	11 (10-12)	2.40	0.016
CAT	300 (279-341)	295 (281-324)	2.22	0.026
MFT	325 (230-444)	239 (188-362)	1.98	0.047

Data are presented as median with interquartile range.

* Wilcoxon Matched Pairs Test

There was significant difference in between preoperative OCT data compared to OCT1 in patients with existing macular edema prior to PPV. Indeed, CST, CV, CAT and MFT have significantly been decreased on 1st postoperative visit ($P=0.002$; $P=0.007$; $P=0.008$; $P=0.026$). Preoperative macular edema and its postoperative evolution has been compared thanks to CST, CV, CAT and MFT in 34 matched pairs eyes with pre-existing macular edema ($\text{MFT}>220 \mu\text{m}$) (Table 3).

On the other hand, there was no significant difference in between the macular thickness preoperative OCT measurements compared to postoperative OCT 1 in patients without macular edema prior to surgery. CST, CV, CAT and MFT were analysed in 6 matched pairs eyes with non-existing macular edema before PPV ($MFT \leq 220 \mu m$) (Table 4).

Table 3. Preoperative and first postoperative OCT data comparison in 34 patients affected by macular edema prior to PPV.

Parameters	Preoperative	Postoperative OCT1	Differences	
	Median (IQR)	Median (IQR)	Z	P*
CST	389 (338-496)	323 (286-431)	3.06	0.002
CV	11.7 (10.7-13.8)	10.9 (10.4-12.2)	2.66	0.007
CAT	325 (298-384)	304 (290-338)	2.64	0.008
MFT	378 (311-460)	344 (241-467)	2.22	0.026

Data are presented as median with interquartile range.

* Wilcoxon Matched Pairs Test

Table 4. Preoperative and postoperative OCT data comparison in 6 patients not affected by macular edema prior to PPV

Parameters	Preoperative OCT	Postoperative OCT1	Differences
	Median (IQR)	Median (IQR)	P*
CST	256 (242-305)	268 (224-350)	1.000
CV	10.3 (10-10.5)	10.4 (10.2-12.2)	0.625
CAT	286 (279-290)	288 (282-338)	0.563
MFT	189 (170-201)	203 (148-276)	0.463

Data are presented as median with interquartile range.

* Wilcoxon Matched Pairs Test

4.2.2. First postoperative and second postoperative OCT follow-up comparison

There was significant difference in between the macular thickness in the first postoperative OCT (OCT1) compared to the second postoperative OCT (OCT2). CAT and MFT were significantly increased on OCT2 follow-up ($P=0.019$, $P=0.015$) while CV stayed the same. However, there was no significant difference in CST after the second OCT ($P=0.130$). Five patients did not have OCT2, thus, the comparison has included 35 matched pairs eyes (Table 5).

Table 5. Postoperative 1 and postoperative 2 OCT recordings comparison

Parameters	Postoperative 1	Postoperative 2	Differences	
	Median (IQR)	Median (IQR)	Z	P*
CST	297 (244-352)	329 (271-415)	1.51	0.130
CV	11 (10-12)	11 (10-12)	2.35	0.019
CAT	295 (281-324)	301 (276-326)	2.35	0.019
MFT	239 (188-362)	313 (201-410)	2.44	0.015

Data are presented as median with interquartile range.

* Wilcoxon Matched Pairs Test

4.2.3. Second postoperative and third postoperative OCT follow-up comparison

There was significant difference in between postoperative OCT2 macular thickness compared to postoperative OCT 3 (OCT3) macular thickness. CST, CV and MFT were significantly decreased on OCT3 ($P=0.020$, $P=0.017$, $P=0.013$). Nevertheless, CAT has shown no significant difference in between postoperative OCT2 and OCT3 follow-up ($P=0.389$). Since twenty patients did not have OCT3, 15 matched pairs eyes were compared on the third check-up (Table 6).

Table 6. Postoperative 2 and postoperative 3 OCT recordings comparison

Parameters	Postoperative 2	Postoperative 3	Differences
	Median (IQR)	Median (IQR)	P*
CST	301 (285.5-335)	292 (277-320)	0.020
CV	10.8 (10.3-12.1)	10.5 (10-11.5)	0.017
CAT	369 (274-463)	325 (259-393)	0.389
MFT	319 (225-504)	319 (210-377)	0.013

Data are presented as median with interquartile range.

* Wilcoxon Matched Pairs Test

4.2.4. Summary of study outcome

At study conclusion, it is interesting to note that macular edema has been influenced by pars plana vitrectomy, the Figure 10, 11 and to a lesser extent Figure 12 are representative of the impact of surgery. Furthermore, postoperative discrepancy of the different OCT data collected illustrate well the difficulty to get rid of macular edema.

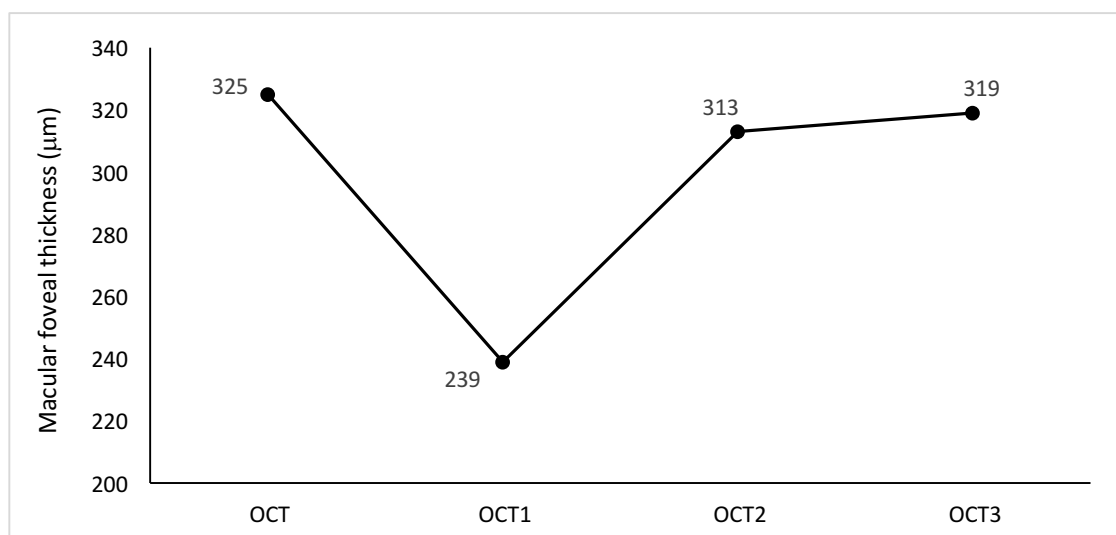


Figure 10. Average macular foveal thickness (MFT) (μm) in all included patients at different OCT follow-up. OCT = preoperative OCT; OCT1 = postoperative OCT1; OCT2 = postoperative OCT2. OCT3 = postoperative OCT3.

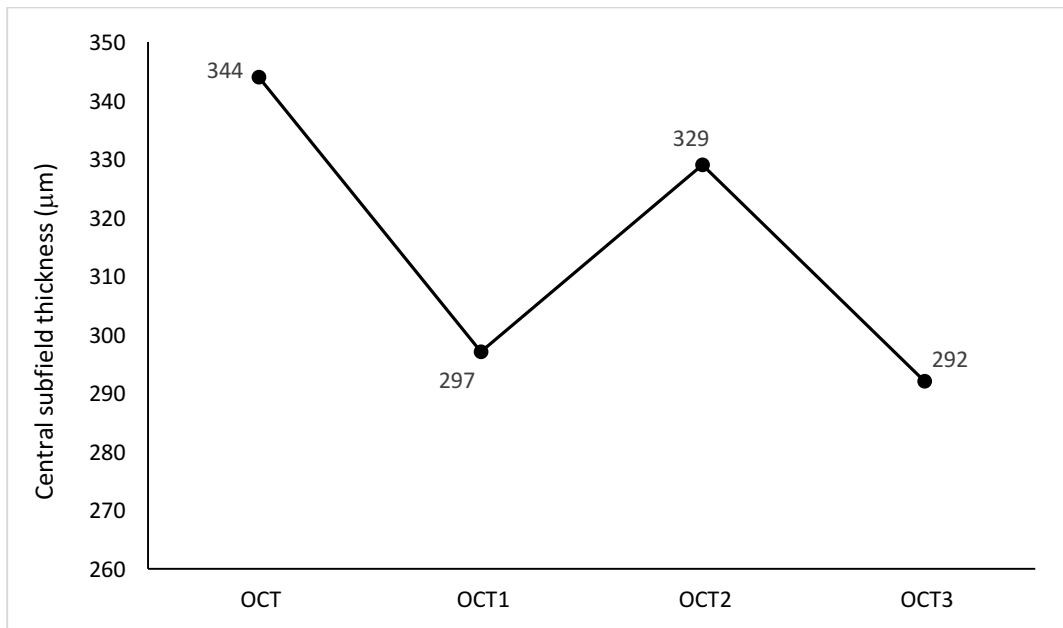


Figure 11. Average central subfield thickness (CST) (μm) in all included patients at different OCT follow-up. OCT = preoperative OCT; OCT1 = postoperative OCT1; OCT2 = postoperative OCT2. OCT3 = postoperative OCT3.

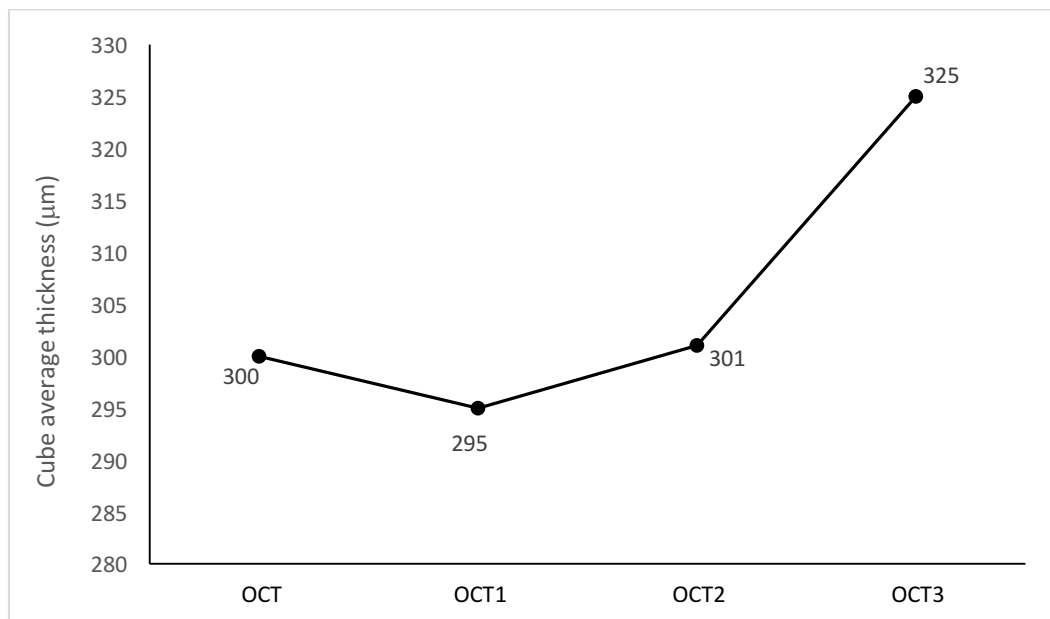


Figure 12. Median cube average thickness (CAT) (μm) in all included patients at different OCT follow-up. OCT = preoperative OCT; OCT1 = postoperative OCT1; OCT2 = postoperative OCT2. OCT3 = postoperative OCT3.

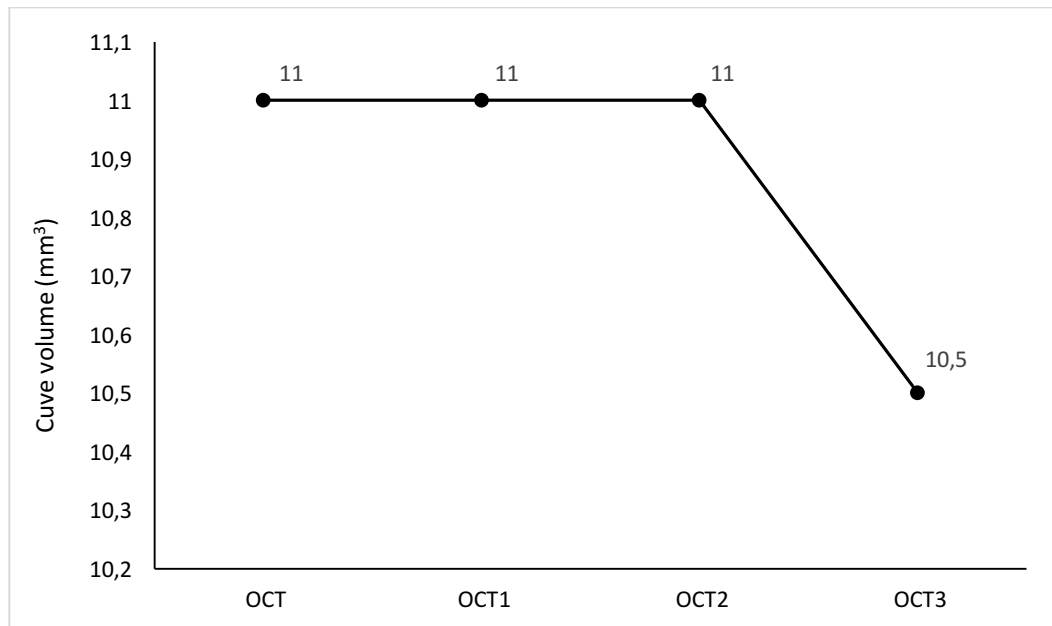


Figure 13. Average cube volume (CV) (mm³) in all included patients at different OCT follow-up. OCT = preoperative OCT; OCT1 = postoperative OCT1; OCT2 = postoperative OCT2. OCT3 = postoperative OCT3.

5. DISCUSSION

Macular edema (ME) knock-on effect is triggered by the accumulation of fluid, which leads to an alteration of the retinal architecture and consequently to loss of vision. The expansion of fluid in the macula begins in the outer plexiform layer and extend towards the inner nuclear and inner plexiform layers of the retina (Figure 1 and 2). The thickening of the central portion of the macula around the fovea characterizes macular edema (1).

The diagnosis of macular edema has been possible thanks to distinct observational methods. On the basis of detecting postsurgical macular edema, optical coherence tomography (OCT) is of upmost accuracy (53). OCT use allowed us to evaluate the impact of pars plana vitrectomy (PPV) on macular edema and its persistence over time.

Macular edema is a slow, fluctuating process and can be caused by different eye conditions, such as: diabetic retinopathy, retinal vein occlusion, uveitis, intraocular surgery, etc. (1) For this reason, a multitude of treatment strategies have been implemented in order to reduce and solve macular edema (15).

Our study aimed to determine the impact and persistence of macular edema after pars plana vitrectomy.

In this study, we have found that macular thickness (MT), represented by macular foveal thickness (MFT), central subfield thickness (CST), cube average thickness (CAT) and cube volume (CV), was significantly reduced on OCT after pars plana vitrectomy (Table 2). The results tended to be similar when we only considered preoperative participants (34 eyes) with existing macular edema prior to surgery (Table 3). In view of our results, it seems that PPV helps to decrease pre-existing macular edema (Table 2 and 3).

Our study results are supported by different theories in the literature. Firstly, in the case of vitreomacular traction, PPV releases the traction pressure which leads to reduced blood vessels leakage into the retinal tissue (58). Secondly, in the case of macular edema of vascular origin (e.g. diabetic retinopathy and retinal vein occlusion), vitrectomy has been proven to increase the transport of oxygen in the eye and to remove excessive inflammatory growth factors, thus decreasing macular edema (58). Finally, peeling of the internal limiting membrane performed seems to be another beneficial effect of PPV for reducing macular edema (59).

Depending on the analysed mean, the evolution of postoperative macular edema, in our study, is not following the same pattern throughout time. Indeed, MFT, CST and CAT are increased in between OCT follow-up one (OCT1) and two (OCT2), unlike CV that stayed constant. On the other hand, when comparing OCT follow-up two and three (OCT3): CST and CV are decreased but most importantly, MFT is constant or slightly increased and CAT is increased (Figure 10,11,12 and 13). Therefore, along OCT check-ups, the evolution of post-

pars plana vitrectomy macular edema tend to be persistent over time and to follow the same pattern as post-cataract surgery macular edema. Accordingly, postsurgical macular edema seems to not only be a long-term complication of cataract surgery but as well a long-term complication of pars plana vitrectomy. We can suppose, following the last sentence assumption, that most post-PPV macular edema cases resolve spontaneously after a certain time with only a small percentage reaching clinical relevance (53).

For further investigations of recalcitrant macular edema after vitreoretinal surgery, it would be first interesting to include a bigger number of participants and includes more subjects with non-existing macular edema prior to surgery. Secondly, preoperative and postoperative OCT follow-ups should be scheduled at regular time intervals for all participants (e.g. within a month preoperatively, at 4 months, 6 months and a year postoperatively). Furthermore, participants should as well be evaluated according to the condition that caused them the necessity to have vitrectomy. Moreover, macular foveal thickness should be measured manually by an ophthalmologist that is experienced in the use and interpretation of optical coherence tomography in order to limit the bias inherent to this process. Finally, OCT scans that yielded poor image quality and scans with signal strength below 5 should be disregarded for better analysis of OCT measurements (MFT, CST, CAT, CV).

6. CONCLUSIONS

1. The macular thickness of non-existing macular edema prior to surgery has not be significantly increased after pars plana vitrectomy (PPV).
2. Macular thickness of existing macular edema prior to surgery was significantly decreased after PPV.
3. Macular edema after vitreoretinal surgery has a tendence to develop not immediately after surgery and to persist in time if not timely recognized and properly treated.

7. REFERENCES

1. Coscas G, Cunha-Vaz J, Soubrane G. Macular Edema: Definition and Basic Concepts. *Dev Ophthalmol*. 2017;58:1-10.
2. Cunha-Vaz J, Bernardes R, Lobo C. Blood-retinal barrier. *Eur J Ophthalmol*. 2011;21 Suppl 6:S3-9.
3. Campbell M, Humphries P. The Blood-Retina Barrier Tight Junctions and Barrier Modulation. In: Yan Cheng C, editor. *Biology and Regulation of Blood Tissue Barriers Advances in experimental medicine and biology*. New-York: Landes Bioscience; 2013. 70-84.
4. Cunha-Vaz J. Mechanisms of Retinal Fluid Accumulation and Blood-Retinal Barrier Breakdown. *Dev Ophthalmol*. 2017;58:11-20.
5. Cunha-Vaz J, Faria de Abreu JR, Campos AJ. Early breakdown of the blood-retinal barrier in diabetes. *Br J Ophthalmol*. 1975;59(11):649-56.
6. Hogan M, Alvarado J, Weddell J. Histology of the Human Eye. In: Hogan M, editor. Philadelphia: WB Saunders; 1971.
7. Marmor MF. Mechanisms of fluid accumulation in retinal edema. *Doc Ophthalmol*. 1999;97(3-4):239-49.
8. Koeppen B, Stanton B. *Berne & Levy Physiology*. 6th ed. Philadelphia: Elsevier; 2008.
9. Staurenghi G, Pellegrini M, Invernizzi A, Preziosa C. Diagnosis and Detection. *Dev Ophthalmol*. 2017;58:39-62.
10. Gonzalez M, Gonzalez C, Stern M, Arredondo B, Martinez S. Diabetes Study Retinopathy Group: Concordance in diagnosis of diabetic retinopathy by fundus phtography between retina specialists and a standardized reading center. *Arch Med Res*. 1995;26:127-31.
11. Cunha-Vaz J, Travassos A. Breakdown of the blood-retinal barriers and cystoid macular edema. *Surv Ophthalmol*. 1984;28:485-92.
12. Snodderly D, Weinhaus R, Choi J. Neural-vascular relationships in central retina of macaque monkeys (*Macaca fascicularis*). *J Neurosci*. 1992;12:1169-93.
13. Weinhaus R, Burke J, Delori F, Snodderly D. Comparison of fluorescein angiography with microvascular anatomy of macaque retina. 1995;61:1-16.
14. Spaide RF, Klancnik JM, Jr., Cooney MJ. Retinal vascular layers imaged by fluorescein angiography and optical coherence tomography angiography. *JAMA Ophthalmol*. 2015;133:45-50.
15. Wolfensberger TJ. Macular Edema - Rationale for Therapy. *Dev Ophthalmol*. 2017;58:74-86.

16. Tranos PG, Wickremasinghe SS, Stangos NT, Topouzis F, Tsinopoulos I, Pavesio CE. Macular edema. *Surv Ophthalmol*. 2004;49:470-90.
17. Cohen SR, Gardner TW. Diabetic Retinopathy and Diabetic Macular Edema. *Dev Ophthalmol*. 2016;55:137-46.
18. Ding J, Wong TY. Current epidemiology of diabetic retinopathy and diabetic macular edema. *Curr Diab Rep*. 2012;12:346-54.
19. Crawford TN, Alfaro DV, Kerrison JB, Jablon EP. Diabetic retinopathy and angiogenesis. *Curr Diabetes Rev*. 2009;5:8-13.
20. Antonetti DA, Barber AJ, Bronson SK, Freeman WM, Gardner TW, Jefferson LS, et al. Diabetic retinopathy: seeing beyond glucose-induced microvascular disease. *Diabetes*. 2006;55:2401-11.
21. Girach A, Vignati L. Diabetic microvascular complications--can the presence of one predict the development of another? *J Diabetes Complications*. 2006;20:228-37.
22. Cheung N, Wong TY. Obesity and eye diseases. *Surv Ophthalmol*. 2007;52(2):180-95.
23. Wang S, Wang JJ, Wong TY. Alcohol and eye diseases. *Surv Ophthalmol*. 2008;53:512-25.
24. Liew G, Klein R, Wong TY. The role of genetics in susceptibility to diabetic retinopathy. *Int Ophthalmol Clin*. 2009;49:35-52.
25. Abhary S, Hewitt AW, Burdon KP, Craig JE. A systematic meta-analysis of genetic association studies for diabetic retinopathy. *Diabetes*. 2009;58:2137-47.
26. Donaghue KC, Fairchild JM, Craig ME, Chan AK, Hing S, Cutler LR, et al. Do all prepubertal years of diabetes duration contribute equally to diabetes complications? *Diabetes Care*. 2003;26:1224-9.
27. Olsen BS, Sjolie AK, Hougaard P, Johannesen J, Marinelli K, Jacobsen BB, et al. The significance of the prepubertal diabetes duration for the development of retinopathy and nephropathy in patients with type 1 diabetes. *J Diabetes Complications*. 2004;18:160-4.
28. Klein BE, Moss SE, Klein R. Is menarche associated with diabetic retinopathy? *Diabetes Care*. 1990;13:1034-8.
29. Cheung N, Mitchell P, Wong TY. Diabetic retinopathy. *Lancet*. 2010;376(9735):124-36.
30. Bandello F, Battaglia Parodi M, Lanzetta P, Loewenstein A, Massin P, Menchini F, et al. Diabetic Macular Edema. *Dev Ophthalmol*. 2017;58:102-38.

31. Antonetti DA, Lieth E, Barber AJ, Gardner TW. Molecular mechanisms of vascular permeability in diabetic retinopathy. *Semin Ophthalmol.* 1999;14:240-8.
32. Girach A, Lund-Andersen H. Diabetic macular oedema: a clinical overview. *Int J Clin Pract.* 2007;61:88-97.
33. Klein R, Klein BE, Moss SE, Cruickshanks KJ. The Wisconsin Epidemiologic Study of Diabetic Retinopathy. XV. The long-term incidence of macular edema. *Ophthalmology.* 1995;102:7-16.
34. Photocoagulation for diabetic macular edema. Early Treatment Diabetic Retinopathy Study report number 1. Early Treatment Diabetic Retinopathy Study research group. *Arch Ophthalmol.* 1985;103(12):1796-806.
35. Eldem B, Ozdek S, Saatci AO, Ozmert E, Ulay E, Nomak G. Clinical Characteristics of Patients with Newly Diagnosed Diabetic Macular Edema in Turkey: A Real-Life Registry Study-TURK-DEM. *J Ophthalmol.* 2017;2017:3596817.
36. Musat O, Cernat C, Labib M, Gheorghe A, Toma O, Zamfir M, et al. Diabetic Macular Edema. *Rom J Ophthalmol.* 2015;59:133-6.
37. Yanoff M, Duker JS. *Ophthalmology.* 4th Edition ed. London: Elsevier; 2013. 600-715.
38. Bowling B. *Kanski's Clinical Ophthalmology: A Systemic Approach.* Elsevier; 2015. 615-68.
39. Kim BY, Smith SD, Kaiser PK. Optical coherence tomographic patterns of diabetic macular edema. *Am J Ophthalmol.* 2006;142:405-12.
40. Jonas JB, Mones J, Glacet-Bernard A, Coscas G. Retinal Vein Occlusions. *Dev Ophthalmol.* 2017;58:139-67.
41. Ip M, Hendrick A. Retinal Vein Occlusion Review. *Asia Pac J Ophthalmol (Phila).* 2018;7:40-5.
42. Hayreh SS. Occlusion of the central retinal vessels. *Br J Ophthalmol.* 1965;49:626-45.
43. Hayreh SS. Classification of central retinal vein occlusion. *Ophthalmology.* 1983;90:458-74.
44. Hayreh SS, Klugman MR, Beri M, Kimura AE, Podhajsky P. Differentiation of ischemic from non-ischemic central retinal vein occlusion during the early acute phase. *Graefes Arch Clin Exp Ophthalmol.* 1990;228:201-17.
45. Coscas G, Dhermy P. [Retinal venous occlusions]. *Bull Mem Soc Fr Ophtalmol.* 1978;90:1-30.
46. Coscas G, Gaudric A. Natural course of nonaphakic cystoid macular edema. *Surv Ophthalmol.* 1984;28 Suppl:471-84.

47. A randomized clinical trial of early panretinal photocoagulation for ischemic central vein occlusion. The Central Vein Occlusion Study Group N report. *Ophthalmology*. 1995;102:1434-44.
48. Baseline and early natural history report. The Central Vein Occlusion Study. *Arch Ophthalmol*. 1993;111:1087-95.
49. de Smet MD. Insights into the Physiopathology of Inflammatory Macular Edema. *Dev Ophthalmol*. 2017;58:168-77.
50. de Smet MD, Okada AA. Cystoid macular edema in uveitis. *Dev Ophthalmol*. 2010;47:136-47.
51. Bagheri N, Wajda BN. *The Wills eye manual : office and emergency room diagnosis and treatment of eye disease*. 5th ed. Philadelphia, PA: 2008.
52. Kiss CG, Barisani-Asenbauer T, Maca S, Richter-Mueksch S, Radner W. Reading performance of patients with uveitis-associated cystoid macular edema. *Am J Ophthalmol*. 2006;142:620-4.
53. Zur D, Loewenstein A. Postsurgical Cystoid Macular Edema. *Dev Ophthalmol*. 2017;58:178-90.
54. Chu CJ, Johnston RL, Buscombe C, Sallam AB, Mohamed Q, Yang YC, et al. Risk Factors and Incidence of Macular Edema after Cataract Surgery: A Database Study of 81984 Eyes. *Ophthalmology*. 2016;123:316-23.
55. Rotsos TG, Moschos MM. Cystoid macular edema. *Clin Ophthalmol*. 2008;2:919-30.
56. Chan A, Duker JS, Ko TH, Fujimoto JG, Schuman JS. Normal macular thickness measurements in healthy eyes using Stratus optical coherence tomography. *Arch Ophthalmol*. 2006;124:193-8.
57. Pradhan Z, Braganza A, Abraham L. Determinants of macular thickness in normal Indian eyes. *J Clin Ophthalmol Res*. 2013;1:11-6.
58. Stefansson E. Physiology of vitreous surgery. *Graefes Arch Clin Exp Ophthalmol*. 2009;247:147-63.
59. Park DH, Kim IT. Long-term effects of vitrectomy and internal limiting membrane peeling for macular edema secondary to central retinal vein occlusion and hemiretinal vein occlusion. *Retina*. 2010;30:117-24.

8. SUMMARY

A RETROSPECTIVE STUDY OF RECALCITRANT MACULAR EDEMA FOLLOWING VITREORETINAL SURGERY

Objectives: Macular edema describes the slow and fluctuating accumulation of fluid in the central portion of the retina around the fovea. Intraocular surgery and other different eye conditions can trigger this process. Our study was aimed to determine the impact and persistence of macular edema after pars plana vitrectomy.

Materials and methods: A retrospective study was carried out on 91 eyes in 91 patients with past scheduled history of pars plana vitrectomy (PPV) and an age range of 31 to 85 (mean 68.5) years. Spectral domain optical coherence tomography (SD-OCT) imaging was performed to evaluate macular thickness, including measurements of central subfield thickness (CST), cube volume (CV), cube average thickness (CAT) and manual measurement of macular foveal thickness (MFT).

Results: There was significant difference of macular thickness in between preoperative OCT and postoperative OCT1 follow-ups in 40 included patients. Indeed, CST, CV, CAT and MFT were significantly decreased on postoperative OCT1 ($P=0.004$, $P=0.016$, $P=0.026$, $P=0.047$). Similarly, macular thickness was significantly decreased postoperatively (OCT1) in patients with existing macular edema prior to surgery ($n=34$), with OCT measurements (CST, CV, CAT and MFT) significantly decreased on OCT1 ($P=0.002$; $P=0.007$; $P=0.008$; $P=0.026$). Postoperative macular foveal thickness was significantly increased in between OCT1 and OCT2 ($n=35$) and in between OCT2 and OCT3 ($n=15$) follow-ups ($P=0.015$, $P=0.013$).

Conclusion: The macular thickness of non-existing macular edema prior to surgery has not be significantly increased after (PPV). However, macular thickness of existing macular edema prior to surgery was significantly decreased after PPV. Finally, macular edema after vitreoretinal surgery is still present after the third optical coherence tomography follow-up (approximately 3 months postoperatively).

9. CROATIAN SUMMARY

Naslov: RETROSPEKTIVNA STUDIJA PERZISTENTNOG MAKULARNOG EDEMA NAKON VITREORETINALNE KIRURGIJE

Ciljevi:

Makularni edem predstavlja sporo nastajuće i fluktuirajuće nakupljanje tekućine u centralnom dijelu mrežnice oko fovee. Intraokularna kirurgija i druge očne bolesti mogu pokrenuti ovaj proces. Naša studija je imala za cilj istražiti učestalost i klinički tijek makularnog edema uzrokovanog pars plana vitrekromijom

Materijali i metode:

Studija je provedena retrospektivno na 91 oku 91 pacijenta koji su bili podvrgnuti pars plana vitrektomiji (PPV). Uključeni bolesnici su bili u rasponu od 31 do 85 godina starosti (srednja vrijednost 68,5 godina). Optička koherentna tomografija spektralne domene (engl. Spectral Domain Optical Coherence Tomography – SD-OCT) je bila snimana kako bi se procijenila debljina makule, uključujući mjere kao što su CST (engl. Central subfield thickness), CV (engl. Cube volume), CAT (engl. Cube average thickness) te je bila manualno izmjerena debljina fovee (engl. Macular foveal thickness – MFT).

Rezultati:

U 40 praćenih bolesnika nađeno je značajno smanjenje debljine makule zabilježene prilikom preoperativnog OCTa i prvog postoperativnog OCTa. Naime, CST, CV, CAT i MFT su bili značajno smanjeni na prvom postoperativnom OCTu ($P=0,004$; $P=0,016$; $P=0,026$; $P=0,047$). Također, makularna debljina je bila značajno smanjena na prvom postoperativnom OCTu u bolesnika s prisutnim predoperativnim makularnim edemom ($n=34$). Kod tih bolesnika CST, CV, CAT i MFT su bili značajno niži ($P=0,002$; $P=0,007$; $P=0,008$; $P=0,026$). Makularna fovealna debljina postoperativno je bila značajno veća između OCT1 i OCT2 ($n=35$) i između OCT2 i OCT3 ($n=15$) ($P=0,015$; $P=0,013$).

Zaključak:

Debljina makule nije bila značajno povećana nakon PPVa u odnosu na preoperativne vrijednosti. Također smo zabilježili da se makularni edem, koji je bio prisutan prije operacije, značajno smanjio nakon PPVa. Na koncu je zabilježeno da se postoperativni makularni edem zadržava i nakon treće postoperativne kontrole (aproksimativno 3 mjeseca nakon operacije).

10. CURRICULUM VITAE

Personal Data:

Name and Surname: Pierre Sanchis

Date of birth 29th March 1991, Bordeaux, France

Citizenship: French

Address: Barakovićeva 14, Gripe, Split

Email: pierre.sanchis@gmail.com

Education

2012-2018	University Split School of Medicine, Split, Croatia
2010-2012	University Bordeaux School of Medicine, Bordeaux France
2010	High School Diploma (Scientific A-level), Lycée privé de la Sauque, La Brède, France

Internships

2018	Hepato-Gastro-Enterology and Oncology Department, University Hospital Bordeaux Haut-Lévêque, France
2016	Ambulatory Surgery Department, Facharztlinik Hamburg, Germany
2014	Assistant Nurse, Bagatelle Hospital, Bordeaux, France

University Involvement

2014-2017	Co-founder and former President of the International Student Association, University of Split School of Medicine (ISA USSM)
2014	Anatomy tutor, University of Split School of Medicine, Split, Croatia

Extracurricular

2016-2018	Lacrosse player in “Split Legion” team, Croatian Lacrosse League
2015	Volunteer in “Teddy's Hospital”, action for children, which allow them to discover the world of health in a fun and educational way

Languages: French (C2), English (C1), German (B1), Spanish (B1), Croatian (A2)