Full mouth rehabilitation in dental implantology

Haxhosaj, Argjend

Professional thesis / Završni specijalistički

2021

Degree Grantor / Ustanova koja je dodijelila akademski / stručni stupanj: **University of Zagreb, School of Dental Medicine / Sveučilište u Zagrebu, Stomatološki fakultet**

Permanent link / Trajna poveznica: https://urn.nsk.hr/urn:nbn:hr:127:814906

Rights / Prava: Attribution-NonCommercial 4.0 International/Imenovanje-Nekomercijalno 4.0 međunarodna

Download date / Datum preuzimanja: **2024-03-29**

Repository / Repozitorij:

University of Zagreb School of Dental Medicine Repository

Sveučilište u Zagrebu

Stomatološki fakultet

Argjend Haxhosaj

FULL MOUTH REHABILITATION IN DENTAL IMPLANTOLOGY

POSLIJEDIPLOMSKI SPECIJALISTIČKI RAD

Zagreb, 2021

Rad je ostvaren u Zavodu za fiksnu protetiku na Stomatološkom fakultetu u Zagrebu.

Naziv poslijediplomskog specijalističkog studija: Dentalna implantologija

Mentor rada: izv.prof.dr.sc. Marko Jakovac

Lektor hrvatskog jezika: Marina Smojver, prof. hrvatskog jezika i književnosti

Lektor engleskog jezika: Adnan Gjakova, prof. engleskog jezika

Sastav Povjerenstva za ocjenu poslijediplomskog specijalističkog rada:

1. Doc.dr.sc. Domagoj Vražić, predsjednik

2. Izv.prof.dr.sc. Marko Jakovac, član

3. Izv.prof.dr.sc. Davor Brajdić, član

Sastav Povjerenstva za obranu poslijediplomskog specijalističkog rada:

1. Doc.dr.sc. Domagoj Vražić, predsjednik

2. Izv.prof.dr.sc. Marko Jakovac, član

3. Izv.prof.dr.sc. Davor Brajdić, član

Datum obrane rada: 09.07.2021.

Rad sadrži: 52 stranice

1 tablica

8 slika

CD

Rad je vlastito autorsko djelo, koje je u potpunosti samostalno napisano uz naznaku izvora drugih autora i dokumenata korištenih u radu. Osim ako nije drukčije navedeno, sve ilustracije (tablice, slike i dr.) u radu su izvorni doprinos autora poslijediplomskog specijalističkog rada. Autor je odgovoran za pribavljanje dopuštenja za korištenje ilustracija koje nisu njegov izvorni doprinos, kao i za sve eventualne posljedice koje mogu nastati zbog nedopuštenog preuzimanja ilustracija odnosno propusta u navođenju njihovog podrijetla.

Zahvala

Zahvaljujem svom mentoru izv.prof.dr.sc. Marko Jakovac na nesebičnoj pomoći, brojnim savjetima i konstruktivnim kritikama.

Zahvaljujem se svojoj obitelji na bezuvjetnoj podršci tijekom studija, kako u moralnom tako i u financijskom smislu, posebna zahvala ide mojoj majci, te ocu Dr. Beqir Haxhosaj (specijalist protetike) koji me je cijelo vrijeme motivirao, te je moj glavni oslonac u karijeri.

Zahvaljujem se također, i svojoj ženi na bezuvjetnoj podršci tijekom studiranja i pisanju rada, te svom sinu koji me nadahnjuje u svemu.

Summary

FULL MOUTH REHABILITATION IN DENTAL IMPLANTOLOGY

Teeth are designed to endure a lifetime, but often patients lose teeth partially or completely because of causes such as dental caries, periodontal problems, accidental traumas, etc. Therefore, replacing missing teeth is important for the patient's general health as well as to the health of his/her other teeth. Not only does the patient lose chewing ability when a tooth is lost, but it can also cause other teeth to be lost, tiped or crowded and create subsequent problems if it is not replaced.

With the advancements in dental science and public awareness of better dental treatment options, a dental implant should always be considered as an option for replacing a failing or missing tooth. The replacement of lost teeth with dental implants has been in use for more than 50 years and is recognized as an effective treatment choice. Many studies and clinical trials worldwide have shown that the dental implant is considered more predictable than the conventional bridgework, resin-bonded bridges and endodontic therapy. Often, the patient is faced with a difficult decision in choosing whether to insert dental implants to replace one or more missing teeth. However, clinical studies have shown a very high success rate for dental implants of around 90-95% on an average. These figures do vary according to the part of the mouth that is being treated. Due to lower bone density and sinus pneumatization, the upper jaw has been and continues to be, more difficult to be treated than the lower jaw, which is reflected in the success rates of clinical studies.

Therefore, the aim of this paper is to present the process of dental reconstruction and rehabilitation, while satisfying all the related factors, including the health of the periodontium, vertical dimension, freeway space, balanced functional occlusion and the esthetic requirements.

Keywords: full mouth rehabilitation, implants, dental implantology, treatment, teeth

Sažetak

ORALNA REHABILITACIJA U DENTALNOJ IMPLANTOLOGIJI

Trajni zubi trebaju trajati cijeli život, ali često pacijenti gube zube djelomično ili u potpunosti zbog uzroka kao što su zubni karijes, parodontni problemi, traume i slično. Nadoknada zubi koji nedostaju je vrlo važna za opće zdravstveno stanje pacijenta, kao i za zdravlje ostalih zubi. Pacijent ne samo da gubi žvačnu funkciju kada izgubi zub, nego to može prouzročiti gubitak, naginjanje ili kompresiju ostalih zuba i stvoriti dodatne probleme.

Napredak u dentalnoj medicini i svijesti javnosti o boljim mogućnostima zbrinjavnaja zuba, omogućio je da se dentalni implantat može razmatrati kao mogućnost nadomještanja zuba. Zamjena izgubljenih zuba implantatima se koristi više od 50 godina i prepoznat je kao učinkoviti izbor terapije. Mnoga istraživanja i klinička ispitivanja širom svijeta su pokazala da se dentalni implantat smatra predvidljivijim od konvencionalnih mostova, adhezivnih mostova i endodontske terapije. Često se pacijent suočava s teškom odlukom pri odabiru terapije implantatima. Međutim, kliničke studije su pokazale vrlo visoku stopu uspješnosti zubnih implantata od oko 90-95% u prosjeku. Ove brojke se razlikuju ovisno o dijelu usne šupljine. Zbog razloga poput smanjene gustoće kostiju, i pneumatizacije sinusa, gornja čeljust je bila i ostaje teža za tretiranje nego donja čeljust, što se odražava na stopi uspjeha. Stoga je cilj i napor rekonstrukcija i rehabilitacija cjeline, zadovoljavajući sve povezane čimbenike, uključujući zdravlje parodonta, vertikalnu dimenziju i slobodni prostor, uravnoteženu funkcionalnu okluziju i estetske zahtjeve.

Ključne riječi: oralna rehabilitacija, implantati, dentalna implantologija, terapija, zubi.

CONTENTS

1. INTRODUCTION 1

2. THE FAIR PROTOCOL 3

2.1. Evolution of the FAIR protocol 4

2.2. Advantages and disadvantages 6

3. PLANNING IN DENTAL IMPLANTOLOGY 10

3.1. Principles 11

3.1.1. Osseointegration 11

3.1.2. Anatomical structures 14

3.1.3. Long term results 16

3.2. Preparatory steps in implant planning 17

3.2.1. Absolute contraindications 17

3.2.2. Relative contraindications 18

3.2.3. Risk for dental implant failure 18

3.3. Implant planning and fixture insertion 19

3.3.1. Preparation of the surgical stent 22

3.3.2. Timing of implant surgery 23

3.3.3. Factor influencing planning and surgical guidelines 25

4. DISCUSSION 32

5. CONCLUSION 34

6. LITERATURE 36

7. CV 51

Abbreviations

FAIR - Full – arch implant rehabilitation

BRONJ – Bisphosponate-related osteonoecrosis of jaw

AIDS/HIV – Acquired Immune Deficiency Syndrome/Human immunodeficiency virus

BIC – bone - implant contact

mm – Millimeter

CT – computer tomography

DICOM - Digital images and communications in medicine

GBR - Guided bone regeneration

FDBA - freeze dried bone allograft

DFDBA - decalcified and freeze dried bone alograft

rHBGF - Recombinant human bone growth factor

rHPDGF- recombinant human platelet-derived growth factor

BAM – resorbable membranes

NAM – non – resorbable membranes

FDP – fixed dental prothesis

Ncm – Normal cubic meter

PSI – pounds per square inch

1. INTRODUCTION

In order for the clinical application of dental endosseous implants to be effective in the long run, an appropriate type of biological bonding between the implant and the bone is required. This process was defined as an osseointegration by Brånemark et al. (1). Many researchers around the world have investigated this procedure and concluded that there is a functional stability of the endosseous between the implants and the bone (2).

In order to cure edentulous or partially edentulous patients with endosseous implants, treatment by several doctors or a team of doctors, including an implant surgeon, restorative dentist, and dental laboratory technicians required. The way in which patients experience aesthetic and functional results partially measures the success of the implant placement. When it comes to the treatment plan, the number, size and the position of the implants to be used in the treatment depend on the visual appearance of the prosthesis, regardless of whether it is a single implant-retained crown or a full-arch prosthesis. Therefore, a restorative phase of the treatment must be implemented prior to the surgical phase (3).

In North America, Brånemark and co-workers concluded a two-stage surgical agreement. Numerous scientific studies have successfully proved the effectiveness of titanium endosseous implants (4-9). In solving clinical problems associated with tooth deficiency, a large number of dentists emphasized osseointegration of dental implants meaningful, logical, and effective (10). Alzarea has concluded that patients can greatly assist dentists in providing satisfactory services with their expectations, and that prostheses implants greatly affect the quality of a patient's oral health (11).

The main purpose of this paper is to closely explain, describe, and portray the process of oral rehabilitation as a part of dental implantation. The aim of this expert thesis created by a dental practitioner, is rehabilitation from the planning phase all the way to the embedding phase in a simple and concise way and as a part of dental implantation.

2. THE FAIR PROTOCOL

2.1.Evolution of the FAIR protocol

The FAIR protocol is a full-arch implant rehabilitation protocol, which is a new scientific advancement in implant therapy for the treatment of a toothless or almost toothless patient. The individual implants are avoided for replacing the missing teeth, but four or five implants are distributed throughout the longitudinal arch after which a temporary fixed denture is placed immediately (12). Numerous scientific studies have shown that wearing classic removable dentures reduces patients' life quality. Such removable dentures can cause pain and discomfort, create chewing and speech difficulties, and reduce occlusive force (13-15).

For patients with a fully or partially edentulous arch, FAIR dental prosthesis provides many advanced features by being immediate, fixed, aesthetically pleasing, highly effective, inexpensive and cost-effective in the long run.

Since classical methods require extensive bone grafting, the FAIR dental systems are much better constructed or shaped, with the purpose of meeting the surgical and restorative needs of many patients with edentulous or partially edentulous arches. Some patients give up due to the invasiveness of the procedure, while some of them are simply not good candidates for bone grafting (16-20).

During the 1990s, the success rate of the number of immediately loaded implants improved greatly, both for the reconstruction of individual teeth and for the implantation of short-span fixed partial dentures (21, 22). In the 1990s, mandibular restoration protocols were developed. In addition, attempts to provide answers to the undertaking of anatomical implantation and redesign of the partial denture architecture in the dense bone of the mandible were also made (23, 24). To overcome this undertaking, the threading, size, and length of the implants were adapted to condense and thicken the bone when placed in the soft bone. Other processes, including the sinus elevation have also been adjusted (25-28).

When pink ceramics for gingiva were introduced into the aesthetics of fixed prosthetics in the 2000s, there was an immediate significant improvement (29-33). For example, when traditional implant surgery and bone grafting for sinus elevation and other procedures are contraindicated in the maxilla due to patient's age and other bone density or availability issues, nontraditional zygomatic implants can be placed near the dense and more cortical cheek bone in the posterior maxilla, and last longer (Figure 1).

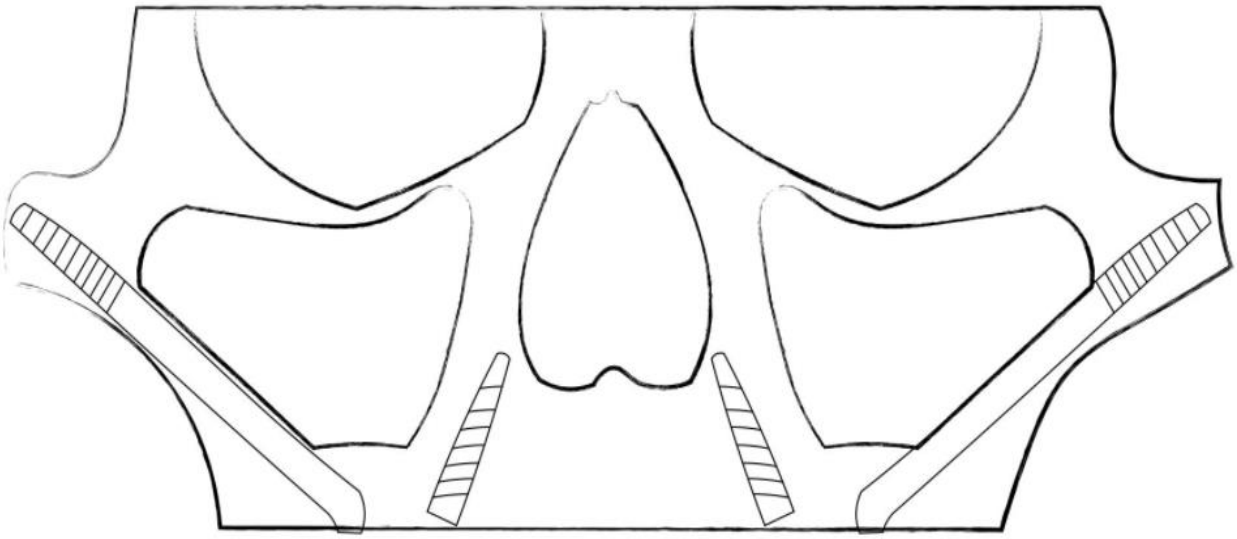

Figure 1. Placing zygomatic implants near the dense and more cortical cheekbone in the posterior maxilla is an example of an early evolution in the full-arch dental prostheses protocol.

Until 2010, a special shift in the implant design and procedures included methods for extra-maxillary anchorage, optimal implant angulation, optional use of cantilevers, and bone reduction if necessary (34-37).

The first step in the treatment of an edentulous patient, which is in line with the developed dental implant technology, is a removable denture with two or four implants (38-40). Unlike the conventional removable dentures, the fixed removable overdenture improves stability and function to approximately 60% that of natural teeth (Figure 2). In addition, it is still relatively inexpensive as a replacement for teeth and gingiva. Compared to classic removable dentures, fixed removable dentures significantly enhance durability and effectiveness at approximately 60% that of natural teeth and is certainly a fairly inexpensive replacement for teeth and gingiva. Besides the advantage of the lip support, the biggest advantage is considered to be the fact that it can be taken out of the mouth and cleaned. Disadvantages include painful spots on the gingiva, certain movements while the patient talks and chews, and also frequent removal for the comfort because of a continued bone resorption.

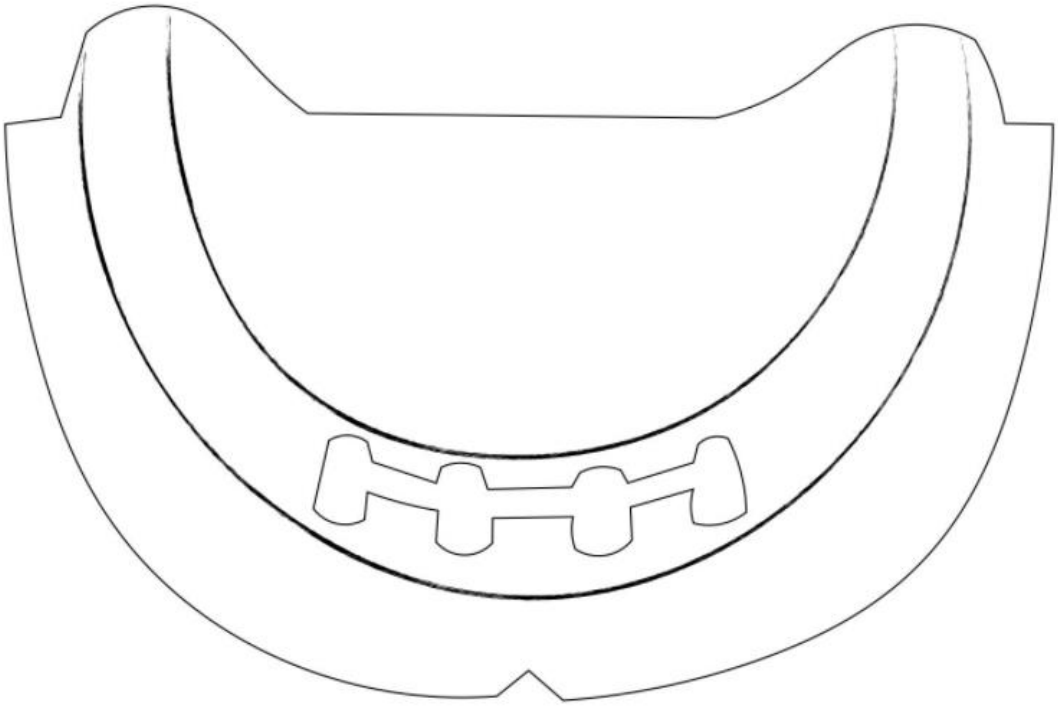

Figure 2. The fixed removable overdenture improves stability and function to approximately 60% that of natural teeth.

2.2. Advantages and disadvantages

In the FAIR prosthesis and other related protocols, surgical treatment and a little time for healing and restoration are considered deficient. The FAIR protocol (Figure 3) provides 70% of natural health functionality, requires very little or no grafting before the placement, and can also be used as a replacement for bones and teeth. Therefore, these shortcomings can be considered almost insignificant. A provisional prosthesis is given the same day the operation is performed, to allow soft food to be consumed until it heals. A permanent denture over 30 years with a fairly natural aesthetic and almost no food restrictions, has a 95% success rate.

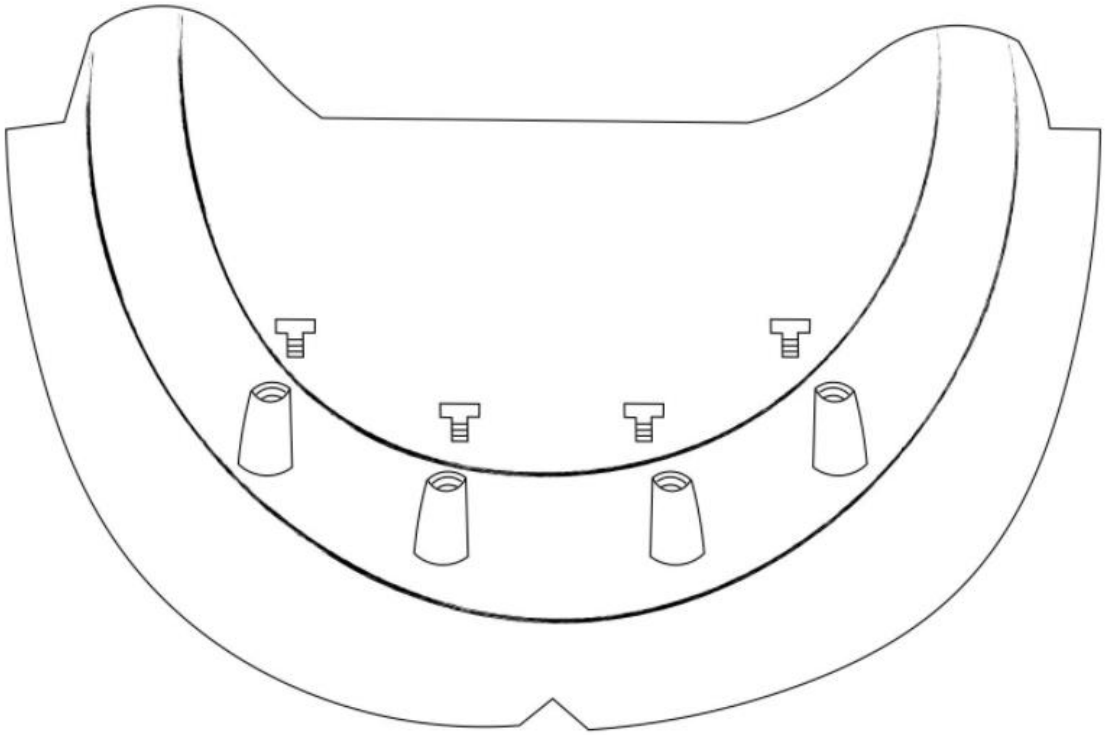

Figure 3. The FAIR protocol provides approximately 70% of natural dentition functionality

Scientific research has shown that edentulism has a long-term negative impact on a patient's overall oral health, so doing nothing in such cases is no longer an option (41,42). Unlike the traditional implants, which placed in the vertical position, like fence posts (Figure 4), the FAIR technique employs a distally tilted or angled implant similar to the angle of a beach umbrella positioned in the sand for greater stability.

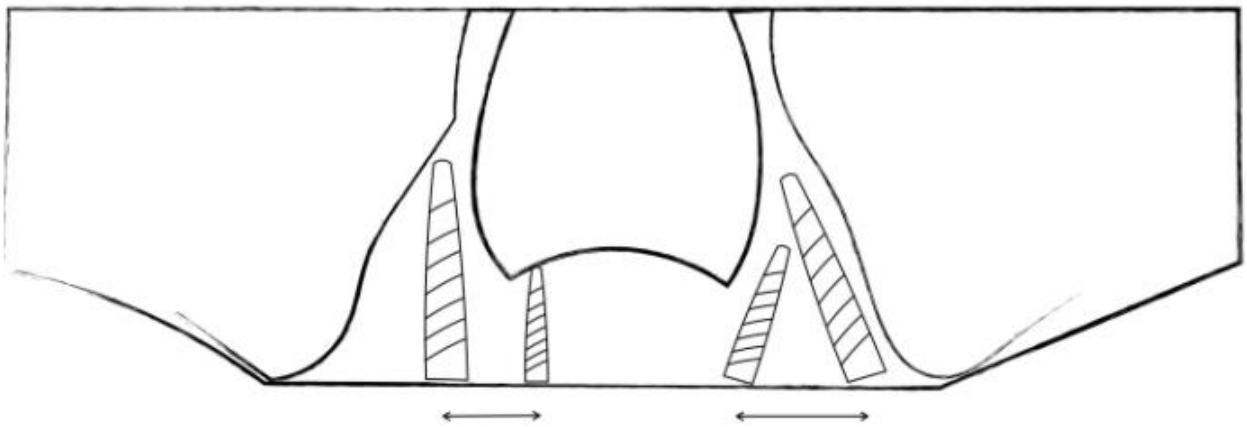

Figure 4. Implants are traditionally placed axially. When using the FAIR technique, the implants are tilted. Note that this also alows for more space in the arch between implants

Yet, in addition to classic dentures and overdentures, there are very simple solutions for edentulism nowadays, since the immediately loaded implant-supported full-arch prosthesis is almost analogous to natural health (43, 44). The FAIR dentures have almost the same occlusal force as the natural dentition, with 70% masticatory function and aesthetics, and are accompanied by a very low failure rate (45, 46). In order to obtain greater stability, the FAIR technique uses a distally tilted or angular implant for greater stability (like an umbrella tilted in the sand), while classical implants are embedded in a vertical position.

The advantage of tilted implants is that they protect important anatomical structures, thus extending the durability of implants and the cortical bone anchorage. Tilted implants preserve important anatomical structures, resulting in longer-lasting implants and good cortical bone anchorage (Figure 5). Also, with tilted implants, the spacing between implants is increased, while the cantilever length and the need for bone augmentation are reduced (28, 47-50). The FAIR surgical and temporary restoration techniques are performed in a single visit and most commonly use four or five implants: a pair of axial implants that are implanted anteriorly and two inclined implants placed posteriorly. To support temporary, fixed, and immediate loading of full-arch prosthesis with a survival rate of 92%-100%, the implants are restored with straight and angular multiunit abutments (51-56).

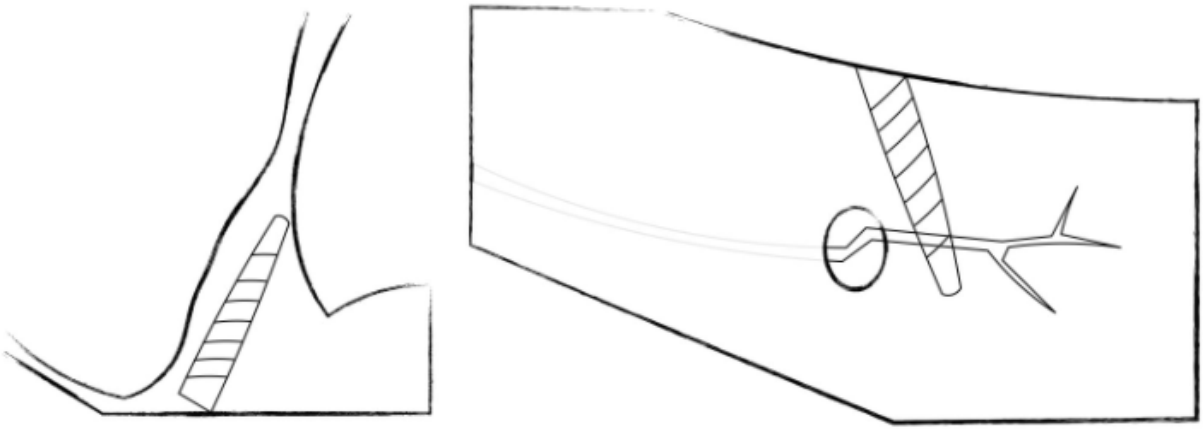

Figure 5. Tilting of implants allows the preservation of important anatomical structures: the maxillary sinus in the maxilla and the inferior alveolar nerve in the posterior mandible.

3. PLANNING IN DENTAL IMPLANTOLOGY

Endosseal implantology has established itself as an integral treatment modality within dentistry and thus considerably widened the spectrum of prosthodontic treatment option. In many clinical situations the patient's teeth can be restored with a fixed and supported implant, instead of a conventional removable prosthesis. Consequently, new dimensions with respect to the patient's desires for a normal function, comfort and aesthetics can be more readily addressed and fulfilled. In order to be able to satisfy patients' high expectations, it is necessary to introduce them to different treatment alternatives with their inherent advantages and disadvantages. In this manner it is possible to achieve the optimal individual prosthetic solution for each patient (57).

3.1.Principles

The dental practitioner dealing with implantology must be aware of the fundamental differences, principles, and conditions that apply to an osseointegrated implant compared to the natural dentition. In addition to surgical ability, the dentist must possess a thorough knowledge of biomechanics, periodontal and prosthodontic principles. Furthermore, the dental office has to institute and structure a strict recall regimen tailored to the individual needs of each and every patient. The cylindrical and screw-shaped fixtures, more commonly referred to as „root form implants" have become the state of the art in oral implantology. Bränemark System was originally concieved as a two-stage surgical procedure with a sub-mucosal healing phase where after which the site is again opened to enable a connection to the transmucosal abutment.

3.1.1. Osseointegration

Osseointegration (lat. Bone and integration) means "merging into one whole" in Latin. The definition of osseointegration is the direct fixation of bone to the body of the implant, and is considered to be the basis of support for a free-standing fixed prosthesis. It also has the property of transmitting occlusal forces directly to the bone (58-60). In order to achieve osseointegration, the surface of the implant should be made of an inert material with affinity to develop a direct contact with the bone tissue, without a soft tissue interface (61).

By the time osseointegration is established, the joint of the implant and the bone – the direct anchorage - is so strong that even a force of 100 kg could not separate or displace the implant, but the application of force would cause bone and implant fracture (61). As a result, a direct contact of the implant with the bone without a soft tissue interface is very important.

Scientists Linkow and Chercheve (62) and Wies (63) were convinced that the peri-implant membrane located between the implant and the bony osteotomy site functions as a periodontal membrane of teeth, thereby reducing the occlusal forces located on the denture, which transfer to the alveolar bone. During following research (64), the process of fibro-integration increased because it did not withstand the forces used under the functional load. It resulted in inflammatory reaction, gradual bone resorption, and loss of hardening. In his further research, Bränemark proved that the use of peri-implant membranes is directly related to the implant failure under the load. In his research, Bränemark also describes the biological and biomechanical differences between natural teeth, fibrointegrated implants, and osseointegrated implants (61). There are three models:

1. Teeth supported by periodontium
2. Implants anchored in non-mineralized connective tissue
3. Implants anchored by osseointegration

In order for the osseointegration to occur, the endostal threaded implant should serve to stabilize the fixation very soon after the preparation of the osteotomy and during the initial healing period. The dynamics of osseointegration and the relationship of endosteal implant with its surrounding alveolar bone can be distinguished over time as three distinct and partially overlapping intervals or periods: healing, remodeling, and dynamic equilibrium.

Primary and secondary healing lasts 18 months, in which the reconstruction phase begins at 3 months and coincides with the healing phase. In the dynamic equilibrium phase, a balance of forces is established to strengthen and reshape the anchor bones (65).

There are several main parameters that have an impact on the predictability of achieving proper osseointegration after the implant placement in a bone osteotomy:

1. The composition and characteristics of the material (commercially pure titanium) (66, 67)
2. A threaded fixture design, which allows for the implant to be placed in an osteotomy with primary stability and a larger surface area along the bony wall of the osteotomy site. This design results in proliferation instead of a direct bone fill and it represents the most precise placement of the endosteal implant in a vital bony osteotomy, all of which is inevitable for a successful procedure (68, 69).

3. Preventing excessive heat generation and the rise of temperatures above 39 °C, by maintaining a speed control of 2000 rpm during the osteotomy and 15 to 20 rpm during the implant placement (70-72).
4. Maintaining the osseointegration stress-free healing period: 6 months for the maxilla and 3 months for the mandible are considered as the standard for the osseointegration after the two-stage protocol (73).

The bones begin to heal as early as one week after the implant placement, and by the fourth week they are already at the peak of healing. The interface between the implant and the osteotomy takes about 8 weeks for it to mature and become bone tissue. After the prosthesis is inserted, the dynamic state of the bone continues. Once the final prosthesis is inserted, it takes about 18 months for the bones to reshape where the resultant woven bone matures into the denser laminar bone. Taking into account the occlusal forces that are created when a functional load is present, several parameters are developed to assess a continuous maintenance of the osseointegration over time. The occlusive forces generated by the dentate patient are approximately 100 psi, and the ones generated by the patients with a classic complete denture are between 15 to 20 psi (74-76). Dentate patients produce the same occlusal forces as patients with fully anchored bone prostheses (77). The standard for the clinical definition of the successfully placed osseointegration of implants was proposed by Albrektsson et al. 1986. Successful implants are defined by the following criteria (78):

- The individual implant remains clinically immobile
- Peri-implant radiolucency is not seen in the periapical radiographs
- One year after the implant placement, the vertical bone loss should not exceed 0.2 mm annually
- Individual implants should not cause pain, infection, neuropathies, or violation of the mandibular canal
- The success rate soon after the procedure is 85% and 80% after five or ten years

In order to determine the best possible assessment of the osseointegration, Bränemark and other scientists have been conducting clinical trials since 1965, based on which they recommend the following criteria (79,80):

- Controlled behavior of titanium in vitro

- A constant developmental technique is needed for a satisfactory healing process
- Implants and prostheses that can withstand continuous functional and parafunctional forces should be designed.

3.1.2. Anatomical structures

Surgical anatomy of the mandible

In order to perform an osteotomy, bone tissue needs to be accessed after the implants are placed. During the bone osteotomy and soft tissue handling, anatomical structures must be handled with care to avoid injuries, which can lead to damage difficult to repair, namely: reversible or irreversible nerve injuries, bleeding, and intrusion into unwanted anatomical areas (81).

Neurovascular structures:

- Osseous – inferior alveolar nerve, inferior alveolar artery
- Buccal – buccal nerve, facial artery branches, mental nerve
- Lingual – lingual nerve

Surgical anatomy of the maxilla

The anterior area

This area is located between the anterior walls and the maxillary sinus, and is generally of good quality. The nasal cavity apically limits this region that communicates with the maxillary sinus. Slight nasal floor penetration or perforation may be uneventful. The canine region is a strategic area due to mechanical stress dispersion. Between the two medial incisors, there is an incisional foramen, whose volume can prevent the implant placement (82).

Maxillary sinus and advanced surgeries

In this region, a sinus lifting procedure is indicated to increase bone volume. The operation procedure itself is usually complicated due to the barriers in the maxillary sinus. The septa are present in approximately 30% of the sinuses, out of which the most in the first or the second molar area. The permeability of the maxillary sinus must be checked before the surgery. In order to avoid the sinus region, the tuberosity one can be used for the implant placement (82). Tuberosity and pterygopalatine regions can be seen in Figure 6 and 7.

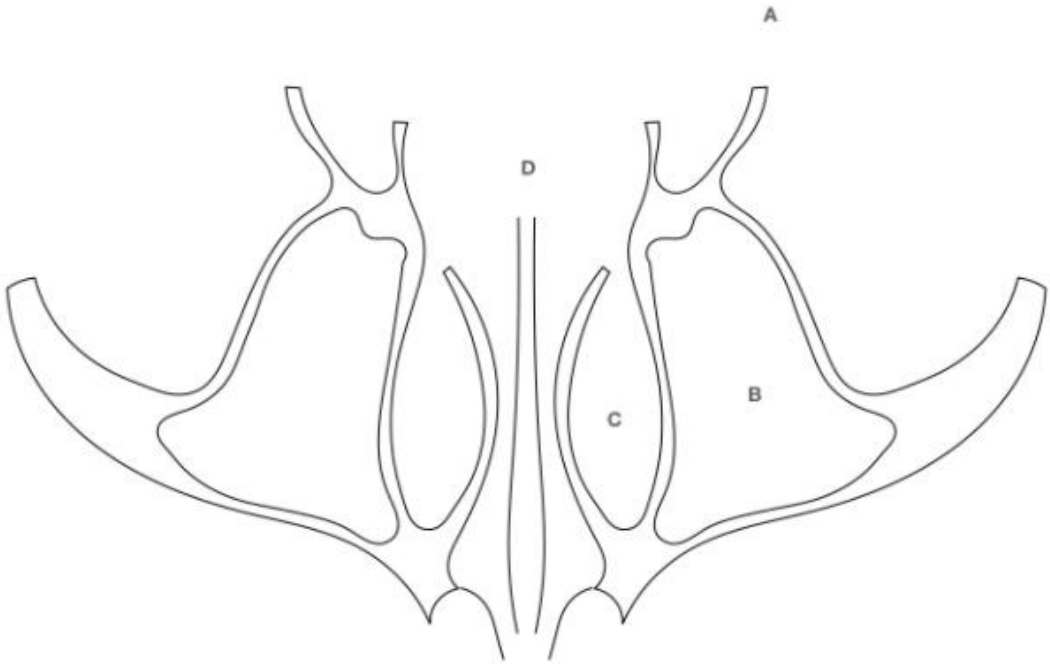

Figure 6. Maxilla: horizontal section. A. Lateral pterygoid plate; B. maxillary sinus; C. inferior nasal meatus; D. nasal septum

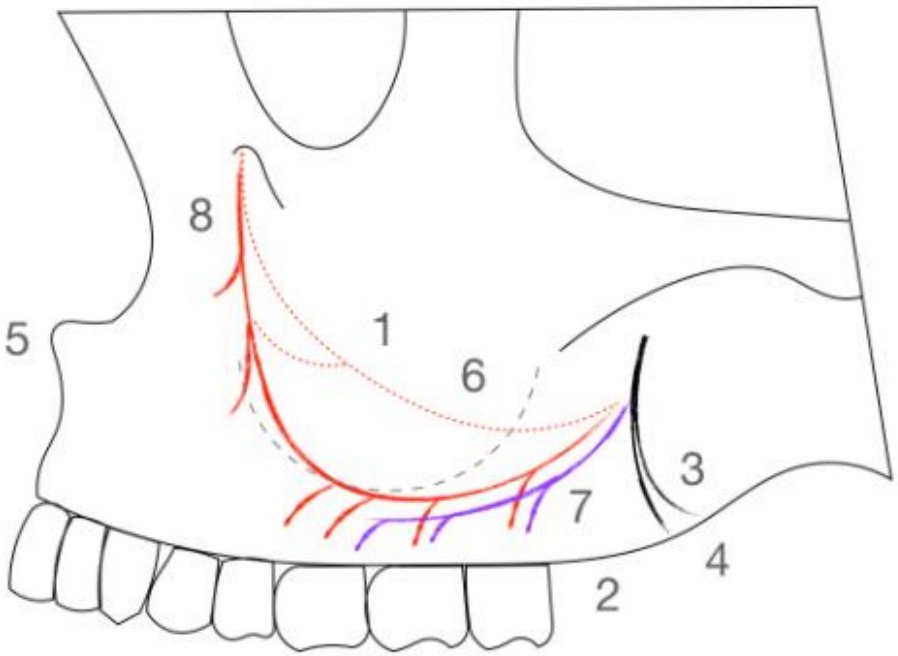

Figure 7. Maxilla: lateral view. 1. Maxillary sinus; 2. maxillary tuberosity; 3. lateral pterygoid plate; 4. palatine bone (pyramidal process); 5. anterior nasal spine; 6. alveolar antral artery; 7. posterior superior alveolar artery and nerve; 8. infraorbital artery branch

Bone classification schemes related to implant dentistry

An appreciation of bone density and its relation to oral implantology has existed for more than 25 years. In 1970, Linkow classified bone density into three categories (62).

Linkow stated that class III bone results in a loose fitting implant, while class II bone has a satisfactory base for implants and class I bone was the most ideal foundation for implant prostheses.

3.1.3. Long term results

The long-term clinical success of dental implants depends on the integration of the surface with hard and soft tissues, i.e. osseointegration, which will ensure implant stability and function (83, 84). Although most procedures have a good outcome, the number of complications and failed implants has increased in recent years (85, 86). These complications can generate pain, discomfort and lead to an eventual failure.

Factors such as surgical skills, patient health, implant design, osteotomy, and mechanical loading are mostly known to contribute to implant success or failure.

While following the process of implantation, the simultaneous interplay between mechanical and biological factors can dictate healing and integration. It is widely known that bacteria and host cells race for surface colonization. If an early biofilm is adhered to the implant surface together with a lower pH, a microenvironment of differential aeration is established between the biofilm and implant surface. This region of acidic pH (crevice) can lead to metallic corrosion and consequent metal ion generation, inducing an adverse immune response and chronic inflammation, which may ultimately trigger bone loss. Thus, an important factor to ensure healing is to first promote the conditions for the soft tissue closure (87).

3.2. Preparatory steps in implant planning

Dental implant therapy unites:

- Surgical treatment aiming to place the implant in the jaws
- Restorative treatment whose primary task is to replace teeth supported by implants. It is definitely necessary to do a radiographic examination before the treatment.

Throughout the history of implantology, the sophistication of surgical and prosthetic techniques has led to numerous options for placing dental implants in the oral cavity. As a result, even in cases where the supporting bone is missing, implants can be installed with certain medical contraindications. Patients are definitely looking for the best possible aesthetic result with as few complications as possible.

During the first consultation, contraindications should be ruled out during the course of the examination. A properly filled out medical questionnaire will greatly help in the initial interview and examination (88).

3.2.1. Absolute contraindications

- Chemoterapies in malignancies
- Radiotherapy
- Cardiac conditions
- Transplantation
- Dialysis catheters
- Intravenous bisphosphonates (BRONJ)

3.2.2. Relative contraindications

The indication for dental implant surgery must be discussed with the physician according to the complexity of the surgical treatment (number of dental implants, preimplant surgery) and the severity of the systemic disease.

Relative contraindications are (89):

- Cardiac conditions
- Oral bisphosphonates
- Diabetes
- Chronic kidney disease
- Acquired Immune Deficiency Syndrome/Human immunodeficiency virus -AIDS/HIV

3.2.3. Risk for dental implant failure

Most studies indicate that dental implants can be successfully placed and maintained while exhibiting a variety of systemic diseases and congenital defects.

The following list indicates potential risk factors that have been adequately documented, and the overall conclusions that can be drawn:

- Age (90)
- Smoking (90)
- History of treated periodontitis (91)
- Ectodermal dysplasia (92)
- AIDS/HIV (93)
- Diabetes (94)
- Bone diseases (95)
- Radiotherapy (95)
- Miscellaneous (95).

Local risk factors

Any situation that poses a risk to the productive osseointegration and restoration of the dental implant at the level of the implant site and surrounding teeth must be considered:

- Implant stability (96)
- Bone density (96)
- Interproximal space (96)
- Infected sites (96)
- Soft tissue thickness (97)
- Keratinized soft tissue (97)
- Surgical procedure (98)

Patient dental history

Not all patients are good candidates for dental implants, even if the clinical situation seems to be a good indicator. The evaluation of dental history allows the clinician to establish a comprehensive treatment plan and prevent the risk of failure or certain complications. Necessary information is provided by the patient during the initial interviews (99):

- Compliance (99)
- Oral hygiene (99)
- Bruxism (100)
- History of tooth loss (100)
- Dental inflammatory or infectious process (100)
- Periodontal history (90)

3.3. Implant planning and fixture insertion

After the plan for the prosthesis placement is finished, the next step is to select the implant so that the properties of the implant adapt to the requirements of the prosthesis: this is the concept of prosthetic-driven implant dentistry. Certain properties are of great importance during the selection of implants, including clinical and radiographic examination and finally surgical evaluation. Implant characteristics include the following: length, diameter, shape,

roughness, number, and position. In addition, aesthetics may affect the choice of implant. Ideally, the diameter of the implant platform should be identical to the cervical dimension of the replaced tooth (101).

For the restoration to be accomplished, most implant systems require a minimum vertical distance of 6 mm. In order to preserve the alveolar bone and allow a hygienic approach, the implant should be separated from the adjacent tooth by a minimum of 1.5 mm. The mesiodistal bone volume must be measured over the entire height of the implant site. Nevertheless, in cases of apical root convergence, a shorter implant or a conical implant avoids root interference (101).

In the posterior area, the implant position and implant axis are determined by the occlusal force distribution, although it is difficult to prove a correlation between the excessive occlusal forces and marginal bone loss or the implant failure. Thanks to that, the bone/implant interface is well adapted to axial compressive forces. Also, shear forces should be avoided. Consequently, for an optimal loading, the implant should be placed in the direction of the axial forces (Figure 8).

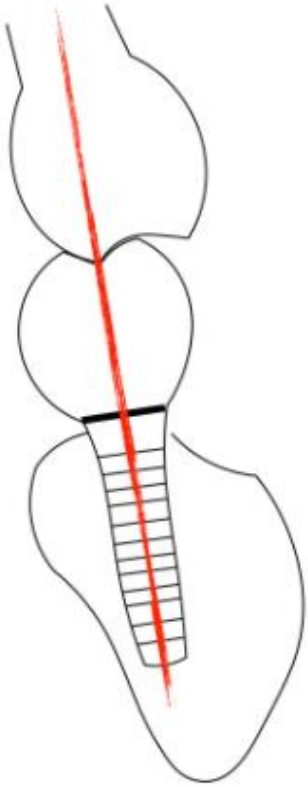

Figure 8. Optimal orientation of the implant: the implant axis should emerge in the central fossa and in the direction of the opposing supporting cusps.

The use of wide-diameter implants increases the bone – implant contact (BIC) and improves mechanical strength of the implant body in strong occlusal forces (102). On the contrary, small–diameter implants are contraindicated with high occlusal loading. For three or more splinted implants, it has been advocated that a tripod configuration improves force distribution.

Ideally, the implant should occupy the maximum bone volume and be surrounded by a sufficient bone thickness (1 mm, and 2 mm buccal in esthetic areas) (Table 1), while respecting the position (emergence point and axis) guided by the prosthesis (surgical template).

Long implant (>10 mm) may be indicated to achieve primary stability in the following situations: immediate implants, bone defect, tilted implants, and poor bone quality.

Table 1. Minimal buccollingual bone volume

Implant diameter	Non-esthetic areas	Esthetic areas
3 mm	5 mm	6 mm
4 mm	6 mm	7 mm
5 mm	7 mm	8 mm
6 mm	8 mm	-

A decision on whether to use a temporary replacement and what type of restoration is needed should be determined during the treatment planning. Reconstruction can be elaborated in different treatment steps: before the extraction and the implant placement and after the implantation, or sensory integration of the implant.

When the clinical situation requires a total lack of compression during the first weeks due to a bone graft or poor primary stability, or in the case of limited interocclusal space, a modified clear resin tray is used as an alternative to a temporary partial denture.

A resin-bonded cast metal bridge is a very reliable, comfortable, and stable solution. However, it may not be easy to remove and reline if necessary. During prosthetic steps, debonding and rebonding procedures can be time-consuming and degrade the bonding strength. In addition, it is more expensive. Those kinds of prosthesis are indicated for long-term temporary placement, particularly in young patients.

With the added advantage of allowing soft tissue maturation, it is a very comfortable and stable solution for the patient. However, indications are restricted to particular clinical conditions and include, among other parameters, sufficient primary stability of implants (103).

3.3.1. Preparation of the surgical stent

The growing interest in flapless surgery, along with the current burden on edentulous patients, has led to the development of software programs that help plan the treatment, make a surgical template, and manufacture a prosthesis that can be provided to the patient immediately after the implant placement. To avoid complications and minimize errors, team cooperation is of great importance. This allows timely correction of minor deviations during the treatment. Understanding each other's responsibilities leads to more predictable outcomes. This chapter

describes the various applications of computer-guided surgery software. To fully appreciate this concept, thorough understanding of scanning protocols is paramount.

In order to visualize the relationship of the patient's prosthesis to the edentulous ridge, the "two scans" technique is used (104). To initiate this protocol, which is easily recognized by a computer tomography (CT), impermeable markers are placed on the patient's denture. When the fit is correct, and precise vertical dimension of the occlusion and the correct position of the front and rear teeth are confirmed, the gutta-percha markers are added to the patient's dentures.

Initially, CT or CT scan with conical rays is performed on a patient while wearing a prosthesis and occluding into the bite registration material. Secondary, scanning refers exclusively to the prosthesis. Digital images and communications in medicine (DICOM) are projected on the appropriate disk and referred to as "patient DICOMs" and "denture DICOMs".

In order to be able to plan and analyze the treatment of the selected and guided surgery program, two-dimensional DICOM files are imported. The patient's DICOM file, i.e. the first scan, is introduced into the guided surgery software and converted into a three-dimensional display, while the DICOM prosthesis file, i.e. the second scan, is introduced and converted into a three-dimensional format. These two three-dimensional images are then merged by overlapping the gutta-percha points of the first image with the corresponding gutta-percha points in the second image. In this way, the patient’s toothless jaw is connected to the prosthesis, and can be visualized on the same screen.

The complete use of computer-controlled surgical software includes a preoperative production of prostheses with immediate loading. Once the surgical patterns are obtained, the prosthesis is made. After that, the following are sent to the laboratory: the surgical template, a stone model of the opposing arch, and a duplicate denture of the edentulous jaw planned for the implant placement.

3.3.2. Timing of implant surgery

In one stage surgery, an implant with an attached transmucosal healing abutment or an integral transmucosal collar or abutment, is placed but not covered with oral mucosa for healing. In two stage surgery, an implant is placed with its platform at the ridge crest level and left to heal for between 3 and 6 months submucosally without loading. The implant is then uncovered and a transmucosal abutment is placed. Esposito et al. have suggested that this

technique may be more appropriate for edentulous cases, due to the risk of inadvertent loading during the process of healing (104).

Implant placement variations include:

- Immediate placement into an extraction site (105)
- Early placement (or immediate-delayed) following soft tissue healing for 4-8 weeks after the extraction
- Delayed placement following bony socket healing for 3-6 months (106)
- Delayed placement after the socket augmentation with alloplastic graft materials left healing for 3-6 months (107)
- Delayed placement following healing for 6-9 months after ridge augmentation or ridge block grafting
- Implant placement in conjunction with the bone augmentation, grafting, and sinus lift (crestal access – indirect, or direct sinus lift) (108).

The possibility of immediate placement of implants following a traumatic extraction and socket curettage should be considered based on patients' individual needs. In their research, Chen et al., but also Lang et al. concluded that the survival rate and clinical outcome of immediate and delayed implants, in a short time, were similar to those of implants placed in healed alveolar ridges (105,107). Sanz et al. suggested that immediate placement of implants may preserve both soft tissue and bone, when compared with delayed protocols (108). By performing the immediate placemen, the final restoration will be improved (109). However, Esposito et al. concluded that there is insufficient evidence to establish the possible advantages or disadvantages of immediate, immediate-delayed (early), or delayed implant placement (104). Atieh et al. corroborated the higher risk of immediate placement versus the conventional surgical protocols (110). Hammerle et al. noted the risk of mucosal recession in aesthetic zones and suggested that the immediate placement procedure may be more appropriate for non-aesthetic areas (111).

Optimum aesthetics may be achievable when a healthy, but damaged tooth needs to be extracted. In this situation, an implant can be placed immediately and left to heal with a transmucosal abutment or provisional crown. Recently, a platform-switching has been promoted as a way of further optimization of the bone retention and soft-tissue aesthetics.

There is currently insufficient evidence available to validate the aesthetic benefit (112-114). These factors are considered important for aesthetic soft tissue management:

- Maintaining or creating an appropriately attached gingival girdle
- Maintenance of an interdental papillae when possible
- Tissue shaping to establish the optimal emergence profile of a crown and maintain soft tissue shape after restoration
- Platform-switching to retain bone and soft tissue.

Gingival grafting may be performed to recover soft tissue recession or to create an adequate band of attached gingiva.

Surgical protocols that use various grafting material and membranes have been used for alveolar preservation after the tooth extraction. Ten Heggeler et al. and Vignoletti et al. reviewed this subject and found that the adoption of such therapies demonstrated less vertical and horizontal contraction (bone loss) of the residual alveolar ridge (113-116).

These variations are complex and require greater experience in the area of the implant treatment group both surgically and restoratively. The implant placement can be combined with various augmentation and sinus elevation procedures.

3.3.3. Factor influencing planning and surgical guidelines

Significant bone deficiency may be congenital, or a result of a certain trauma, pathology, or long-term edentulism. For a very long time, autogenous bone grafts have been the standard for increasing the edentulous ridge bone volume. However, given the morbidity of harvesting the bone from remote sites, other less invasive bone augmentation techniques have become more popular for increasing the bone volume (117). The process of augmentation may be strategically important in certain scenarios to achieve the ideal aesthetic and biomechanical implant placement. In other cases, where implant length is an issue, shorter implants have been shown to provide a viable alternative to a vertical ridge augmentation (118, 119).

Inadequate solutions for the bone volume:

- Use short implants and/or more implants
- Use horizontal and/or vertical ridge augmentation

Types of ridge grafting/augmentation

- Horizontal and/or vertical ridge augmentation with block grafting and/or Guided bone regeneration (GBR) techniques. Block auto-grafts can be harvested from mandible, iliac crest or tibia,
- Indirect sinus lift/sinus augmentation using summers osteotome technique (120)
- Open sinus grafting or direct sinus lift (Caldwell-Luc procedure)
- Distraction osteogenesis
- Ridge splitting to expand the ridge width
- Repositioned mandibular nerve to allow for the implant placement

Types of graft materials and membranes:

- Autograft: block or particulate host bone
- Allograft: bone derived from another human, usually from a cadaver. It may be freeze dried bone allograft (FDBA) or decalcified and freeze dried bone alograft (DFDBA)
- Xenograft: nonhuman bone such as bovine or porcine
- Alloplast: synthetic graft materials based on hydroxyapatite or $CaSO_4$
- Recombinant human bone growth factor (rhBGF) or recombinant human platelet-derived growth factor (rhPDGF) along with a collagen or other support matrix
- Resorbable membranes (BAM)
- Non-resorbable membranes (NAM)

Implant selection is based on a comprehensive diagnosis and restorative preplanning along with a careful surgical site assessment during surgery. The implant systems present an array of diameters, lengths, shapes, and surface characteristics. The surgeon must balance all his knowledge and experience with the team recommendations and decide on the best solution for the clinical situation. Certain guidelines have been developed empirically over the past thirty years. While scientific rationale is limited, factors such as the size and number of the missing teeth, bone volume, and quality are important.

Implant platform, diameter

Clinicians developed a preference for particular implant designs for different clinical situations, such as parallel walled or tapered implants, or implants with machined, textured, or flared collars. An implant diameter should allow a satisfactory emergence profile of the final restoration. The required implant diameter can be loosely related to the cervical tooth diameter measurements. The following guidelines may be used (121):

- Narrow or small diameter (3.0-3.5 mm) for maxillary lateral and mandibular incisors
- Standard or regular diameter (4.0-4.5 mm) for maxillary central incisors, canines and premolars. This size is also ideal for over-dentures and hybrid dentures
- Wide diameter (>5.0 mm) for molars.
- Implant length

Clinicians are cognizant of tooth length and the concept of crown-to-root-ratio, and are comfortable duplicating these ratios with implants. Early Bränemark protocol expected an engagement of both cortical plates in the anterior mandible regardless of the implant length. As implant therapy was applied to other areas of the jaws, there was an uncertainty about the desired implant length due to variations in bone height and density in other areas of the jaws. In general, it is currently acceptable to have an approximate implant length in the region of 10-15.0 mm regardless of the implant shape or diameter. Short implants may be regarded as less than 10.0 mm long. With immediate placement, the implant must engage the bone in the apical portion of the socket or beyond, often making the implant longer than the tooth root it replaces. It has been suggested that placing shorter implants may be more desirable than the complex ridge augmentation procedures which enable the use of longer implants (122).

There are no clear guidelines for the use of short implants, and limited data on their endurance rates in different clinical scenarios is provided. Van Assche et al. demonstrated excellent short-term results for short implants with maxillary overdentures. Romeo et al. also found no significant differences in endurance rates for shorter and longer implants (121-124).

Implant number

When bone height dictates the use of short implants, the clinician should consider using additional implants (up to a maximum of one implant per premolar unit). Similarly, if small diameter implants must be used, the number of implants should be increased.

Implant configuration

Certain implant companies promote implant designs for areas with minimal height and soft bone quality (e.g., Bicon, Nobel Active®). Evidence currently suggests that machined surfaces are less desirable than textured surfaces, especially in the soft bone. Moreover, tapered screws achieve greater initial stability than cylindrical screws. Many press-fit implants have adopted threads to enhance the initial stability. Additionally, platform-switched designs, with a textured surface extended to the implant platform, may offer the best prognosis in areas of the soft bone and in aesthetic zones (125).

Provisional restorative options

Although temporary restoration and integration of implants are important for some patients, the ultimate success of implant restoration is of paramount importance both for the patience and clinicians. The implant integration must not be compromised by an inadvertent loading caused by a provisional restoration. It is important that the early stages of the osseointegration are not disturbed by any function. Provisional restorations may be inserted during or immediately after the surgery. Postsurgical soft tissue swelling and the pressure on healing tissue must be accounted for. Removable prosthesis must provide generous relief over the implant site. Options include:

- No provisional restoration
- An acrylic partial or complete denture fabricated in advance. It may be modified clinically with soft materials
- A resin retained FDP fabricated in advance
- A provisional FDP supported by the adjacent teeth
- An implant supported provisional restoration with no occlusal contact.

Immediate/early loading

Traditionally, implants are loaded after between 3 and 6 months of the bone healing. The restorative dentist and surgeon may cooperate to carry out an immediate loading with a provisional restoration, or place one at the second-stage surgery to shape the tissue for a better aesthetic result. The surgeon will have a view of when the implants should be loaded depending on the implant stability at the time of surgery.

In order to shorten the treatment time and enable the best possible temporary aesthetics and function, alternative loading protocols have been introduced (126, 127). At the time of implant placement, a temporary bracket is connected to the current load, and a temporary crown is placed. In this protocol, the implant must be stable at a torque force of >45 Ncm, which proves the existence of an outstanding bone quality (type I or type II). Besides, the provisional restoration is kept out of occlusion. Immediate loading may create an unnecessary risk to the process of osseointegration, and it is advisable to refer patients demanding such treatments to a specialist implant group.

With the advent of shorter osseointegration processes through the use of textured surfaces, it has become possible to functionally restore implants in as little as 6 weeks after the surgery. More long-term studies are needed to validate early loading protocols (128).

Postoperative management and surgical review

The surgeon prescribes antibiotics and pain medication as indicated by the particular case. Additionally, chlorhexidine or saline mouthwash may be prescribed. Certain minor problems may be anticipated depending on the case, such as minor bleeding, swelling and bruising, and transient paresthesia. The patient is given postoperative instructions for a minor oral surgery. Most problems that may arise, such as undesirable wound opening and infection, are still easily treated. Non-absorbable sutures are removed after 10-14 days, and provisional procedures are then finalized. If there is an ongoing infection, it may be necessary to remove a non-integrating or mobile implant (128).

After a healing period of 3-6 months, the second-stage surgery is performed to uncover the implant. The waiting period is based on the surgeon's knowledge of the surgical placement procedure nuances such as the bone density and initial stability at the time of placement. For that reason, this particular period is determined by the surgeon. The implant healing cap is located with a probe and either a flap is elevated, or a surgical punch is used to remove the overlying mucosa. The punch technique is not recommended when there is only a small band of attached mucosa. When feasible, the punch method is kinder to the patient as there is a minimal discomfort. Maintenance of an adequate labial band of attached gingiva is paramount for hygiene measures. Occasionally, an apically repositioned flap is indicated to recreate a band of attached gingiva. The labial soft tissue grafting may also be needed to fill out a bony depression depending on the circumstances. There are many surgical techniques for soft tissue

manipulation, for the purpose of improving the aesthetics. These are covered in textbooks on advanced implant topics (128).

Clinical indicators of the osseointegration:

- Absence of an infection and mobility
- Lack of crestal bone loss (on the radiograph)
- A radiograph that shows no radiolucency around the implant
- A ringing sound indicating ankylosis, which happens when tapping the implant with a metal instrument, for example, mirror handle.

After a transmucosal healing abutment is selected, it is finger tightened to between 10 and 15 Ncm, and checked with a radiograph. Alternatively, an expanded healing abutment or provisional crown may be placed in order to create an optimum soft tissue contour for the final restoration. The loss of integration may be suspected if an implant movement is detected, a significant discomfort occurs while removing the cover screw or abutment, or in the time of tightening the abutment (128).

Although no guidelines are currently available, it may be possible to leave the implant in place and monitor the situation for infection or reintegration if the movement is minimal and painful. Alternatively, the implant should be removed, the osteotomy site derided, in-filled with a particulate graft material, and allowed to heal for 6 months.

Implant stability testing

When an implant is placed, its stability is subjective and related to the type of bone, implant, and the technique of placing the implant. The insertion torque value gives a measure of the initial stability. Secondary implant stability is attributable to osseointegration and has been assessed by several methods. Impact testing and resonance frequency analysis are noninvasive stability testing devices that a promising future clinical use at least to some extent. Their clinical prognostic value has not been established up to this time (128).

Complications related to surgery and healing:

- Life – treating problems with anesthesia and surgery
- Hemorrhage, infection, pain, swelling, and ecchymoses
- Failure of the implant to osseointegrate

- Dehiscence and fenestration of the bone alveolar plates
- Damage to the vital anatomic structures necessitating an implant removal, for example, perforation of the mandibular nose or sinus canal floor
- Neurosensory problems – trauma of the mental nerve during the flap retraction, postoperative pressure on the nerve due to hematoma or edema, a direct injury to mandibular nerve during osteotomy: trauma, implant pressuring the nerve, transection of the minor or accessory nerves in the anterior mandible
- Wound dehiscence
- Poor position or an angulation of the implant

4. DISCUSSION

The practical paradigm, the shift of the time was to minimize treatment costs and patient morbidity, while at the same time, providing the most satisfactory patient-centered treatment outcome, all in line with recent experience in dental practice. With the all-on-four treatment concept, attempts have been made to achieve these goals, while providing relatively direct and predictable treatment options for the rehabilitation of edentulous patients with a high degree of life quality (129). The protocol for using 3.5 mm diameter Nobel Active implants with the all-on-4 concept was described by Babbush et al., who reported the results of 227 implants after 1 to 3 years of a follow-up.

The cumulative endurance rate was 98.7% at the end of 3 year period, with a 100% survival rate (130). Paul Malo conducted retrospective clinical studies on 245 patients who had completely edentulous mandibles. They were in the process of rehabilitation through the concept of all-on-four treatment and came to a conclusion of a cumulative implant survival rate of 93.8% and 94.8% (131).

To assess medium and long-term outcome of completely edentulous jaws rehabilitation results in the all-on-four immediate function while using a computer-assisted surgical protocol, Lopes et al. conducted a study and concluded that the overall cumulative survival rate was 96.6% after 5 years of a follow-up (132). Available research on the all-on-four concept shows that survival rates vary between 92.2% and 100% (133).

In the last ten years, the clinical trials have been conducted and resulted in more than four dental implants, which are generally unnecessary, supporting a full, fixed bridge. In addition, a placement of more than four implants is not a measure of greater success (134). Owing to the freedom of tilting, the implants can be anchored in dense bone structures (anterior bone with higher density) and well spread anteriorly-posteriorly, while giving an effective prosthetic base. When the number of implants is reduced to four, then each implant is placed without disturbing the adjacent implants. This treatment approach, when using an inclination and a smaller number of implants, instead of a large number that then create a "crowd", shows very good results.

5. CONCLUSION

Edentulism has been shown to negatively affect the psyche of individuals, and as a consequence it has a negative impact on the aesthetics of the face, oral cavity, chewing function and speech ability. As a consequence of the combination of the above factors, patient's life quality decreases. Although for now, the implant placement is a demanding surgical procedure and requires adequate planning for both the treatment and surgical techniques. There are several prosthetic options to rehabilitate severely atrophic maxillae and mandibles which have been developed as conventional complete dentures, implant supported removable, and implant supported fixed prosthesis. There is a possibility that in some cases, when the vital anatomical structures are empty and the quality and quantity of bones is poor, a prosthesis with an implant may not be feasible.

The all-on-four concept for total rehabilitation has proved to be clinically effective and have a high success rate. Also, the patient acceptance alongside the applicability have improved in many situations where more complicated procedures would have been indicated. It is a standardized treatment procedure that can be routinely applied to most patients in need of a complete rehabilitation. It is well adapted to further simplifications such as the flapless surgery based on computer planning and can be recommended as a method of choice for the rehabilitation of completely edentulous jaws.

6. LITERATURE

1. Brånemark PI, Hansson BO, Adell R, Breine U, Lindström J, Hallén O, Ohman A. Osseointegrated implants in the treatment of the edentulous jaw. Experience from a 10-year period. Scand J Plast Reconstr Surg Suppl. 1977;16:1-132.

2. Davies JE. Mechanisms of endosseous integration. Int J Prosthodont. 1998 Sep-Oct;11(5):391-401.

3. Zarb G. Proceedings of the Toronto conferences on osseointegration in clinical dentistry. The Journal of Prosthetic Dentistry. 1993;49:50–5.

4. Adell R, Lekholm U, Rockler B, Brånemark PI. A 15-year study of osseointegrated implants in the treatment of the edentulous jaw. Int J Oral Surg. 1981;10(6):387-416. doi: 10.1016/s0300-9785(81)80077-4.

5. Friberg B, Jemt T, Lekholm U. Early failures in 4,641 consecutively placed Brånemark dental implants: a study from stage 1 surgery to the connection of completed prostheses. Int J Oral Maxillofac Implants. 1991;6(2):142-6.

6. Sullivan DY, Sherwood RL, Porter SS. Long-term performance of Osseotite implants: a 6-year clinical follow-up. Compend Contin Educ Dent. 2001;22(4):326-8, 330, 332-4.

7. Testori T, Del Fabbro M, Feldman S, Vincenzi G, Sullivan D, Rossi R Jr, Anitua E, Bianchi F, Francetti L, Weinstein RL. A multicenter prospective evaluation of 2-months loaded Osseotite implants placed in the posterior jaws: 3-year follow-up results. Clin Oral Implants Res. 2002;13(2):154-61.

8. Östman PO, Hellman M, Sennerby L. Ten years later. Results from a prospective single-centre clinical study on 121 oxidized (TiUnite™) Brånemark implants in 46 patients. Clin Implant Dent Relat Res. 2012;14(6):852-60.

9. Nicoli LG, Oliveira GJPL, Lopes BMV, Marcantonio C, Zandim-Barcelos DL, Marcantonio E Jr. Survival/Success of Dental Implants with Acid-Etched Surfaces: A Retrospective Evaluation After 8 to 10 Years. Braz Dent J. 2017;28(3):330-336.

10. Davarpanah M, Martinez H, Etienne D, Zabalegui I, Mattout P, Chiche F, Michel JF. A prospective multicenter evaluation of 1,583 3i implants: 1- to 5-year data. Int J Oral Maxillofac Implants. 2002;17(6):820-8.

11. Alzarea BK. Assessment and Evaluation of Quality of Life (OHRQoL) of Patients with Dental Implants Using the Oral Health Impact Profile (OHIP-14) - A Clinical Study. J Clin Diagn Res. 2016;10(4):57-60.

12. Uhlendorf Y, Sartori IA, Melo AC, Uhlendorf J. Changes in Lip Profile of Edentulous Patients After Placement of Maxillary Implant-Supported Fixed Prosthesis: Is a Wax Try-in a Reliable Diagnostic Tool? Int J Oral Maxillofac Implants. 2017;32(3):593–597.

13. Barbosa GA, Bernardes SR, de França DG, das Neves FD, de Mattos Mda G, Ribeiro RF. Stress Over Implants of One-Piece Cast Frameworks Made With Different Materials. J Craniofac Surg. 2016;27(1):238-41.

14. Maló P, de Araújo Nobre M, Lopes A, Ferro A, Gravito I. All-on-4® Treatment Concept for the Rehabilitation of the Completely Edentulous Mandible: A 7-Year Clinical and 5-Year Radiographic Retrospective Case Series with Risk Assessment for Implant Failure and Marginal Bone Level. Clin Implant Dent Relat Res. 2015;17 Suppl 2:531-41.

15. Buser DA, Schroeder A, Sutter F, Lang NP. The new concept of ITI hollow-cylinder and hollow-screw implants: Part 2. Clinical aspects, indications, and early clinical results. Int J Oral Maxillofac Implants. 1988;3(3):173-81.

16. Piattelli A, Ruggeri A, Franchi M, Romasco N, Trisi P. An histologic and histomorphometric study of bone reactions to unloaded and loaded non-submerged single implants in monkeys: a pilot study. J Oral Implantol. 1993;19(4):314-20.

17. Henry P, Rosenberg I. Single-stage surgery for rehabilitation of the edentulous mandible: preliminary results. Pract Periodontics Aesthet Dent. 1994;6(9):15-22.

18. Spiekermann H, Jansen VK, Richter EJ. A 10-year follow-up study of IMZ and TPS implants in the edentulous mandible using bar-retained overdentures. Int J Oral Maxillofac Implants. 1995;10(2):231-43.

19. Salama H, Rose LF, Salama M, Betts NJ. Immediate loading of bilaterally splinted titanium root-form implants in fixed prosthodontics--a technique reexamined: two case reports. Int J Periodontics Restorative Dent. 1995;15(4):344-61.

20. Biglani M, Lozada JL. Immediately loaded dental implants—Influence of early functional contacts on implant stability, bone level integrity and soft tissue quality: A retrospective 3 and 6 year analysis. Int J Oral Maxillofac Implants 1996;11:126–27.

21. Balshi TJ, Wolfinger GJ. Immediate loading of Brånemark implants in edentulous mandibles: a preliminary report. Implant Dent. 1997;6(2):83-8.

22. Jemt T, Lekholm U. Implant treatment in edentulous maxillae: a 5-year follow-up report on patients with different degrees of jaw resorption. Int J Oral Maxillofac Implants. 1995;10(3):303-11.

23. Cannizzaro G, Felice P, Leone M, Viola P, Esposito M. Early loading of implants in the atrophic posterior maxilla: lateral sinus lift with autogenous bone and Bio-Oss versus crestal mini sinus lift and 8-mm hydroxyapatite-coated implants. A randomised controlled clinical trial. Eur J Oral Implantol. 2009;2(1):25-38.

24. Balevi B. Implant-supported cantilevered fixed partial dentures. Evid Based Dent. 2010;11(2):48-9.

25. Maló P, Nobre Md, Lopes A. Immediate loading of 'All-on-4' maxillary prostheses using trans-sinus tilted implants without sinus bone grafting: a retrospective study reporting the 3-year outcome. Eur J Oral Implantol. 2013;6(3):273-83.

26. Rocci A, Martignoni M, Gottlow J. Immediate loading in the maxilla using flapless surgery, implants placed in predetermined positions, and prefabricated provisional restorations: a retrospective 3-year clinical study. Clin Implant Dent Relat Res. 2003;5 Suppl 1:29-36.

27. Kinsel RP, Liss M. Retrospective analysis of 56 edentulous dental arches restored with 344 single-stage implants using an immediate loading fixed provisional protocol: statistical predictors of implant failure. Int J Oral Maxillofac Implants. 2007;22(5):823-30.

28. Eliasson A, Blomqvist F, Wennerberg A, Johansson A. A retrospective analysis of early and delayed loading of full-arch mandibular prostheses using three different implant systems: clinical results with up to 5 years of loading. Clin Implant Dent Relat Res. 2009;11(2):134-48.

29. Fortin Y. Placement of Zygomatic Implants into the Malar Prominence of the Maxillary Bone for Apical Fixation: A Clinical Report of 5 to 13 Years. Int J Oral Maxillofac Implants. 2017;32(3):633-641.

30. Fortin Y, Sullivan RM. Terminal posterior tilted implants planned as a sinus graft alternative for fixed full-arch implant-supported maxillary restoration: A case series with 10- to 19-year results on 44 consecutive patients presenting for routine maintenance. Clin Implant Dent Relat Res 2017;19:56–68.

31. Pi Urgell J, Revilla Gutiérrez V, Gay Escoda CG. Rehabilitation of atrophic maxilla: a review of 101 zygomatic implants. Med Oral Patol Oral Cir Bucal. 2008;13(6):363-70.

32. Lifshitz AB, Muñoz M. Evaluation of the stability of self-drilling mini-implants for maxillary anchorage under immediate loading. World J Orthod. 2010;11(4):352-6.

33. Harirforoush R, Arzanpour S, Chehroudi B. The effects of implant angulation on the resonance frequency of a dental implant. Med Eng Phys. 2014;36(8):1024-32.

34. Alencar SM, Nogueira LB, Leal de Moura W, Rubo JH, Saymo de Oliveira Silva T, Martins GA, Moura CD. FEA of Peri-Implant Stresses in Fixed Partial Denture Prostheses with Cantilevers. J Prosthodont. 2017;26(2):150-155.

35. Sheridan RA, Decker AM, Plonka AB, Wang HL. The Role of Occlusion in Implant Therapy: A Comprehensive Updated Review. Implant Dent. 2016;25(6):829-838.

36. Galindo DF. The implant-supported milled-bar mandibular overdenture. J Prosthodont. 2001;10(1):46-51.

37. Chee WW. Treatment planning: implant-supported partial overdentures. J Calif Dent Assoc. 2005;33(4):313-6.

38. Shetty PP, Gangaiah M, Chowdhary R. Hidden Overdenture Bar in Fixed Implant-retained Hybrid Prosthesis: Report of a Novel Technique. J Contemp Dent Pract. 2016;17(9):780-782.

39. Emami E, de Souza RF, Kabawat M, Feine JS. The impact of edentulism on oral and general health. Int J Dent. 2013;2013:498305.

40. Gil-Montoya JA, de Mello AL, Barrios R, Gonzalez-Moles MA, Bravo M. Oral health in the elderly patient and its impact on general well-being: a nonsystematic review. Clin Interv Aging. 2015;10:461-7.

41. Dellavia C, Rosati R, Del Fabbro M, Pellegrini G. Functional jaw muscle assessment in patients with a full fixed prosthesis on a limited number of implants: a review of the literature. Eur J Oral Implantol. 2014;7 Suppl 2:155-69.

42. Rosenbaum N. Full-arch implant-retained prosthetics in general dental practice. Dent Update. 2012;39(2):108-10, 112, 114-6.

43. Papaspyridakos P, Chen CJ, Chuang SK, Weber HP. Implant loading protocols for edentulous patients with fixed prostheses: a systematic review and meta-analysis. Int J Oral Maxillofac Implants. 2014;29 Suppl:256-70.

44. Balshi TJ, Wolfinger GJ, Slauch RW, Balshi SF. A retrospective analysis of 800 Brånemark System implants following the All-on-Four™ protocol. J Prosthodont. 2014;23(2):83-8.

45. Malhotra AO, Padmanabhan TV, Mohamed K, Natarajan S, Elavia U. Load transfer in tilted implants with varying cantilever lengths in an all-on-four situation. Aust Dent J. 2012;57(4):440-5.

46. Krennmair S, Piehslinger E. Clinical outcome and peri-implant findings of four-implant-supported distal cantilevered fixed mandibular prostheses: five-year results. Int J Oral Maxillofac Implants. 2013;28(3):831-40.

47. Drago C. Frequency and Type of Prosthetic Complications Associated with Interim, Immediately Loaded Full-Arch Prostheses: A 2-Year Retrospective Chart Review. J Prosthodont. 2016;25(6):433-9.

48. Spinelli D, Ottria L, DE Vico G, Bollero R, Barlattani A, Bollero P. Full rehabilitation with nobel clinician(®) and procera implant bridge(®): case report. Oral Implantol (Rome). 2013;6(2):25-36.

49. Kwon T, Bain PA, Levin L. Systematic review of short- (5-10 years) and long-term (10 years or more) survival and success of full-arch fixed dental hybrid prostheses and supporting implants. J Dent. 2014;42:1228–41.

50. Francetti L, Rodolfi A, Barbaro B, Taschieri S, Cavalli N, Corbella S. Implant success rates in full-arch rehabilitations supported by upright and tilted implants: a retrospective investigation with up to five years of follow-up. J Periodontal Implant Sci. 2015;45(6):210-5.

51. Krennmair S, Weinländer M, Malek M, Forstner T, Krennmair G, Stimmelmayr M. Mandibular Full-Arch Fixed Prostheses Supported on 4 Implants with Either Axial Or Tilted Distal Implants: A 3-Year Prospective Study. Clin Implant Dent Relat Res. 2016;18(6):1119-1133.

52. Ayub KV, Ayub EA, Lins do Valle A, Bonfante G, Pegoraro T, Fernando L. Seven-Year Follow-up of Full-Arch Prostheses Supported by Four Implants: A Prospective Study. Int J Oral Maxillofac Implants. 2017;32(6):1351-1358.

53. Testori T, Galli F, Fumagalli L, Capelli M, Zuffetti F, Deflorian M, Parenti A, Del Fabbro M. Assessment of Long-Term Survival of Immediately Loaded Tilted Implants Supporting a Maxillary Full-Arch Fixed Prosthesis. Int J Oral Maxillofac Implants. 2017;32(4):904-911.

54. Lopes A, Maló P, de Araújo Nobre M, Sánchez-Fernández E, Gravito I. The NobelGuide® All-on-4® Treatment Concept for Rehabilitation of Edentulous Jaws: A Retrospective Report on the 7-Years Clinical and 5-Years Radiographic Outcomes. Clin Implant Dent Relat Res. 2017;19(2):233-244.

55. Natali Arturo N, editor. Dental biomechanics. London/New York: Taylor & Francis; 2003, ISBN 9-780-415-30666-9, p. 69–87.

56. Gerds TA, Vogeler M. Endpoints and survival analysis for successful osseointegration of dental implants. Stat Methods Med Res. 2005 Dec;14(6):579-90.

57. Brånemark PI. Osseointegration and its experimental background. J Prosthet Dent. 1983 Sep;50(3):399-410.

58. Carlsson L, Röstlund T, Albrektsson B, Albrektsson T, Brånemark PI. Osseointegration of titanium implants. Acta Orthop Scand. 1986 Aug;57(4):285-9.

59. Brånemark PI. The osseointegration book: From calvarium tobcalcaneus. Chicago: Quintessence; 2005. p. 22-25.

60. Linkow LI, Chercheve R. Theories and techniques of oral implantology. St. Louis: Mosby; 1970. p. 698

61. Weiss CM. Tissue integration of dental endosseous implants: description and comparative analysis of the fibro-osseous integration and osseous integration systems. J Oral Implantol. 1986;12(2):169-214.

62. Brunski JB, Moccia AF Jr, Pollack SR, Korostoff E, Trachtenberg DI. The influence of functional use of endosseous dental implants on the tissue-implant interface. II. Clinical aspects. J Dent Res. 1979;58(10):1970-80.

63. Brånemark PI. Introduction to osseointegration. In: Brånemark PI, Zarb G, Albrektsson T, editors. Tissueintegrated prosthesis-osseointegration in clinical dentistry. Chicago: Quintessence; 1985. p. 352

64. Albrektsson T. Direct bone anchorage of dental implants. J Prosthet Dent. 1983;50(2):255-61.

65. Kasemo B. Biocompatibility of titanium implants: surface science aspects. J Prosthet Dent. 1983;49(6):832-7.

66. Carlsson L, Röstlund T, Albrektsson B, Albrektsson T, Brånemark PI. Osseointegration of titanium implants. Acta Orthop Scand. 1986;57(4):285-9.

67. Haraldson T. A photoelastic study of some biomechanical factors affecting the anchorage of osseointegrated implants in the jaw. Scand J Plast Reconstr Surg. 1980;14(3):209-14.

68. Lavelle CL, Wedgwood D, Love WB. Some advances in endosseous implants. J Oral Rehabil. 1981;8(4):319-31.

69. Eriksson RA: Heat-induced bone tissue injury. An in vivo investigation of heat tolerance of bone tissue and temperature rise in the drilling of cortical bone. Unpublished thesis. Sweden: University of Gothenburg; 1984, p. 705-711

70. Eriksson RA, Albrektsson T. The effect of heat on bone regeneration: an experimental study in the rabbit using the bone growth chamber. J Oral Maxillofac Surg. 1984;42(11):705-11.

71. Lekholm U. Clinical procedures for treatment with osseointegrated dental implants. J Prosthet Dent. 1983;50(1):116-20.

72. Carr AB, Laney WR. Maximum occlusal force levels in patients with osseointegrated oral implant prostheses and patients with complete dentures. Int J Oral Maxillofac Implants. 1987 Spring;2(2):101-8.

73. Laney WR, Tolman DE, Keller EE, Desjardins RP, Van Roekel NB, Brånemark PI. Dental implants: tissue-integrated prosthesis utilizing the osseointegration concept. Mayo Clin Proc. 1986;61(2):91-7.

74. Haraldson T, Karlsson U, Carlsson GE. Bite force and oral function in complete denture wearers. J Oral Rehabil. 1979;6(1):41-8.

75. Haraldson T. Masticatory muscle function in patients rehabilitated with OIB. Swed Dent J Suppl. 1985;28:137-42.

76. Albrektsson T, Zarb G, Worthington P, Eriksson AR. The long-term efficacy of currently used dental implants: a review and proposed criteria of success. Int J Oral Maxillofac Implants. 1986 Summer;1(1):11-25.

77. Brånemark PI, Hansson BO, Adell R, Breine U, Lindström J, Hallén O, Ohman A. Osseointegrated implants in the treatment of the edentulous jaw. Experience from a 10-year period. Scand J Plast Reconstr Surg Suppl. 1977;16:1-132.

78. Zarb GA, Schmitt A, Baker G. Tissue-integrated prostheses: osseointegration research in Toronto. Int J Periodontics Restorative Dent. 1987;7(1):8-35.

79. Greenstein G, Tarnow D. The mental foramen and nerve: clinical and anatomical factors related to dental implant placement: a literature review. J Periodontol. 2006;77(12):1933-43.

80. Greenstein G, Cavallaro J, Romanos G, Tarnow D. Clinical recommendations for avoiding and managing surgical complications associated with implant dentistry: a review. J Periodontol. 2008;79(8):1317-29.

81. Lekholm U, Zarb GA: Patient selection and preparation. In Brånemark P-I, Zarb GA, Albrektsson T, editors: Tissue-integrated prostheses. Osseointegration in clinical dentistry. Chicago: Quintessence; 1985. p. 199-209

82. Frost HM: Mechanical adaptation. Frost's mechanostat theory. In Martin RB, Burr DB, editors. Structure, function, and adaptation of compact bone. New York: Raven Press; 1989. p. 154-178

83. Manor Y, Oubaid S, Mardinger O, Chaushu G, Nissan J. Characteristics of early versus late implant failure: a retrospective study. J Oral Maxillofac Surg. 2009;67(12):2649-52.

84. Snauwaert K, Duyck J, van Steenberghe D, Quirynen M, Naert I. Time dependent failure rate and marginal bone loss of implant supported prostheses: a 15-year follow-up study. Clin Oral Investig. 2000;4(1):13-20.

85. Sánchez MC, Llama-Palacios A, Fernández E, Figuero E, Marín MJ, León R, Blanc V, Herrera D, Sanz M. An in vitro biofilm model associated to dental implants: structural and quantitative analysis of in vitro biofilm formation on different dental implant surfaces. Dent Mater. 2014;30(10):1161-71.

86. Scharer P, Rinn LA, Kopp FR. Asthetische Richtlinien fur die rekonstruktive Zahnkeilkunde. Berlin: Quintessenz; 1985. p. 241

87. Sanz M, Naert I; Working Group 2. Biomechanics/risk management (Working Group 2). Clin Oral Implants Res. 2009;20 Suppl 4:107-11.

88. Heitz-Mayfield LJ, Huynh-Ba G. History of treated periodontitis and smoking as risks for implant therapy. Int J Oral Maxillofac Implants 2009;24 Suppl:39-68.

89. Cochran DL, Schou S, Heitz-Mayfield LJ, Bornstein MM, Salvi GE, Martin WC. Consensus statements and recommended clinical procedures regarding risk factors in implant therapy. Int J Oral Maxillofac Implants. 2009;24 Suppl:86-9.

90. Bornstein MM, Cionca N, Mombelli A. Systemic conditions and treatments as risks for implant therapy. Int J Oral Maxillofac Implants. 2009;24 Suppl:12-27.

91. Yap AK, Klineberg I. Dental implants in patients with ectodermal dysplasia and tooth agenesis: a critical review of the literature. Int J Prosthodont. 2009;22(3):268-76.

92. Ferreira SD, Silva GL, Cortelli JR, Costa JE, Costa FO. Prevalence and risk variables for peri-implant disease in Brazilian subjects. J Clin Periodontol. 2006;33(12):929-35.

93. Madrid C, Sanz M. What impact do systemically administrated bisphosphonates have on oral implant therapy? A systematic review. Clin Oral Implants Res. 2009;20 Suppl 4:87-95.

94. Molly L. Bone density and primary stability in implant therapy. Clin Oral Implants Res. 2006;17 Suppl 2:124-35.

95. Bengazi F, Wennström JL, Lekholm U. Recession of the soft tissue margin at oral implants. A 2-year longitudinal prospective study. Clin Oral Implants Res. 1996;7(4):303-10.

96. Hämmerle CH, Chen ST, Wilson TG Jr. Consensus statements and recommended clinical procedures regarding the placement of implants in extraction sockets. Int J Oral Maxillofac Implants. 2004;19 Suppl:26-8.

97. Van Steenberghe D, Lekholm U, Bolender C, Folmer T, Henry P, Herrmann I, Higuchi K, Laney W, Linden U, Astrand P. Applicability of osseointegrated oral implants in the rehabilitation of partial edentulism: a prospective multicenter study on 558 fixtures. Int J Oral Maxillofac Implants. 1990;5(3):272-81.

98. Salvi GE, Brägger U. Mechanical and technical risks in implant therapy. Int J Oral Maxillofac Implants. 2009;24 Suppl:69-85.

99. Frederiksen NL. Diagnostic imaging in dental implantology. Oral Surg Oral Med Oral Pathol Oral Radiol Endod. 1995;80(5):540-54.

100. Friedland B. Risk-benefit analysis of the radiographic standards of care. Int J Periodontics Restorative Dent. 2005;25(1):6-7.

101. Kassebaum DK, Nummikoski PV, Triplett RG, Langlais RP. Cross-sectional radiography for implant site assessment. Oral Surg Oral Med Oral Pathol. 1990;70(5):674-8.

102. Van Steenberghe D, Naert I, Andersson M, Brajnovic I, Van Cleynenbreugel J, Suetens P. A custom template and definitive prosthesis allowing immediate implant loading in the maxilla: a clinical report. Int J Oral Maxillofac Implants. 2002;17(5):663-70.

103. Chiu WK, Luk WK, Cheung LK. Three-dimensional accuracy of implant placement in a computer-assisted navigation system. Int J Oral Maxillofac Implants. 2006;21(3):465-70.

104. Esposito M, Grusovin MG, Chew YS, Coulthard P, Worthington HV. One-stage versus two-stage implant placement. A Cochrane systematic review of randomised controlled clinical trials. Eur J Oral Implantol. 2009 Summer;2(2):91-9.

105. Chen S, Buser D. ITI treatment guide, volume 1: Implant placement in post-extraction sites-treatment options. In Buser D, Wismeijer D, Belser D, editorrs. Berlin: Quintessence; 2008. p. 195.

106. Jensen S, Katsuyama H. ITI treatment guide, volume 5: Sinus floor elevation procedures. In: Chen S, Buser D, Wismeijer D, editors. Berlin: Quintessence; 2011. p. 25

107. Lang NP, Pun L, Lau KY, Li KY, Wong MC. A systematic review on survival and success rates of implants placed immediately into fresh extraction sockets after at least 1 year. Clin Oral Implants Res. 2012;23 Suppl 5:39-66.

108. Sanz I, Garcia-Gargallo M, Herrera D, Martin C, Figuero E, Sanz M. Surgical protocols for early implant placement in post-extraction sockets: a systematic review. Clin Oral Implants Res. 2012;23 Suppl 5:67-79.

109. Esposito M, Grusovin MG, Polyzos IP, Felice P, Worthington HV. Timing of implant placement after tooth extraction: immediate, immediate-delayed or delayed implants? A Cochrane systematic review. Eur J Oral Implantol. 2010;3(3):189-205.

110. Atieh MA, Payne AG, Duncan WJ, Cullinan MP. Immediate restoration/loading of immediately placed single implants: is it an effective bimodal approach? Clin Oral Implants Res. 2009 Jul;20(7):645-59.

111. Hämmerle CH, Araújo MG, Simion M; Osteology Consensus Group 2011. Evidence-based knowledge on the biology and treatment of extraction sockets. Clin Oral Implants Res. 2012;23 Suppl 5:80-2.

112. Esposito M, Maghaireh H, Grusovin MG, Ziounas I, Worthington HV. Soft tissue management for dental implants: what are the most effective techniques? A Cochrane systematic review. Eur J Oral Implantol. 2012;5(3):221-38.

113. Ten Heggeler JM, Slot DE, Van der Weijden GA. Effect of socket preservation therapies following tooth extraction in non-molar regions in humans: a systematic review. Clin Oral Implants Res. 2011;22(8):779-88.

114. Vignoletti F, Matesanz P, Rodrigo D, Figuero E, Martin C, Sanz M. Surgical protocols for ridge preservation after tooth extraction. A systematic review. Clin Oral Implants Res. 2012;23 Suppl 5:22-38.

115. Jokstad A, editor. Osseointegration and Dental Implants. Ames: Wiley-Blackwell; 2009. p. 448

116. Esposito M, Grusovin MG, Felice P, Karatzopoulos G, Worthington HV, Coulthard P. The efficacy of horizontal and vertical bone augmentation procedures for dental implants - a Cochrane systematic review. Eur J Oral Implantol. 2009;2(3):167-84.

117. Annibali S, Cristalli MP, Dell'Aquila D, Bignozzi I, La Monaca G, Pilloni A. Short dental implants: a systematic review. J Dent Res. 2012;91(1):25-32.

118. Davarpanah M, Martinez H, Tecucianu JF, Hage G, Lazzara R. The modified osteotome technique. Int J Periodontics Restorative Dent. 2001;21(6):599-607.

119. Stanley J, Nelson M. Wheeler's Dental Anatomy, Physiology and Occlusion, 9th ed. St. Louis: Saunders/Elsevier; 2010. p. 368

120. Esposito M, Pellegrino G, Pistilli R, Felice P. Rehabilitation of postrior atrophic edentulous jaws: prostheses supported by 5 mm short implants or by longer implants in augmented bone? One-year results from a pilot randomised clinical trial. Eur J Oral Implantol. 2011;4(1):21-30.

121. Van Assche N, Michels S, Quirynen M, Naert I. Extra short dental implants supporting an overdenture in the edentulous maxilla: a proof of concept. Clin Oral Implants Res. 2012;23(5):567-76.

122. Romeo E, Bivio A, Mosca D, Scanferla M, Ghisolfi M, Storelli S. The use of short dental implants in clinical practice: literature review. Minerva Stomatol. 2010;59(1-2):23-31.

123. Atieh MA, Ibrahim HM, Atieh AH. Platform switching for marginal bone preservation around dental implants: a systematic review and meta-analysis. J Periodontol. 2010;81(10):1350-66.

124. Morton D, Ganeles J. ITI treatment guide, volume 2. Loading protocols in implant dentistry: Partially Dentate Patients. In: Wismeijer D, Buser D, Belser U, editors. Berlin: Quintessence; 2007. p. 161

125. Wismeijer D, Casentini P, Gallucci GO, Chiapasco M. ITI Treatment Guide, volume 4. Loading Protocols in Implant Dentistry-Edentulous Patients. In: Wismeijer D, Buser D, Belser U, editors., Berlin: Quintessence; 2010. p. 248

126. Grütter L, Belser UC. Implant loading protocols for the partially edentulous esthetic zone. Int J Oral Maxillofac Implants. 2009;24 Suppl:169-79.

127. Lindh C, Petersson A, Klinge B. Measurements of distances related to the mandibular canal in radiographs. Clin Oral Implants Res. 1995;6(2):96-103.

128. Tyndall DA, Brooks SL. Selection criteria for dental implant site imaging: a position paper of the American Academy of Oral and Maxillofacial radiology. Oral Surg Oral Med Oral Pathol Oral Radiol Endod. 2000;89(5):630-7.

129. Rangert B, Jemt T, Jörneus L. Forces and moments on Branemark implants. Int J Oral Maxillofac Implants. 1989;4(3):241-7.

130. Babbush CA, Kanawati A, Brokloff J. A new approach to the All-on-Four treatment concept using narrow platform NobelActive implants. J Oral Implantol. 2013;39(3):314-25.

131. Maló P, de Araújo Nobre M, Lopes A, Ferro A, Gravito I. All-on-4® Treatment Concept for the Rehabilitation of the Completely Edentulous Mandible: A 7-Year Clinical and 5-Year Radiographic Retrospective Case Series with Risk Assessment for Implant Failure and Marginal Bone Level. Clin Implant Dent Relat Res. 2015;17 Suppl 2:531-41.

132. Lopes A, Maló P, de Araújo Nobre M, Sanchez-Fernández E. The NobelGuide® All-on-4® Treatment Concept for Rehabilitation of Edentulous Jaws: A Prospective Report on Medium- and Long-Term Outcomes. Clin Implant Dent Relat Res. 2015;17 Suppl 2:406-16.

133. Thumati P, Reddy M, Mahantshetty M, Manwani R.“All-On-4/ DIEM 2” A concept to rehabilitate completely resorbed edentulous arches. J Dent Implant. 2005;5(1): 76-81.

134. Brånemark PI, Svensson B, van Steenberghe D. Ten-year survival rates of fixed prostheses on four or six implants ad modum Brånemark in full edentulism. Clin Oral Implants Res. 1995;6(4):227-31.

7. CV

Argjend Haxhosaj was born on May 15, 1981 in Decani, Republic of Kosovo. He finished primary school in Decani, after which he enrolled in the Bedri Pejani Gymnasium in Peja (science and mathematics). He enrolled at the Faculty of Dentistry of the University of Prishtina in the academic year 2004/2005 and graduated in 2012. Since 2010, he has been working with his father in a private dental practice “Diesa Dental Clinic” in Peja. In 2017, he enrolled in the postgraduate specialist study Dental Implantology at the Faculty of Dentistry, University of Zagreb.